











Long-Term Clinical and Radiologic Outcomes after Stent-Graft Placement for the Treatment of Late-Onset Post-Pancreaticoduodenectomy Arterial Hemorrhage

췌십이지장절제술 후 발생한 후기 출혈에서 스텐트-그라프트를 이용한 치료의 장기적 임상, 영상의학적 결과

Woo Jin Kim, MD¹ , Chang Ho Jeon, MD¹ , Hoon Kwon, MD¹ ,
Jin Hyeok Kim, MD² , Ung Bae Jeon, MD^{2,3} , Suk Kim, MD^{1,3} ,
Hyung Il Seo, MD⁴ , Chang Won Kim, MD^{1,3*} 

Departments of ¹Radiology and ⁴Surgery, Pusan National University Hospital, Busan, Korea
²Department of Radiology, Pusan National University Yangsan Hospital, Yangsan, Korea
³Department of Radiology, School of Medicine, Pusan National University, Yangsan, Korea

Purpose To evaluate the long-term radiologic and clinical outcomes of stent-graft placement for the treatment of post-pancreaticoduodenectomy arterial hemorrhage (PPAH) based on the imaging findings of stent-graft patency and results of liver function tests.

Materials and Methods We retrospectively reviewed the medical records of nine consecutive patients who underwent stent-graft placement for PPAH between June 2012 and May 2017. We analyzed the immediate technical and clinical outcomes and liver function test results. Stent-graft patency was evaluated using serial CT angiography images.

Results All stent-grafts were deployed in the intended position for the immediate cessation of arterial hemorrhage and preservation of hepatic arterial blood flow. Technical success was achieved in all nine patients. Eight patients survived after discharge, and one patient died on postoperative day 28. The median follow-up duration was 781 days (range: 28–1766 days). Follow-up CT angiography revealed stent-graft occlusion in all patients. However, serum aspartate aminotransferase or alanine aminotransferase levels in all patients were well below those observed in hepatic infarction cases.

Received August 3, 2020
Revised September 14, 2020
Accepted September 16, 2020









***Corresponding author**

Chang Won Kim, MD
Department of Radiology,
Pusan National University
Hospital, 179 Gudeok-ro,
Seo-gu, Busan 49241, Korea.

Tel 82-51-240-7354
Fax 82-51-244-7534
E-mail radkim@nate.com

This is an Open Access article distributed under the terms of the Creative Commons Attribution Non-Commercial License (<https://creativecommons.org/licenses/by-nc/4.0>) which permits unrestricted non-commercial use, distribution, and reproduction in any medium, provided the original work is properly cited.

ORCID iDs

Woo Jin Kim 
[https://
orcid.org/0000-0001-7425-2196](https://orcid.org/0000-0001-7425-2196)
Chang Ho Jeon 
[https://
orcid.org/0000-0002-1762-5379](https://orcid.org/0000-0002-1762-5379)
Hoon Kwon 
[https://
orcid.org/0000-0003-4055-5863](https://orcid.org/0000-0003-4055-5863)
Jin Hyeok Kim 
[https://
orcid.org/0000-0001-6703-2419](https://orcid.org/0000-0001-6703-2419)
Ung Bae Jeon 
[https://
orcid.org/0000-0002-7731-162X](https://orcid.org/0000-0002-7731-162X)
Suk Kim 
[https://
orcid.org/0000-0003-3268-1763](https://orcid.org/0000-0003-3268-1763)
Hyung Il Seo 
[https://
orcid.org/0000-0002-4132-7662](https://orcid.org/0000-0002-4132-7662)
Chang Won Kim 
[https://
orcid.org/0000-0001-7853-5580](https://orcid.org/0000-0001-7853-5580)

Conclusion Stent-graft placement is a safe and effective treatment method for acute life-threatening PPAH. Liver function and distal hepatic arterial blood flow were maintained postoperatively despite the high incidence of stent-graft occlusion observed on follow-up CT.

Index terms Embolization, Therapeutic; Liver Function Tests; Pancreaticoduodenectomy; Postoperative Hemorrhage; Stent

INTRODUCTION

Surgical resection is the standard treatment for localized periampullary cancer. In particular, when surgery is not contraindicated, pancreaticoduodenectomy (PD) or pylorus-preserving pancreaticoduodenectomy (PPPD) with negative resection margins are the typical treatments for localized periampullary cancer. However, PD and PPPD are complex procedures, and are, therefore, fraught with various complications. Post-pancreaticoduodenectomy arterial hemorrhage (PPAH) is an uncommon but fatal complication of PD or PPPD (1). The incidence and mortality rates of PPAH are reported to be 3% to 5% and up to 60%, respectively (2, 3). PPAH can be differentiated into early- and late-onset according to the definition of the International Study Group of Pancreatic Surgery (4). Early-onset PPAH occurs within 24 h of the end of the surgical procedure and is usually caused by technical failure, incomplete hemostasis, or inadequate management of coagulation disorders; late-onset PPAH is mostly caused by rupture of a pseudoaneurysm, with inflammatory erosion of the arterial wall or erosive bleeding of the skeletonized vessels (1). Surgical treatment of late-onset PPAH is difficult, due to the friability of the surrounding postsurgical tissue and adhesions (5, 6). Endovascular treatment plays an important role in the management of late-onset PPAH, since it has been proven to be clinically effective for treating PPAH (7, 8). The endovascular treatment modalities include coil embolization and stent-graft placement. Although the superiority of one technique over the other is unclear, stent-grafting is preferred because it is thought to preserve hepatic arterial flow and poses a lower risk of ischemic injury (9). Several studies have shown that stent-grafting provides effective hemostasis for treating PPAH (1, 7, 9, 10). Therefore, stent-graft placement is recommended as a first-line treatment for extrahepatic arterial hemorrhage that is not accompanied by any anatomical limitations (7, 11).

However, even though endovascular treatment has proved to be effective for late-onset PPAH in the short-term, no study has reported the long-term follow-up of the patency of stent-grafts placed for the treatment of late-onset PPAH. In this study, we evaluated the long-term radiologic and clinical outcomes after stent-graft placement for the treatment of late-onset PPAH, based on radiologic evaluation of stent-graft patency, and liver function tests (LFTs)—serum aspartate aminotransferase (AST) and alanine aminotransferase (ALT) levels.

MATERIALS AND METHODS

PATIENT CHARACTERISTICS

This retrospective study was approved by the Institutional Review Board (IRB No. H-1807-

006-068). The requirement to obtain informed consent was waived. Nine patients with late-onset PPAH (age range: 61–75 years) who were treated using stent-grafts between June 2012 and May 2017 were included in the study. The underlying malignancies included common bile duct cancer, pancreatic head cancer, and ampulla of Vater cancer. The patients' characteristics are summarized in Table 1. The bleeding culprit pseudoaneurysm was confirmed using follow-up CT 8 to 55 (mean: 25.56 ± 12.89) days after PD or PPPD. Clinical manifestations that led to CT evaluation included abdominal pain ($n = 1$, 11.1%), melena ($n = 1$, 11.1%), a sudden change in Jackson–Pratt (JP) drain discharge from serous to bloody fluid ($n = 2$, 22.2%), dizziness with a sudden change in JP drain discharge from serous to bloody fluid ($n = 2$, 22.2%), abdominal pain with a sudden change in JP drain discharge from serous to bloody fluid ($n = 1$, 11.1%), and melena with a sudden change in JP drain discharge from serous to bloody fluid ($n = 2$, 22.2%).

INTERVENTIONAL PROCEDURES

Interventional management was performed within 24 h of performing CT. Conventional angiography was performed with a digital subtraction angiography unit (AXIOM Artis Zee; Siemens Medical Solutions, Malvern, PA, USA). A 5-French (Fr) sheath and a 5-Fr diagnostic catheter (Rosch hepatic or Cobra, Cook Medical, Bloomington, IN, USA) were introduced over a 0.035-inch guidewire, after puncture of either the right or left femoral artery. All patients underwent angiography of the superior mesenteric artery and common hepatic artery. Common hepatic angiography was used to determine the location of the bleeding culprit pseudoaneurysm and for evaluation of vascular tortuosity; the diameter and length of the proper and common hepatic arteries were measured subsequently. The diameter of the artery with the bleeding culprit pseudoaneurysm was also measured preoperatively using CT.

The size of the stent-graft to be deployed was determined based on the CT and conventional angiography parameters. The catheter and 5-Fr sheath were removed after placing a 0.035-inch, 260-cm long hydrophilic stiff or extra-stiff guidewire (Rosen, Cook Medical, Bloomington, IN, USA) via a catheter. A 7-Fr introducer sheath was subsequently introduced over the

Table 1. Baseline Characteristics of Patients

Patient	Age (Years)	Sex	Underlying Malignancy	Type of Surgery	Interval between Surgery and Interventional Procedure (Days)
1	72	M	CBD cancer	PPPD	55
2	72	M	CBD cancer	PPPD	14
3	65	M	AoV cancer	PPPD	22
4	72	M	CBD cancer	PPPD	29
5	61	M	CBD cancer	PD	22
6	75	F	CBD cancer	PPPD	27
7	75	M	Pancreatic head cancer	PPPD	18
8	63	M	AoV cancer	PPPD	35
9	63	M	Pancreatic head cancer	PD	8

AoV = ampulla of Vater, CBD = common bile duct, PD = pancreaticoduodenectomy, PPPD = pylorus-preserving pancreaticoduodenectomy

guidewire, near the orifice of the celiac artery, and a stent-graft was introduced over the guidewire and deployed across the bleeding culprit lesion. Viabahn (W.L. Gore and Associates, Flagstaff, AZ, USA) endoprosthesis stent-grafts were used in all the patients. The Viabahn endoprosthesis has been widely used to treat various endovascular conditions since being approved by the United States Food and Drug Administration in 2005. Several studies have proved the safety and efficacy of the Viabahn endoprosthesis for endovascular management of bleeding pseudoaneurysms (12-14).

TECHNICAL AND CLINICAL SUCCESS ASSESSMENT

Technical success was defined as stent-graft placement at the planned position. Clinical success was defined as the sustained cessation of hemorrhage with clinical findings of hemodynamic stability and the lack of need for additional management during hospitalization. Patients were encouraged to notify doctors of the onset of new symptoms during hospitalization. After discharge, 1 to 6 months of follow-up was recommended at the outpatient clinic, along with LFTs. CT evaluation was recommended for all patients, who were encouraged to visit the emergency department in the event of abdominal pain, hematochezia, melena, dizziness, or other symptoms.

POSTOPERATIVE CT ANALYSIS AND LFT

Contrast-enhanced CT was performed within 2 weeks after stent-graft placement, for evaluating any possible postoperative complications. After discharge, CT was conducted on a 1-month to 6-month basis to evaluate for tumor recurrence or metastasis. The patency of the stent-graft was evaluated by two independent observers using CT. Patency of the stent-graft was defined if at least one or more of the following criteria were present on CT imaging:

- Presence of contrast medium within the stent-graft lumen
- Absence of low attenuation areas within the stent-graft
- Presence of contrast medium in the artery just distal to the stent-graft

Evaluation using only the attenuation within the stent-graft on CT has limited value, due to the presence of partial volume artifacts or metal artifacts of the stent-graft. Therefore, we added the criterion of attenuation of the artery immediately distal to the stent-graft. The absence of the listed criteria was defined as occlusion of the stent-graft. Disagreements between the two observers were resolved by consensus.

The serum AST and ALT levels were analyzed from the day of the stent-graft placement to a maximum period of 5 years. During hospitalization, LFT was performed either daily or on alternate days. After discharge, LFT was performed on a 1-month to 6-month basis, similar to the interval for CT at the outpatient clinic.

COMPLICATIONS

Complications associated with stent-graft placement were assessed by reviewing the medical records and postoperative CT images. This study evaluated the major and minor complications defined by the Society of Interventional Radiology clinical practice guidelines (15). We focused on complications such as stent-graft migration, stent-graft fracture, reintervention rate, and other reported complications of hepatic artery embolotherapy in patients with

PPAH, such as hepatic abscess formation and gallbladder fibrosis (16).

We observed the patients for early complications of the stent-graft deployment during the procedure and post-operative hospitalization period. Delayed complications were assessed at the follow-up visits, whether to the outpatient clinic or the emergency department. Furthermore, the follow-up CT scans and electronic medical records of the patient were reviewed for patency of the stent-graft, hepatic ischemia or infarction, and abnormal fluid collection or abscess in the perihepatic space. Complications that required extended hospitalization, an advanced level of care, or those that resulted in permanent adverse sequelae or death were classified as major complications (15); the remaining complications were considered to be minor.

STATISTICAL ANALYSES

Statistical analyses were performed using GraphPad Prism 8 software (GraphPad, La Jolla, CA, USA). Data are shown as mean \pm standard deviation or median with range. The Kaplan-Meier method was applied to evaluate the patency of stent-graft. The mean stent-graft patency duration of all patients was calculated.

RESULTS

PATIENTS' BASELINE CHARACTERISTICS

The median age of the patients was 72 years, with a range of 61 to 75 years. PPPD and PD were performed in seven and two patients, respectively. The participants' sex ratio, underlying malignancy, type of surgical procedure are summarized in Table 1. The interval between PD or PPPD and stent-graft placement was 8 to 55 days (median: 22 days, Table 1). The pres-

Table 2. Details of the Procedure and Duration of Stent-Graft Patency

Patient	Site of Pseudoaneurysm	Artery in Which Stent-Graft Was Placed	Size of Stent-Graft [diameter (mm) \times length (cm)]	Interval between Stent-Graft Placement and CT-Confirmed Obstruction (Days)
1	PHA	PHA, LHA	5 \times 5 6 \times 5	248
2	GDA stump	PHA to CHA	5 \times 2.5	70
3	GDA stump	PHA to CHA	6 \times 5	85
4	GDA stump	PHA to CHA	5 \times 5	112
5	GDA stump	PHA to CHA	5 \times 5 5 \times 2.5	328
6	GDA stump	PHA to CHA, RHA, LHA	5 \times 5	223
7	GDA stump	PHA to CHA	5 \times 2.5	Censored
8	GDA stump	PHA to CHA, RHA, LHA	6 \times 5	316
9	PHA	PHA	6 \times 2.5	40
Total patency duration (days)*			177.8 \pm 40.6	

*Data are presented as mean \pm standard deviation.

CHA = common hepatic artery, GDA = gastroduodenal artery, LHA = left hepatic artery, PHA = proper hepatic artery, RHA = right hepatic artery

ence of PPAH was confirmed as a pseudoaneurysm using CT in all patients (Fig. 1). The bleeding culprit pseudoaneurysm was located at the stump of the gastroduodenal artery (GDA) in seven patients and the proper hepatic artery in two patients.

TECHNICAL AND CLINICAL OUTCOMES

The stent-graft was placed in the intended position for blocking blood flow to the bleeding culprit pseudoaneurysm in all patients (Fig. 2). The diameter or length of the stent-graft, site of bleeding, and site (artery) of the stent-graft placement are summarized in Table 2.

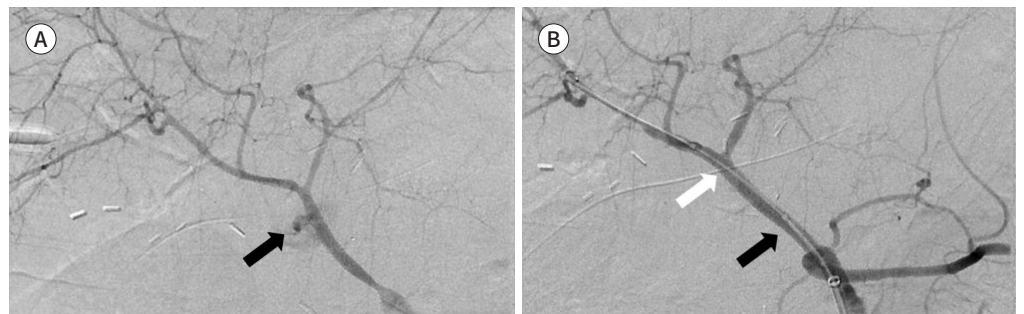
Technical success was achieved in nine patients and clinical success was achieved in eight patients. Eight patients in the clinical-success group were treated with conservative management after stent-graft placement and discharged without any additional surgical or interventional procedure (mean hospitalization: 50.13 ± 22.31 days). One patient died 28 days after stent-graft placement. According to the electronic medical records, a sudden decrease in

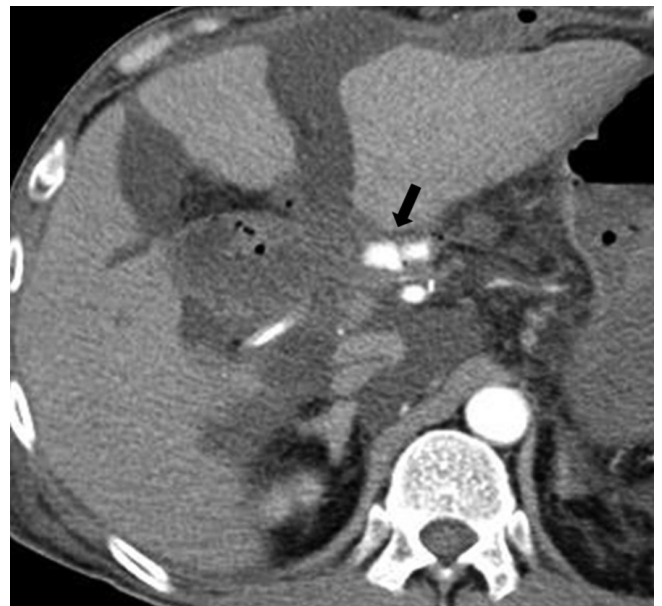

Fig. 1. The postoperative arterial-phase CT scan of patient 5 shows a bleeding culprit pseudoaneurysm at the gastroduodenal artery stump (arrow).

Fig. 2. Conventional hepatic angiogram of patient 5.

A. The hepatic angiogram reveals a ruptured pseudoaneurysm at the gastroduodenal artery stump (arrow). **B.** Satisfactory separation of the pseudoaneurysm is confirmed with the maintenance of distal circulation after placing a 5 mm × 5 cm-sized stent-graft in the appropriate position. Black and white arrows indicate the proximal and distal ends of the stent-graft, respectively.



blood pressure was observed, with abrupt drainage of bloody discharge from the JP drain 3 hours before death. Therefore, rebleeding was suspected in this patient.

STENT-GRAFT PATENCY

All CT images obtained after stent-graft placement in the nine patients were analyzed. Except for one case of clinical failure, stent-graft occlusion was confirmed in eight patients (Fig. 3). The interval between stent-graft placement and arterial occlusion confirmed by CT varied between patients, with a median stent-graft patency duration of 167.5 days (range: 40–328 days). The Kaplan-Meier curves for the cumulative patency of the stent-grafts are shown in Fig. 4.

LFT FOLLOW-UP

During the follow-up period, the mean value of the maximum AST levels between the interventional procedure and confirmation of stent-graft occlusion (on CT) was 125.63 ± 148.96 IU/L. The highest AST levels were observed to decrease to below 40 IU/L within 7 days in all patients either without treatment or with the administration of ursodeoxycholic acid (400 mg/day). Since PPAH itself can cause elevation of serum AST by reducing hepatic arterial flow, the relationship between stent-graft occlusion and AST levels could be evaluated with greater precision after the patients have recovered fully from PPAH. The mean value of the maximum AST levels between discharge and confirmation of stent-graft occlusion (on CT) was 59.25 ± 65.30 IU/L. There was no elevation in the LFT values, suggestive of hepatic infarction, in any patient.

COMPLICATIONS

There were no procedure-related deaths or major procedure-related complications, according to the categories defined by the Society for Interventional Radiology. Minor compli-

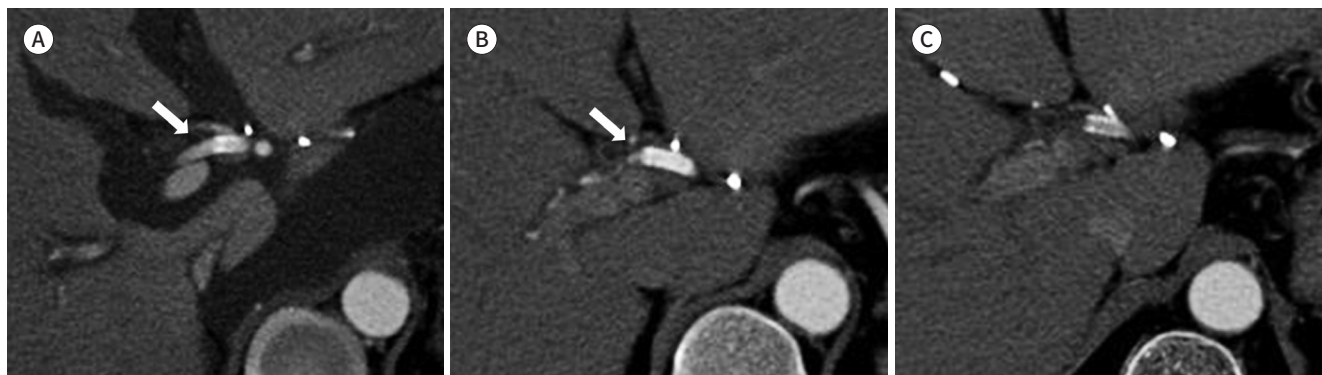Fig. 3. Postoperative follow-up CT scans of patient 5.

A. The CT scan obtained on POD 14 shows contrast medium within the stent-graft in the artery, distal to the stent-graft (arrow). Therefore, the stent-graft is considered to be patent.

B. The CT scan obtained on POD 224 shows decreased caliber of the artery, distal to the stent-graft, along with decreased flow (arrow) from the stent-graft compared to that on POD 14. However, the stent-graft is still considered to be patent.

C. The CT scan obtained on POD 449 shows a low-attenuation lesion within the stent-graft without distal arterial flow to the stent-graft; however, no hepatic ischemia or other arterial obstruction-related pathologic findings are seen in the liver.

POD = postoperative day



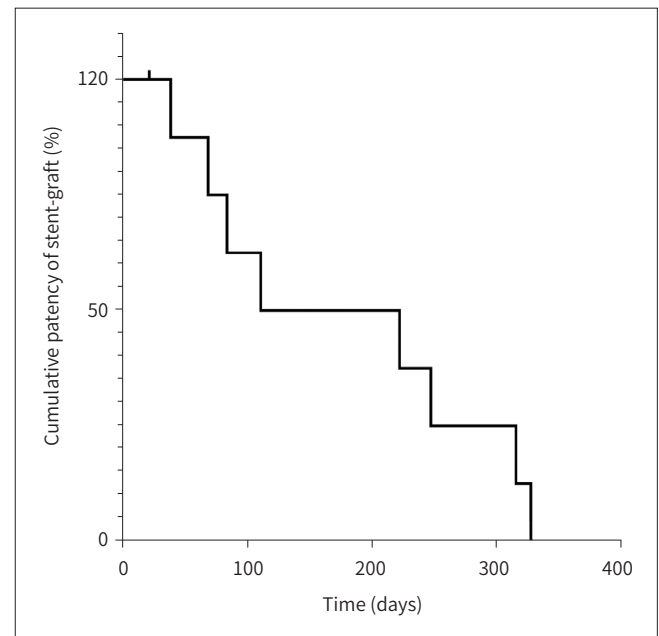


Fig. 4. The Kaplan-Meier curve for the cumulative patency of the stent-graft. The mean patency duration is 177.8 ± 40.6 days. The small vertical tick represents the observation in patient 7, whose findings are censored at the time of death.

cations were observed in 77.8% (7 of 9) of patients: abdominal or flank discomfort in 44.4% (4 of 9), nausea and vomiting in 22.2% (2 of 9), and fever in 11.1% (1 of 9) of patients. Abdominal or flank symptoms resolved either spontaneously or after the administration of analgesics and antihistamines. Blood culture was negative for microorganisms in the patient with fever, who improved after receiving both antipyretics and empirical antibiotics. Puncture site hematoma was resolved with manual compression. Stent-graft fracture, stent-graft migration, need for reintervention, and gallbladder fibrosis were not observed during follow-up.

During the follow-up period, two patients developed liver abscess. Liver abscess is one of the reported late complications of proper hepatic artery embolization; however, the pathophysiology of abscess formation is unknown (16). The intervals between stent-graft placement and confirmation of liver abscess formation (on CT) in these two patients were 320 and 519 days. Their condition was resolved without the need for further surgery, after drainage of the abscess and antibiotic treatment in one patient, and spontaneously in the other patient. Recurrence was not observed in either of these two patients.

DISCUSSION

This study reports the long-term radiologic and clinical results of PPAH treated with the Viabahn endoprosthesis. The results of our study suggest that stent-grafting is an effective treatment for bleeding, but does not ensure good long-term patency. Both liver function and distal hepatic arterial blood flow were maintained postoperatively. However, stent-graft occlusion was observed in all patients.

An interventional approach can be used to treat the various types of arterial hemorrhage that can occur during abdominal surgery. This approach ensures a good clinical outcome by reducing the risk of re-operation and providing proper control of arterial bleeding. Stent-grafting is one of the most effective treatment modalities, because it permits immediate he-

modynamic control with preservation of organ perfusion in the acute stage (8). The reported incidence of PPAH is less than 10%, but it requires immediate management due to high mortality (2, 3). CT is the standard diagnostic imaging modality for PPAH and is usually performed to evaluate postoperative complications such as abdominal pain, a sudden change in the discharge from the JP drain, or hematemesis. Not only CT is useful for diagnosis of PPAH, CT also is useful for evaluation of portal vein patency, which is important for interventional treatment of PPAH. Embolization of hepatic artery cause hepatic infarction in more than 30% of cases (17). Therefore, if portal vein is occluded in PPAH patient, stent-graft is recommended rather than embolization of hepatic artery. In our study, portal vein is patent in all patients at pre-procedure CT images.

Immediate intervention in PPAH is essential for a good prognosis because of the high risk of massive bleeding. In this study, emergency interventional procedures were performed within 6 h of performing CT in 6 of 9 patients, stent-grafts were placed in the intended position in all patients, and immediate hemostasis was confirmed using angiography. The bleeding culprit pseudoaneurysm was located at the GDA stump in 7 of 9 patients, which is concordant with reports that the GDA stump was the most common site of bleeding pseudoaneurysms (18), as well as other reports of a > 80% technical and clinical success rate of stent-grafting in late-onset PPAH (1, 7).

Although stent-grafting has advantages, it is not the perfect option for treating PPAH; occlusion of the stent-graft is one of the most clinically important complications. In our study, although stent-grafting restricted blood flow to the pseudoaneurysm, the stent-grafts were occluded within approximately 6 months of placement. Despite this, no major complications associated with arterial occlusion were observed in any of the patients. However, stent-graft occlusion can block the vascular flow, which can cause ischemic changes in organs. Although the liver is thought to be vulnerable to circulatory disturbances due to its high metabolic activity, the dual supply from the portal vein and proper hepatic artery and collateral vessels allow it to withstand occlusion of the proper hepatic artery. Collateral arteries such as the inferior phrenic arteries, intercostal arteries, and gastric arteries are not ligated during pancreatobiliary surgery. However, it is noteworthy that blood flow from the collateral vessels has been shown to be decreased compared to normal blood flow after PD or PPPD because of lymphadenectomy and skeletonization of the vasculature (7, 8). Therefore, clinicians should carefully consider that occlusion of the hepatic artery could cause hepatic infarction or hepatic failure. Indeed, a previous study by Miura et al. (6) reported that 3 of 11 patients who underwent transarterial coil embolization for pseudoaneurysms arising from hepatic arteries died of hepatic failure. Similarly, Zhang et al. (18) reported that ischemic liver injuries were found in more than 80% of patients with delayed post-hepatobiliary surgery arterial bleeding when the hepatic artery was occluded by transarterial coil embolization.

Interestingly, Gwon et al. (7) have reported that hepatic infarction was significantly associated with serum AST levels exceeding 700 IU/L and serum ALT levels exceeding 500 IU/L ($p = 0.031$) after transarterial embolization for extrahepatic artery hemorrhage after pancreatobiliary surgery. In our study, serum ALT levels were elevated above 100 IU/L within 3 days of the procedure in two patients, but were subsequently reduced below 50 IU/L after 7 days. Only one patient had elevated ALT levels above 100 IU/L between 1 week postoperatively and

a confirmation of stent-graft occlusion on CT. However, the highest levels of serum AST and ALT in this patient were 119 and 92 IU/L, respectively, which were far lower than the AST and ALT levels in patients with hepatic infarction reported by Gwon et al. (7). Since CT revealed stent-graft occlusion in 8 of 9 patients in our study, we suspect that the serum AST and ALT levels were elevated before stent-graft occlusion. Therefore, based on the LFT and CT findings, we believe that the revascularization of the occluded hepatic artery in patients with late-onset PPAH treated with stent-grafting is not necessary. One possible explanation for this is that occlusion of the stent-graft occurs gradually, thus allowing the liver to also gradually adapt to the decreased hepatic arterial flow. Moreover, the gradual occlusion also allows time for the compensatory formation of collateral extrahepatic arterial supply. Indeed, the formation of hypertrophied extrahepatic collateral arteries such as the superior mesenteric artery, inferior phrenic artery, internal mammary artery, or left gastric artery to maintain intrahepatic arterial flow was observed during follow-up (Fig. 5). If there is no relationship between hepatic infarction and the occlusion of stent-grafts placed in the hepatic artery, this will have implications for the various indications of stent-grafting. To the best of our knowledge, this is the first study to report the long-term radiologic and clinical results of PPAH treated with the Viabahn endoprosthesis, until stent-graft occlusion was observed in all patients.

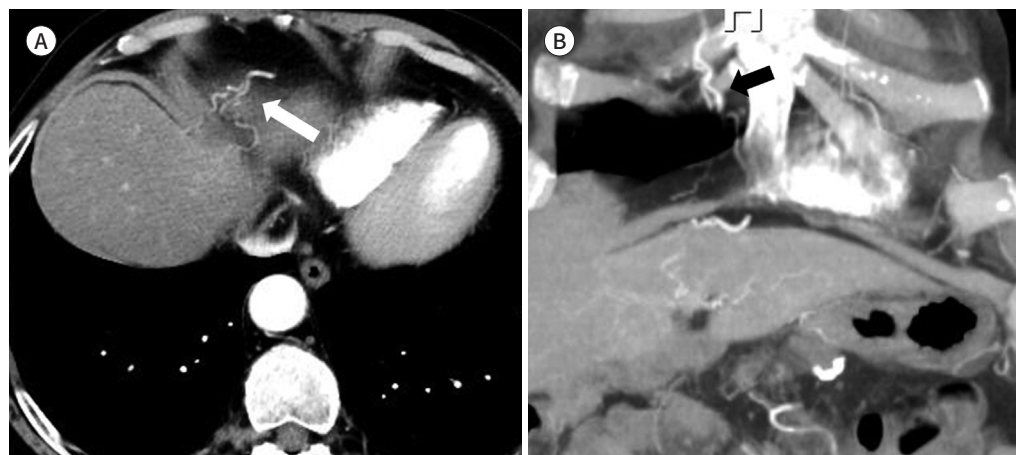
In comparison with other studies, our study shows much lower rate of stent-graft patency. Gwon et al. (7) report 85.7% of stent-graft patency in PPAH during 22.8month of follow up and You et al. (19) report 63.2% of stent-graft patency in PPAH during 24month of follow up. The reason that our study shows low stent-graft patency is because diameter of stent-grafts used in our study is smaller than other studies. Mean diameter of stent-grafts in our study is 5.4 mm and 7.4 mm for Gwon's study (7) and 8.0 mm for You's study (19). This difference of stent-graft diameter leads to discrepancy of stent-graft patency between studies.

The technical difficulty of stent-graft placement in late-onset PPAH should be acknowledged. Stent-grafting is not always possible, especially for the celiac trunk and its branches,

Fig. 5. Collateral arterial blood supply from extrahepatic arteries.

A. The CT scan obtained on postoperative day 898 in patient 3 shows that the collateral artery originates from the right internal mammary artery, which supplies blood to the liver (arrow).

B. The coronal reformatted image also shows the collateral arterial supply to the liver parenchyma in the same patient (arrow).



which are tortuous. In our study, the stent-graft was placed by passing a stiff guidewire through the celiac trunk to reach the right hepatic artery and inserting the guiding catheter deeply. Although we successfully performed stent-grafting in all patients, it may be technically impossible in some cases. Other endovascular management modalities, such as coil embolization, should be considered in such cases.

Our study had some limitations. It was a single-center retrospective study and had a relatively small sample size. Thus, further studies are needed to investigate the relationship between stent-graft occlusion and liver function.

In conclusion, stent-grafting could be an effective option for treating PPAH. Although stent-graft occlusion may occur after approximately 6 months of placement, it does not cause abnormal liver function.

Author Contributions

Conceptualization, J.C.H., K.C.W.; data curation, K.W.J., J.C.H.; formal analysis, K.W.J., J.C.H.; investigation, K.W.J., J.C.H.; methodology, K.W.J., J.C.H.; validation, all authors; visualization, K.W.J., J.C.H.; writing—original draft, K.W.J., J.C.H., K.C.W.; and writing—review & editing, all authors.

Conflicts of Interest

Chang Ho Jeon and Ung Bae Jeon have been an Editorial Board Member and Section Editor of Journal of the Korean Society of Radiology, since 2021; however, they were not involved in the peer reviewer selection, evaluation, or decision process of this article. Otherwise, no other potential conflicts of interest relevant to this article were reported.

Funding

This work was supported by a 2-year Research Grant of Pusan National University.

REFERENCES

- Huo Y, Chi J, Zhang J, Liu W, Liu D, Li J, et al. Endovascular intervention for delayed post-pancreaticoduodenectomy hemorrhage: clinical features and outcomes of transcatheter arterial embolization and covered stent placement. *Int J Clin Exp Med* 2015;8:7457-7466
- Khalsa BS, Imagawa DK, Chen JI, Dermirjian AN, Yim DB, Findeiss LK. Evolution in the treatment of delayed postpancreatectomy hemorrhage: surgery to interventional radiology. *Pancreas* 2015;44:953-958
- Treckmann J, Paul A, Sotiropoulos GC, Lang H, Ozcelik A, Saner F, et al. Sentinel bleeding after pancreaticoduodenectomy: a disregarded sign. *J Gastrointest Surg* 2008;12:313-318
- Wente MN, Veit JA, Bassi C, Dervenis C, Fingerhut A, Gouma DJ, et al. Postpancreatectomy hemorrhage (PPH): an International Study Group of Pancreatic Surgery (ISGPS) definition. *Surgery* 2007;142:20-25
- De Castro SM, Kuhlmann KF, Busch OR, Van Delden OM, Laméris JS, Van Gulik TM, et al. Delayed massive hemorrhage after pancreatic and biliary surgery: embolization or surgery? *Ann Surg* 2005;241:85-91
- Miura F, Asano T, Amano H, Yoshida M, Toyota N, Wada K, et al. Management of postoperative arterial hemorrhage after pancreato-biliary surgery according to the site of bleeding: re-laparotomy or interventional radiology. *J Hepatobiliary Pancreat Surg* 2009;16:56-63
- Gwon DI, Ko GY, Sung KB, Shin JH, Kim JH, Yoon HK. Endovascular management of extrahepatic artery hemorrhage after pancreatobiliary surgery: clinical features and outcomes of transcatheter arterial embolization and stent-graft placement. *AJR Am J Roentgenol* 2011;196:W627-W634
- Wang MQ, Liu FY, Duan F, Wang ZJ, Song P, Fan QS. Stent-grafts placement for treatment of massive hemorrhage from ruptured hepatic artery after pancreaticoduodenectomy. *World J Gastroenterol* 2010;16:3716-3722
- Ching KC, Santos E, McCluskey KM, Orons PD, Bandi R, Friend CJ, et al. Covered stents and coil embolization for treatment of postpancreatectomy arterial hemorrhage. *J Vasc Interv Radiol* 2016;27:73-79
- Sanjay P, Kellner M, Tait IS. The role of interventional radiology in the management of surgical complica-

tions after pancreatoduodenectomy. *HPB (Oxford)* 2012;14:812-817

11. Sato A, Yamada T, Takase K, Matsuhashi T, Higano S, Kaneda T, et al. The fatal risk in hepatic artery embolization for hemostasis after pancreatic and hepatic surgery: importance of collateral arterial pathways. *J Vasc Interv Radiol* 2011;22:287-293
12. Chen AY, Laniado I Jr, Lin PH. Durability of the Viabahn stent graft after axillary artery pseudoaneurysm exclusion. *J Vasc Surg Cases Innov Tech* 2017;3:99-101
13. Ouchi T, Kato N, Nakajima K, Higashigawa T, Hashimoto T, Chino S, et al. Splenic artery aneurysm treated with endovascular stent grafting: a case report and review of literature. *Vasc Endovascular Surg* 2018;52:663-668
14. Zaghlool D, Franz R. Treatment of a high large extracranial carotid artery pseudoaneurysm from trauma using a Viabahn graft. *Ann Vasc Surg* 2015;29:837.e1-7
15. Sacks D, McClenny TE, Cardella JF, Lewis CA. Society of Interventional Radiology clinical practice guidelines. *J Vasc Interv Radiol* 2003;14:S199-S202
16. Christensen T, Matsuoka L, Heestand G, Palmer S, Mateo R, Genyk Y, et al. Iatrogenic pseudoaneurysms of the extrahepatic arterial vasculature: management and outcome. *HPB (Oxford)* 2006;8:458-464
17. Biondetti P, Fumarola EM, Ierardi AM, Carrafiello G. Bleeding complications after pancreatic surgery: interventional radiology management. *Gland Surg* 2019;8:150-163
18. Zhang J, Qian HG, Leng JH, Qiu H, Wu JH, Liu BN, et al. Ischemic liver injury after complete occlusion of hepatic artery in the treatment of delayed postoperative arterial bleeding. *J Gastrointest Surg* 2015;19:2235-2242
19. You Y, Choi SH, Choi DW, Heo JS, Han IW, Han S, et al. Long-term clinical outcomes after endovascular management of ruptured pseudoaneurysm in patients undergoing pancreaticoduodenectomy. *Ann Surg Treat Res* 2019;96:237-249

취십이지장절제술 후 발생한 후기 출혈에서 스텐트-그라프트를 이용한 치료의 장기적 임상, 영상의학적 결과

김우진¹ · 전창호¹ · 권 훈¹ · 김진혁² · 전용배^{2,3} · 김 석^{1,3} · 서형일⁴ · 김창원^{1,3*}

목적 간 기능 검사와 영상 소견을 기반으로 하여 취십이지장절제술 후 발생한 후기 출혈에서 스텐트-그라프트를 이용한 치료의 장기적 영상의학적, 임상적 경과를 보고자 한다.

대상과 방법 2012년 6월부터 2017년 5월까지 취십이지장절제술 후 발생한 후기 출혈로 스텐트-그라프트 삽입술을 받은 9명의 환자를 후향적으로 분석하였다. 저자들은 시술 직후 술기적, 임상적 결과와 간 기능 검사를 검토하였다. 스텐트-그라프트의 개통성은 CT angiography를 이용하여 평가하였다.

결과 모든 스텐트-그라프트는 즉각적인 동맥 출혈을 멈추면서 간동맥 혈류를 유지할 수 있도록 의도했던 위치에 배치되었다. 기술적 성공은 모든 9명의 환자에게서 이루어졌다. 8명의 환자는 시술 후 생존하여 퇴원하였으며 한 명의 환자는 시술 28일 후 사망하였다. 평균 추적 관찰 기간은 781일이었다(범위: 28~1766일). 추적관찰 CT angiography에서 모든 환자의 스텐트-그라프트는 폐쇄되었다. 그러나 모든 환자들에서 간 경색을 시사할 만한 혈중 아스파르테이트아미노전달효소나 알라닌아미노전달효소 수치 증가를 보이지 않았다.

결론 스텐트-그라프트 삽입술은 취십이지장절제술 후 발생한 생명을 위협하는 후기 출혈의 안전하고 효과적인 치료이다. 간 기능과 간 말단부 동맥혈 공급은 추적관찰 CT상 스텐트-그라프트가 높은 확률로 막힘에도 불구하고 유지된다.

부산대학교병원 ¹영상의학과, ⁴외과,
²양산부산대학교병원 영상의학과,
³부산대학교 의과대학 영상의학교실