



Steroid-induced Psychosis in Adolescent Patient with Crohn's Disease

Jin Woo Kim¹, Ki Soo Kang², and Na Ri Kang³

¹Medical Course, Jeju National University School of Medicine, Jeju, Korea

²Department of Pediatrics, Jeju National University School of Medicine, Jeju, Korea

³Department of Psychiatry, Jeju National University School of Medicine, Jeju, Korea

Crohn's disease is a chronic inflammatory disease that involves the upper and lower gastrointestinal tracts, including the oral cavity. For the conventional treatment of inflammatory bowel diseases, steroids are usually used as induction therapy, and azathioprine is used as maintenance therapy. Steroids are associated with various side effects. Under rare circumstances, they can even cause psychotic symptoms, and reports on steroid-induced psychosis in the pediatric population are few. Here, we report the first case of steroid-induced psychosis in a 16-year-old female with Crohn's disease administered with steroids as induction therapy in South Korea. She showed psychotic symptoms, including auditory hallucination, loosening of association, and idea of reference, after 2 weeks of administering prednisolone 60 mg/day. One week after steroid discontinuation, the patient gradually recovered and was treated with quetiapine. Therefore, pediatricians should be aware of serious psychiatric adverse effects when administering corticosteroids for various indications.

Key Words: Crohn's disease; Steroid; Psychosis; Adolescent.

Received: May 22, 2020 / Revision: June 4, 2020 / Accepted: June 8, 2020

Address for correspondence: Na Ri Kang, Department of Psychiatry, Jeju National University School of Medicine, 15 Aran 13-gil, Jeju 63241, Korea
Tel: +82-64-717-1850, Fax: +82-64-717-1849, E-mail: lnaree@hanmail.net

INTRODUCTION

Crohn's disease is a chronic inflammatory disease that involves the upper and lower gastrointestinal tracts, including the oral cavity. Along with ulcerative colitis, it is classified as a subtype of inflammatory bowel disease (IBD). While the etiology of Crohn's disease has not been clearly identified, it is generally known to result from the combined effects of genetic disposition, intestinal microbiota imbalance, inappropriate immune response, and various environmental factors. The incidence of IBD among children and adolescents is reportedly 10 per 100,000 in the United States and Canada, and steroids are commonly used as an effective treatment for inducing clinical remission, with mucosal healing achieved in approximately 1/3 of the pediatric patients [1]. However, long-term steroid use causes various adverse effects, including growth retardation in pediatric patients [2] and neuropsychiatric complications, such as depression, agitation, mood lability, anxiety, delusion, and psychosis. Among such complications, a rare case of steroid-induced psychosis has been reported [3], but no such case has been reported for pediatric patients with IBD in South Korea. We experienced a case of

steroid-induced psychosis that occurred in a pediatric patient with Crohn's disease after administration of prednisolone as induction therapy. Herein, we report the case together with a literature review.

CASE REPORT

A 16-year-old female visited our pediatric department because of repeated episodes of diarrhea over 3 months. She was admitted for evaluation of chronic diarrhea. She had a height of 154.3 cm and weight of 44.6 kg, both of which corresponded to the 10–25 percentile on the growth chart. Laboratory tests performed at admission showed a slightly reduced hemoglobin level (11.2 g/dL), elevated C-reactive protein level (2.58 mg/dL) and erythrocyte sedimentation rate (78 mm/h), and normal albumin (4 g/dL) and total protein (7.7 g/dL) levels. The calprotectin level in her stool sample was elevated at 3,094 mg/kg. Additional diagnostic immunoassay showed positive findings for the anti-saccharomyces cerevisiae antibody IgG at 52.2 units. Colonoscopy findings identified multiple superficial ulcers in the terminal ileum, while esophagogastroduodenoscopy and capsule endoscopy findings identified aphthous ulcers in the small intestine, including the duodenum. Based on these findings, she was diagnosed with Crohn's disease with A1b, L1/4a, B1p in the Paris Classi-

This is an Open Access article distributed under the terms of the Creative Commons Attribution Non-Commercial License (<https://creativecommons.org/licenses/by-nc/4.0>) which permits unrestricted non-commercial use, distribution, and reproduction in any medium, provided the original work is properly cited.

fication, and her pediatric Crohn's disease activity index (PCDAI) score at the time was 15 points, indicating mild activity with involvement of the small intestine. Accordingly, she was started on steroid induction therapy using prednisolone (60 mg/day, P.O.). She was also prescribed with mesalazine (2,000 mg/day, P.O.) and azathioprine (50 mg/day, P.O.).

The patient began to experience anxiety, depression, and mood changes 2 weeks after starting steroid induction therapy. Therefore, after 3 weeks, the prednisolone dose was reduced from 60 to 40 mg/day, with a reduction of 5 mg/day every 2 days, at the pediatric outpatient department visits. Even after dose reduction, she complained of difficulties at school and showed signs of worsening mood swings. Accordingly, based on the suspicion of mood changes caused by steroid administration, the prednisolone dose was reduced further to 20 mg/day. However, the patient became more paranoid and exhibited incoherent speech due to diminished reality testing, while presenting with progression of psychotic symptoms, including auditory hallucinations. Consequently, prednisolone was discontinued after admission. On pediatric ward admission day 2, she became more irritable, began to suddenly lie on the floor of the ward or scream, exhibited incoherent speech, became averse to sleeping due to anxiety attacks claiming someone is watching her, and complained about auditory hallucinations of others talking negatively about her. As a result, we consulted the department of neuropsychiatry. The mental status examination performed at the time indicated that her general appearance showed good hygiene, but she had poor eye contact and could not concentrate during the interview. She

also exhibited incoherent speech and irrelevant answers; labile, irritable moods; and inappropriate affect. In perception, she exhibited signs of auditory hallucination, claiming she heard voices of children throughout the day and a voice of concern during nighttime. In thought process, she exhibited loosening of association, along with the idea of reference and tangentiality. Based on these signs and symptoms, she was assessed to be in a psychotic state and transferred to the neuropsychiatry ward on the 9th day of hospitalization. The PCDAI score at the time of transfer was 35 points, which indicated worsening to moderate activity. Induction therapy with infliximab (IV, 200 mg) was planned, and two rounds of therapy were subsequently administered. During her stay at the neuropsychiatry ward, quetiapine was administered (starting from 12.5 mg and escalated up to 300 mg/day over 2 weeks) to control her psychotic behavior and agitation caused by loss of reality testing. Within 1 week after discontinuation of steroid therapy, her symptoms of auditory hallucination and persecutory ideation improved, and after 2 weeks, remission of anxiety and idea of reference were achieved. Subsequently, she remained in a stable condition and was therefore discharged. Over a period of approximately 3 months after the discharge, the quetiapine dose was gradually reduced to 150 mg/day by the neuropsychiatric outpatient department, and she remained in remission stably without any recurrence. However, she was lost to follow-up because of a change of residence (Fig. 1). For Crohn's disease, two rounds of infliximab were administered during the pediatric outpatient follow-ups, including the third induction therapy and first maintenance therapy. During those

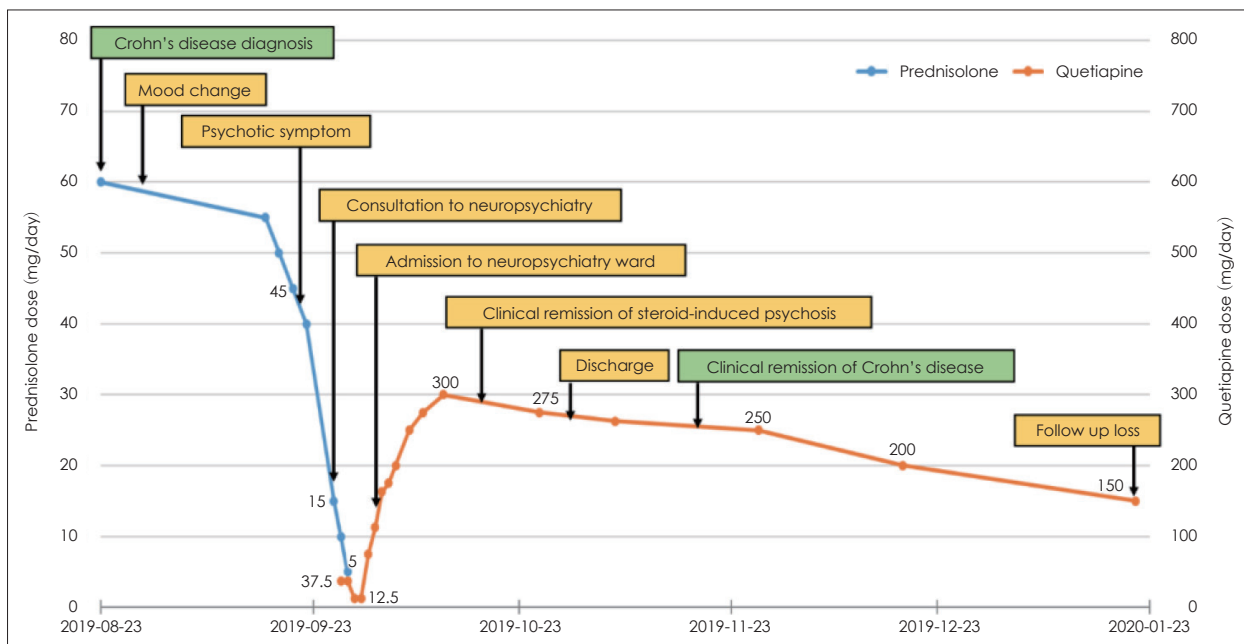


Fig. 1. Clinical timeline of the case report events.

times, her PCDAI scores were 5 and 2.5 points, respectively, indicating that she remained in remission.

DISCUSSION

Steroid-induced psychosis is classified as a substance/medication-induced psychotic disorder in the Diagnostic and Statistical Manual of Mental Disorders-5th edition (DSM-5) [4]. According to the DSM-5 diagnostic criteria for substance/medication-induced psychotic disorder, the patient must experience episodes of delusion or hallucination during or after being exposed to medication or a particular substance. In addition, such symptoms must not be explained by a non-substance/medication-induced psychotic disorder. Finally, the symptoms must also cause clinically significant distress or functional impairment. Moreover, it is necessary to rule-out other factors that could cause neuropsychiatric symptoms, such as electrolyte imbalance, infection, and hypoglycemia or hyperglycemia [5]. The patient in our case had no specific underlying disease, including psychiatric disorders, except for hemorrhoid surgery, which she had undergone 1 year prior to her first admission. After being diagnosed with Crohn's disease, the patient began exhibiting mood changes 2 weeks after starting the induction therapy with prednisolone, which gradually progressed to psychotic symptoms, such as inappropriate affect, loosening of association, auditory hallucination, and idea of reference. Symptoms persisted for up to 1 week after discontinuing steroid therapy and improved thereafter. We determined that 5-aminosalicylates used together with steroids may cause serious hematologic disorder, such as aplastic anemia [6], but it is not likely to cause psychotic symptoms, while azathioprine, also known as an immunomodulator, may cause adverse events, such as pancreatitis or bone marrow suppression [7], but they also cannot trigger psychotic symptoms. Blood tests, including electrolyte tests, were unremarkable. No other findings indicative of other causes that could induce psychotic symptoms were present. Consequently, she was diagnosed with steroid-induced psychosis. Moreover, non-medication-induced psychosis should have been excluded as well in our case but considering that temporality was found between steroid administration by induction therapy and manifestation of symptoms as well as the fact that the psychotic symptoms improved and sufficient remission was achieved shortly after discontinuing steroid therapy and using relatively low-dose anti-psychotic medication and the patient remained stable state over a certain period, we determined that this case corresponded to steroid-induced psychosis.

The pathophysiology of steroid-induced psychosis is not widely known, but what was known is that synthetic steroids activate glucocorticoid receptors to interfere with the cortical

pathway of the hypothalamic-pituitary-adrenal axis, which causes mood disorders [5]. Moreover, steroids could impact the monoamine level, and it has been identified that large quantities of glucocorticoids could elevate the dopamine level to have a neurological effect [8]. It is believed that the impact on actions of such monoamine neurotransmitters is associated with psychiatric complications.

According to a 2018 study by Hodgins et al. [9], 13 cases of steroid-induced psychosis in pediatric patients have been reported to date. The age of the patients in these cases ranged between 5 and 17 years, and there were more male (n=9) than female (n=4). Underlying diseases included asthma, nephrotic syndrome, systemic erythematosus lupus, and acute lymphoblastic leukemia. The administered dose of steroids ranged between 25 and 200 mg/day. The duration between the start of steroid therapy to manifestation of psychotic symptoms varied, from as short as 1 day to as long as 4 months, and the patients exhibited various symptoms, including anxiety, hallucination, delusion, bizarre behavior, auditory hallucination, mood change, and insomnia. While some patients showed improvement after discontinuation of steroid therapy, most required the use of anti-psychotic medication [9]. In our case, prednisolone (60 mg/day) was used, and after 2 weeks from the start of steroid administration, the patient began exhibiting mood changes, subsequently leading to psychotic symptoms. Psychotic symptoms persisted for up to 1 week after discontinuation of steroid therapy, but remission was achieved after treatment with anti-psychotic medication. Patients in previously reported cases mostly exhibited symptoms within 2 weeks, particularly within 3–4 days after starting the steroid therapy, but psychotic symptoms may appear any time, even after the discontinuation of treatment, and last from several days to several weeks [10,11].

Considering the literature review on steroid-induced psychosis in pediatric patients [9] and our case, the duration between the start of steroid therapy and manifestation of symptoms varies significantly among adolescents. This is reportedly due to adolescents having low drug bioavailability and a fast metabolism as well as less volume of distribution than adults, making it difficult to predict dose adjustment for response to the drug [9]. With respect to steroid-induced psychosis in pediatric patients with Crohn's disease a case involving a 17-year-old female had been previously reported. In that case, the patient began to exhibit mood changes with steroid administration of 5–25 mg/day and psychotic symptoms when the dose was escalated to 40 mg/day. Subsequently, she achieved remission of psychotic symptoms with anti-psychotic drug therapy after discontinuation of steroid therapy [12]. To date, there had been no reported case in South Korea on steroid-induced psychosis in pediatric patients with underly-

ing Crohn's disease. In our case, similar to previous reports, the patient showed a steroid-induced onset of mood changes and a gradual progression to psychotic symptoms. Based on this, it is worth considering the possibility that mood change is a common sign of steroid-induced neuropsychiatric complications and that it may be an early indication of progression to steroid-induced psychosis in some cases.

Treatments for steroid-induced psychosis in pediatric patients have not been systematically studied. However, the most important first-line treatment for steroid-induced psychosis is discontinuation of the steroid that induced psychosis. While some patients may see improvement in symptoms and recovery just by discontinuation of the steroid, there have been other cases in which anti-psychotic medication, such as risperidone or quetiapine, was used because of gradually worsening psychotic symptoms even after discontinuation of steroid therapy, as in our case, or for severe symptoms, including auditory hallucination, delusion, and psychotic behavior [9,13]. However, the dose and duration of use for anti-psychotic medication vary across cases since there are no clear guidelines. In most cases, low-dose, comparable to 1/3 of the maximum dose used for schizophrenia spectrum disorder, was used and gradually reduced over 3–4 months. In a case of steroid-induced psychosis in a 12-year-old child, risperidone 1.5 mg/day was administered, and remission of positive symptoms occurred gradually over 3 weeks, after which, the therapy was discontinued over 3 months during the symptom-free period [13]. Another case involving an adult patient reported using olanzapine 7.5 mg, which was gradually reduced over 4 months after discharge. Even in our case, we planned to gradually reduce the dose of quetiapine by 50 mg at each outpatient follow-up visit after discharge, and the patient was able to maintain remission during the follow-up period [11].

In conclusion, we experienced the first case of steroid-induced psychosis that occurred in a pediatric patient with Crohn's disease after induction therapy using prednisolone. Based on this case, we believe that it is necessary to closely look for mood change and psychotic symptoms in the first 2–3 weeks when starting induction therapy with steroids in pediatric patients diagnosed with IBD. Therefore, if steroid-induced psychosis is suspected in patients who received steroid therapy, it should be checked whether the symptoms could be explained by other factors or not. Moreover, the steroid dose must be reduced as soon as possible or even discontinued, and the treatment should be initiated in consultation with the department of neuropsychiatry. Even with our case, steroid-induced psychosis in pediatric patients is rare. Because

its pathophysiology is not clearly understood and treatment modalities have not been systematically established, it is believed that future studies and guidelines are required for steroid-induced psychiatric complications.

Acknowledgments

None.

Conflicts of Interest

The authors have no potential conflicts of interest to disclose.

Author Contributions

Conceptualization: Ki Soo Kang. Supervision: Ki Soo Kang, Na Ri Kang. Visualization: Jin Woo Kim. Writing—original draft: Jin Woo Kim. Writing—review & editing: Ki Soo Kang, Na Ri Kang.

ORCID iDs

Jin Woo Kim	https://orcid.org/0000-0001-5989-1491
Ki Soo Kang	https://orcid.org/0000-0001-6374-8356
Na Ri Kang	https://orcid.org/0000-0002-2086-0927

REFERENCES

- 1) **Rosen MJ, Dhawan A, Saeed SA.** Inflammatory bowel disease in children and adolescents. *JAMA Pediatr* 2015;169:1053-1060.
- 2) **Kitamura M.** [Growth retardation in children with frequent relapsing nephrotic syndrome on steroid--improvement of height velocity after administration of immunosuppressive agent]. *Nihon Jinzo Gakkai Shi* 1992;34:117-124.
- 3) **Lewis DA, Smith RE.** Steroid-induced psychiatric syndromes. A report of 14 cases and a review of the literature. *J Affect Disord* 1983;5:319-332.
- 4) **American Psychiatric Association.** Diagnostic and statistical manual of mental disorders (DSM-5®). Arlington, VA: American Psychiatric Pub; 2013.
- 5) **Janes M, Kuster S, Goldson TM, Forjuoh SN.** Steroid-induced psychosis. *Proc (Bayl Univ Med Cent)* 2019;32:614-615.
- 6) **Wiesen A, Wiesen J, Limaye S, Kaushik N.** Mesalazine-induced aplastic anemia. *Am J Gastroenterol* 2009;104:1063.
- 7) **Su C, Lichtenstein GR.** Treatment of inflammatory bowel disease with azathioprine and 6-mercaptopurine. *Gastroenterol Clin North Am* 2004;33:209-234.
- 8) **French J, Khan A, White H.** Steroid induced psychosis in an asthmatic child: case report & 10 year literature review. *Can Child Adolesc Psychiatr Rev* 2003;12:117-118.
- 9) **Hodgins GE, Saltz SB, Gibbs EP, Gonzalez R, Regan J, Nemeroff C.** Steroid-induced psychosis in the pediatric population: a new case and review of the literature. *J Child Adolesc Psychopharmacol* 2018;28:354-359.
- 10) **Warrington TP, Bostwick JM.** Psychiatric adverse effects of corticosteroids. *Mayo Clin Proc* 2006;81:1361-1367.
- 11) **Kenna HA, Poon AW, de los Angeles CP, Koran LM.** Psychiatric complications of treatment with corticosteroids: review with case report. *Psychiatry Clin Neurosci* 2011;65:549-560.
- 12) **Mullen RS, Romans-Clarkson SE.** Behavioural sensitisation and steroid-induced psychosis. *Br J Psychiatry* 1993;162:549-551.
- 13) **Bag O, Erdoğan I, Onder ZS, Altinoz S, Ozturk A.** Steroid-induced psychosis in a child: treatment with risperidone. *Gen Hosp Psychiatry* 2012;34:103.e5-e6.