

Degenerative intraspinal cyst of the cervical spine

Hidetoshi Nojiri, Yoshio Sakuma,
Soichi Uta

Department of Orthopaedics, Saisei
Hospital, Chiba, Japan

Abstract

We describe two cases of degenerative intraspinal cyst of the cervical spine that caused a gradually progressive myelopathy. One case had a cyst that arose from the facet joint and the other case had a cyst that formed in the ligamentum flavum. The symptoms improved immediately after posterior decompression by cystectomy with laminoplasty.

Introduction

The cervical spine is a relatively rare location for a degenerative intraspinal cyst compared to the lumbar spine.^{1,4} A ganglion cyst is a cystic mass that usually occurs in close proximity to a tendon sheath or joint space. The etiology of spinal cysts is poorly understood. Several theories include extrusion of synovial fluid from a defect in the joint capsule, myxoid degeneration and cyst formation in collagen connective tissue, increased production of hyaluronic acid by fibroblasts, and non-specific proliferation of mesenchymal cells.⁵ Trauma is generally thought not to play a significant role, even though several cases demonstrated evidence of hemorrhage in the lumbar cyst.⁶ Several authors concluded that facet cysts are closely related to degenerative spinal instability including spondylolisthesis.¹ Furthermore, the development of post-operative intraspinal facet cysts was related to the presence of segmental spinal instability before and after surgery.⁷

Here, we report two cases of ganglion cyst in the cervical region. One case had a cyst that arose from the facet joint and the other case had a cyst that was formed in the ligamentum flavum. We describe the clinical, radiological and pathological findings of each case with a review of the literature.

Case 1

A 61-year old man presented with a gradually progressive gait disturbance and dullness below the iliac crests that began two months

earlier. An examination revealed an increased response to knee and ankle tendon reflexes without motor deficits. The pin-prick test showed a slight decrease in sensation at and below the nipple level on both sides.

Plain radiographs of the cervical spine showed narrowing of the disc space at C5-6 and C6-7 with osteophytes and slight slippage at C7-T1. Cervical magnetic resonance imaging (MRI) revealed a cystic lesion at the C7-T1 level that was hypointense on T1-weighted images and hyperintense on T2-weighted images. The lesion showed enhancement of the wall, but not within the lesion after gadolinium contrast injection. The mass was located in the posterior aspect of the extradural space adjacent to the right C7-T1 facet joint, and caused marked compression of the spinal cord. The facet joint showed fluid that was hyperintense on T2-weighted images (Figure 1A). A computed tomography (CT) myelogram demonstrated a mass compressing the spinal cord ventromedially on the right side of the spinal canal, as well as degenerative changes of the right C7-T1 facet joint and bone erosion of the C7 lamina (Figure 1B).

A laminectomy of T1 and a modified expansive open-door (right side-opening) laminoplasty⁸ of C5-C7 using hydroxyapatite spacers (PENTAX Co., Tokyo, Japan) were performed. The mass was removed together with the ligamentum flavum tightly adhering to both the dura and the C7 lamina. In the first few days after surgery, there was an evident improvement in motility, which enabled the patient to walk unaided. Post-operative MRI taken at the 2-year follow-up demonstrated a complete resection of the cyst and a decompressed spinal cord (Figure 1C). Plain CT revealed expansion of the cervical spinal canal (Figure 1D).

Pathological examination showed the cyst to be composed of fibrous connective tissue without a discernible epithelial or synovial cell lining. All findings including focal myxoid change, stromal cell reaction and chronic granular formation were consistent with a ganglion cyst (Figure 1E).

Case 2

A 77-year old woman presented with a 2-month history of a progressive gait disturbance, bilateral arm numbness, clumsiness of both hands and posterior cervical pain. An examination revealed increased response to left biceps, brachioradialis and triceps tendon reflexes, as well as bilateral patellar and Achilles tendon reflexes. Left side dominant motor weakness of finger motion was detectable. The grasp and release test decreased to 15 times on the right side and 16

Correspondence: Hidetoshi Nojiri,
Department of Orthopaedics, Juntendo University School of Medicine, 2-1-1 Hongo, Bunkyo-ku, Tokyo 113-8421, Japan.
E-mail: hnojiri@juntendo.ac.jp

Key words: cervical spine, ganglion, intraspinal extradural cyst, cystectomy, laminoplasty

Received for publication: 16 April 2009.

Revision received: 28 July 2009.

Accepted for publication: 28 July 2009.

This work is licensed under a Creative Commons Attribution 3.0 License (by-nc 3.0)

©Copyright H. Nojiri et al., 2009
Licensee PAGEPress, Italy
Orthopedic Reviews 2009; 1:e17
doi:10.4081/or.2009.e17

times on the left side. The finger escape sign was positive only in the left hand.

Cervical MRI revealed a cystic lesion at the C2-3 level that was hypointense on T1-weighted images and hyperintense on T2-weighted images. The mass was located in the posterior aspect of the extradural space with left-deviated compression of the spinal cord (Figure 2A).

Extensive simultaneous multisegment laminectomy⁹ was performed. The mass, filled with gelatinous fluid, was removed together with the ligamentum flavum. In the first few months after surgery the patient experienced remarkable improvement in neurological findings, which enabled her to walk unaided. MRI at two years post-surgery demonstrated a complete resection of the cyst and a decompressed spinal cord (Figure 2B). Histopathological diagnosis was a ganglion cyst without an epithelial or synovial cell lining.

Discussion

Intraspinal cysts are classified as intradural or extradural cysts. Intradural cysts include arachnoid cysts and enterogenous cysts, while extradural cysts include arachnoid cysts, synovial cysts, ganglion, and discal cysts.² An intraspinal extradural cyst is an uncommon lesion that occurs most frequently in the lumbar spine and rarely in the cervical spine.^{1,4} Cysts arising from the facet joints^{3,10} or the ligamentum flavum¹¹ can cause an extradural spinal cord compression leading to clinical signs consistent with a myelopathy, radiculopathy or radiculomyelopathy. Although the external appearance is macroscopically similar, ganglion cysts are histologically distinct from synovial cysts.¹² Ganglion cysts are thought to derive from mucoid degeneration of the fibrous adventitial tissue, excess produc-

tion of hyaluronic acid by the fibroblasts, and proliferation of the pluripotent mesenchymal cells, whereas synovial cysts seem to originate from herniation of the synovial membrane across the articular capsule of the facet.¹ Previous authors suggested that the diagnosis of a synovial cyst did not require the presence of synovial epithelium or communication with the articular space because a regressive phenomenon of the epithelium secondary to chronic inflammation may lead to an obliteration of the connection with the articular space.¹ Hsu reported a case with a cyst that was similar to both a synovial and ganglion cyst.¹³ Moreover, Awwad *et al.* described that the difference was often not distinct as there are many transitional forms of these cysts. They represent different stages of the same degenerative process.¹⁴ The differential diagnosis between the two types of cyst is not meaningful from a clinical standpoint, because the treatment is the same regardless of the kind of cyst.¹⁵ Some authors proposed the term “juxtafacet cyst” to categorize cysts that arise at the capsule of the facet joints,^{4,10,15} or the term “degenerative intraspinal cyst” as a more accurate description of cysts in the spinal canal that arise from degenerated spinal structures including not only facet joints, but also ligaments and discs.²

In diagnosing a degenerative intraspinal cyst, both MRI and CT scans are useful. Myelography is very sensitive and is able to demonstrate extradural lesions.^{4,12} MRI identified the cystic lesions as hypo/isointense on T1-weighted images and hyperintense on T2-weighted images. There is a hypointense rim on T2-weighted images, which displayed marginal enhancement around the cyst wall after administration of gadolinium.¹ The location of lesions adjacent to the facet joint is the characteristic feature of a cyst arising from the facet joint, whereas no obvious deviation could be detected in the location of a cyst formed in the ligamentum flavum shown in our report. CT scan may demonstrate a gas content in the cyst, strongly suggesting that the cyst communicates with a facet joint or a degenerated disc.² Epstein reported that a degenerated facet joint containing air could be detected in cases by MRI, myelography, and myelo-CT.³ Cystography has not been reported for cervical cysts, presumably because of the potential risk for neurological complication.

The etiology of the cysts is controversial and several factors are thought to play a role in their origin. Most patients simultaneously present signs of spondylodiscarthrosis and hypermobility of the spinal segment, secondary to degeneration of the intervertebral disc.¹ This leads to progressive weakening of the capsule of the facet joint that may result in degenerative spondylolisthesis, which is present in 67% of patients with lumbar synovial

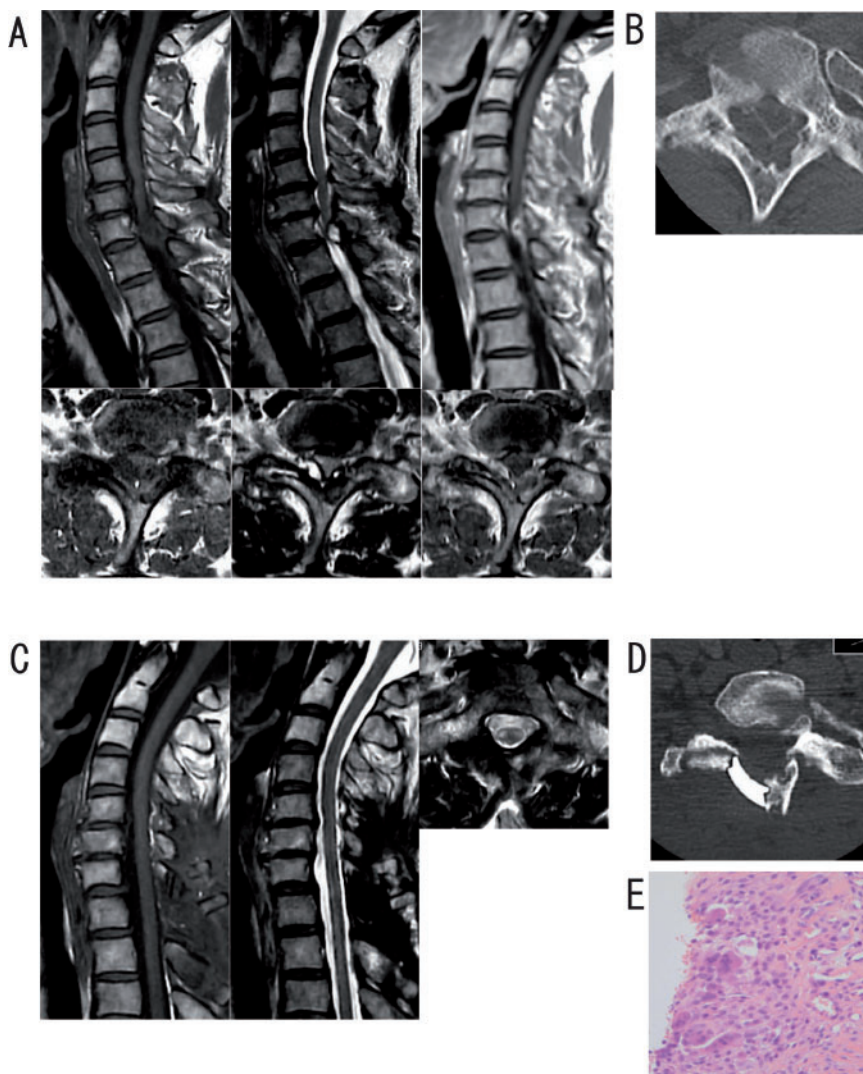


Figure 1. Case 1. (A) Sagittal (upper row) and axial (lower row) magnetic resonance images show an intraspinal cystic lesion located posterolaterally to the right of the spinal cord at the level of the interlaminar space of C7-T1, with marked compression of the neuraxial structure and peripheral signal enhancement after administration of gadolinium on T1-weighted images. (B) Computed tomography (CT) myelogram shows a mass compressing the spinal cord and bone erosion of the C7 lamina. (C) Post-operative magnetic resonance imaging after two years shows complete resection of the cyst and a decompressed spinal cord. (D) Plain CT reveals expansion of the cervical spinal canal. (E) Pathological examination showed the cyst to be composed of fibrous connective tissue without a discernible epithelial or synovial cell lining.

cysts.¹⁶ The cervical lesions are located preferentially in the cervicothoracic junction, as seen in Case 1. The C7-T1 segment is thought to be the most mobile segment immediately superior to the immobile thoracic spine.¹⁷ Continuous stress due to minor chronic trauma such as subluxation may predispose the formation of the cyst.¹¹ Gradual growth of the cervical degenerative cyst is suggested because of erosion of the facet and sclerotic change of the neighboring bony structures such as the pedicle and lamina. Conversely, Cameron *et al.* reported a rapid progression of

clinical signs associated with the development of a synovial cyst.¹⁸

The clinical progression of patients with degenerative intraspinal cysts is variable. In cases without signs of neurological detriment, observation may be recommended because spontaneous reduction or resolution of the cyst during rest has been reported.¹⁹ On the other hand, surgical excision is the standard treatment for degenerative intraspinal cyst of the cervical spine in cases with myelopathy or radiculopathy or both. Posterior decompression of the cervical spinal cord has proven to be

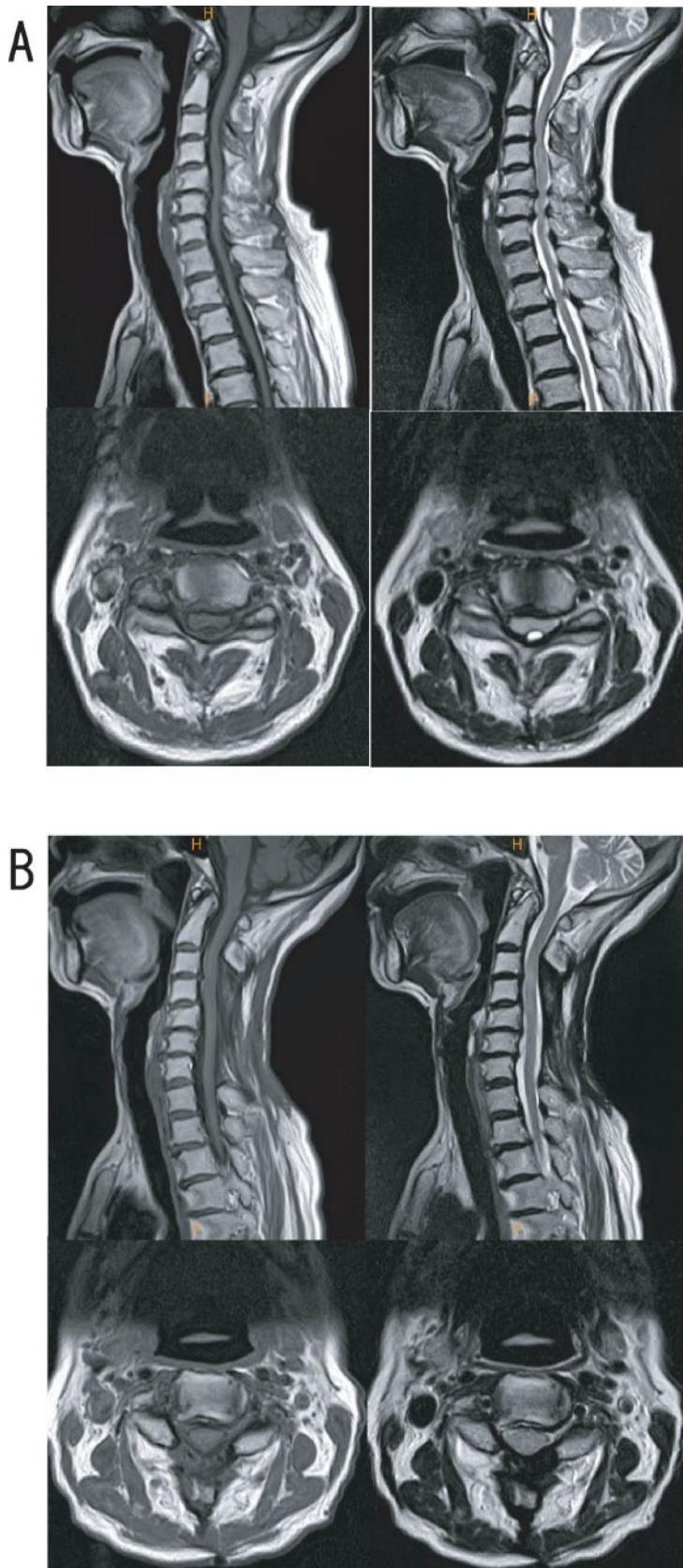


Figure 2. Case 2. (A) Cervical magnetic resonance imaging reveals a cystic lesion at the C2-3 level that is hypointense on T1-weighted images and hyperintense on T2-weighted images. The mass is located in the posterior aspect of the extradural space with compression of the spinal cord. (B) Post-operative magnetic resonance imaging after two years shows complete resection of the cyst and a decompressed spinal cord.

effective in cases of intraspinal cyst originating from the posterior vertebral component. Although the cysts are firmly attached to the dura, removal of the cyst can be performed without difficulty. Often there is associated spondylotic spinal canal stenosis, which is an indication for laminoplasty in addition to cyst removal. Open-door laminoplasty is the procedure of choice if the cystic lesions are positioned around the facets, whereas spinous process-splitting laminoplasty could be another choice if the cysts are within the lamina. Laminectomy can be performed, but is sometimes complicated with well-known sequelae, such as segmental instability, kyphosis, and perineural adhesions. Laminoplasty associated low incidence of post-operative instability and kyphotic deformity.²⁰ If the resection of the cyst involving the part of facet joint or lamina is sufficient to affect stability of the segment, fusion should be considered.⁴ From a stability point of view, we confirmed that the fusion was not necessary for these cases, because obvious instability could not be detected on the dynamic X-ray. Decompression of the spinal cord and the root result in good neurological recovery after surgery, and recurrence is unlikely if the excision is adequate.^{2,4,15} The other adjacent stenosis due to degenerative changes in the cervical spine or the cervicothoracic junction would often occur. The other pathology in the cervical spine would relate to the extent of the surgery performed. There is no evidence as to whether mono or multi-segment decompression is better in the cases of degenerative intraspinal cyst with mild multi-segment stenosis in the cervical spine. We have chosen to perform complete decompression with multisegment laminoplasty. CT-guided percutaneous aspiration of the cystic fluid may provide temporary improvement but carries the risk of neurological complications in the cervical lesion. We would recommend that cases with progressive neurological deficits and/or intolerable pain should be treated with operative procedures, though cases in asymptomatic or stable status neurologically need periodic observation.

In this study, we demonstrated two cases with degenerative intraspinal cyst of the cervical spine. In the first case, the cyst arose from the facet joint, while in the second case the cyst formed in the ligamentum flavum. Compression of the spinal cord in both cases resulted in a gradually progressive myelopathy that showed remarkable improvement immediately after posterior decompression by cystectomy with laminoplasty. The precise diagnosis and correct timing of decompression are essential for the management of degenerative intraspinal cyst of the cervical spine, and quality of life of patients can be improved.

References

1. Lunardi P, Acqui M, Ricci G, et al. Cervical synovial cysts: case report and review of the literature. *Eur Spine J* 1999;8:232-7.
2. Shima Y, Rothman SL, Yasura K, Takahashi S. Degenerative intraspinal cyst of the cervical spine: case report and literature review. *Spine* 2002;27:E18-22.
3. Epstein NE, Hollingsworth R. Synovial cyst of the cervical spine. *J Spinal Disord* 1993; 6:182-5.
4. Stoodley MA, Jones NR, Scott G. Cervical and thoracic juxtafacet cysts causing neurologic deficits. *Spine* 2000;25:970-3.
5. Pendleton B, Carl B, Pollay M. Spinal extradural benign synovial or ganglion cyst: case report and review of the literature. *Neurosurgery* 1983;13:322-6.
6. Kao CC, Uihlein A, Bickel WH, Soule EH. Lumbar intraspinal extradural ganglion cyst. *J Neurosurg* 1968;29:168-72.
7. Ikuta K, Tono O, Oga M. Prevalence and clinical features of intraspinal facet cysts after decompression surgery for lumbar spinal stenosis. *J Neurosurg Spine* 2009; 10:617-22.
8. Hirabayashi K, Satomi K. Operative procedure and results of expansive open-door laminoplasty. *Spine* 1988;13:870-6.
9. Miyazaki K, Kirita Y. Extensive simultaneous multisegment laminectomy for myelopathy due to the ossification of the posterior longitudinal ligament in the cervical region. *Spine* 1986;11:531-42.
10. Kao CC, Winkler SS, Turner JH. Synovial cyst of spinal facet. Case report. *J Neurosurg* 1974;41:372-6.
11. Gazzeri R, Galarza M, Gorgoglione L, et al. Cervical cyst of the ligamentum flavum and C7-T1 subluxation: case report. *Eur Spine J* 2005;14: 807-9.
12. Freidberg SR, Fellows T, Thomas CB, Mancall AC. Experience with symptomatic spinal epidural cysts. *Neurosurgery* 1994;34:989-93; discussion 93.
13. Hsu KY, Zucherman JF, Shea WJ, Jeffrey RA. Lumbar intraspinal synovial and ganglion cysts (facet cysts). Ten-year experience in evaluation and treatment. *Spine* 1995;20:80-9.
14. Awwad EE, Martin DS, Smith KR Jr, Bucholz RD. MR imaging of lumbar juxtaarticular cysts. *J Comput Assist Tomogr* 1990;14:415-7.
15. Sabo RA, Tracy PT, Weinger JM. A series of 60 juxtafacet cysts: clinical presentation, the role of spinal instability, and treatment. *J Neurosurg* 1996;85:560-5.
16. Onofrio BM, Mih AD. Synovial cysts of the spine. *Neurosurgery* 1988;22:642-7.
17. Krauss WE, Atkinson JL, Miller GM. Juxtafacet cysts of the cervical spine. *Neurosurgery* 1998;43:1363-8.
18. Cameron SE, Hanscom DA. Rapid development of a spinal synovial cyst. A case report. *Spine* 1992;17:1528-30.
19. Ewald C, Kalff R. Resolution of a synovial cyst of the lumbar spine without surgical therapy - a case report. *Zentralbl Neurochir* 2005;66:147-51.
20. Lee TT, Green BA, Gromelski EB. Safety and stability of open-door cervical expansive laminoplasty. *J Spinal Disord* 1998;11: 12-5.