

Correspondence

Curative effect of hepatic portal venous administration of autologous bone marrow in AIDS patients with decompensated liver cirrhosis

B Liu^{*1,3}, X Chen^{2,3}, Y Wang² and Y Shi^{*2}*Cell Death and Disease* (2013) 4, e739; doi:10.1038/cddis.2013.261; published online 25 July 2013

Subject Category: Experimental Medicine

Dear Editor,

Acquired immunodeficiency syndrome (AIDS) caused by human immunodeficiency virus type 1 (HIV-1) infection remains a major public health threat worldwide.¹ Although the antiretroviral therapy (ART) improved the life quality and increased longevity of HIV-infected patients, comorbidities of liver diseases have assumed far greater importance as a cause of morbidity and mortality in AIDS patients.² As their CD4⁺T-cell-based immune response is attenuated, HIV-infected patients are often coinfecting with hepatitis B virus (HBV) or hepatitis C virus (HCV), which, in addition to the hepatotoxicity of ART, leads to the development of liver cirrhosis and failure.^{3,4} Traditional treatment has low rates of sustained antiviral response in coinfecting patients. Thus, effective treatment strategies tailored to meet the needs of these AIDS patients with liver cirrhosis are urgently in demand.

Recent studies have employed the bone marrow-derived stem cells to treat end-stage liver diseases in clinical settings.⁵ However, the low efficiency in obtaining autologous stem cells hindered the progress in this application. Thus, it is considered feasible to directly transfuse fresh bone marrow (bone marrow transplantation (BMT)) to achieve therapeutic goals.^{6,7} To assess the efficacy and safety of transfusing autologous bone marrow in AIDS patients accompanied by advanced liver cirrhosis, we conducted a single-arm trial. The protocol was approved by the Ethics Committee of the Public Health Clinical Center Affiliated with Fudan University. Upon obtaining informed consent, four AIDS patients with decompensated liver cirrhosis caused by HBV or HCV were recruited (Supplementary Table 1). Although the viral loads in peripheral blood of the four patients were under control after ART, their conditions were still progressing with dramatically decreased CD4⁺T-cell count. Their Child-Pugh scores were B or C. Owing to portal hypertension induced by liver cirrhosis, all patients suffered from splenomegaly and hypersplenism

with low counts of white blood cells and platelets. Thus, splenectomy was performed in each patient to alleviate portal vein hypertension and avoid internal bleeding. During the surgical procedure, a catheter was placed in the superior mesenteric vein in preparation for BMT. One week later, 40 ml bone marrow was aspirated by puncture of the iliac crest. Bone marrow cells were suspended in saline without further manipulation and directly transfused through the attached catheter into the portal vein (Figure 1a). One or two BMTs were administered to each patient at 1-month interval.

The outcome of BMT is surprisingly rewarding. During a 24-month follow-up in patient 1, 2, and 3 and a 3-month follow-up in patient 4 (the most recent patient), the portal vein transfusion of autologous bone marrow cells did not result in any observable side effect and complication. Besides recovery of serum albumin levels and diminishment of ascites, total white blood cell and platelet counts were also significantly improved (Figure 1b and Supplementary Figures 1a–c). Although the prothrombin time and total bilirubin in all patients did not recover completely, the absolute indexes demonstrated stable decrease (Supplementary Figures 1d and e). Moreover, their Child-Pugh scores became A in patient 1, 2 and 3, 1 year after the first transfusion and in patient 4, 3 months after the first transfusion (Supplementary Figure 1f). Surprisingly, 1 month after the first transfusion, CD4⁺T-cell count in the peripheral blood of each patient began to increase (Figure 1c). Interestingly, this increasing tendency was maintained in the remaining follow-up period, which is extraordinary in AIDS patients with common ART.

Taken together, our data demonstrated the efficacy and safety of autologous BMT on treating advanced liver cirrhosis and recovering CD4⁺T cells in AIDS patients. Although splenectomy might participate in regaining total white blood cells in peripheral blood, the stable increase of CD4⁺T cells in AIDS patients after autologous BMT indicated a possibility

¹Department of Surgery, Shanghai Public Health Clinical Center Affiliated to Fudan University, 2901 Caolang Road, Shanghai 201508, China and ²Key Laboratory of Stem Cell Biology, Institute of Health Sciences, Shanghai Institutes for Biological Sciences, Chinese Academy of Sciences/Shanghai Jiao Tong University School of Medicine, 225 South Chongqing Road, Shanghai 200025, China

*Corresponding author: B Liu, Department of Surgery, Shanghai Public Health Clinical Center Affiliated to Fudan University, 2901 Caolang Road, Shanghai 201508, China. Tel/Fax: +86-21-3799033, ext 3213; E-mail: liubaochi2002@yahoo.com.cn or Y Shi, Key Laboratory of Stem Cell Biology, Institute of Health Sciences, Shanghai Institutes for Biological Sciences, Chinese Academy of Sciences/Shanghai Jiao Tong University School of Medicine, 225 South Chongqing Road, Shanghai 200025, China. Tel: +86-21-63848329; Fax: +86-21-63852655; E-mail: yufangshi@sibs.ac.cn

³These authors contributed equally to this work.

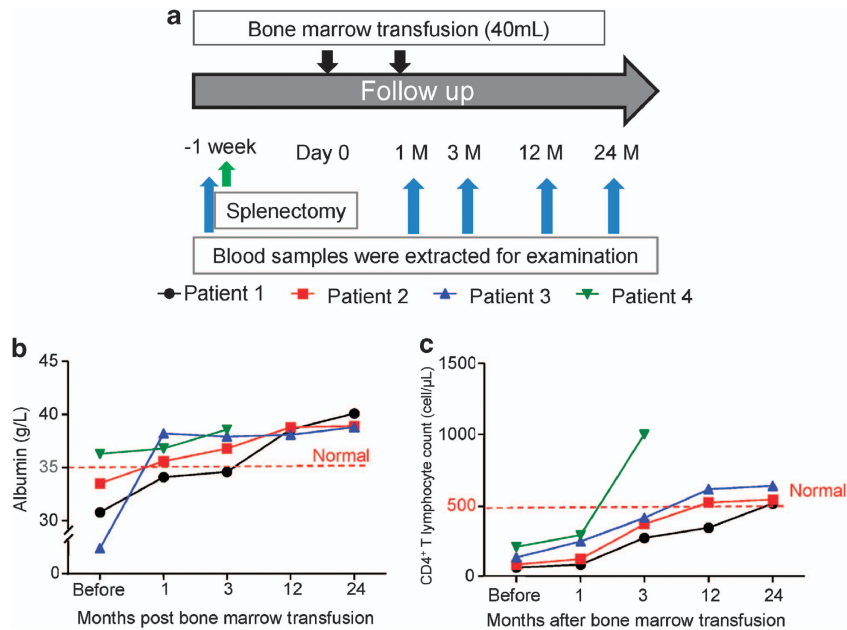


Figure 1 (a) Schematic illustration of splenectomy and BMT in AIDS patient with decompensated liver cirrhosis. (b and c) Albumin and CD4⁺ T-cell count in AIDS patient with decompensated liver cirrhosis were assayed before splenectomy and at different times after BMT during a 24-month follow-up. Red dotted lines denote the normal threshold of human albumin and CD4⁺ T-cell count (AIDS can be defined in terms of CD4⁺ T-cell count < 200 cells/μL in HIV patient)

that autologous BMT through the hepatic portal vein may reactivate the hematopoietic supportive capability of the liver in adult AIDS patients, which is an exciting research direction warranting further exploration. Importantly, the feasible surgical procedure will make autologous BMT an effective adjuvant therapy to bring benefits to AIDS patients.

Conflict of Interest

The authors declare no conflict of interest.

Acknowledgements. This work was supported by grants from Scientific Innovation Project of the Chinese Academy of Sciences (XDA01040000), the Ministry of Science and Technology of China (2010CB945600, 2011DFA30630,

2009ZX09503-024). We are grateful for research support from the Ethics Committee of the Public Health Clinical Center Affiliated with Fudan University.

1. Moir S, Chun TW, Fauci AS. *Annu Rev Pathol* 2011; **6**: 223–248.
2. Lacombe K, Rockstroh J. *Gut* 2012; **61**(Suppl 1): i47–i58.
3. Levy V, Grant RM. *Clin Infect Dis* 2006; **43**: 904–910.
4. Lin W, Weinberg EM, Chung RT. *J Infect Dis* 2013; **207**(Suppl 1): S13–S18.
5. Kallis YN, Alison MR, Forbes SJ. *Gut* 2007; **56**: 716–724.
6. Sakaida I, Terai S, Yamamoto N *et al*. *Hepatology* 2004; **40**: 1304–1311.
7. Roderfeld M, Rath T, Pasupuleti S *et al*. *Gut* 2012; **61**: 907–916.



Cell Death and Disease is an open-access journal published by **Nature Publishing Group**. This work is licensed under a **Creative Commons Attribution-NonCommercial-NoDerivs 3.0 Unported License**. To view a copy of this license, visit <http://creativecommons.org/licenses/by-nc-nd/3.0/>

Supplementary Information accompanies this paper on Cell Death and Disease website (<http://www.nature.com/cddis>)