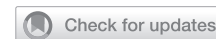

SURGERY

An Alternative Option for Gender-Affirming Revision Vaginoplasty: The Tubularized Urachus-Peritoneal Hinge Flap



Shannon M. Smith, MD, MPH,^{1,2} Nance Yuan, MD,³ Jenna Stelmar, BS,¹ Grace Lee PA-C,¹ Amit Gupta, MD,⁴ Hyung L. Kim, MD,² and Maurice M. Garcia, MD, MAS^{1,2,5}

ABSTRACT

Introduction: Gender-affirming peritoneal vaginoplasty has been described, and previous descriptions are modifications of the Davydov technique.

Aim: To describe our alternative technique for gender-affirming peritoneal vaginoplasty (PV) using a single-pedicle, urachus-peritoneal hinge flap, discussing proposed advantages.

Methods: Retrospective review of all consecutive transfeminine patients with neovaginal shortening after prior penile inversion vaginoplasty (PIV) who underwent our PV technique from May 2019 to July 2022. PV was performed via combined transperineal and laparoscopic (robot-assisted) approaches. After spatulation of the neovaginal remnant, a midline, inferiorly based urachus-peritoneal hinge flap was elevated craniocaudally from the umbilicus to the mid-posterior bladder. The free end of the flap was flipped posteriorly and sutured to posterior edge of the open canal remnant, forming a peritoneal pouch. The lateral edges of the pouch were sutured together for water-tight closure. Patients resumed dilation on POD 6 and douching on POD 10.

Main Outcome Measures: Ten transfeminine patients underwent PV, with good outcomes. We measured: Pre-op penile and scrotal skin lengths, intra-op tubularized scrotal skin length, pre and post-op vaginal depth and width (immediate and at last follow-up).

Results: Pre-op: mean neovaginal depth was 9.2cm (SD 1.5); width was 12cm. Immediate post-op: mean depth was 15.1 cm (SD 2.2 cm, mean net increase: 5.9 cm). At mean follow-up of 18.3 months, mean depth was 12.5 cm (SD 2.1 cm, mean net increase: 3.3 cm) and width was 12 cm. There were no immediate post-op complications. Eight (80%) of the 10 patients report satisfactory vaginal receptive intercourse. The other 2 have not yet attempted vaginal receptive intercourse.

Clinical Implications: Advantages of the proposed technique over existing techniques include no tension on peritoneal suture lines and total exclusion of the rectum.

Strengths and Limitations: Strengths include a short learning curve for urologic surgeons with robotic experience. The study is limited by small sample size.

Conclusions: Our PV technique is a safe and effective option for salvage peritoneal vaginoplasty after primary PIV. **Smith SM, Yuan N, Stelmar J, et al. An Alternative Option for Gender-Affirming Revision Vaginoplasty: The Tubularized Urachus-Peritoneal Hinge Flap. Sex Med 2022;10:100572.**

Copyright © 2022 The Authors. Published by Elsevier Inc. on behalf of the International Society for Sexual Medicine. This is an open access article under the CC BY-NC-ND license (<http://creativecommons.org/licenses/by-nc-nd/4.0/>).

Received May 9, 2022. Accepted August 26, 2022.

¹Cedars-Sinai Transgender Surgery and Health Program, Cedars-Sinai Medical Center, Los Angeles, CA, USA;

²Division of Urology, Cedars-Sinai Medical Center, Los Angeles, CA, USA;

³Huntington Plastic Surgery Institute, Pasadena, CA, USA;

⁴Beverly Hills Urology, Beverly Hills, CA, USA;

⁵Departments of Anatomy and Urology, University of California San Francisco, San Francisco, CA, USA

Copyright © 2022 The Authors. Published by Elsevier Inc. on behalf of the International Society for Sexual Medicine. This is an open access article under the CC BY-NC-ND license (<http://creativecommons.org/licenses/by-nc-nd/4.0/>).
<https://doi.org/10.1016/j.esxm.2022.100572>

Key Words: Vaginal Reconstruction; Transgender Persons; Robotics; Urachus; Peritoneum

INTRODUCTION

Penile inversion vaginoplasty (PIV) is considered the first-line technique for gender-affirming vaginoplasty with neovaginal canal creation.¹ Penile shaft skin is used as neovaginal canal lining, often augmented by scrotal skin grafts. Lifelong postoperative vaginal dilation is necessary for maintaining neovaginal depth and width. Unfortunately, complications from neovaginal canal stenosis and/or shortening are not uncommon and negatively impact quality of life.²⁻⁴ In such cases, alternative tissue types are needed to restore neovaginal canal depth and satisfactory sexual function.

Options for salvage vaginoplasty to increase usable neovaginal canal depth include colon and peritoneal vaginoplasty (PV) techniques.^{3,4} PV has been reported for treatment of disorders of sex development (DSD), such as congenital vaginal agenesis.⁵ In recent years, gender-affirming PV has also been performed,⁶⁻⁹ but most reports have focused only on primary gender-affirming vaginoplasty^{6,9} to augment neovaginal depth in cases of penoscrotal hypoplasia. Published PV techniques have been modifications of the Davydov technique,¹⁰ wherein peritoneum adherent to the bladder and rectum is incised and the left and right edges of the advancement flaps are approximated to surround the rectovesical peritoneal fold space, which is put in continuity with the distal end of the shortened neovaginal canal. It should be noted that the Davydov technique was designed to bridge a gap in the *proximal* vaginal canal (congenital atresia at the introitus). In contrast, PV to address shortening of the vaginal vaginal canal after feminizing gender affirming vaginoplasty aims to address a gap in the *distal* neovaginal canal (shortening of the deepest portion due to loss of viability of the skin flaps brought to line it).

In contrast to this technique, which incorporates peritoneum that remains adherent to the anterior wall of the rectum, the technique we describe does not incorporate the rectum or its peritoneum in any way. Instead, the technique we describe utilizes a long pedicle-flap of peritoneum, urachus and transversalis fascia from the dome of the bladder to the level of the umbilicus. This flap is then flipped back on itself, and the end originally closest to the umbilicus is sutured to the epithelium comprising the posterior wall of the shortened neovaginal canal. As such, when this flap is not in use (eg, filled with a neovaginal dilator or during receptive vaginal intercourse), the flap “rests” in a collapsed state. As such, it lacks resting stretch tension along the suture lines connecting peritoneum still adherent to the anterior wall of the rectum to the peritoneal flap of the bladder and to the neovaginal canal, as may occur with the previously described technique.

Few studies have focused on PV specifically as a salvage technique to treat the complication of loss of neovaginal depth of after primary PIV.^{7,11} No studies to date have assessed sexual function after PV, despite recognition that such studies are warranted given that satisfactory sexual function is an important end point for transgender patients.¹¹

The present study highlights an alternative PV technique, using a single-pedicled urachus-peritoneal hinge flap that has not been previously reported. We report our experience with this technique, which safely and effectively treats post-PIV neovaginal canal shortening. We also report patient satisfaction and postoperative sexual function, which has not been well-described in PV literature, and describe early and long-term gains in vaginal depth using peritoneum. We review proposed advantages of our technique as compared to previously reported techniques, and we discuss our algorithm for using PV vs colon vaginoplasty for salvage surgery. Finally, we review sexual function outcomes after salvage peritoneal vaginoplasty by the technique we describe, as to this point this has not been described.

MATERIALS AND METHODS

We performed retrospective review of all consecutive transfeminine patients with neovaginal shortening after prior penile inversion vaginoplasty (PIV) who underwent our salvage PV using our single-pedicled urachus-peritoneal hinge flap technique from May 2019 to July 2022. All patients presented with a complaint of bothersome neovaginal shortening that precluded dilation or intercourse with their partner(s). This study was approved by the Institutional Review Board (IRB Study #0000107). Demographics, operative details, and outcomes were recorded.

Surgical Technique

All patients underwent the same procedure, as described below and as summarized in Video 1. All cases were performed in a 2-team approach via combined transperineal and robotic-laparoscopic approaches using the DaVinci surgical robot (Intuitive Surgical, Sunnyvale, CA). The first 8 of 10 cases were performed with the DaVinci Xi, and the last 2/10 cases were performed with the DaVinci Single Port unit.

Patients were placed in lithotomy position. Preoperative neovaginal depth and width were measured by the study group directly in a standard manner using a vaginal dilator. Depth was measured from the labia at the vaginal introitus. The peritoneal cavity was accessed using a Veress needle, and the abdominal cavity was insufflated.

Establishing Continuity Between Neovaginal Canal and the Pelvic Space

Robotic ports were placed under direct visualization. With guidance from a dilator placed in the neovagina transperineally, the neovaginal dome was visualized from within the pelvis.

To minimize risk of bladder injury, we filled the bladder to identify its margins.

Another recent innovation to our technique that we have found useful to minimize risk of injury to the bladder or rectum is to insert a lighted flexible or rigid cystoscope into the vaginal canal. From the laparoscopic view, visualization of the light from the scope readily confirms the location of the vaginal canal terminus.

The terminal neovaginal canal remnant and its overlying peritoneum were incised (Figure 1). To minimize risk of stenosis at the junction of the peritoneal flap and the remnant vaginal canal epithelium, we *spatulate the incision* at the canal-end over a dilator inserted in the neovagina to maximize final anastomosis circumference. Instead of incising the canal terminus in a straight line from 9:00 to 3:00, we curve the incision anteriorly (ie, an “upside-down smile” shape: 9:00-12:00-3:00). This makes the anterior edge of the canal epithelium short, and importantly off-set (anterior-posteriorly) relative to the posterior edge. In all cases we ensured that the vaginal canal was able to accommodate a vaginal dilator of 12cm in circumference.

Anterior Peritoneal Anastomosis

With the canal end now fully opened, the vaginal canal remnant’s anterior epithelial edge was sutured to the anterior peritoneal incision (Figure 2) with a running 6-inch or 9-inch V-loc suture from the 9-o’clock to 3-o’clock positions. Just as with the previously described technique,¹¹ this brings the vaginal canal in continuity with the peritoneal space anteriorly.

Our flap was centered at midline over the urachus, with the flap’s lateral borders lateral to the medial umbilical ligament on either side to incorporate the urachus into the flap (Figure 3). The flap was outlined with electrocautery to be at least 8cm wide in its relaxed state. The flap was inferiorly based and elevated cranio-caudally off the posterior abdominal wall, from the umbilicus to the mid-posterior bladder, terminating at the vas deferens.

Posterior Peritoneal Anastomosis

The flap’s free end was then folded posteriorly like a hinge over the open end of the vaginal canal remnant. With dilator guidance, the flap edge was sutured to the posterior epithelial edge of the open vaginal canal remnant using V-loc sutures. (The longer posterior vaginal canal wall edge we gained by *spatulating* the vaginal canal-end makes it easier to suture it to the urachus-end of the peritoneal flap.)

Of note, we do not secure the apex of the peritoneal hinge flap for 2 reasons. First, the flap begins >7 cm from the introitus and would be unlikely to ever be able to prolapse to reach the

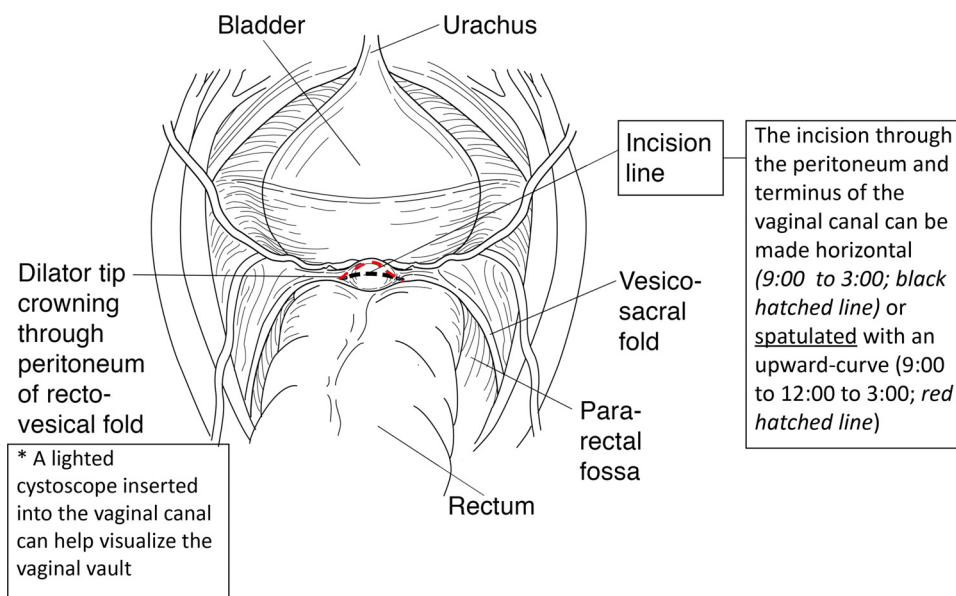


Figure 1. Incision and spatulation of remnant vaginal canal end. A. Midline sagittal section of pelvis, showing a dilator inserted into the remnant vaginal canal. B. The dilator is inserted to a depth where its tip causes end of the terminus of the vaginal canal to visibly “bulge” beneath overlying peritoneum at the peritoneal rectovesical fold. The minimum required vaginal canal depth (cm) necessary for the tip of the dilator, pushed into the vagina under mild-moderate pushing force) is 8–9 cm from the vaginal introitus (orange bracket). C. An electrocautery hook instrument is used (cutmode) to incise the peritoneum (horizontally, with releasing incisions as shown), and the vaginal vault, to allow the dilator to be passed into the pelvis (D).

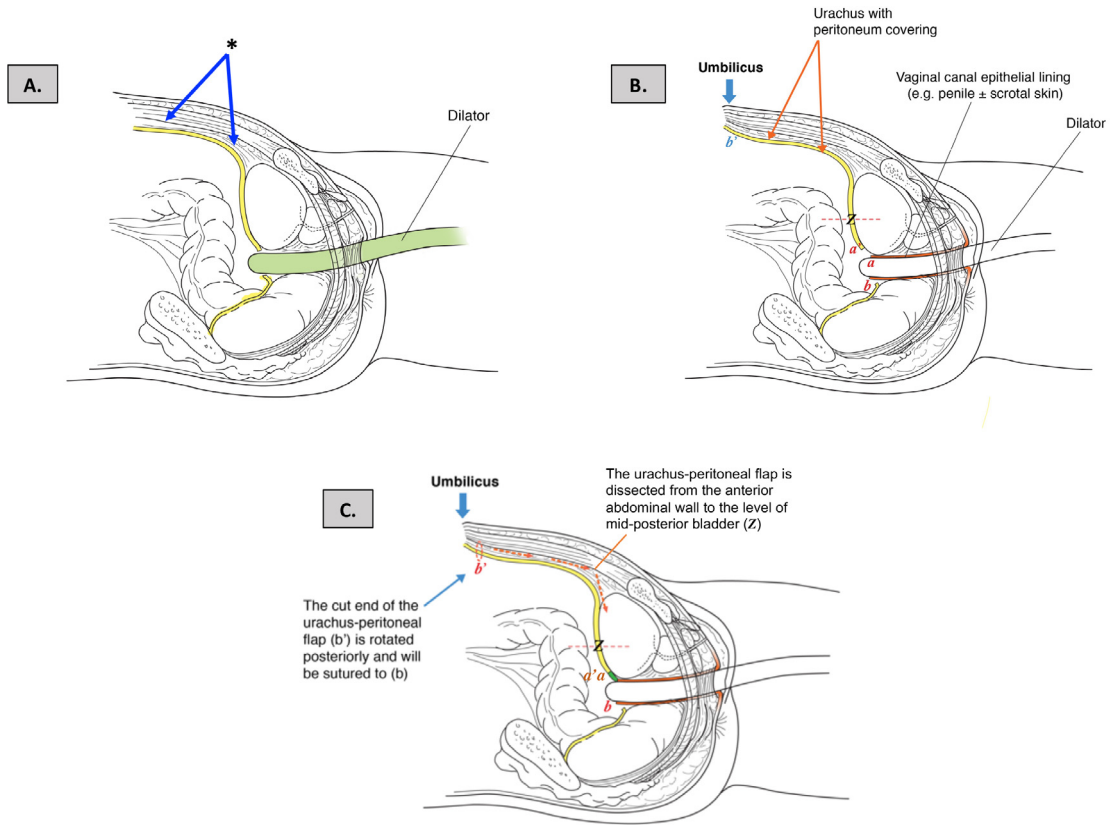


Figure 2. Peritoneal-epithelium suturing and elevation of urachus-peritoneal flap. A. The midline urachus and peritoneum anterior to the dilator’s entry site (*) will be incorporated into the hinge flap used to augment vaginal canal depth. B. Before mobilizing the flap, the anterior epithelial edge of the remnant vaginal canal (a; 9:00–3:00 on a clock-face pattern) is sutured to the anterior peritoneal edge that was incised as the dilator entry site (a’; 9:00–3:00). C. After suturing a to a’ (green), a 6–8 cm wide flap of peritoneum overlying the urachus is mobilized and dissected from the anterior abdominal wall in a craniocaudal direction, beginning at the level of the umbilicus (blue arrow), towards the mid-posterior bladder wall (–Z–).

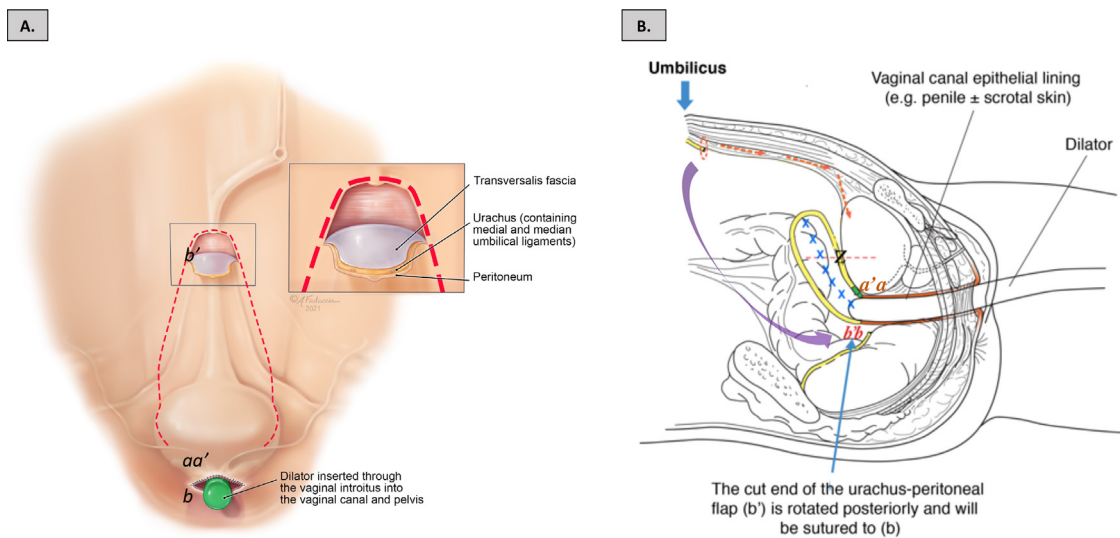


Figure 3. Peritoneal flap inset. A. Coronal section view of anterior abdominal wall, showing the urachus-peritoneal flap outline (red hatched line) bordered medially by each of the 2 medial umbilical ligaments. The flap is comprised of 3 layers (superficial to deep): 1. peritoneum, 2. Urachus, and 3. Transversalis fascia. B. The flap is dissected posteriorly to the level of mid-posterior bladder wall. The cranial end of the flap (b’) is flipped posteriorly (purple arrow), and the peritoneal edge of b’ is sutured to the peritoneal edge of b (located along the posterior face of the vaginal canal, 3:00 to 9:00).

Table 1. Neovaginal depths and circumferences before and after peritoneal vaginoplasty

| | Mean neovaginal depth (SD), cm | Mean increase in depth from pre-op, cm (SD) | Mean neovaginal circumference, cm (SD) |
|---|--------------------------------|---|--|
| Pre-op, before peritoneal vaginoplasty | 9.2 (1.5) | – | 12 (0) |
| Immediate post-op after peritoneal vaginoplasty | 15.1 (2.2) | 5.9 (3.1) | 12 (0) |
| At final follow-up (mean follow-up 1.3 ± 0.6 years) | 12.5 (2.1) | 3.5 (1.5) | 12 (0) |

introitus. Second, an anchoring suture through the flap could potentially tear the peritoneal flap. Furthermore, with penile inversion vaginoplasty we also never anchor the vault of the skin-lined vaginal canal to pelvic structures, and we have never encountered vaginal prolapse.

Closure of the Flap's Open Lateral Edges

Finally, the peritoneal pouch's lateral edges were sutured for watertight closure. Final vaginal depth (from the introitus) and width were measured using vaginal dilators.

Postoperative Care

Postoperatively, patients were admitted to the inpatient ward for 3–4 days, awaiting return of bowel function. A Silvadene-covered vaginal packing was placed in the canal until hospital discharge. Patients resumed outpatient vaginal dilation on postoperative day (POD) 6 and douching on POD 10.

Overall Satisfaction and Sexual Function Questionnaire

We surveyed all PV patients on their experiences and satisfaction. Patients were asked about postoperative pain, recovery, pre- vs post-surgery orgasm quality and satisfaction, and, whether they experience vaginal wetness with mental sexual arousal and with sexual stimulation.

RESULTS

Demographics

Ten transfeminine patients underwent our PV technique. All patients had previously undergone PIV, with complications of neovaginal stenosis and/or neovaginal canal shortening. Average age was 36.4 years (SD 10.2). Average BMI was 26.3 (SD 5.1). One patient was diabetic. No patients were smokers. Mean follow-up time was 18.3 months (SD 14 mo) (range = 1.2–39.4 months; median = 19.6 months).

Preoperative vs Postoperative Neovaginal Depth

Mean preoperative neovaginal depth was 9.2 cm (SD 1.5) and width was 12 cm (Table 1). Mean immediate post-operative

depth after salvage PV was 15.1 cm (range: 11–17.8, SD 2.2), or a mean net increase of 5.9 cm (SD 3.1) relative to preoperative depth. At a mean long-term follow-up of 1.1 (SD 0.7) years, mean neovaginal depth was 12.5 cm (SD 2.1), or mean net increase in depth of 3.5 cm (SD 1.5) relative to preoperative depth. Width remained 12 cm.

Outcomes

There were no immediate postoperative complications. One patient developed anastomotic narrowing at 6 weeks postoperatively. This was managed conservatively with dilation under anesthesia, with excellent outcomes. One patient suffered an acute mental health crisis 5 months after PV and discontinued dilation for over 1 month. When she resumed dilating, there was at least 4 cm of neovaginal depth loss. However, she still maintained an increase in vaginal depth of 3.8 cm as compared to her pre-PV vaginal depth.

Postoperatively, 3 (30%) of 10 patients experienced temporary culture-negative, non-infectious urinary frequency, with symptoms improving with time and completely resolving in all cases by 2–6 months post-op.

Patient Experience and Satisfaction

All 10 patients who underwent PV were administered the satisfaction survey. All 10 patients completed the survey (response rate: 100%): 6 patients completed the survey at more than 1 year post-operatively, 4 patients completed it within 6 months post-operatively.

Assessment of Pain, Ease of Recovery, and for Possible Prolapse

Eight of 10 patients (80%) reported the same or less pain and discomfort after salvage PV as compared to what was experienced after primary PIV. All 10 patients reported that ease of surgical recovery and ability to resume non-strenuous daily postoperatively was the same or improved as compared to post-PIV recovery. No patients demonstrated any complaints to suggest prolapse of the peritoneal segment. Our technique in all cases yielded a favorable maximum depth (mean 6.0 inches), with high patient satisfaction.

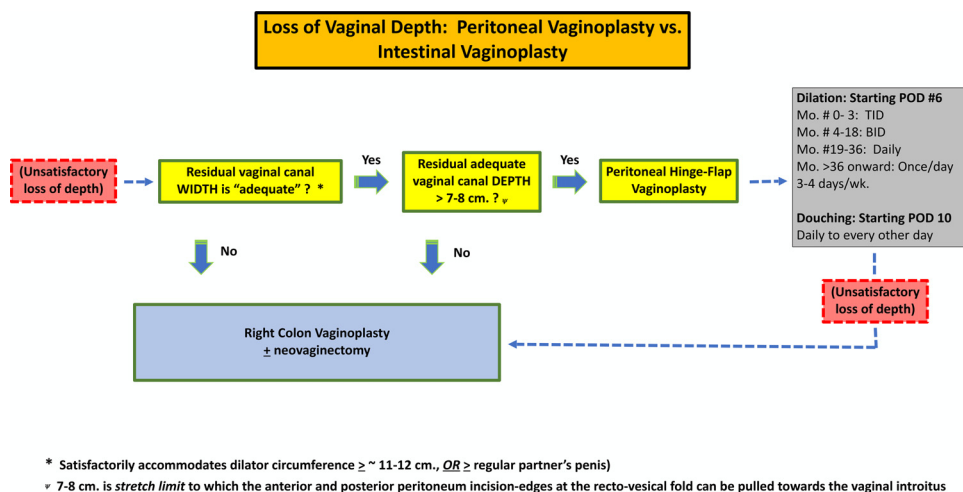


Figure 4. a) Change in orgasm quality after PV. (n = 8 because two patients reported that they could not orgasm prior to their initial surgery, and had not been able to orgasm after their primary PIV or revision PV.); b) Vaginal depth was satisfactory for 8 of the 10 patients at last follow up; c) 70% of patients report being bothered by the abdominal laparoscopy scars, with 40% of patients being extremely bothered. One patient is so bothered by these scars that she stated this as the reason she would not choose to undergo PV again; d) Eight of 10 patients would choose to undergo PV if they had the opportunity to choose again.

Orgasm Quality Pre Vs Post PV

Eight of the 10 patients (80%) endorsed good orgasm and masturbatory function. Five of the 10 patients (50%) have reported satisfactory vaginal receptive intercourse with male partners. Five of the 10 patients (50%) have not had receptive sexual intercourse. Four of these 5 patients plan to have receptive vaginal intercourse in the future, but 1 patient does not desire to. (This patient is currently with a female partner and does not practice receptive vaginal intercourse; however, she reports “significantly improved” sexual function and satisfaction due to improved body image.

Regarding orgasm quality, of the 8 patients who were able to achieve orgasm after PV, 25% reported that their orgasm quality remained the same, 50% reported the quality was slightly improved, and 25% reported that their orgasm quality was significantly improved as compared to immediately before PV. The remaining 2/10 patients in our series reported that they were never able to achieve orgasm at any time, including before their primary PIV, after PIV, and after PV (Figure 4A).

Eight of 10 patients (80%) reported that they were satisfied with their vaginal depth after PV (Figure 4B), while 1/10 patients (also incapable of achieving orgasm pre or post PV) wanted greater depth, and 1/10 patients did not plan to undergo receptive vaginal intercourse.

Assessment of Vaginal Moisture With Mental and Physical Sexual Arousal After PV

Five of our patients (50%) reported that they did not experience any vaginal “wetness,” after their initial PIV. Post-PV, 7 of the 10 patients (70%) reported occasional to frequent

subjective sensation of increased vaginal wetness with sexual arousal (Figure 5A). The other 3 patients (30%) stated that they did not notice increased vaginal wetness with sexual arousal. One of the latter clarified that while she did not experience vaginal wetness with sexual arousal, she did feel increased wetness specifically with masturbation.

Of the 5 patients that reported vaginal moisture before PV, 1/5 patients reported that they have *less* moisture after PV than they had with PIV, 1/5 patients reported that they had *the same* amount, and 3/5 patients reported that they had *more* moisture after PV than they did after PIV (2 reported “slightly more” and 1 reported “significantly more” moisture) (Figure 4B).

Assessment of Body Image and Satisfaction With Vaginal Depth After PV

Eight of 10 patients (80%) reported same or improved body image after PV. It is interesting to note that 7 of 10 patients (70%) reported being bothered by the appearance of the abdominal laparoscopy scars, with 4 of the 7 reporting that they are “extremely bothered”. One patient reported worsened body image, as the patient works as a model and is bothered by the appearance of her abdominal scars which have become keloids. For this reason, she stated that she would not choose to undergo PV again. Eight of 10 patients (80%) reported that, if given the opportunity to go back in time, that they would choose again to undergo PV to treat neovaginal stenosis and loss of depth (Figure 4D).

Based on our data, improvements in vaginal depth can greatly help improve sexual satisfaction and function for patients that have suffered complications of neovaginal shortening. It is

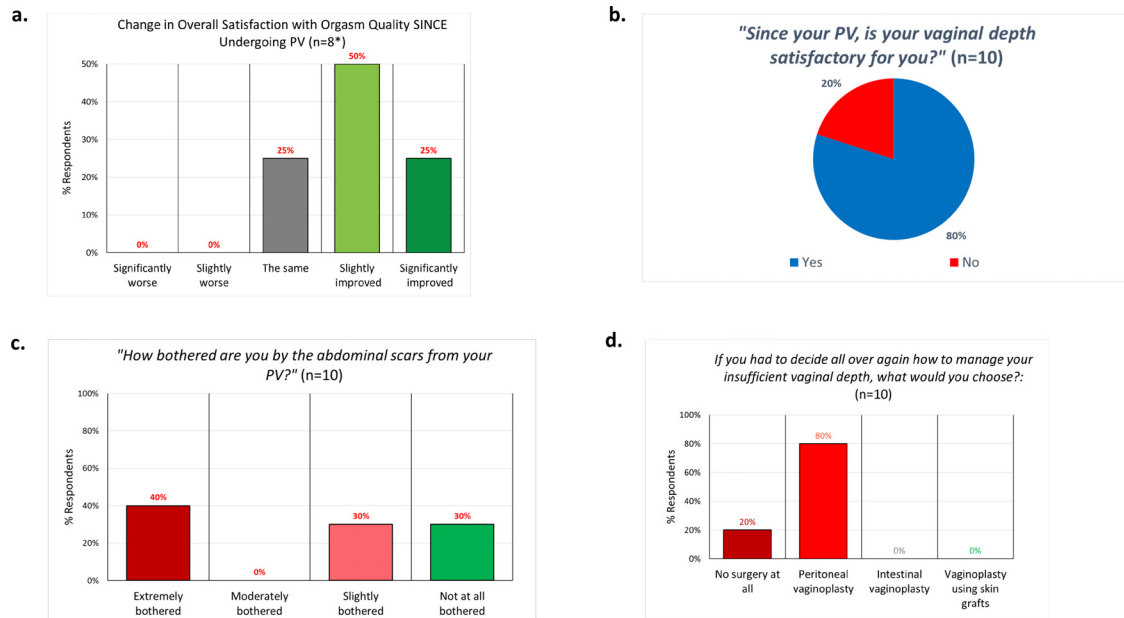


Figure 5. a) Patient reported experience of vaginal moisture with sexual thoughts and/or physical stimulation before and after PV; b) Comparison of subjective feeling of moisture after PV compared to initial PIV. (n = 5 because 5 patients did not report feeling vaginal moisture after their initial PIV.)

possible that high satisfaction rates in our study resulted from improved body image and/or improved sexual function from even modest increases in vaginal depth. It should be noted that, to date, it is unclear what minimum vaginal depth predicts patient satisfaction among both trans- and cis-gender women.

DISCUSSION

PV was first described by Davydov in 1974 for cases of congenital vaginal agenesis among cis-gender women with rudimentary to absent uterine structures.¹⁰ This technique involved advancement of peritoneum adherent to the bladder and rectum. Most reports of PV have been for treatment of congenital conditions^{5,13,14} and are modifications of the Davydov technique,⁹ with laparoscopic and robotic-laparoscopic approaches commonly used in recent years.^{11,14,15}

The use of PV specifically for gender-affirming vaginoplasty is relatively new and has only been rarely reported.^{6,7,9} Most reports of gender-affirming PV have highlighted use of peritoneum in primary gender-affirming vaginoplasty,⁷⁻⁹ as an alternative to traditional primary PIV (which uses only penile and scrotal skin).⁶ These authors describe dissecting a neovaginal cavity and lining it with penile skin and/or scrotal skin grafts, but then augmenting depth by incorporating surrounding peritoneal tissue (modified Davydov technique) around the vaginal apex to achieve vaginal depth of ~14 cm. We choose to not use peritoneum for primary vaginoplasty surgery for a variety of reasons. First, because we have found that the depth limiting factor is typically not availability of epithelium to line the canal, but the

distance between the introitus and the recto-vaginal peritoneal fold. Second, because use of penile+scrotal skin typically achieves equal depth to what is reported with augment by peritoneum. Third, because we feel it is advantageous to reserve use of peritoneum for salvage cases.

Use of peritoneum specifically for salvage vaginoplasty to treat neovaginal shortening after PIV has been even less commonly reported.^{7,11} In a series of 11 cases of peritoneal vaginoplasty for various indications, Acar et al included only 5 salvage vaginoplasties that utilized peritoneum. Furthermore, these cases did not utilize peritoneum alone for reconstruction. In all cases, peritoneum overlying the posterior bladder and rectum (by the modified Davydov technique) was combined with lateral abdominal full-thickness skin grafts that were interposed in between the residual vaginal canal and the peritoneum-lined portion.⁷ Dy et al also report on the use of peritoneum for 24 salvage cases, and in those patients in whom the peritoneal flaps did not reach the residual canal, they also harvested full thickness skin grafts to augment the canal.¹¹

Furthermore, in all reports of gender-affirming vaginoplasty, it was unclear what proportion of the final vaginal canal length was created from peritoneum vs from penile and/or scrotal skin, as only total final postoperative vaginal depth was measured.⁶⁻⁹ To date, the small number of reports from the literature using peritoneum for salvage surgeries, combined with the use of mixed tissues, has prevented accurate assessment of outcomes from salvage PV.

Furthermore, another gap in the literature is confusion stemming from terminology used to differentiate between neovaginal

canal stenosis and shortening. Stenosis is a term typically used in Urology, and by Merriam Webster to mean “a narrowing or constriction of the diameter of a bodily passage or orifice,”¹⁶ and not the shortening of the neovaginal canal that treated patients are described to have. Loss of vaginal depth due to loss of viability of the skin flaps lining the deepest portion of the canal should be referred to as canal “shortening”. For example, neither previous described techniques, nor the one we describe, describe salvage of epithelium-lined canal deep to any “stenosis”, which would be expected if only “stenosis” was being treated. Instead, both describe creation of new vaginal depth. As such, these techniques treat *shortening*, and not “stenosis”.

Proposed Advantages of the Single-Pedicled Peritoneal Hinge Flap

Single-pedicled vaginoplasty techniques have only been rarely reported.⁸ X.W. Zhao et al reported use of a single peritoneal flap in 83 cis-gender patients with Mayer-Rokitansky-Küster-Hauser (MRKH) syndrome.⁵ However, this flap was superiorly based, with the undivided portion of the peritoneum near the navel. Meanwhile, Suwajo et al reported 1 case of a single-pedicled peritoneal flap for use in primary gender-affirming vaginoplasty.⁸ This flap was based on the deep inferior epigastric vessels and involved externalization of the flap through a groin incision, with the flap delivered into the neovaginal cavity extra-peritoneally through a separate perineal incision.⁸

Using the Davydov technique^{7,9,11} 2 separate segments of peritoneum (anterior peritoneum adherent to the posterior-bladder and posteriorly, peritoneum adherent to the rectum) are approximated to form a new neovaginal apex. This contrasts with our technique, which uses a single flap to create the entire circumference of the peritoneal portion of the neovagina (vs separate segments of peritoneum) and, importantly, excludes the rectum. (Figure 3)

Proposed advantages of our single-pedicled urachus-peritoneal hinge flap technique include total exclusion of the rectum. The resulting peritoneal vaginal canal pouch has no suture lines at the vaginal canal apex, and no resting tension on the pouch's lateral suture lines. Our technique includes use of a spatulated technique which also has never been described. This contrasts with the modified Davydov technique, where a full rectum and bladder apply resting tension to the suture lines. Furthermore, our technique allows for interposition of an omental flap to support and reinforce the vaginal-peritoneal anastomosis. Finally, inclusion of the urachus (the fibrous vascularized remnant of the allantois) allows for a more substantive flap than peritoneum alone.

Achievable Additional Depth from Use of Peritoneum and Impact on Surgical Planning

Understanding the amount of vaginal depth that can be restored with peritoneum exclusively is crucial for patient counseling and surgical decision-making. Our present series estimates the increase in depth that can be achieved with

peritoneum alone, because vaginal canal depth was measured both preoperatively and postoperatively for all cases, and no tissue other than peritoneum was used. The natural limitations of peritoneal reach are important technical considerations that have not been emphasized in the prior vaginoplasty literature. When PV is performed for MRKH patients, the neovaginal lining can often be made completely with peritoneum because the absence of a prostate gland facilitates deeper pelvic dissection and transposition of peritoneal flaps.⁷ In contrast, in gender-affirming cases, most authors combine peritoneum with use of skin grafts,^{6,8,9,11,17} presumably because they recognize that there is insufficient pelvic peritoneum to reach as far as the introitus. The actual achievable reach (ie, the minimum required residual vaginal depth to use this technique) has not previously been defined prior to this study.

Applications of Peritoneal Vaginoplasty: Our Algorithm

In our experience, use of peritoneum for salvage surgery (by any method) has the following minimum criteria: first, the patient's residual vaginal canal must have sufficient width (circumference) to afford satisfactory intromission (mean erect cis-gender penis girth is 12cm)¹⁸; second, patients must have a minimum vaginal depth of about 7 cm to allow abdominal peritoneum to reach the residual vaginal canal vault. This length corresponds to the vaginal canal space that lies between the introitus and the rectovesical junction, which is out of reach of peritoneal flaps mobilized from the pelvis. Within the pelvis there is a relatively paucity of available peritoneum. For example, the minimum area of peritoneum necessary to line a 7 cm cylindrical space is 84 cm² (7 cm x 12 cm).

In our hands, peritoneal vaginoplasty is not an option in patients with <7cm of residual canal for 2 reasons. First, there is no peritoneum between the introitus and the rectovesical fold, which based on our colon vaginoplasty and peritoneal vaginoplasty series resides on average approximately 10 cm from the introitus.⁴ The only source of peritoneum that could be mobilized to reach the introitus is peritoneum anterior and posterior to the peritoneal incision at the rectovesical fold. In our operative experience, this peritoneum can be pulled a maximum of ~ 3 cm. towards the introitus, but it cannot be pulled a distance of 10 cm. to reach the introitus.

For patients with < 7cm of residual skin-lined vaginal canal (and/or patients with insufficient residual vaginal canal *width* to afford satisfactory intromission), we favor performing salvage right colon vaginoplasty⁴ (Figure 6).

PV could be useful in primary gender-affirming vaginoplasty for cases of significant penoscrotal hypoplasia when there is insufficient skin from the penis and scrotum to line the neovaginal canal. However, in such cases, it is important to perform preoperative genital skin measurements to estimate the amount of vaginal canal lining that can be achieved.

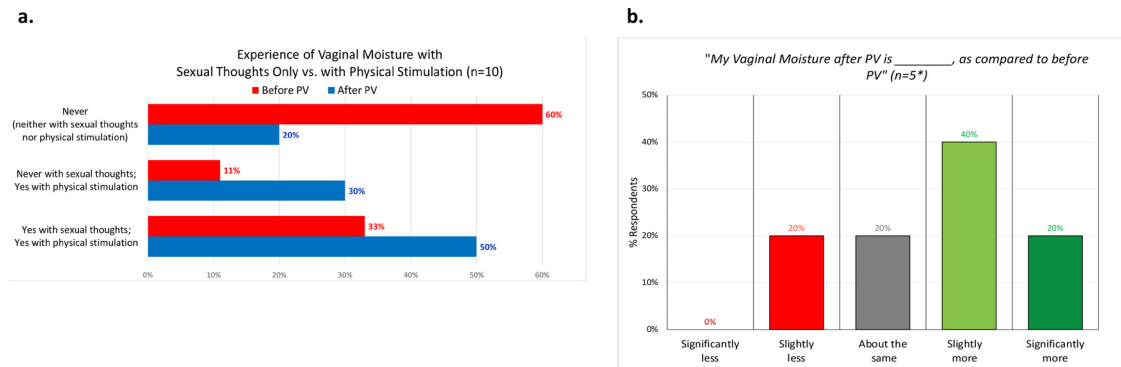


Figure 6. Proposed salvage vaginoplasty treatment algorithm.

Durability of Vaginal Depth Augmented by Peritoneum

Vaginal depth with PV at both early and late follow-up time-points has not previously been well defined; therefore, the durability of PV over time is not well understood. Our study compared immediate postoperative vaginal depth with vaginal depth at final follow-up of more than 1 year. We found that there is a variable degree of contraction and loss of depth that occurs between immediate and long-term follow-up. However, all patients (100%) maintained a net gain in vaginal depth by an average of 3.4cm (range: 1–6.4).

Patient's Subjective Experience of Vaginal Moisture post-PV

Other studies have previously suggested that the use of peritoneum may contribute to natural vaginal lubrication ("wetness") with arousal.^{8,12} Our results show that many do experience lubrication with sexual arousal. Given the improbability that peritoneum would be able to acquire this function and contribute to vaginal moisture, we hypothesized the "wetness" these patients described was likely normal pre-ejaculate fluid draining from their urethral opening. As such, this would reflect the decrease in gender dysphoria, improved self-image, and improved sexual function we so often see after gender-affirming GAS.

Patient Satisfaction and Experience

Our results thus far demonstrate that overall satisfaction with PV is high and that the procedure is well tolerated. Nearly all patients stated that they would choose their surgery again to treat neovaginal shortening. In our series, noninfectious urinary frequency occurred in less than half of the patients. This may be related to temporary neuropraxia of bladder sensory nerves/nerve plexus with the posterior peritoneal dissection and was found to fully resolve by 2–6 months. Patients should be counseled about this risk and reassured should symptoms arise. One of our patients (a model) expressed severe dissatisfaction over her (well-healed) abdominal scars after use of the multi-arm DaVinci Xi. We have scheduled her for a scar revision. While the robotic port

scars are small, they can be particularly bothersome if the patient is prone to keloids. We have learned to counsel patients about expected cosmesis and keloid risks.

CONCLUSIONS

Revision vaginoplasty with our single-pedicled peritoneal hinge flap technique is a safe and effective technique for treating complications of neovaginal stenosis and canal shortening after gender-affirming PIV. As peritoneal reach is limited, residual usable vaginal canal must be at least 7cm to allow for restoration of adequate depth with peritoneum alone. The single-pedicled peritoneal hinge flap technique has potential advantages over existing PV techniques in that it results in no tension on suture lines and completely excludes the rectum. While not described in this paper, other potential uses of our peritoneal hinge flap include use to reinforce the repair site for rectovesical fistulae in men and women, and for post-hysterectomy rectovaginal fistulae in women.

Corresponding Author: Maurice M. Garcia, MD, MAS, 8635 W. Third St., Suite 1070W, Los Angeles, CA 90048, USA.; E-mail: maurice.garcia@cshs.org

Conflict of Interest: The authors report no conflicts of interest.

Funding: Funded by a research grant from Dr. Richard Onofrio to the Cedars-Sinai Transgender Surgery and Health Program.

STATEMENT OF AUTHORSHIP

Shannon M. Smith: Writing – Original Draft, Writing – Review & Editing, Visualization; Nance Yuan: Writing – Review & Editing, Visualization; Jenna Stelmar: Visualization; Grace Lee: Writing – Review & Editing; Amit Gupta: Conceptualization, Methodology, Investigation; Hyung L. Kim: Methodology, Investigation; Maurice M. Garcia: Conceptualization, Methodology, Investigation, Visualization, Supervision.

REFERENCES

1. Bouman MB, Buncamper ME, van der Sluis WB, et al. Total laparoscopic sigmoid vaginoplasty. *Fertil Steril* 2016;106:e22–e23.
2. Gaither TW, Awad MA, Osterberg EC, et al. Postoperative complications following primary penile inversion vaginoplasty among 330 male-to-female transgender patients. *J Urol* 2018;199:760–765.
3. Pariser JJ, Kim N. Transgender vaginoplasty: techniques and outcomes. *Transl Androl Urol* 2019;8:241–247.
4. Garcia MM, Shen W, Zhu R, et al. Use of right colon vaginoplasty in gender affirming surgery: proposed advantages, review of technique, and outcomes. *Surg Endosc* 2021;35:5643–5654.
5. Zhao XW, Ma JY, Wang YX, et al. Laparoscopic vaginoplasty using a single peritoneal flap: 10 years of experience in the creation of a neovagina in patients with Mayer-Rokitansky-Kuster-Hauser syndrome. *Fertil Steril* 2015;104:241–247.
6. Dy GW, Jun MS, Blasdel G, et al. Outcomes of gender affirming peritoneal flap vaginoplasty using the da vinci single Port versus Xi robotic systems. *Eur Urol* 2021;79:676–683.
7. Acar O, Sofer L, Dobbs RW, et al. Single port and multiport approaches for robotic vaginoplasty with the davydov technique. *Urology* 2020;138:166–173.
8. Suwajo P, Ratanalert W, Sooksatian K, et al. Pedicled peritoneal flap vaginoplasty in male-to-female gender affirmation surgery: a case report. *Female Pelvic Med Reconstr Surg* 2020;26:e23–e26.
9. Jacoby A, Maliha S, Granieri MA, et al. Robotic davydov peritoneal flap vaginoplasty for augmentation of vaginal depth in feminizing vaginoplasty. *J Urol* 2019;201:1171–1176.
10. Davydov SN, Zhvitiashvili OD. Formation of vagina (colpoptosis) from peritoneum of Douglas pouch. *Acta Chir Plast* 1974;16:35–41.
11. Dy GW, Blasdel G, Shakir NA, et al. Robotic peritoneal flap revision of gender affirming vaginoplasty: A novel technique for treating neovaginal stenosis. *Urology* 2021;154:308–314.
12. Mhatre P, Mhatre J, Sahu R. New laparoscopic peritoneal pull-through vaginoplasty technique. *J Human Reproduct Sci* 2014;7:181–186.
13. Qin C, Luo G, Du M, et al. The clinical application of laparoscope-assisted peritoneal vaginoplasty for the treatment of congenital absence of vagina. *Int J Gynaecol Obstet* 2016;133:320–324.
14. Ma Y, Qin R, Bi H, et al. The use of peritoneal tissue mobilised with a novel laparoscopic technique to reconstruct a neovagina. *J Plast Reconstr Aesthet Surg* 2009;62:326–330.
15. Jun MS, Gonzalez E, Zhao LC, et al. Penile inversion vaginoplasty with robotically assisted peritoneal flaps. *Plast Reconstr Surg* 2021;148:439–442.
16. Merriam-Webster. "Stenosis". 2022 [cited 2022 4/28/2022].
17. Salibian AA, Schechter LS, Kuzon WM, et al. Vaginal canal reconstruction in penile inversion vaginoplasty with flaps, peritoneum, or skin grafts: where is the evidence? *Plast Reconstr Surg* 2021;147 634e-643e.
18. Wessells H, Lue TF, McAninch JW. Penile length in the flaccid and erect states: guidelines for penile augmentation. *J Urol* 1996;156:995–997.