

A Cadaveric Anatomical Study on Anterior Communicating Artery Aneurysm Surgery by Extended Endoscopic Endonasal Approach

Abstract

Background: The use of minimally invasive approaches in the management of cerebral aneurysms continues to evolve and a purely endoscopic endonasal approach (EEA) for cerebral aneurysm has its own advantages. The purpose of the present study is to perform a detailed anatomical dissection study to test the usefulness of the extended EEAs for selected anterior communicating artery (ACoA) aneurysm. **Materials and Methods:** Nine human cadaveric heads were used for this study, and all dissections were performed through the endonasal corridor. Endoscopic endonasal surgical dissections were carried out, and surgery was simulated in all specimens to reach the ACoA region. The ACoA complex, its neural and osseous relations, degree of vascular exposure, and the ability to perform clip placement were observed and analyzed. **Results:** The transplanum and transtuberulum approaches exposed the A1 and A2 segments of the anterior cerebral artery and the ACoA in all specimens. This route allowed clip ligation of the distal A1 branches, ACoA and proximal A2 branches to the level of the pericallosal segment. Proximal and distal control was most readily achievable at the level of the ACoA complex. **Conclusion:** The present cadaveric study on nine specimens with bilateral dissection has demonstrated that the endonasal transplanum transtuberulum approach to the ACoA region provides excellent visualization of the vasculature. When selected prudently, such lesions may be favorable targets for an extended endoscopic endonasal (EEA) in comparison to transcranial approaches that may provide a suboptimal exposure.

Keywords: Anterior communicating artery, cadaveric study, cerebral aneurysm, endoscopic endonasal approach

Introduction

The use of minimally invasive approaches in the management of cerebral aneurysms continues to evolve as a result of the ongoing search for safer and effective treatments. Although keyhole approaches, such as the supraorbital craniotomy, have been used to reduce brain exposure and retraction for the treatment of the anterior communicating artery (ACoA) aneurysms, the main disadvantage of such approaches is difficulty in managing an intraoperative aneurysm rupture through the narrow surgical corridor, particularly in the case of an edematous and swollen brain.^[1] The significant advancement in the management of cerebral aneurysms has prompted neurosurgeons to utilize the endoscopic endonasal approach (EEA) for intracranial aneurysm clipping.^[2-4] The application of the endoscope as an adjunct to the microscope to clip intracranial aneurysm through

craniotomy has been showed as a safe and effective tool for better visualization of cerebrovascular branch points and to increase the quality of treatment^[2,5-7] The introduction of the EEA for the treatment of cerebral aneurysms is a natural evolutionary step in the advancement of endoscopic surgery.^[1,8-12]

Purely EEA for cerebral aneurysm clipping is still in its early years, although the interest in extended endoscopic transsphenoidal approaches has been renewed for many pathological entities. The purpose of the present study is to perform a detailed anatomical dissection study to test the usefulness of the extended EEAs for selected ACoA aneurysms.

We performed a cadaveric dissection study on nine specimens to study the relevant vascular anatomy through the extended EEA. We also aimed to assess the possible

**Anil Kumar Sharma,
Dhyanesh Kumar
Sharma¹**

*Departments of Neurosurgery
and ¹Anatomy, All India Institute
of Medical Sciences, Raipur,
Chhattisgarh, India*

Address for correspondence:

*Dr. Anil Kumar Sharma,
Department of Neurosurgery,
All India Institute of Medical
Sciences, Raipur,
Chhattisgarh, India.
E-mail: dr.anilsharma02@
gmail.com*

Access this article online

Website: www.asianjns.org

DOI: 10.4103/ajns.AJNS_160_20

Quick Response Code:



This is an open access journal, and articles are distributed under the terms of the Creative Commons Attribution-NonCommercial-ShareAlike 4.0 License, which allows others to remix, tweak, and build upon the work non-commercially, as long as appropriate credit is given and the new creations are licensed under the identical terms.

For reprints contact: WKHLRPMedknow_reprints@wolterskluwer.com

How to cite this article: Sharma AK, Sharma DK. A cadaveric anatomical study on anterior communicating artery aneurysm surgery by extended endoscopic endonasal approach. Asian J Neurosurg 2020;15:908-12.

Submitted: 16-Apr-2020

Revised: 30-May-2020

Accepted: 25-Jul-2020

Published: 19-Oct-2020

maneuverability of anterior circulation vessels, the visibility of adjacent vessels, and surrounding perforator anatomy through the EEA to simulate the surgical treatment of cerebral aneurysms.

Materials and Methods

Nine human cadaveric heads were used for this study and all dissections were performed through the endonasal corridor. Local institutional research board and ethics was approved for the anatomic study of the human specimens. Endoscopic endonasal surgical dissections were carried out using a rigid endoscope 4 mm in diameter, 18 cm in length, with 0°, 30°, and 45° optics (Karl Storz, Germany). All nine cadaveric specimens were dissected for exposure of the cerebral vasculature of interest, with the removal of the surrounding bone and dura for simulating the operative approach. The surgical dissection was carried out with 0° and 30° endoscopes, and 45° endoscopes were used for examination of vascular branch points and clip blades following clip application.

An endoscopic binostril approach was simulated in all specimens to reach the sellar region. The transnasal approach started with bilateral middle turbinectomies and localization of the bilateral sphenopalatine foramina. Subsequently, a posterior septectomy, bilateral posterior ethmoidectomies, and a wide sphenoidotomy were carried out to expose the sella. At this stage, the exposed area extends from the planum sphenoidale and tuberculum sellae superiorly to the floor of the sphenoid sinus inferiorly. The ACoA complex and its neural and osseous relations were observed and analyzed. The degree of vascular exposure and the capability for temporary clip placements were also assessed. The ability to perform clip placement on the A1, A2 segments and ACoA, was graded as dichotomous outcomes of possible or not possible. Surgical maneuverability was examined for clip placements through both ipsilateral and contralateral nostrils.

Surgical dissection

The middle turbinate was lateralized or removed to facilitate visualization of the entire sphenoid anterior wall. A 20 mm posterior nasal septectomy was performed to allow for an extended endonasal technique. The sphenoid sinus was opened widely, exposing the parasellar segment of the ICA, sella, and planum sphenoidale [Figure 1]. The sphenoid was exposed from the lateral opticocarotid recess (OCR) to the contralateral OCR. The anterior sella floor, tuberculum sellae, and planum sphenoidale were removed. The osseous opening of the planum was extended in the posteroanterior direction for approximately 20 mm. Once the dura mater was opened and resected maximally along the margins of the transplanum opening, the chiasmatic cistern and the lamina terminalis were clearly visible. The dissection of the chiasmatic cistern allowed for the exposure of the optic chiasm and the medial portion of the optic nerve. The

arachnoid of the lamina terminalis was opened using sharp dissection, which brought into view the ACoA in all cases, without the need of any brain manipulation.

Results

Exposure of the ACoA complex was made through an endonasal endoscopic transplanum transtuberculum approach in all cases without injuring the pituitary gland and stalk, other vessels, nerves, and brain parenchyma. The transplanum and transtuberculum approaches exposed the A1 and A2 segments of the anterior cerebral artery and the ACoA [Figure 2]. The average distance from the alar floor to the ACoA was 90 ± 7 mm. The width of skull base defect for adequate exposure was 24 ± 4 mm. The average length of the exposed ACoA was 3 ± 2 mm. We were able to expose the A1 and A2 segments with an average of 6 ± 2 mm and 7 ± 3 mm, respectively [Table 1]. This route allowed clip ligation of the distal A1 branches, ACoA and proximal A2 branches to the level of the pericallosal segment [Figures 3 and 4]. Proximal and distal control was possible at the level of the ACoA complex in all cases. Based on our observations and findings, the EEA provides ready access and visualization to all surfaces of the ACoA, except for the posterior surface. Although the technical challenges of a true ACoA aneurysm could not be studied

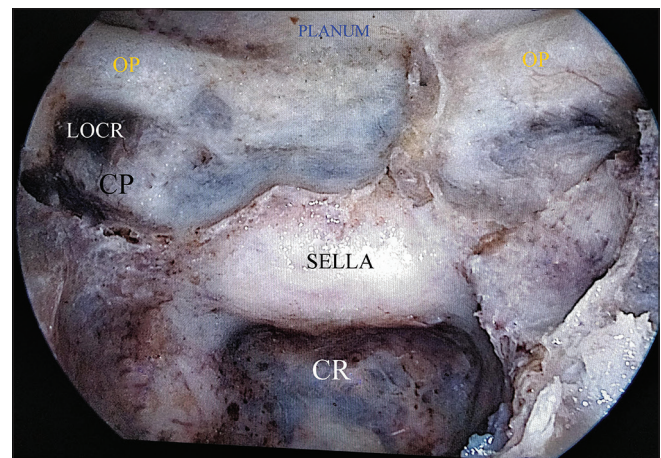


Figure 1: Bony exposure showing sella, optic protuberance, carotid protuberance, lateral opticocarotid recess, clival recess, and planum

Table 1: Morphometric parameters of anterior communicating artery complex vessels and endonasal corridor

Morphometric parameters	Mean length±SD (mm)
Length of A1 exposed	6±2
Length of A2 exposed	7±3
Length of ACoA exposed	3±2
Distance from alar floor to ACoA	90±7
Width of skull base defect for adequate exposure	24±4

ACoA – Anterior communicating artery; A1, A1 segment of the anterior cerebral artery; A2, A2 segment of the anterior cerebral artery. SD – Standard deviation

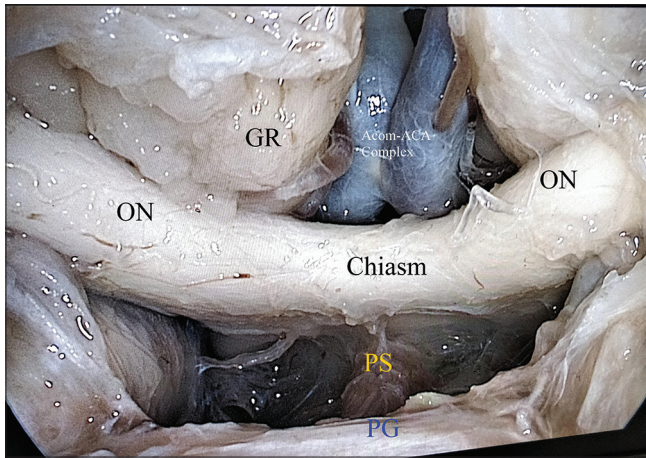


Figure 2: Endoscopic transplanum transtuberulum approach. The dura mater is opened and both optic nerves, the chiasma, pituitary gland, pituitary stalk, both gyrus rectus and anterior communicating artery (ACom-ACA) complex come into view

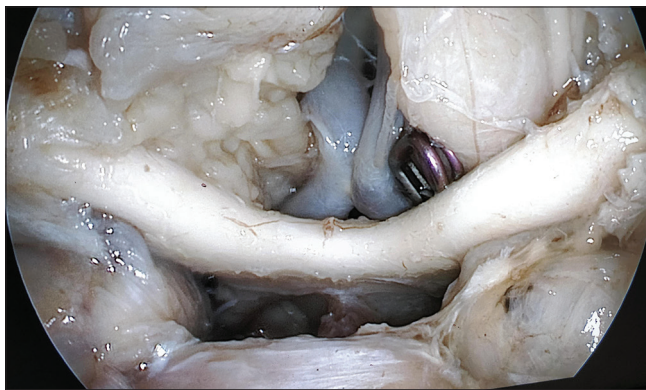

Figure 3: Exposure of anterior communicating artery, distal segments of the proximal anterior cerebral arteries, proximal segments of the distal anterior cerebral arteries, and clipping of the distal segment of the left proximal anterior cerebral artery was performed

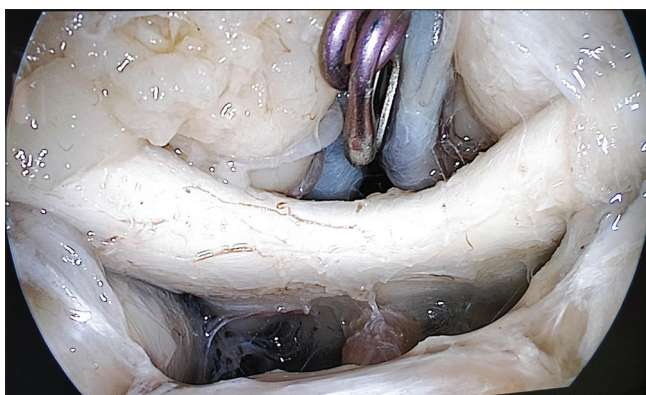

Figure 4: Clipping of the anterior communicating artery was performed and the structures after clipping

in the present study, clip placement was possible in all subjects for the superior, anterior, and inferior surfaces. An anterosuperiorly projecting aneurysm dome would offer the most favorable access for endonasal clip application, best visualization of the aneurysm neck as well as perforators,

and minimal risk of sac rupture. Our results have been critically analyzed with the aim of highlighting the relevant anatomical consideration for clinical application.

Instrument access and clip application

In this feasibility study, we successfully demonstrate how to place an aneurysm clip through an EEA. An excellent visualization of the ACoA, the distal A1, and the proximal A2 was obtained in all cases [Table 2]. All the visualized vessels could be prepared for the application of a clip, if required. Thus, using the extended transsphenoidal approach enables a possible route to the ACoA, with no need for brain manipulation. The single shaft clip applicator offers flexibility for clip removal and placement with adequate visualization of the target vessel, surrounding perforators, and clip tongs during placement.

Discussion

Kassam *et al.* reported the first case of an EEA for vertebral artery aneurysm clipping in 2006.^[11] Several reports, both cadaveric^[3,13-17] and clinical studies,^[1,8,9,12,18,19] have described the advantages of the direct route to address the pathology without brain retraction and better visualization of the vascular anatomy with minimal bone disruption. The transtuberulum-transplanum approach has been used for the clipping of aneurysms arising from the superior hypophyseal, ophthalmic, anterior communicating, and paraclinoid carotid aneurysms.^[1,9,10,20] Cavallo *et al.* demonstrated that extended EEAs provide the possibility of exposing the entire midline skull base from below to reach the brain with its neurovascular structures.^[21] In a cadaveric study, it was found that the endoscopic endonasal transtuberulum approach to the ACoA complex provides excellent visualization of the vasculature in the region with the exception of A2.^[14] Xiao *et al.* concluded that the superior and medial projection of paraclinoid aneurysm and superior and anterior projection of ACoA aneurysm are suitable to be clipped through EEA.^[4]

EEA can provide direct access for microsurgical clipping of strictly selected cerebral aneurysms and may utilize the microsurgical techniques as an alternative to the transcranial approach.^[4] For well-selected cases, EEA may provide a better visualization of the operative field, an increased or equivalent vascular control and direct access to the aneurysm and parent artery, easy access to proximal ICA control without another incision, no need to stretch or resect the brain, no brain parenchyma or any other neurovascular structures between the surgeon and the aneurysm leading to direct surgical corridor compared to transcranial approaches, and quicker recovery of patients.^[2,13] Moreover, it provides a wider, close-up view of the surgical field allowing better exposure “around the aneurysm” in order to visualize blind corners, a close and detailed visualization of the main neurovascular structures and to be sure of full exclusion of the aneurysm from the main cerebral circulation.^[2,13,14]

Table 2: The percentage of success of vascular exposure, instrument access, and clip placements by vascular segment site

Vascular segment	Vascular exposure (%)	Access and clip placements (%)
Distal A1	Visible on both sides in nine specimens (100%)	Clip placement possible in all cases (100%)
Proximal A2	Visible on both sides in nine specimens (100%)	Clip placement possible in all cases (100%)
ACoM	Visible in all cases (100%)	Clip placement possible in all cases (100%)

ACoM – Anterior communicating artery

Nonetheless, the EEA applied to cerebral aneurysm has several limitations that should be taken into consideration, e.g., the inability to perform cerebral revascularization or anastomosis, narrow surgical corridor with leaving less room for the surgeon to comfortably dissect and definitively clip the aneurysm, aneurysm rupture may cloud the endoscope and hamper visualization, the significant endoscopic skills required, and steep learning curve.^[2,4,13,22] The considerable variability of the complex and optic apparatus, the varied and often hidden portions of the precommunicating segments, poor visualization of the posterior perforators, and cadaveric studies demonstrating limited A2 exposure for potential distal control add significant limitations to this approach.^[23] However, further studies have illustrated that the A2 segment of the anterior cerebral artery was accessible in only 40% of cadaveric specimens, adding significant concern to the ability to obtain distal control from this corridor. Although the superior, inferior, and anterior surfaces of the ACoA are usually visible, the posterior aspect can be tricky to fully appreciate. Perforators off the posterior aspect of the ACoA complex must be fully visualized and avoided during clipping; poor visualization of this area may prevent safe clipping from this route. Furthermore, in the setting of a prefixed chiasm and temporary clip placement, there will be less space for neurovascular dissection and exploration in an already confined exposure. It is important to note that in a cadaveric study, one cannot assess the risk of the sac rupture because there is not a method to provide such evidence yet. The present study is limited by its design to explore only anatomical relationships in cadavers with no history of aneurysms. The placement of temporary clips may further reduce the working room in an already confined corridor and prevent good visualization of neurovascular structures. Lower profile technology with greater degrees of freedom, including clips and single-shaft applicators, may help address this limitation.

The indications for endoscopic clip ligation of aneurysms are limited but can be used as part of the multimodality management of intracranial aneurysms in very select cases. An anterior and superiorly projecting aneurysm dome would offer the most favorable access for endonasal clip application along with paramount visualization of the aneurysm neck and perforators. The careful preoperative planning should facilitate the surgeon to decide if the EEA can be a favorable route to treat a specific aneurysm. The application of endoscopic endonasal treatment for

arterial lesions such as aneurysms should be reserved for experienced dedicated endonasal skull base and cerebrovascular teams. Such a technique necessitates advanced familiarity with endoscopic surgery and adequate training in endoscopic arterial lesion management. The establishment of these skill sets should be a prerequisite before such surgeries are considered. We think that more work still needs to be done to further delineate this role, especially as compared to the classic transcranial routes. Furthermore, in cases of an aneurysm, the anticipated morbidity of a new treatment option and approach must be balanced against the morbidity rate of endovascular treatment and transcranial approaches.

Conclusion

The present cadaveric study on nine specimens with bilateral dissection has demonstrated that the endonasal transplanum transtuberculum approach to the ACoA region provides excellent visualization of the vasculature. When selected prudently, such lesions may be favorable targets for an EEA in comparison to transcranial approaches that may provide a suboptimal exposure. Further clinical and case-control studies are required to explore the indications and potential applications of the endonasal route for managing intracranial aneurysms. To establish the safety and applicability in routine clinical practice of the endoscopic endonasal corridor for clip ligation of aneurysms and especially for ruptured cases, larger patient series are needed.

Financial support and sponsorship

Nil.

Conflicts of interest

There are no conflicts of interest.

References

1. Froelich S, Cebula H, Debry C, Boyer P. Anterior communicating artery aneurysm clipped via an endoscopic endonasal approach: Technical note. *Neurosurgery* 2011;68:310-6.
2. Kumar A, Chaturvedi J, Deora H. Endoscopic endonasal clipping of cerebral aneurysms: Started from the bottom, now we are here! *J Neurosurg Sci* 2020;64:308-9.
3. Szentirmai O, Hong Y, Mascarenhas L, Salek AA, Stieg PE, Anand VK, *et al.* Endoscopic endonasal clip ligation of cerebral aneurysms: An anatomical feasibility study and future directions. *J Neurosurg* 2016;124:463-8.
4. Xiao LM, Tang B, Xie SH, Huang GL, Wang ZG, Zeng EM,

- et al.* Endoscopic endonasal clipping of anterior circulation aneurysm: Surgical techniques and results. *World Neurosurg* 2018;115:e33-44.
5. Fischer G, Oertel J, Perneczky A. Endoscopy in aneurysm surgery. *Neurosurgery* 2012;70:184-90.
 6. Peris-Celda M, Da Roz L, Monroy-Sosa A, Morishita T, Rhoton AL Jr. Surgical anatomy of endoscope-assisted approaches to common aneurysm sites. *Neurosurgery* 2014;10 Suppl 1:121-44.
 7. Yoshioka H, Kinouchi H. The roles of endoscope in aneurysmal surgery. *Neurol Med Chir (Tokyo)* 2015;55:469-78.
 8. Drazin D, Zhuang L, Schievink WI, Mamelak AN. Expanded endonasal approach for the clipping of a ruptured basilar aneurysm and feeding artery to a cerebellar arteriovenous malformation. *J Clin Neurosci* 2012;19:144-8.
 9. Germanwala AV, Zanation AM. Endoscopic endonasal approach for clipping of ruptured and unruptured paraclinoid cerebral aneurysms: Case report. *Neurosurgery* 2011;68:234-9.
 10. Kassam AB, Gardner PA, Mintz A, Snyderman CH, Carrau RL, Horowitz M. Endoscopic endonasal clipping of an unsecured superior hypophyseal artery aneurysm. Technical note. *J Neurosurg* 2007;107:1047-52.
 11. Kassam AB, Mintz AH, Gardner PA, Horowitz MB, Carrau RL, Snyderman CH. The expanded endonasal approach for an endoscopic transnasal clipping and aneurysmorrhaphy of a large vertebral artery aneurysm: Technical case report. *Neurosurgery* 2006;59:ONSE162-5.
 12. Somanna S, Babu RA, Srinivas D, Narasinga Rao KV, Vazhayil V. Extended endoscopic endonasal transclival clipping of posterior circulation aneurysms-an alternative to the transcranial approach. *Acta Neurochir (Wien)* 2015;157:2077-85.
 13. Di Somma A, de Notaris M, Stagno V, Serra L, Enseñat J, Alobid I, *et al.* Extended endoscopic endonasal approaches for cerebral aneurysms: Anatomical, virtual reality and morphometric study. *Biomed Res Int* 2014;2014:703792.
 14. Lai LT, Morgan MK, Dalgorf D, Bokhari A, Sacks PL, Sacks R, *et al.* Cadaveric study of the endoscopic endonasal transtuberular approach to the anterior communicating artery complex. *J Clin Neurosci* 2014;21:827-32.
 15. Lai LT, Morgan MK, Snidvongs K, Chin DC, Sacks R, Harvey RJ. Endoscopic endonasal transplanum approach to the paraclinoid internal carotid artery. *J Neurol Surg B Skull Base* 2013;74:386-92.
 16. Sanmillan JL, Lawton MT, Rincon-Torroella J, El-Sayed IH, Zhang X, Meybodi AT, *et al.* Assessment of the endoscopic endonasal transclival approach for surgical clipping of anterior pontine anterior-inferior cerebellar artery aneurysms. *World Neurosurg* 2016;89:368-75.
 17. Unnithan AS, Omofoye O, Lemos-Rodriguez AM, Sreenath SB, Doan V, Zanation AM, *et al.* The expanded endoscopic endonasal approach to anterior communicating artery aneurysms: A cadaveric morphometric study. *World Neurosurg* 2016;89:26-32.
 18. Gardner PA, Vaz-Guimaraes F, Jankowitz B, Koutourousiou M, Fernandez-Miranda JC, Wang EW, *et al.* Endoscopic endonasal clipping of intracranial aneurysms: Surgical technique and results. *World Neurosurg* 2015;84:1380-93.
 19. Yildirim AE, Divanlioglu D, Karaoglu D, Cetinalp NE, Belen AD. Pure endoscopic endonasal clipping of an incidental anterior communicating artery aneurysm. *J Craniofac Surg* 2015;26:1378-81.
 20. Kitano M, Taneda M. Extended transsphenoidal approach to anterior communicating artery aneurysm: Aneurysm incidentally identified during macroadenoma resection: Technical case report. *Neurosurgery* 2007;61:E299-300.
 21. Cavallo LM, Messina A, Cappabianca P, Esposito F, de Divitiis E, Gardner P, *et al.* Endoscopic endonasal surgery of the midline skull base: Anatomical study and clinical considerations. *Neurosurg Focus* 2005;19:E2.
 22. Kumar A. Extended endoscopic endonasal approach for cerebral aneurysm: What we know today. *Acta Sci Neurol* 2020;3:01-2.
 23. Heiferman DM, Somasundaram A, Alvarado AJ, Zanation AM, Pittman AL, Germanwala AV. The endonasal approach for treatment of cerebral aneurysms: A critical review of the literature. *Clin Neurol Neurosurg* 2015;134:91-7.