



Mini-open Repair of the Floating Anterior Inferior Glenohumeral Ligament: Combined Treatment of Bankart and Humeral Avulsion of the Glenohumeral Ligament Lesions

Zachary S. Aman, B.A., Mitchell I. Kennedy, B.S., Anthony Sanchez, B.S., Joseph J. Krob, B.A., Colin P. Murphy, B.A., Connor G. Ziegler, M.D., and Matthew T. Provencher, M.D., MC, USNR, CAPT

Abstract: Anterior shoulder instability often results from avulsion of the anterior inferior glenohumeral ligament (aIGHL) off its insertion on the glenoid, yielding a Bankart lesion. Although less common, avulsion of the ligament attachment to the humerus results in a humeral avulsion of the glenohumeral ligament (HAGL) lesion. Combined Bankart and HAGL lesions, also termed the “floating aIGHL,” create a complex pathology that is not detailed significantly in the literature. We believe a mini-open approach is a viable and reproducible procedure for treatment because it allows for protection of the axillary nerve and other neurovascular structures while providing optimal exposure to both the humeral insertion site of the distal aIGHL and the Bankart lesion, ensuring anatomic restoration. The purpose of this Technical Note is to describe our preferred technique to surgically treat the floating aIGHL, consisting of an anterior HAGL and concomitant Bankart lesion repair through a mini-open approach.

Humeral avulsion of the inferior glenohumeral ligament is a relatively low-prevalence pathology, yet it is a significant contributor to shoulder dysfunction, particularly in recurrent shoulder instability,

where this pathology is reportedly identified in 2.8% to 9.3% of cases.¹⁻⁶ Humeral avulsion of the glenohumeral ligament (HAGL) injuries have been found to more commonly occur in younger male patients.⁷ The cause of a HAGL lesion is typically a high-energy traumatic event, such as an anterior dislocation of the shoulder, and it rarely occurs as an isolated injury.¹

Most commonly, anterior shoulder instability results in avulsion of the anterior inferior glenohumeral ligament (aIGHL) and anteroinferior labrum from their insertion on the glenoid, known as a “Bankart lesion.” Inversely, if avulsion of the ligament occurs at its other attachment on the humerus, the resulting lesion is termed a “HAGL lesion.” Glenohumeral ligament avulsions can occur anteriorly or posteriorly, but anterior tears are the more common variety, reportedly being affected in up to 93% of HAGL cases.^{8,9} However, HAGL lesions are often overlooked because these lesions rarely present as the sole cause of a patient’s loss of function.¹⁰ Avulsion at both the humeral and glenoid attachments of the aIGHL was first described by Warner and Beim¹¹ and termed the “floating aIGHL.” This can be difficult to treat because of its rare occurrence and complexity innate to the bipolar nature of the injury.

From the Steadman Philippon Research Institute (Z.S.A., M.I.K., A.S., J.J.K., C.P.M.) and The Steadman Clinic (C.G.Z., M.T.P.), Vail, Colorado, U.S.A.

The authors report the following potential conflicts of interest or sources of funding: A.S. receives grant support from DJO, educational support from Arthrex and Smith & Nephew, and travel expenses from Arthrex. C.G.Z. receives educational support, travel and lodging, and food and beverage support from Smith & Nephew and food and beverage support from Medtronic USA. M.T.P. serves on the Editorial Board for Arthroscopy, Orthopaedics, Knee, and SLACK and is a committee member of the American Orthopaedic Society for Sports Medicine, American Shoulder and Elbow Surgeons, International Society of Arthroscopy, Knee Surgery & Orthopaedic Sports Medicine (ISAKOS), AAOS, Arthroscopy Association of North America, Society of Military Orthopaedic Surgeons, and San Diego Shoulder Institute; is a paid consultant for Arthrex and the Joint Restoration Foundation (Allosource); and receives IP royalties from Arthrex. Full ICMJE author disclosure forms are available for this article online, as [supplementary material](#).

Received July 28, 2018; accepted August 7, 2018.

Address correspondence to Matthew T. Provencher, M.D., MC, USNR, CAPT, The Steadman Clinic, 181 W Meadow Dr, Ste 400, Vail, CO 81657, U.S.A. E-mail: mprovencher@thesteadmanclinic.com

Published by Elsevier on behalf of the Arthroscopy Association of North America. This is an open access article under the CC BY-NC-ND license (<http://creativecommons.org/licenses/by-nc-nd/4.0/>).

2212-6287/18944

<https://doi.org/10.1016/j.eats.2018.08.015>

When indicated, surgical intervention for isolated HAGL and Bankart lesions has been shown to be effective in biomechanical studies,^{12,13} early outcome studies,^{4-7,14-16} and systematic reviews.^{1,7,17} Case series and case report studies have reported a full return to activities after floating aIGHL treatment,^{4-6,11,14-16,18} yet more outcome studies are needed to validate the treatment protocols used to address these injuries. The purpose of this Technical Note is to describe our preferred technique to surgically treat a floating aIGHL, consisting of an anterior HAGL and concomitant Bankart lesion repair through a mini-open approach (Video 1).

Surgical Technique

Objective Diagnosis

A comprehensive assessment should examine range of motion (ROM) and apprehension; include relocation tests, load-and-shift tests, and strength and neurovascular assessment; and compare findings with the uninjured, contralateral shoulder. Standard shoulder radiographs should be obtained to assess the osseous anatomy of the glenoid and humerus, with close attention being paid to evidence of anterior glenoid bone loss and a Hill-Sachs lesion. Magnetic resonance imaging can confirm the diagnosis and allow for sizing of a HAGL lesion, in addition to showing concomitant chondral or labral pathology. Although not typically necessary for diagnosis, magnetic resonance arthrography can provide further confirmation of the presence of a HAGL lesion, the hallmark of which is the extension of intra-articular contrast into the pericapsular soft tissues of the shoulder (Fig 1).

Patient Positioning and Anesthesia

The patient is positioned in the supine position on the operating table, and general anesthesia is induced by the anesthesia team. Adjunctive regional nerve blocks may be used to improve postoperative pain control, which helps reduce the need for narcotic pain medication. Prophylactic perioperative antibiotics should also be administered. The patient is then transferred to the beach-chair position. An examination under anesthesia is performed to assess the degree of shoulder instability. We prefer to use a padded Mayo stand to support the arm at the elbow rather than an arm positioner.

Diagnostic Arthroscopy

The procedure begins with a standard diagnostic arthroscopy (Fig 2) performed through a posterior and midglenoid portal. This allows for direct visualization and assessment of the articular cartilage, glenoid labrum, biceps tendon, rotator cuff, humeral head, and glenoid, as well as the shoulder capsule. Confirmation of the HAGL's location and extent of injury should be performed at this time, along with any indicated arthroscopic procedures.

Mini-open HAGL Repair

The open repair begins with a standard deltopectoral approach as described by Arciero and Mazzocca.¹⁹ A 6-cm incision is made beginning just lateral to the coracoid, extending toward the axillary crease. Once through the skin and subcutaneous tissue, visualization is maintained with Gelpi retractors placed inferiorly and superiorly. Full-thickness skin flaps are created with a needle-tip Bovie device (Bovie Medical, Clearwater, FL) and Metzenbaum scissors, and the cephalic vein is

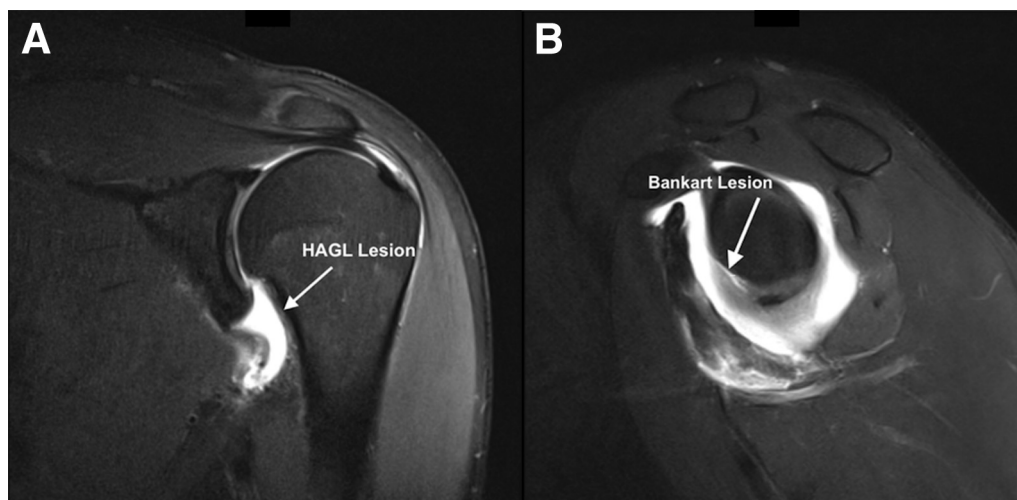


Fig 1. Magnetic resonance arthrograms of a left shoulder showing humeral avulsion of glenohumeral ligament (HAGL) lesion (coronal view) (A) and Bankart lesion (sagittal view) (B). Although not typically needed, magnetic resonance arthrography can provide further confirmation of the presence of a HAGL lesion, the hallmark of which is the extension of intra-articular contrast into the pericapsular soft tissues of the shoulder. Extravasation of intra-articular contrast is shown in A (arrow).

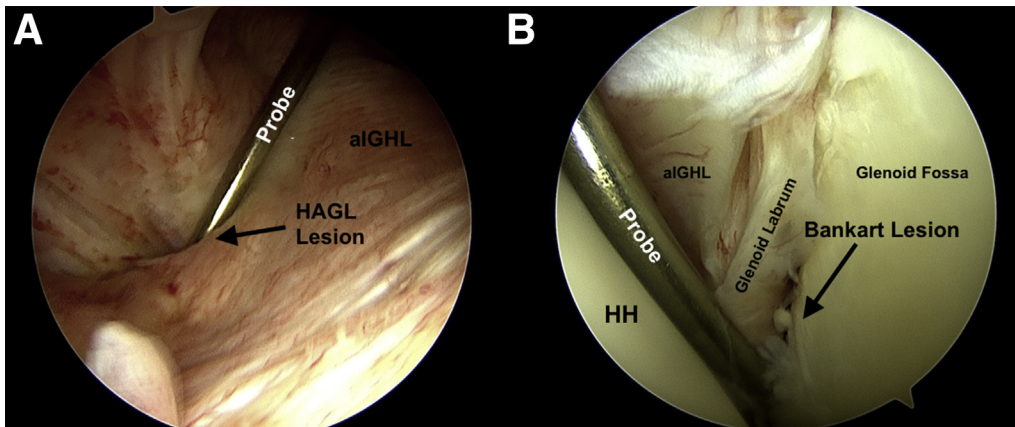


Fig 2. Arthroscopic view from posterior portal confirming humeral avulsion of glenohumeral ligament (HAGL) lesion (A) and Bankart lesion (B) in a left shoulder. Before open repair of the HAGL and Bankart lesions is performed, a diagnostic arthroscopy should be performed to confirm the diagnosis. Once these lesions are confirmed, open surgical repair can proceed. (aIGHL, anterior inferior glenohumeral ligament; HH, humeral head.)

delineated and dissected along its medial aspect to retract laterally. The deltopectoral interval is developed, subdeltoid adhesions are released using scissors and blunt dissection, and the clavipectoral fascia is incised along with removal of any overlying bursal tissue. The conjoint tendon is identified along its lateral extent and mobilized. Care is taken to limit retraction force on the conjoint tendon to protect the musculocutaneous nerve. The superior part of the falciform ligament is then released. A Kolbel retractor is subsequently positioned under the conjoint tendon and deltoid to expose the subscapularis and improve visualization and exposure. The subscapularis anatomy is explored, and its insertion medial to the bicipital groove is marked with a needle-tip Bovie device. The superior and inferior margins are similarly marked, with care taken to protect the anterior circumflex vessels located at the inferior border of the subscapularis muscle body.

Next, the subscapularis tendon is measured from the superior to inferior borders, and a split is made in the tendon at the junction of the superior three-fifths and inferior two-fifths using a No. 15 blade. Depending on the location of the HAGL, it may be visible at this point. In this case, however, the inferior location of the lesion necessitates an inferior subscapularis peel for visualization. This peel is completed by marking the inferior subscapularis insertion at its humeral attachment with a needle-tip Bovie device and then elevating the tendon off the humerus with a No. 15 blade. Care should be taken to always protect the axillary nerve, and external rotation of the arm can help move the nerve away from the surgical field. Again, the anterior circumflex vessels are protected and not incised. After the inferior subscapularis and capsular interval have been dissected and the inferior subscapularis peel is completed, the HAGL tear should be easily identified. In this case,

a small Cobb elevator can be inserted through the capsular defect into the joint, confirming the pathology (Fig 3). Thus, dissection of only the inferior 2 cm of the subscapularis tendon, directly above the protected anterior circumflex vessels, is needed to allow easy identification of the anteroinferior joint capsule and HAGL tear.

Next, the humeral insertion site of the aIGHL is prepared for reattachment using a small Cobb elevator and an arthroscopic rasp. Suture anchor fixation is the preferred repair method. We use one 4.75-mm anchor with suture tape (SwiveLock and FiberTape; Arthrex, Naples, FL). A 3.0- or 3.5-mm interference anchor may also be used depending on the size of the tear. The suture tape is weaved through the avulsed tissue, and

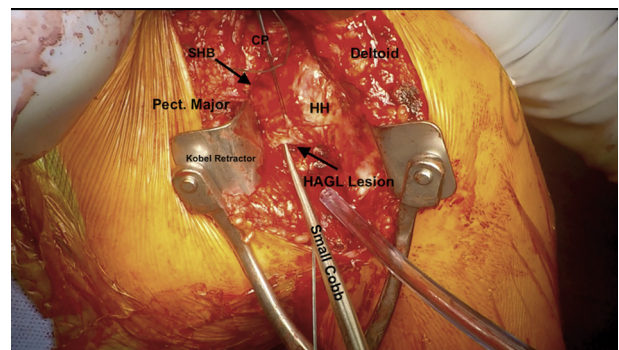


Fig 3. Open view of humeral avulsion of glenohumeral ligament (HAGL) lesion exposed through deltopectoral interval in a left shoulder. After the inferior subscapularis and capsular interval have been exposed and inferior subscapularis peel is completed, the HAGL tear should be easily identified. In this case, a small Cobb elevator could be inserted through the capsular defect into the joint, confirming the pathology. (CP, coracoid process; HH, humeral head; Pect, pectoralis; SHB, short head of biceps tendon.)

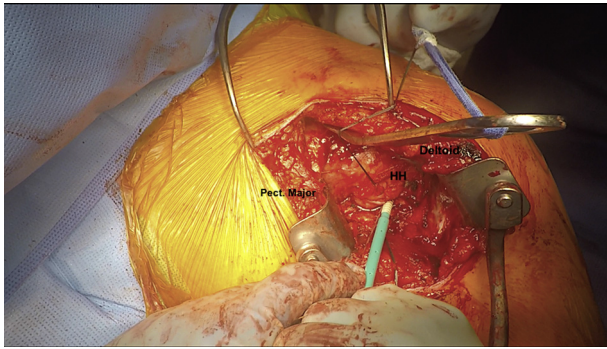


Fig 4. Anchor placement for humeral avulsion of glenohumeral ligament reduction in a left shoulder. The insertion site of the humeral avulsion of the glenohumeral ligament was prepared with a small Cobb elevator and arthroscopic rasp. Suture tape was weaved through the capsular defect, and the suture tails were loaded in a 4.75-mm anchor. The anchor tunnel was predrilled and tapped, and the anchor was subsequently secured in place. (HH, humeral head; Pect, pectoralis.)

an anchor is placed after first predrilling and tapping, given the hard cortical bone located here (Fig 4). We use an additional knotless suture anchor (2.9-mm PushLock anchor; Arthrex) to bolster the repair. After the HAGL repair, attention is turned to the Bankart lesion. We find it easier to repair the capsule to the humerus first and then complete the Bankart repair.

Open Bankart Repair

The open Bankart repair begins with an extension of the horizontal capsulotomy to the glenoid neck. A Gelpi retractor is positioned perpendicular to the incision and used to widen the capsulotomy to expose the glenohumeral joint and Bankart lesion. Retraction in the glenohumeral joint is maintained using a small Cobb elevator or Fukuda retractor. In preparation for repair, an arthroscopic labral elevator is used to elevate the labrum off the glenoid neck and prepare a bleeding, bony repair site. Repair of the labrum is achieved using 4 knotless anchors with suture tape (2.9-mm PushLock and FiberTape) passed through the labrum in a horizontal mattress configuration beginning inferiorly at the 6-o'clock position, progressing sequentially up the anterior face as needed (Fig 5). A total of 4 anchors are used for this case. All anchors can be placed and sutures passed before securing if desired.

Attention is then turned to closure, beginning with the horizontal capsulotomy. This is closed in a side-to-side fashion using figure-of-8 stitches (No. 2 FiberWire; Arthrex). Next, the inferior subscapularis peel is fixed to its previously marked insertion point on the lesser tuberosity (4.75-mm SwiveLock and FiberTape), and the horizontal subscapularis split is repaired with suture tape (FiberTape) in a figure-of-8 fashion. The advantages and disadvantages of the described

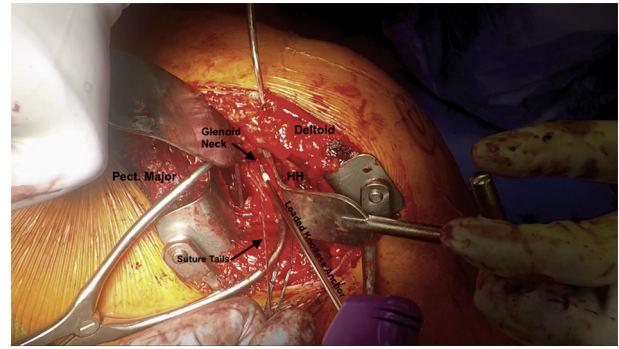


Fig 5. Anchor placement for Bankart repair in a left shoulder. Suture tape is passed through the labrum in a horizontal mattress configuration beginning inferiorly at the 6-o'clock position. Knotless suture anchors with suture tape are placed sequentially from inferior to superior for each passed suture. (HH, humeral head; Pect, pectoralis.)

technique are summarized in Table 1, and pearls and pitfalls are summarized in Table 2.

Postoperative Rehabilitation

The postoperative rehabilitation protocol is summarized in Table 3. After surgery, the affected shoulder is placed in a sling for 6 weeks. Rehabilitation phase I begins immediately with passive ROM to achieve 30° of internal rotation and 60° of external rotation. Phase II includes active-assisted ROM, isometrics, active ROM, and progression to low-load prolonged stretches. Phase III of rehabilitation is the initial resistance and strengthening stage involving strengthening and proprioception exercises in external rotation, internal rotation, initial closed-chain stability, and overhead activity. Phase IV stresses external rotation at 45° and reaching 90° at week 13. Return to sport is phase V. The criteria for a return to full activities include functional, pain-free active ROM; maximized strength; and proper scapulothoracic mechanics.

Table 1. Advantages and Disadvantages

Advantages	Disadvantages
Open repair allows for improved exposure to ensure optimal anatomic repair	Cosmesis concerns from incision Slightly increased risk of blood loss
Open dissection with careful attention to anatomy helps avoid iatrogenic neurovascular injury	Need for combination arthroscopy and open procedure, which may result in longer procedure
Open technique with deltopectoral approach allows for concomitant pathologies to be treated in 1 operation	
Surgical repair results in improved stability when compared with nonoperative treatment	

Table 2. Pearls and Pitfalls

Pearls	Pitfalls
Careful attention to anatomy and adequate exposure will minimize risk of iatrogenic injury to neurovascular structures	Iatrogenic injury to neurovascular structures including axillary nerve
Diagnostic arthroscopy allows for confirmation of diagnoses and planning for surgical repair of concomitant pathologies	Inadequate exposure of lesion
Standard deltopectoral approach is relatively unchallenging	Inadequate preparation of humeral neck or glenoid rim
Anterior circumflex vessels should be avoided	
Subscapularis split is less traumatic to tendon and does not require ROM restrictions	

ROM, range of motion.

Discussion

In any patient presenting with anterior shoulder instability, it is essential to fully evaluate the cause of instability, which includes assessing for a HAGL lesion. HAGL lesions reportedly occur in 9% of patients with anterior shoulder instability¹³; however, Bankart lesions are exceedingly common, occurring in 97% of first-time anterior shoulder dislocators,²⁰ and are the most frequently associated injuries, with a rate of 15% to 41% of cases.^{7,17} Surgical intervention is highly

recommended to address both lesions because failure to diagnose and subsequently treat concomitant HAGL tears has been reported to result in a high rate of recurrent anterior instability and isolated Bankart repair failure.^{5,6,17,21,22}

Literature regarding the surgical treatment and outcomes of concomitant anterior HAGL and Bankart lesions is limited.^{4-7,11,14-16} To date, there is no consensus regarding the optimal surgical technique for treatment of these combined lesions. Several reports have

Table 3. Summary of Postoperative Rehabilitation Protocol

Phase	Weeks	Protocol Details
Phase I: passive ROM	1-6	Shoulder is placed in sling for 6 wk postoperatively Day 1: passive ROM, including cervical, elbow/hand/wrist, ball squeeze, scapular retraction/depression, abduction, internal rotation, external rotation to 30°, and forward elevation/scapular plane elevation to 100° Weeks 1-2: arm-supported computer use and driving Week 3: pendulums, aqua therapy for active-assisted ROM, external rotation to 60°, and forward elevation/scapular plane elevation to 120° Week 6: eating/drinking, dressing, and washing with affected shoulder
Phase II: active-assisted or active ROM	6-9	Week 6: active-assisted ROM, isometrics, active ROM, and eventually low-load prolonged stretches; active-assisted ROM and isometric activities should include internal rotation, external rotation, flexion, and abduction Week 7: active ROM, including bench-press series, modified military press, side-lying external rotation, salutes, full can, prone row progression, and open chair proprioception; lifting of up to 5 lb begins Week 8: low-load prolonged stretches with towel internal rotation, cross-arm stretch, and sleeper stretch; progression to door-jam series and TV watching stretch Weeks 8-9: prone external rotation to 90°, prone Y's, and prone liftoff are initiated
Phase III: initial resistance	9	Week 9: strengthening and proprioception exercises in external rotation, internal rotation, double-arm external rotation, full can, forward punch, rows, biceps curl, triceps extension, latissimus pull down, and initial closed-chain stability; overhead activity begins
Phase IV: advanced resistance	10-21	Week 10: bear hugs, external rotation to 45°, rhythmic stabilization exercises, and lifting > 5 lb begins Week 13: external rotation to 90° is added Weeks 17-21: advanced closed-chain stability, plyometrics, and decelerations are added
Phase V: RTS	Approximately 17-25	Sports clearance once reaching RTS criteria: Week 17: skiing may begin Week 21: throwing progression begins Week 25: overhead/serving sports, contact sports, and swimming resume

ROM, range of motion; RTS, return to sport.

described all-arthroscopic as well as open repair techniques to treat anterior instability.^{4-7,11,15,16} Shah and Selesnick¹⁴ proposed arthroscopically repairing the Bankart lesion with a subsequent mini-open HAGL repair procedure. Our surgical technique emphasizes addressing the HAGL lesion and Bankart lesion concurrently with an open procedure, making sure the humeral head is reduced before performing the Bankart repair to avoid overconstraint of the joint and possible restriction of motion.

Historically, open repairs of isolated Bankart lesions have been reported to have lower rates of recurrent instability and lower rates of persistent capsular laxity than arthroscopic techniques.^{12,15,23} For isolated HAGL lesions, both open and all-arthroscopic techniques have resulted in promising patient outcomes; however, these comparisons are limited to small case series and case studies.^{10,15,18,24} In 4 studies reporting the outcomes of 13 patients in total undergoing concomitant treatment of both lesions, 100% of patients returned to full activity without any evidence of recurrent instability or symptoms regardless of technique at a minimum of 12 months' follow-up.^{4,11,14-16} Potential shortcomings include stiffness and decreased range of external rotation.^{17,25}

In this Technical Note, we describe a viable and reproducible open procedure for managing combined anterior HAGL and Bankart lesions. We acknowledge that an open repair for the treatment of both lesions requires a larger incision in comparison with an isolated open HAGL repair as described by Godin et al.²⁵ or a cosmetically superior arthroscopic technique.^{24,25} However, an open repair allows for improved protection of the axillary nerve and other neurovascular structures and provides optimal exposure of both the humeral insertion site of the distal aIGHL and the Bankart lesion, ensuring complete anatomic restoration.^{23,25} Although recent literature and our experience with this surgical treatment have yielded positive results, further research on the long-term patient outcomes must be performed to validate this surgical technique.

References

- Bui-Mansfield LT, Banks KP, Taylor DC. Humeral avulsion of the glenohumeral ligaments: The HAGL lesion. *Am J Sports Med* 2007;35:1960-1966.
- Wolf EM, Cheng JC, Dickson K. Humeral avulsion of glenohumeral ligaments as a cause of anterior shoulder instability. *Arthroscopy* 1995;11:600-607.
- Tirman PF, Steinbach LS, Feller JF, Stauffer AE. Humeral avulsion of the anterior shoulder stabilizing structures after anterior shoulder dislocation: Demonstration by MRI and MR arthrography. *Skeletal Radiol* 1996;25:743-748.
- Rhee YG, Cho NS. Anterior shoulder instability with humeral avulsion of the glenohumeral ligament lesion. *J Shoulder Elbow Surg* 2007;16:188-192.
- Bokor DJ, Conboy VB, Olson C. Anterior instability of the glenohumeral joint with humeral avulsion of the glenohumeral ligament. A review of 41 cases. *J Bone Joint Surg Br* 1999;81:93-96.
- Huberty DP, Burkhart SS. Arthroscopic repair of anterior humeral avulsion of the glenohumeral ligaments. *Tech Shoulder Elbow Surg* 2006;7:186-190.
- Bozzo A, Oitment C, Thornley P, et al. Humeral avulsion of the glenohumeral ligament: Indications for surgical treatment and outcomes—A systematic review. *Orthop J Sports Med* 2017;5. 2325967117723329.
- Bui-Mansfield LT, Taylor DC, Uhorchak JM, Tenuta JJ. Humeral avulsions of the glenohumeral ligament: Imaging features and a review of the literature. *AJR Am J Roentgenol* 2002;179:649-655.
- Ames JB, Millett PJ. Combined posterior osseous Bankart lesion and posterior humeral avulsion of the glenohumeral ligaments: A case report and pathoanatomic subtyping of "floating" posterior inferior glenohumeral ligament lesions. *J Bone Joint Surg Am* 2011;93. e118(1)-(4).
- George MS, Khazzam M, Kuhn JE. Humeral avulsion of glenohumeral ligaments. *J Am Acad Orthop Surg* 2011;19:127-133.
- Warner JJ, Beim GM. Combined Bankart and HAGL lesion associated with anterior shoulder instability. *Arthroscopy* 1997;13:749-752.
- Park KJ, Tamboli M, Nguyen LY, McGarry MH, Lee TQ. A large humeral avulsion of the glenohumeral ligaments decreases stability that can be restored with repair. *Clin Orthop Relat Res* 2014;472:2372-2379.
- Southgate DF, Bokor DJ, Longo UG, Wallace AL, Bull AM. The effect of humeral avulsion of the glenohumeral ligaments and humeral repair site on joint laxity: A biomechanical study. *Arthroscopy* 2013;29:990-997.
- Shah AA, Selesnick FH. Traumatic shoulder dislocation with combined Bankart lesion and humeral avulsion of the glenohumeral ligament in a professional basketball player: Three-year follow-up of surgical stabilization. *Arthroscopy* 2010;26:1404-1408.
- Kon Y, Shiozaki H, Sugaya H. Arthroscopic repair of a humeral avulsion of the glenohumeral ligament lesion. *Arthroscopy* 2005;21:632.
- Field LD, Bokor DJ, Savoie FH III. Humeral and glenoid detachment of the anterior inferior glenohumeral ligament: A cause of anterior shoulder instability. *J Shoulder Elbow Surg* 1997;6:6-10.
- Longo UG, Rizzello G, Ciuffreda M, et al. Humeral avulsion of the glenohumeral ligaments: A systematic review. *Arthroscopy* 2016;32:1868-1876.
- Provencher M, McCormick F, LeClere LE, Dewing CB, Solomon DJ. A prospective outcome evaluation of humeral avulsions of the glenohumeral ligament (HAGL) tears repairs in an active population. *Orthop J Sports Med* 2014;2. 2325967114S2325900013.
- Arciero RA, Mazzocca AD. Mini-open repair technique of HAGL (humeral avulsion of the glenohumeral ligament) lesion. *Arthroscopy* 2005;21:1152.
- Taylor DC, Arciero RA. Pathologic changes associated with shoulder dislocations. Arthroscopic and

- physical examination findings in first-time, traumatic anterior dislocations. *Am J Sports Med* 1997;25:306-311.
21. Bach B, Warren R, Fronck J. Disruption of the lateral capsule of the shoulder. A cause of recurrent dislocation. *J Bone Joint Surg Br* 1988;70:274-276.
 22. Mauro CS, Voos JE, Hammoud S, Altchek DW. Failed anterior shoulder stabilization. *J Shoulder Elbow Surg* 2011;20:1340-1350.
 23. Chen L, Xu Z, Peng J, Xing F, Wang H, Xiang Z. Effectiveness and safety of arthroscopic versus open Bankart repair for recurrent anterior shoulder dislocation: A meta-analysis of clinical trial data. *Arch Orthop Trauma Surg* 2015;135:529-538.
 24. Fritz EM, Pogorzelski J, Hussain ZB, Godin JA, Millett PJ. Arthroscopic repair of humeral avulsion of the glenohumeral ligament lesion. *Arthrosc Tech* 2017;6:e1195-e1200.
 25. Godin JA, Sanchez G, Kennedy NI, Ferrari MB, Provencher MT. Open repair of an anterior humeral avulsion of the glenohumeral ligament. *Arthrosc Tech* 2017;6:e1367-e1371.