

Images in medicine

Lens dislocation delaying the diagnosis of metastasis to the optic nerve

Cherkaoui Mandour^{1,&}, Mohammed Boucetta¹

¹Affiliation¹Departement Of Neurosurgery, Military Hospital Mohammed V, Rabat, PC: 10000 Morocco

[&]Corresponding author: Cherkaoui Mandour , Departement Of Neurosurgery, Military Hospital Mohammed V, Rabat, PC: 10000 Morocco

Key words: Metastasis, eye, optic nerve, lens dislocation

Received: Date_30/10/2012 - Accepted: 20/11/2012 - Published: 23/10/2013

Pan African Medical Journal. 2013 16:66. doi:10.11604/pamj.2013.16.66.2165

This article is available online at: <http://www.panafrican-med-journal.com/content/article/16/66/full>

© Cherkaoui Mandour et al. The Pan African Medical Journal - ISSN 1937-8688. This is an Open Access article distributed under the terms of the Creative Commons Attribution License (<http://creativecommons.org/licenses/by/2.0>), which permits unrestricted use, distribution, and reproduction in any medium, provided the original work is properly cited.

Image in medicine

Metastasis to the eye is rare, it can affect almost all ocular tissues. The association of metastasis to the optic nerve and lens dislocation in the same orbit is exceptional. We report a 63 years old man presented with blindness due to a lens dislocation in the left eye. One month later, he presented a right hemiparesis. Brain magnetic

resonance imaging (MRI) showing brain and intra orbital metastasis associated with a lens dislocation. The histological result was provided by a stereotactic biopsy. The eye may be the site of several lesions to both. A lens dislocation can retarded a diagnosis of the nerve optic metastasis.

Figure 1: Brain magnetic resonance imaging (MRI) showing metastasis of the optic nerve associated with a lens dislocation

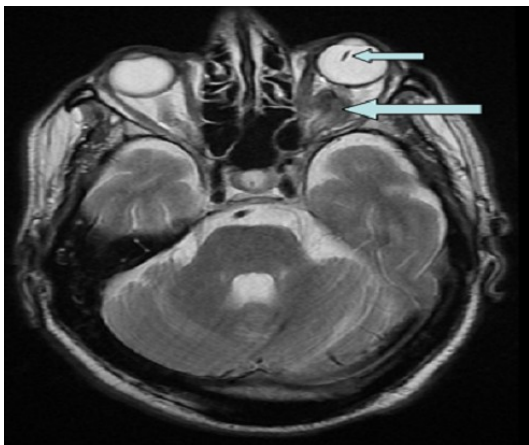


Figure 1: Brain magnetic resonance imaging (MRI) showing metastasis of the optic nerve associated with a lens dislocation