

## How I Do It



# Botulinum Toxin Injection for the Treatment of Delayed Gastric Emptying Following Pylorus-Preserving Gastrectomy: an Initial Experience

Jung Hwan Lee , Chan Gyoo Kim , Young-Woo Kim , Il Ju Choi ,  
Jong Yeul Lee , Soo-Jeong Cho, Young-Il Kim , Bang Wool Eom ,  
Hong Man Yoon , Keun Won Ryu

Center for Gastric Cancer, National Cancer Center, Goyang, Korea

## OPEN ACCESS

**Received:** Apr 13, 2017

**Revised:** May 9, 2017

**Accepted:** May 22, 2017

### Correspondence to

Chan Gyoo Kim

Center for Gastric Cancer, National Cancer Center, 323 Ilsan-ro, Ilsandong-gu, Goyang 10408, Korea.

Tel: +82-31-920-1620

Fax: +82-31-920-2798

E-mail: glse@ncc.re.kr

### Correspondence to

Young-Woo Kim

Department of Cancer Control and Population health, Graduate School of Cancer Science and Policy, Center for Gastric Cancer, National Cancer Center, 323 Ilsan-ro, Ilsandong-gu, Goyang 10408, Korea.

Tel: +82-31-920-1635

Fax: +82-31-920-2798

E-mail: gskim@ncc.re.kr

Copyright © 2017. Korean Gastric Cancer Association

This is an Open Access article distributed under the terms of the Creative Commons Attribution Non-Commercial License (<https://creativecommons.org/licenses/by-nc/4.0>) which permits unrestricted noncommercial use, distribution, and reproduction in any medium, provided the original work is properly cited.

## ABSTRACT

**Purpose:** To report our experience of endoscopic botulinum toxin injection in patients who experienced severe delayed gastric emptying after pylorus-preserving gastrectomy (PPG).

**Materials and Methods:** We reviewed the medical records of 6 patients who received the botulinum toxin injection. They presented with severe delayed gastric emptying in the early postoperative period. Endoscopic botulinum toxin was administered as 4 injections of 25–50 IU into each of the 4 quadrants of the prepyloric area.

**Results:** All botulinum toxin injections were successful without any complications, enabling 5 patients to tolerate soft solid diets and one to tolerate a soft fluid diet within 10 days. The endoscopic criteria of 4 patients improved. Symptom recurrence caused 2 patients to undergo repeat injections that were successful. The median follow-up period was 27 months, and all patients could ingest normal regular diets at the last follow-up.

**Conclusions:** Endoscopic botulinum toxin injection is a feasible treatment option for early delayed gastric emptying after PPG.

**Keywords:** Surgery; Gastric stasis; Gastrectomy; Complications; Endoscopy; Botulinum toxins

## INTRODUCTION

The proportion of early gastric cancer (EGC) cases has increased among surgically treated patients with gastric cancer in Eastern Asia and some Western countries. As the incidence of EGC has increased, minimally invasive surgeries have been performed more widely [1].


Among minimally invasive surgery techniques, pylorus-preserving gastrectomy (PPG) is an attractive option for the treatment of EGC to reduce the development of dumping syndrome and postoperative malnutrition [2]. However, PPG can cause delayed gastric emptying with early fullness and vomiting associated with pyloric spasm. The reported incidence of delayed gastric emptying after PPG ranges from 6.2% to 8.0% [3,4]. The reasons for delayed gastric emptying are not well-established. In a study of resection of the pyloric branch of the canine


## ORCID iDs


Jung Hwan Lee   
<https://orcid.org/0000-0001-7567-0664>

Chan Gyoo Kim   
<https://orcid.org/0000-0002-1651-2559>

Young-Woo Kim   
<https://orcid.org/0000-0002-1559-9672>

Il Ju Choi   
<https://orcid.org/0000-0002-8339-9824>

Jong Yeul Lee   
<https://orcid.org/0000-0001-8709-5097>

Young-Il Kim   
<https://orcid.org/0000-0002-2614-3419>

Bang Wool Eom   
<https://orcid.org/0000-0002-0332-2051>

Hong Man Yoon   
<https://orcid.org/0000-0002-6218-7080>

Keun Won Ryu   
<https://orcid.org/0000-0002-5935-9777>

## Funding

This work was supported by the National Cancer Center, Korea (grant number: 1710280 and 1410130 and 1710120-1).

## Conflict of Interest

No potential conflict of interest relevant to this article was reported.

vagus nerve, gastric stasis developed during the early postoperative period, caused by tonic and phasic contractions of the pylorus [5].

Botulinum toxin has been found to be effective in the treatment of spastic disorders of the smooth muscle. In light of this observation, botulinum toxin could interfere with the tonic contraction of the pylorus, which may be the reason for the improvement of gastric stasis after botulinum toxin injection. It has already been used for the prevention and treatment of gastric stasis as a complication of esophagectomy associated with vagotomies [6], diffuse esophageal spasm, achalasia, and refractory gastroparesis [6-9]. However, no report has evaluated intrapyloric botulinum toxin injection for the treatment of patients with delayed gastric emptying after PPG.

Here, we describe our experience in using intrapyloric botulinum toxin injection to manage patients who complain of gastric stasis symptoms after PPG.

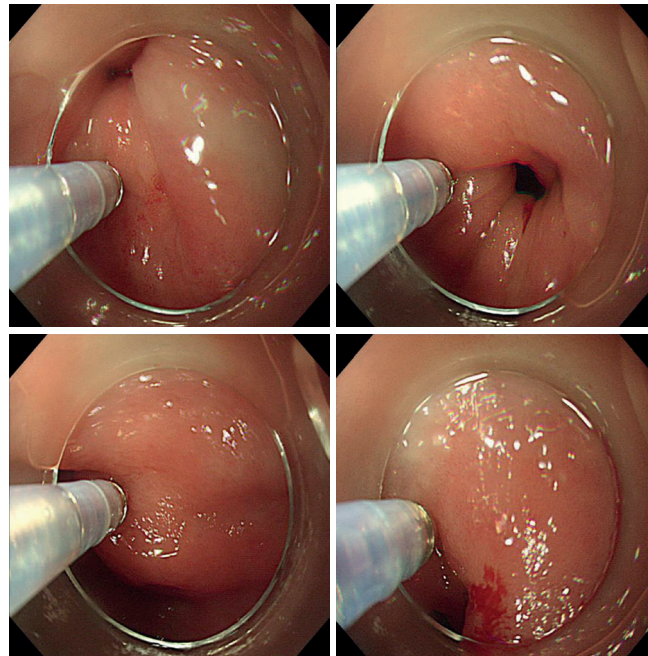
## MATERIALS AND METHODS

From February 2012 to July 2015, 177 patients with EGC underwent laparoscopic-assisted or robotic-assisted PPG at the National Cancer Center of Korea. A total of 13 patients (7.3%) needed managements for delayed gastric emptying after surgery. Seven of these recovered with conservative treatment, such as Levin tube insertion and prokinetics. The other 6 patients were treated with botulinum toxin injection. Informed consent was obtained from all the patients before the procedure. This study conforms to the ethical standards of the Institutional Review Board of the National Cancer Center, Korea and the Helsinki Declaration of 1964 and later versions. Thus, this study was approved by the Ethics Review Board of the National Cancer Center (study number: NCC2016-0177).

Botulinum toxin (25–50 IU per injection; total, 100–200 IU in 5 mL of 0.9% normal saline solution) was injected into the 4 quadrants of the prepyloric area (within 1 cm of the pyloric channel) after the sclerotherapy needle tip was buried firmly into the gastric wall. These procedures were performed by 3 expert endoscopists (**Fig. 1**).

We retrospectively reviewed the outcome of this procedure using medical records and telephone interviews. The Gastric Outlet Obstruction Scoring System (GOOSS) was used to assess the severity of symptoms before and after botulinum toxin injection as follows: 0) no oral intake; 1) only liquid diet; 2) soft solid diet; and 3) low residue or full diet [10,11]. We checked the GOOSS score of each patient before and 10 days after the procedure and at every outpatient clinic visit. Improvements in delayed gastric emptying were defined as the relief of gastric outlet obstruction symptoms or improvement in the GOOSS score 10 days after the procedure.

We also evaluated the improvements in delayed gastric emptying using endoscopic criteria. The amount of residual food was classified into 4 grades: grade 0, no residual food; grade 1, a small amount of residual food; grade 2, a moderate amount of residual food, but possible to observe the entire surface of the remnant stomach with body rolling; and grade 3, a large amount of residual food that hinders observation of the entire surface even with body rolling [12].



**Fig. 1.** Endoscopic botulinum toxin injection into the pylorus area. Botulinum toxin (25–50 IU per site; total, 100–200 IU) is injected into each quadrant of the pylorus area using a standard sclerotherapy needle via capped endoscopy.

## RESULTS

All patients' detailed clinical characteristics are shown in **Table 1**. Five patients who received botulinum toxin injection showed symptom improvements, particularly in tolerating soft solid or full diet within 10 days, i.e., the GOOSS score improved from 0 to 2 or 3 (**Table 2**). Upper gastrointestinal series and subsequent daily simple abdominal X-rays showed that pyloric spasm had improved, and gastric emptying was resolved (**Fig. 2**). One patient improved, i.e., able to ingest a soft fluid diet within 10 days, and was discharged. We confirmed the further improvement of his diet to a soft solid diet at the outpatient clinic 1 month after botulinum toxin injection.

Four patients also received prokinetics after botulinum toxin injection (erythromycin for 1 week in 1 patient, metoclopramide and corydaline for 2 weeks in 2 patients, and corydaline for 2 weeks in 1 patient).

**Table 1.** Clinical characteristics of the post-PPG patients who underwent intrapyloric botulinum toxin injection

No.	Sex	Age (yr)	BMI (kg/m <sup>2</sup> )	Operation	Location of tumor	Size of tumor (cm)	TNM stage	LN dissection
1	F	51	23.0	LAPPG	LB/LC	1.0×1.0	T1bNOM0	D1+
2	M	64	23.9	RAPPG	LB/LC	2.2×0.8	T1bNOM0	D1+
3	M	70	23.8	LAPPG	Antrum/GC	4.0×3.0	T1bNOM0	D1+
4	F	78	22.2	LAPPG	LB/PW	3.2×2.1	T1bNOM0	D1+
5	M	62	21.1	LAPPG	LB/LC	8.8×4.7	T1bNOM0	D1+
					LB/LC	0.8×0.4	T1bNOM0	
6	M	52	24.5	LAPPG	LB/AW	1.2×1.0	T1aNOM0	D1+

PPG = pylorus-preserving gastrectomy; BMI = body mass index; TNM = tumor, node, and metastasis; LN = lymph node; F = female; M = male; LAPPG = laparoscopic-assisted pylorus-preserving gastrectomy; RAPPG = robotic-assisted pylorus-preserving gastrectomy; LB = lower body; GC = greater curvature; LC = lesser curvature; AW = anterior wall side; PW = posterior wall side.

Botulinum Toxin for Gastric Stasis after PPG

Table 2. Outcomes of the intrapyloric botulinum toxin injection

No.	Period (from operation to botulinum toxin injection; day)	Improvement						No. of procedures
		GOOSS score* (post-procedure day)			Endoscopic food grade† (post-procedure day)			
		Pre	→	Post-10 days	Pre	→	Post	
1‡	22	0	→	2	3	→	2	1
2	16	0	→	2	3	→	0	1
3	33	2	→	3	3	→	1	5
4	29	0	→	1	3	→	3	1
5§	20	1	→	2	3	→	3	2
6	32	2	→	3	3	→	2	1

GOOSS = Gastric Outlet Obstruction Scoring System.

\*GOOSS: 0) no oral intake; 1) only liquid diet; 2) soft solid diet; and 3) low residue or full diet; †Endoscopic food grade: 0) no residual food; 1) a small amount of residual food; 2) a moderate amount of residual food, but possible to observe the entire surface of the remnant stomach with body rolling; and 3) a large amount of residual food that hinders observation of the entire surface even with body rolling. Post-procedure endoscopy is performed at a median of 38 days after the botulinum toxin injection (range, 6–148 days); ‡Balloon pyloroplasty is performed before botulinum toxin injection, which does not improve the symptoms; §Mild anastomosis site stricture is observed.

All patients underwent follow-up esophagogastroduodenoscopy at a median of 38 days after botulinum toxin injection (range, 6–148 days). The endoscopic remnant food grade of all 6 patients was 3 (a large amount) before the procedure, and 4 patients showed improvements in the endoscopic food grade from 0 (no residual food) to 2 (a moderate amount).

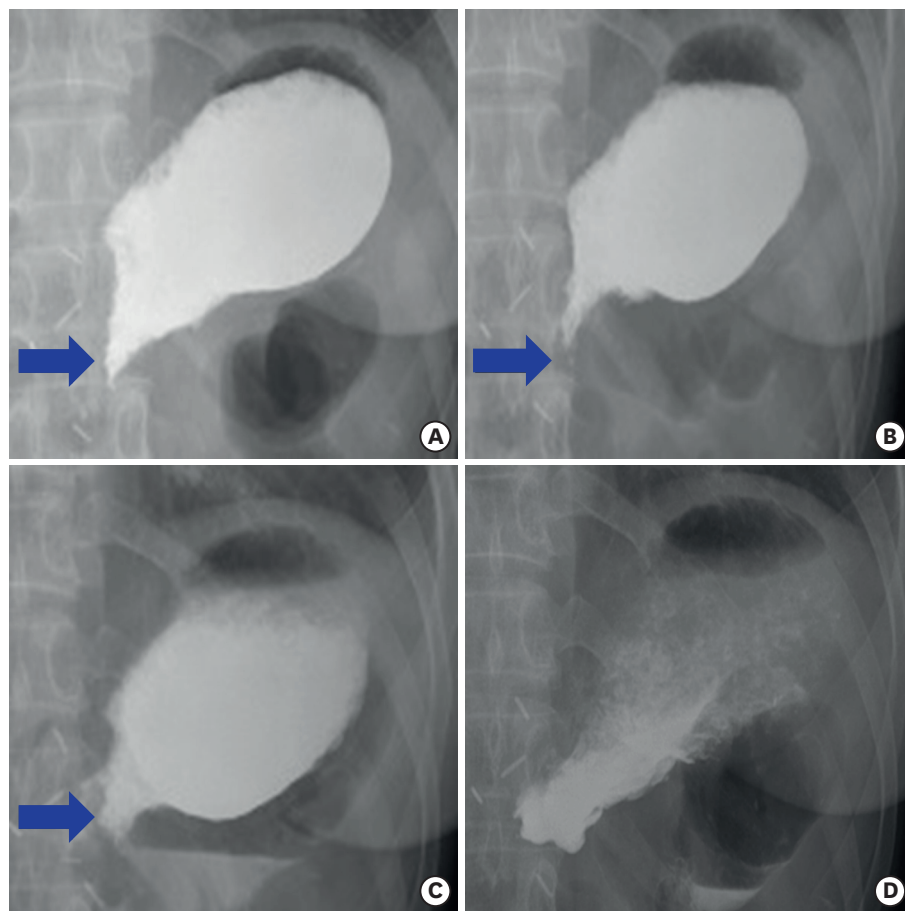


Fig. 2. Upper gastrointestinal series and follow-up simple X-ray after botulinum toxin injection. (A) Pre-injection, (B) 2 days post-injection, (C) 4 days post-injection, and (D) 7 days post-injection. The nearly closed pylorus gradually opened (blue arrow), and the residual food in the stomach decreased after botulinum toxin injection. After 1 week, the pylorus widely opened, and the residual food emptied.

There were no immediate or delayed complications attributable to botulinum toxin injection. Two patients received additional botulinum toxin injections. One patient underwent one additional procedure due to a recurrence of symptoms, such as nausea and vomiting 5 months after the first botulinum toxin injection. The other patient showed little (grade 1) to no residual remnant food in 6 monthly endoscopic examinations after botulinum toxin injection; however, he strongly desired to receive repeated botulinum toxin injection due to indigestion recurrence at 6 months after each botulinum toxin injection. After a total of 5 botulinum toxin injections, he did not need further treatment.

The patients' median follow-up period was 27 months (range, 14.8–36.1 months). All patients were able to ingest normal regular diets at the last follow-up.

## DISCUSSION

We have successfully managed postoperative delayed gastric emptying using botulinum toxin injection following PPG. The GOOSS score improved in all patients, and 5 of them were able to consume a soft solid diet within 10 days after the procedure. To our knowledge, this study is the first to report the use of botulinum toxin to alleviate delayed gastric emptying after PPG.

In refractory gastroparesis caused by diabetes and surgery and of unknown origin, the mean duration of botulinum toxin response was 5.1 months [7]. The duration of botulinum toxin effect (5–6 months) seems to be a sufficient time for the recovery of gastric emptying in most PPG patients. In an animal study, gastric stasis improved 1 month after resection of the pyloric branch of the canine vagus nerve, and the rate of gastric emptying after 1 month was similar to that of controls [5]. Humans may need a longer period for gastric emptying restoration compared to dogs [13]. Two patients required reinjection after 6 months from the first treatment, and both of their conditions improved again after botulinum toxin reinjection.

Recently, balloon dilation and/or retrievable stent insertion into the pylorus have been introduced for the treatment of patients with gastric stasis after PPG [14]. Overall, 73.3% of cases showed a good response to balloon dilation, and non-responders to balloon dilation were subsequently treated by a retrievable stent. However, balloon dilation or stent insertion frequently results in damages to the pyloric sphincter. Transmural tearing can develop with balloon dilation or stent insertion. Transmural tearing of the pylorus or pyloroplasty after PPG runs counter to the purpose of PPG, which is implemented to preserve the pylorus in contrast with subtotal gastrectomy. Moreover, patients require admission to the hospital for balloon dilation or stent insertion.

Botulinum toxin injection for the treatment of pyloric spasm has several advantages compared with balloon dilation and stenting. This procedure does not require fluoroscopic guidance. This procedure is easy and safe; thus, hospital admission for the procedure is not essential. Among a total of 11 sessions of botulinum toxin injections, 6 sessions were performed at outpatient clinics, and no complications developed after any session. A major advantage of botulinum toxin injection is that it does not damage the pyloric sphincter and permits time for natural recovery. Balloon dilation or stent insertion could be attempted if there is no improvement of symptoms with botulinum toxin injection.

Our study has several limitations. First, only 6 cases were enrolled. Therefore, it is difficult to evaluate the general efficacy of botulinum toxin injection in patients with delayed gastric emptying after PPG. In the future, a prospective study including a larger number of patients is needed to evaluate the efficacy of botulinum toxin. Second, the effect of botulinum toxin injection on gastric stasis was evaluated semi-quantitatively, based on the improvement of symptoms, diet grade, and endoscopic findings. A gastric emptying study as an objective evaluation method was not conducted. However, a gastric emptying study also lacks standardization to evaluate gastric emptying.

In summary, this study is the first to report the successful outcome of botulinum toxin injection in patients with delayed gastric emptying following PPG. We found that this technique could be an easier and more effective method than previous therapeutic trials. Further prospective studies are needed to determine the role of this treatment in patient management.

## REFERENCES

1. Bollschweiler E, Berth F, Baltin C, Mönig S, Hölscher AH. Treatment of early gastric cancer in the Western World. *World J Gastroenterol* 2014;20:5672-5678.  
[PUBMED](#) | [CROSSREF](#)
2. Oh SY, Lee HJ, Yang HK. Pylorus-preserving gastrectomy for gastric cancer. *J Gastric Cancer* 2016;16:63-71.  
[PUBMED](#) | [CROSSREF](#)
3. Jiang X, Hiki N, Nunobe S, Fukunaga T, Kumagai K, Nohara K, et al. Postoperative outcomes and complications after laparoscopy-assisted pylorus-preserving gastrectomy for early gastric cancer. *Ann Surg* 2011;253:928-933.  
[PUBMED](#) | [CROSSREF](#)
4. Suh YS, Han DS, Kong SH, Kwon S, Shin CI, Kim WH, et al. Laparoscopy-assisted pylorus-preserving gastrectomy is better than laparoscopy-assisted distal gastrectomy for middle-third early gastric cancer. *Ann Surg* 2014;259:485-493.  
[PUBMED](#) | [CROSSREF](#)
5. Nakabayashi T, Mochiki E, Garcia M, Haga N, Suzuki T, Asao T, et al. Pyloric motility after pylorus-preserving gastrectomy with or without the pyloric branch of the vagus nerve. *World J Surg* 2002;26:577-583.  
[PUBMED](#) | [CROSSREF](#)
6. Cerfolio RJ, Bryant AS, Canon CL, Dhawan R, Eloubeidi MA. Is botulinum toxin injection of the pylorus during Ivor Lewis [corrected] esophagogastrectomy the optimal drainage strategy? *J Thorac Cardiovasc Surg* 2009;137:565-572.  
[PUBMED](#) | [CROSSREF](#)
7. Bromer MQ, Friedenber F, Miller LS, Fisher RS, Swartz K, Parkman HP. Endoscopic pyloric injection of botulinum toxin A for the treatment of refractory gastroparesis. *Gastrointest Endosc* 2005;61:833-839.  
[PUBMED](#) | [CROSSREF](#)
8. Storr M, Allescher HD, Rösch T, Born P, Weigert N, Classen M. Treatment of symptomatic diffuse esophageal spasm by endoscopic injection of botulinum toxin: a prospective study with long term follow-up. *Gastrointest Endosc* 2001;54:18A.  
[PUBMED](#) | [CROSSREF](#)
9. Kolbasnik J, Waterfall WE, Fachnie B, Chen Y, Tougas G. Long-term efficacy of botulinum toxin in classical achalasia: a prospective study. *Am J Gastroenterol* 1999;94:3434-3439.  
[PUBMED](#) | [CROSSREF](#)
10. Adler DG, Baron TH. Endoscopic palliation of malignant gastric outlet obstruction using self-expanding metal stents: experience in 36 patients. *Am J Gastroenterol* 2002;97:72-78.  
[PUBMED](#) | [CROSSREF](#)
11. Kim CG, Choi IJ, Lee JY, Cho SJ, Park SR, Lee JH, et al. Covered versus uncovered self-expandable metallic stents for palliation of malignant pyloric obstruction in gastric cancer patients: a randomized, prospective study. *Gastrointest Endosc* 2010;72:25-32.  
[PUBMED](#) | [CROSSREF](#)

12. Kubo M, Sasako M, Gotoda T, Ono H, Fujishiro M, Saito D, et al. Endoscopic evaluation of the remnant stomach after gastrectomy: proposal for a new classification. *Gastric Cancer* 2002;5:83-89.  
[PUBMED](#) | [CROSSREF](#)
13. Jung HJ, Lee JH, Ryu KW, Lee JY, Kim CG, Choi IJ, et al. The influence of reconstruction methods on food retention phenomenon in the remnant stomach after a subtotal gastrectomy. *J Surg Oncol* 2008;98:11-14.  
[PUBMED](#) | [CROSSREF](#)
14. Bae JS, Kim SH, Shin CI, Joo I, Yoon JH, Lee HJ, et al. Efficacy of gastric balloon dilatation and/or retrievable stent insertion for pyloric spasms after pylorus-preserving gastrectomy: retrospective analysis. *PLoS One* 2015;10:e0144470.  
[PUBMED](#) | [CROSSREF](#)