

Case report

Open Access

## Spontaneous pneumothorax as a first sign of pulmonary carcinoma

Vladislavas Vencevičius\*<sup>1</sup> and Saulius Cicėnas<sup>1,2</sup>

Address: <sup>1</sup>Department of Thoracic Surgery and Oncology, Institute of Oncology, Vilnius University, Santariškių 1, Vilnius, Lithuania and <sup>2</sup>Vilnius University, Medical Faculty, Institute of Rehabilitation, Sport Medicine and Nursing, Vilnius, Lithuania

Email: Vladislavas Vencevičius\* - v.vencevicius@gmail.com; Saulius Cicėnas - saulius.cicenas@vuoi.lt

\* Corresponding author

Published: 30 June 2009

Received: 27 March 2009

World Journal of Surgical Oncology 2009, 7:57 doi:10.1186/1477-7819-7-57

Accepted: 30 June 2009

This article is available from: <http://www.wjso.com/content/7/1/57>

© 2009 Vencevičius and Cicėnas; licensee BioMed Central Ltd.

This is an Open Access article distributed under the terms of the Creative Commons Attribution License (<http://creativecommons.org/licenses/by/2.0>), which permits unrestricted use, distribution, and reproduction in any medium, provided the original work is properly cited.

### Abstract

**Background:** Spontaneous pneumothorax (SP) is a rare manifestation of lung cancer. The mechanisms by which pneumothorax occurs in lung cancer is not clear, resulting in different views being expressed.

**Case presentation:** Here we present a case in which pneumothorax occurred as a first manifestation of lung cancer. The chest x-ray of a 68 year old man revealed a right partial pneumothorax. VATS was then performed: the visceral pleura lying over segment S<sub>3</sub> was destroyed and air leaks were found in this section. Pathologic examination of the biopsy specimen revealed non-small cell carcinoma. Thoracoscopic talc pleurodesis was performed.

**Conclusion:** Spontaneous pneumothorax in association with lung cancer is rarely seen. Pneumothorax can be the first sign of lung cancer. The most common possibility for SP complicating lung cancer is the tumor necrosis mechanism or, in separate cases, rupture of the emphysematous bullae. Lung cancer should always be considered as a possible cause of SP in elderly patients or in heavy smokers.

### Background

SP is generally attributed to a rupture of the sub-pleural blebs or emphysematous bullae [1]. This can complicate primary or secondary lung tumors. SP in primary pulmonary neoplasm or lung metastasis is very rare and the estimated rate of joint occurrence is approximated to be between 0,03 and 0,05 percent for primary lung cancer [1-5]. Pneumothorax due to primary lung cancer is also rare and prognosis is poor because most often the cancer is either at an advanced stage or the diagnosis of cancer was delayed [1,5].

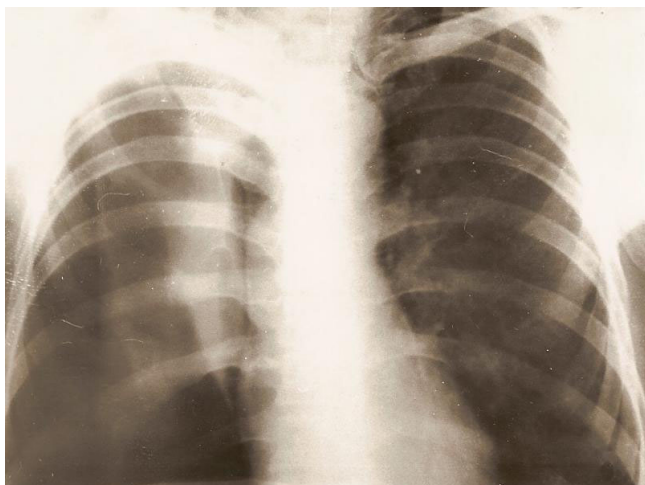
### Case presentation

A 68 year old man was admitted in September 2007 with complaints of chest pain, dyspnea and cough in the past 6

days. He was a heavy smoker. Physical examination revealed tachycardia and tympanic percussion over the right chest, dullness with decreased breath sounds over the right lower chest. His chest radiograph of the thorax showed a lesion in the upper zone of the right lung and partial pneumothorax (Figures 1, 2).

Routine investigations revealed Hb: 8%, TLC: 9700/cumm, DLC: P62 L 38 cumin and ERS 20 mm in the first hour. Blood urea and sugar, etc. were normal. Direct smear examination of the sputum was negative for acid fast bacilli as well as malignant cells.

Primary lung carcinoma was suspected. Thorascopy (VATS) was performed: the visceral pleura lying over seg-



**Figure 1**  
**Right spontaneous pneumothorax VATS: right S<sub>3</sub> segment granulations in centrally visceral pleura defect. Biopsy: squamous cell cancer.**

ment S<sub>3</sub> was destroyed and air leaks were found in this section. Histological examination of the biopsy specimen (S<sub>3</sub>) revealed non-small cell cancer (Figure 3). When bronchoscopy was performed, compression invasion of the right upper lobe bronchus was noted, but histological examination of the bronchoscopic biopsy specimen was negative (T2 b N0 M 0 stage II A).

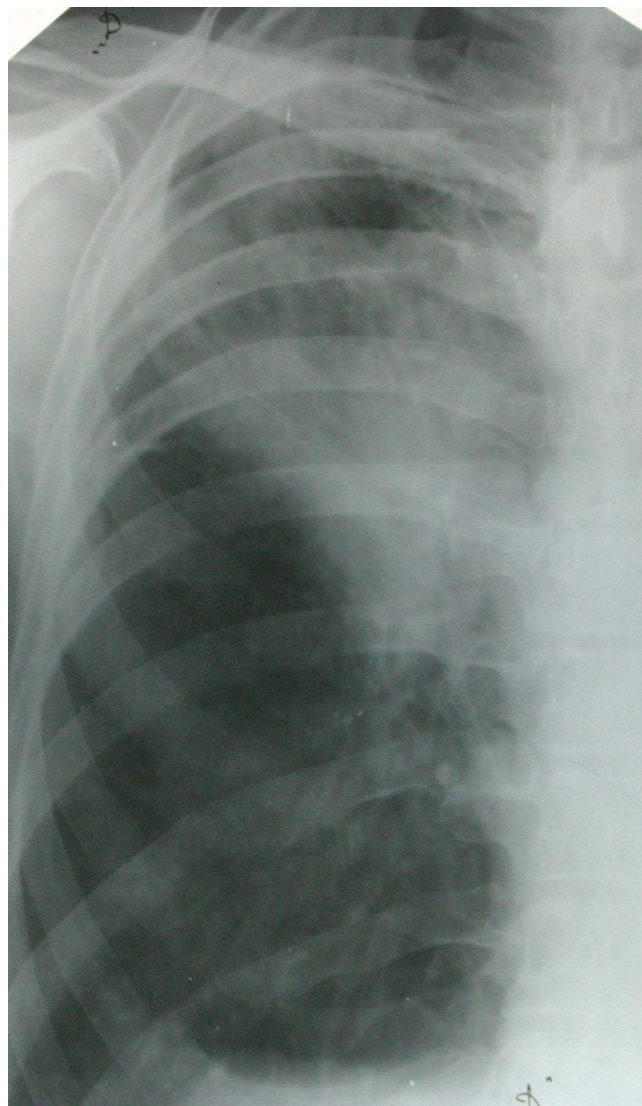
Thoracoscopic talc pleurodesis was performed. Chest drains were removed after 6 days. Because the patient refused surgery, he then received chemotherapy.

**Discussion**

Spontaneous pneumothorax is divided into primary and secondary. Primary SP most commonly afflicts the young and healthy. The secondary type can develop with obstruction, infection, infarction, neoplasm and diffuse lung disease.

SP as a complication of primary lung carcinoma (LC) is rare [6,7]. It is estimated that only 2% of all SP is coexistent with malignant lung diseases, either primary or secondary. This tumor complication must be especially considered in older patients [8].

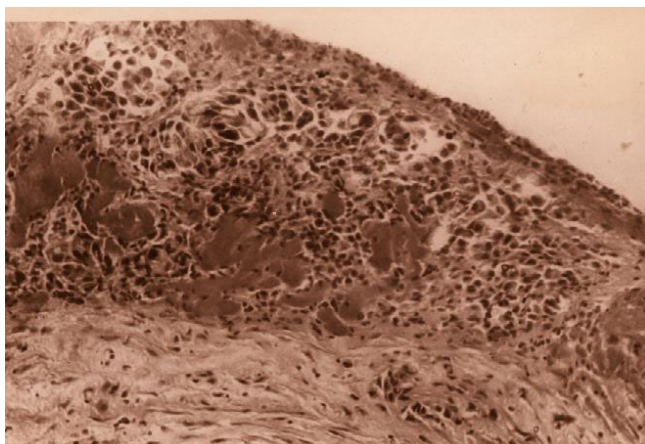
To date, among the 1200 adults who were found to have SP from 1970–2007, 37 (3%) had lung cancer. In all such patients, the pneumothorax occurred in the same side as the carcinoma. The main cause of SP was the rupture of a necrotic tumor nodule or necrosis of subpleural metastases (for 21 patients). It also became the communication cause between the bronchus and pleural cavity, producing a bronchopleural fistula that resulted in pneumothorax.



**Figure 2**  
**Picture shows: after active pleural drainage – lung expanded. Right upper lobe: non homogenic infiltration – tumour.**

We demonstrate that these case reports of lung cancer with pneumothorax are a rare complication of primary lung carcinoma.

The mechanism producing pneumothorax from lung cancer is not well understood, but a number of theories have been advanced. The first is that it may be the result of tumor necrosis – rupture of the necrotic neoplastic tissue in the pleural cavity [9]; the second, that it may be caused by the rupture of the necrotic tumor nodule or necrosis of subpleural metastases [5]. A third is cancer of the check valve mechanism: the tumor at the lung periphery can obstruct bronchioles and lead to local overdistention and



**Figure 3**  
Microview of biopsy specimen H & E stain, × 20  
Tumor cells.

rupture of the lung [10]. The fourth is that most patients with lung cancer have chronic bronchitis or emphysema bullae and these bullae may rupture following the disturbance of the lung architecture due to bronchial cancer [11].

Pneumothorax related to therapy has been reported in patients receiving chemotherapy and/or radiotherapy for lung cancer [12]. There is the possibility that SP and lung cancer are two independent and incidental processes. These theories suggest that lung cancer should always be considered as a possible cause of SP in older patients [13].

### Conclusion

Spontaneous pneumothorax in association with lung cancer is rarely seen. Pneumothorax can be the first sign of lung cancer. The most common possibility for SP complicating lung cancer is the tumour necrosis mechanism or, in separate cases, rupture of the emphysematous bullae. Lung cancer should always be considered as a possible cause of SP in elderly patients or in heavy smokers.

### Consent

Written informed consent was obtained from the patient for publication of this case presentation and accompanying images. A copy of the written consent is available for review by the Editor-in-Chief of this journal.

### Competing interests

The authors declare that they have no competing interests.

### Authors' contributions

VV wrote the manuscript, sent the specimen to the pathologist, prepared the material for publication and operated the patients. SC collected data on a number of patients,

operated on them, treated them and used diagnosis methods.

### References

- Bauman MH, Noppen M: **Pneumothorax**. *Respirology* 2004, **9**:157-164.
- Sahn SA, Heffner JE: **Spontaneous pneumothorax**. *N Engl J Med* 2000, **342**:868-874.
- Takashi I, Kiyotoshi I, Ryuhei M, Takuma T, Masaya Y, Shigefumi S: **Acute nonbacterial pleuritis caused by spontaneous rupture of metastatic pulmonary adenocarcinoma**. *Gen Thorac* 2008, **56**:347-350.
- Smevik B, Klepp O: **The risk of spontaneous pneumothorax in patients with osteogenic sarcoma and testicular cancer**. *Cancer*. 1982, **49**(8):1734-1737.
- Steinhäuslin CA, Cuttat JF: **Spontaneous pneumothorax. A complications of lung cancer**. *Ann Thorac Surg* 2005, **79**:716.
- Galbis CJM, Mafé MJJ, Baschwitz GB, Pérez CA, Rodríguez PJM: **Spontaneous pneumothorax as the first sign of pulmonary carcinoma**. *Arch Bronconeumol* 2001, **37**(9):397-400.
- O'Connor BM, Ziegler P, Spaulding MB: **Spontaneous pneumothorax in small cell lung cancer**. *Chest* 1992, **102**(2):628-629.
- Pohl D, Herse B, Crieé CP, Dalichau H: **Spontaneous pneumothorax as the initial symptom of bronchial cancer**. *Pneumologie* 1993, **47**(2):69-72.
- Tsukamoto T, Satoh T, Yamada K, Nagasawa M: **Primary lung cancer presenting as spontaneous pneumothorax**. *Nihon Kyobu Shikkan Gakkai Zasshi* 1995, **33**(9):936-939.
- Yeung KY, Bonnet JD: **Bronchogenic carcinoma presenting as spontaneous pneumothorax. Case report with review of literature**. *Cancer* 1977, **39**(5):2286-2289.
- Okada D, Koizumi K, Haraguchi S, Kawamoto M, Mikami I, Tanaka S: **Pneumothorax manifesting primary lung cancer**. *J Thorac Cardiovasc Surg*. 2002, **50**(3):133-136.
- Nishioka M, Fukuoka M, Nakagawa K, Matsui K, Nakajima T: **Spontaneous pneumothorax following partial resolution of total bronchial obstruction**. *Chest* 1993, **104**(1):160-163.
- Minami H, Sakai S, Watanabe A, Shimokata K: **Check-valve mechanism as a cause of bilateral spontaneous pneumothorax complicating bronchioloalveolar cell carcinoma**. *Chest* 1991, **100**(3):853-855.

Publish with **BioMed Central** and every scientist can read your work free of charge

"BioMed Central will be the most significant development for disseminating the results of biomedical research in our lifetime."

Sir Paul Nurse, Cancer Research UK

Your research papers will be:

- available free of charge to the entire biomedical community
- peer reviewed and published immediately upon acceptance
- cited in PubMed and archived on PubMed Central
- yours — you keep the copyright

Submit your manuscript here:  
[http://www.biomedcentral.com/info/publishing\\_adv.asp](http://www.biomedcentral.com/info/publishing_adv.asp)

