

Posterior open occlusion management by registration of overlay removable partial denture: A clinical report

Saeid Nosouhian, Amin Davoudi¹, Mohammad Derhami²

Dental Implants Research Center and Department of Prosthodontics, School of Dentistry, ¹Dental Students Research Center, School of Dentistry, ²Department of Prosthodontics, Faculty of Dentistry, Mashhad University, Mashhad, Iran

Abstract

This clinical report describes prosthetic rehabilitation of posterior open bite relationship in a patient with several missing teeth and skeletal Class III malocclusion. Primary diagnostic esthetic evaluations were performed by mounting casts in centric relation and estimating lost vertical dimension of occlusion. Exclusive treatments were designated by applying overlay removable partial denture with external attachment systems for higher retentions.

Key Words: Oral rehabilitation, overlay removable partial denture, retention, vertical dimension

Address for correspondence:

Dr. Amin Davoudi, Dental Students Research Center, School of Dentistry, Hezarjarib Street, Isfahan, Iran.

E-mail: Amindvi@yahoo.com

Received: 31th March, 2015, **Accepted:** 13th June, 2015

INTRODUCTION

Posterior open bite is defined as the lack of occlusal contact in posterior teeth in any occluding position of the anterior teeth. This condition might occur bilaterally; however, unilateral manifestation is more frequent.^[1]

Some factors have been related in presence of this condition such as: Primary failure of eruption; hypothyroidism and hypopituitarism; ankylosis of teeth; condylar trauma; cleidocranial dysplasia; mechanical obstruction by the fingers, tongue, or cheeks and etc.^[2]

Several missing or lost teeth are the other factors that might cause distal rotation, the intrusion of posterior teeth, and retraction of anterior teeth.^[2]

In spite of many remarkable achievements and success rates in implant science, preservation of natural teeth or their roots are recommended to postpone future edentulism of a patient.^[3]

Posterior open bite relationships can be managed in several methods depending on their severity and diagnosis. The safety of permanent rehabilitating of vertical dimension loss is proposed, but some probable signs and symptoms may be encountered which have an interim nature.^[4]

Overlay removable partial denture (ORPD) is a prosthesis that covers and rests on natural teeth or roots of them^[5] to enhance the vertical dimension loss. The other option

Access this article online	
Quick Response Code:	Website: www.j-ips.org
	DOI: 10.4103/0972-4052.171822

This is an open access article distributed under the terms of the Creative Commons Attribution-NonCommercial-ShareAlike 3.0 License, which allows others to remix, tweak, and build upon the work non-commercially, as long as the author is credited and the new creations are licensed under the identical terms.

For reprints contact: reprints@medknow.com

How to cite this article: Nosouhian S, Davoudi A, Derhami M. Posterior open occlusion management by registration of overlay removable partial denture: A clinical report. J Indian Prosthodont Soc 2015;15:386-9.

is orthodontic treatment in combination with segmental osteotomy.

This clinical report represents a patient with bilateral posterior open bite relationship who was treated with maxillary and mandibular ORPDs.

CASE REPORT

Interviewing and diagnoses

A 38-year-old man referred to the prosthodontics department of Mashhad Dental Faculty, Mashhad University of Medical Sciences, Iran. After profiling personal information, medical, and dental history were recorded. No systemic problem was indicated, and his chief complaint was about inconvenient and insufficient quality of chewing.

Extra oral evaluations revealed no facial asymmetry with normal muscle tonicity, no signs of temporomandibular joint (TMJ) disorders, no lymph node enlargement, and no myofascial pain.

Intraoral examinations showed following findings [Figure 1]

Bilateral posterior open bite; Class III skeletal modification with severe loss of occlusal vertical dimension (VDO); maxillary Kennedy Class III, modification II, and mandibular

Class II, modification I; poor oral hygiene but with normal mucosa; loss of several teeth (number 18, 16, 14, 13, 22, 24, 25, 26, 28, 38, 37, 36, 46, 47, and 48); previous endodontic treated teeth (number 34 and 35) and several cavitated teeth.

Before preparing diagnostic casts, he was informed about the procedures and his consent was obtained. Hence, maxillary and mandibular impressions were made with alginate (Super

Golchai, Tehran, Iran) by using custom trays. A semi-adjustable articulator (Dentatus, New York, USA) were registered, and adjusted in 15° for the Bennett angle and 30° for the path of condylar angle. The maxillary cast was mounted by using face-bow record. The mandibular cast was mounted in centric relation (CR) to the maxillary cast by using a silicone-based interocclusal CR record (Speedex, Coltene, Swiss) which was obtained by bilateral manipulation technique from the patient in CR.

The vertical dimension at rest (VDR) was obtained by marking two reference points on the patient's nose and chin. The patient was asked to swallow several times and then relax his jaws. Then phonetic pronunciation was tested, and the distance between the references was measured.

Vertical dimension loss was recorded 16 mm for the right side and 18 mm for the left side.

Preliminary treatments

Based on diagnostic data and patient's willing to choose ORPD instead of orthognathic surgery, the essential teeth for prosthodontics rehabilitation were remarked and following treatment plans were administered.

Oral health instruction and overall periodontal scaling; endodontic therapy for tooth number 12, 11, 21, 23, 27, and 45; also, restorative filling for tooth number 17, 15, 33, 31, and 42.

Special treatments

After initial treatment plan, following exclusive treatments were considered [Figure 2]

- Casting posts and copings for maxillary right lateral and both central incisors [Figure 2a and b]; The root canal

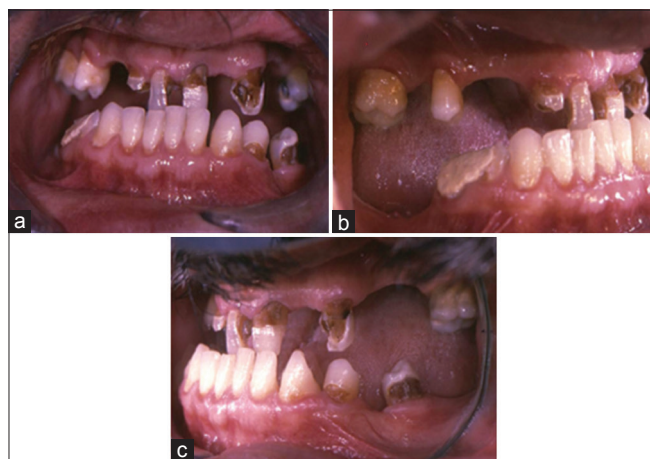

Figure 1: Intraoral examinations of patient in frontal (a), right side (b), and left side views (c)

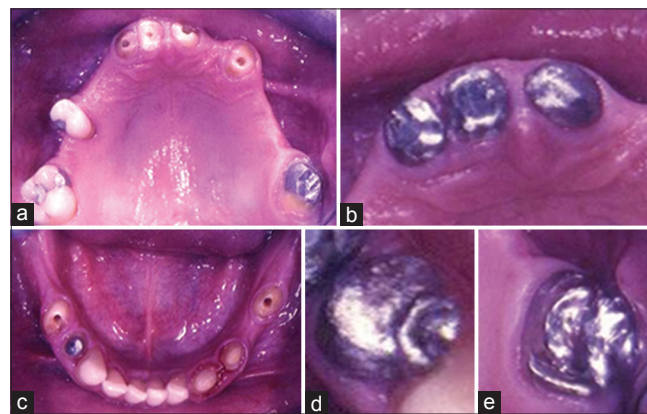


Figure 2: Overall oral preparation for initiating procedure of fabricating overlay removable partial denture. Preparing maxillary arch for posts and copings (a and b); preparing mandibular arch for post core crowns and ball attachments (c); rest seat on mesial site of crowns (d); and a ledge for adaptation of clasp (e)

was expelled from gutta-percha by using pesoreamers (Largo peso reamer, Dentsply Maillefer, Ballaigues, Switzerland) based on prior radiograph assessments. Duralay acrylic resin (Reliance Dental Mfg. Co., Alsip, USA) was manipulated based on manufacturer instruction. Loose consistency of acryl was driven to the canal by using a sprue (Pinjet, Angelus, Londoria, Brazil) to fabricate direct pattern of the canal. The provided patterns with their copings were casted with base metal alloy (VeraBond, Fairfield, CA). These copings were planned to enhance retention for final ORPD

- A post core crown for the first right lower premolar [Figure 2c]: The canal preparation and casting procedure were the same as a previous treatment but with core and crown preparation
- Ball attachments for both mandibular second premolars and maxillary left canine [Figure 2c]: After appropriate root canal preparation for each tooth, single sphere castable ball attachments (OT Cap, Zago, Bologna) with 2.5 mm diameter casted with acrylic post patterns together by base metal alloy. The role of these ball attachments was providing valuable retention for ORPD especially for the mandible
- Full metal-ceramic crowns for the maxillary left second molar and left mandibular canine: The teeth were milled by using high-speed carbide burs (Teeskavan, Tehran, Iran) based on conventional chamfer and shoulder finishing lines. After obtaining stone casts (type IV) (Vel mix, Gildund, Germany), crowns were waxed up by using Inlay blue wax (Renfert GmbH, Hilzingen, Germany) and surveyor (Seashin, Daegu, Korea) with rest seats on the mesial site of the required teeth [Figure 2d] plus cingolom rest for the canine. A ledge was carved on the buccal of maxillary molar [Figure 2e] for the adaptation of retentive and reciprocal arms of casted clasp. The casting procedure was accomplished by Ni-Cr alloy (Sankin, nonberyllium, Dentsply, Japan) and porcelain (VMC, VITA, Zahnfabrick, Badsackingen, Germany) by following conventional methods
- Meantime, interim ORPDs [Figure 3] were fabricated on the casts by using autopolymerized acrylic resins (Acropars-Marlic, Tehran, Iran) with wrought wire clasps on mandibular left first premolar and right canine plus maxillary second molars. The interim ORPDs were applied for 4 months for providing esthetic and VDO adoptability for the patient. During this period, the patient's condition and functions such as muscle tenderness, discomfort of TMJ, mastication, range of the motions, swallowing, and speech were evaluated. The anterior guidance and posterior disclusion on excursive movement were established. Adjusted occlusion was

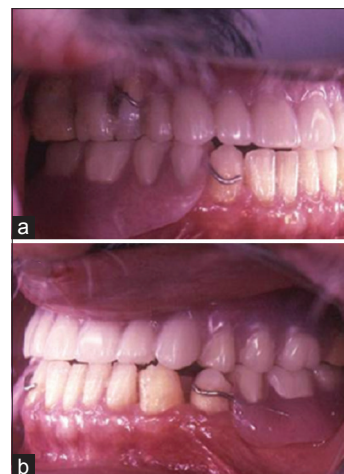


Figure 3: Interim overlay removable partial dentures for providing esthetic and function. Left (a) and right views (b)

transferred to customized anterior guide table, which was made with acrylic resin.

Preparing final overlay removable partial dentures

After cementation of posts and crowns with zinc phosphate (Harvard, Berlin, Germany) as a permanent luting agent, special trays were fabricated for both jaws, and definitive impressions were made by using additional silicones (Soft Panasil, Kettenbach, Germany). Impressions were poured with type III dental stone (Pars Dandan, Tehran, Iran). The resultant master casts were duplicated to gain refractory cast (Neiryck and Vogt, Schelle, Belgium).

The ORPD patterns were waxed on the refractory casts, and the frameworks were cast with Co-Cr alloy (Cobaltan, Shofu, Kyoto, Japan). The design for the final mandibular overlay framework consisted of the lingual plate major connector with mesial rests on first premolars and cingolom rest on the left canine. Furthermore, the space for ball attachments (Patrx housings) was anticipated. The design for maxillary framework included an anterior-posterior palatal strap with occlusal coverage of the remained tooth and space for ball attachments (Patrx housings). Furthermore, Aker clasps were waxed up for second molars and right second premolar.

The frameworks with wax and compound record base (Kerr, Salerno, Italy) were tried in the patient's mouth, and the maxillomandibular relation was recorded with the help of face-bow in CR.

The patient was asked to close into CR while the maxillary and mandibular interim ORPD were in place. The phonetic pronunciation and other mentioned tests were done during recording reconstructed VDO. This measurement should coincide with a previous record, which was without interim

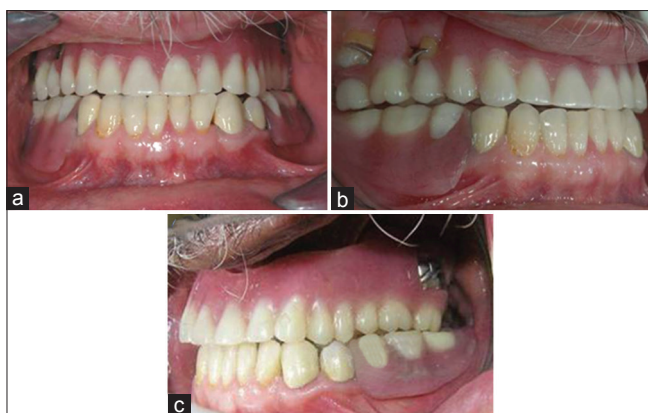

Figure 4: Final finished and polished overlay removable partial dentures (a) and during latrusive movements (b and c)

ORPD. The existence of maxillary right second molar and premolar had a positive impact for providing precise CR record. The record transferred to the articulator, and the occlusal plane was aligned and adjusted. The acrylic tooth mounted in the modeling wax (Dentsply, Hoorn, England), and try-in dentures were formed. In the following visit, occlusal interferences were eliminated, and try-in dentures were delivered to the laboratory for final acrylic (Meliodent Multicryl, Heraeus-Kulzer, GmbH, Wehrheim, Germany) processing.

After deflasking ORPD, the occlusion was adjusted, and the prostheses were finished and polished. The maxillary and mandibular ORPDs were evaluated in patient's mouth with minor occlusal adjustments. Latrusive and protrusive movements were checked [Figure 4]. Finally, oral hygiene and home care instructions were given to the patient.

DISCUSSION

In this clinical report, enhancement of VDO was determined not only by standardized esthetic evaluations but also with patient's physiologic factors such as VDR and speech. If the increase of VDO were ordered arbitrarily without specific evaluation, multiple complications would be the consciences and longer treatment period might be needed.^[6]

Rehabilitation of partial dentition with lost VDO by using fixed or removable prostheses is complex and difficult to manage. Assessment of the VDO has a paramount role for providing a comprehensive treatment plan.^[7]

Depending on the patient's adaptation ability, the interim ORPD period can be modified. Furthermore, a careful monitoring may shorten the overall treatment duration.^[8]

Six months follow-up after ORPD delivery, patient's satisfaction was noticed. For improving esthetic modalities and retention, ball attachments were administered specially for the mandible.^[9] Patel and Bencharit tried ORPD in a patient with lost VDO. The final outcomes were delightful, and patient satisfaction was indicated, however, no attachment system was designated for that ORPDs.^[5] Attachment systems can distribute biting forces, eliminate trauma to abutments and soft tissues.^[9] It is stated that using ball attachment in combination with clasps would increase the survival rate of removable partial dentures dramatically.^[10] In this case, the retention was provided as much as possible by using clasps, predicting ball attachment and using post copings in the anterior region.

CONCLUSION

The vertical dimension rehabilitation by using ORPD is affordable for many patients,^[8] specially those who need orthognathic surgeries because of intraoral complications. Furthermore, designating attachment systems or other methods for increasing esthetic and retention is impressively recommended.

Financial support and sponsorship

Nil.

Conflict of interest

There are no conflict of interest.

REFERENCES

1. Proffit WR, Vig KW. Primary failure of eruption: A possible cause of posterior open-bite. *Am J Orthod* 1981;80:173-90.
2. Uribe F, Janakiraman N, Nanda R. Interdisciplinary approach for increasing the vertical dimension of occlusion in an adult patient with several missing teeth. *Am J Orthod Dentofacial Orthop* 2013;143:867-76.
3. Brewer AA, Morrow RM. *Overdentures*. 2nd ed. St. Louis: CV Mosby; 1980.
4. Jain AR, Nallaswamy D, Ariga P, Philip JM. Full mouth rehabilitation of a patient with reduced vertical dimension using multiple metal ceramic restorations. *Contemp Clin Dent* 2013;4:531-5.
5. Patel MB, Bencharit S. A treatment protocol for restoring occlusal vertical dimension using an overlay removable partial denture as an alternative to extensive fixed restorations: A clinical report. *Open Dent J* 2009;3:213-8.
6. Hempton TJ, Dominici JT. Contemporary crown-lengthening therapy: A review. *J Am Dent Assoc* 2010;141:647-55.
7. Song MY, Park JM, Park EJ. Full mouth rehabilitation of the patient with severely worn dentition: A case report. *J Adv Prosthodont* 2010;2:106-10.
8. Ganddini MR, Al-Mardini M, Graser GN, Almog D. Maxillary and mandibular overlay removable partial dentures for the restoration of worn teeth. *J Prosthet Dent* 2004;91:210-4.
9. Jayasree K, Bharathi M, Nag VD, Vinod B. Precision attachment: Retained overdenture. *J Indian Prosthodont Soc* 2012;12:59-62.
10. Owall B. Precision attachment-retained removable partial dentures: Part 2. Long-term study of ball attachments. *Int J Prosthodont* 1995;8:21-8.