

## REVIEW

# Total parathyroidectomy in a large cohort of cases with hyperparathyroidism associated with multiple endocrine neoplasia type 1: experience from a single academic center

Fabio Luiz de Menezes Montenegro,<sup>1</sup> Delmar Muniz Lourenço Junior,<sup>II</sup> Marcos Roberto Tavares,<sup>1</sup> Sergio Samir Arap,<sup>1</sup> Climerio Pereira Nascimento Junior,<sup>1</sup> Ledo Mazzei Massoni Neto,<sup>1</sup> André D'Alessandro,<sup>1</sup> Rodrigo Almeida Toledo,<sup>II</sup> Flávia Lima Coutinho,<sup>II</sup> Lenine Garcia Brandão,<sup>1</sup> Gilberto de Britto e Silva Filho,<sup>1</sup> Anói Castro Cordeiro,<sup>1</sup> Sergio Pereira Almeida Toledo<sup>II</sup>

<sup>1</sup>Hospital das Clínicas da Faculdade de Medicina da Universidade de São Paulo, Head and Neck Surgery Section, Department of Surgery, São Paulo/SP, Brazil.

<sup>II</sup>Hospital das Clínicas da Faculdade de Medicina da Universidade de São Paulo, Endocrine Genetics Unit, Endocrinology Division, São Paulo/SP, Brazil.

Most cases of sporadic primary hyperparathyroidism present disturbances in a single parathyroid gland and the surgery of choice is adenomectomy. Conversely, hyperparathyroidism associated with multiple endocrine neoplasia type 1 (hyperparathyroidism/multiple endocrine neoplasia type 1) is an asynchronous, asymmetrical multiglandular disease and it is surgically approached by either subtotal parathyroidectomy or total parathyroidectomy followed by parathyroid auto-implant to the forearm. In skilful hands, the efficacy of both approaches is similar and both should be complemented by prophylactic thymectomy. In a single academic center, 83 cases of hyperparathyroidism/multiple endocrine neoplasia type 1 were operated on from 1987 to 2010 and our first surgical choice was total parathyroidectomy followed by parathyroid auto-implant to the non-dominant forearm and, since 1997, associated transcervical thymectomy to prevent thymic carcinoid. Overall, 40% of patients were given calcium replacement (mean intake 1.6 g/day) during the first months after surgery, and this fell to 28% in patients with longer follow-up. These findings indicate that several months may be needed in order to achieve a proper secretion by the parathyroid auto-implant. Hyperparathyroidism recurrence was observed in up to 15% of cases several years after the initial surgery. Thus, long-term follow-up is recommended for such cases. We conclude that, despite a tendency to subtotal parathyroidectomy worldwide, total parathyroidectomy followed by parathyroid auto-implant is a valid surgical option to treat hyperparathyroidism/multiple endocrine neoplasia type 1. Larger comparative systematic studies are needed to define the best surgical approach to hyperparathyroidism/multiple endocrine neoplasia type 1.

**KEYWORDS:** Hyperparathyroidism; Parathyroidectomy; MEN1; Parathyroid glands; Parathyroid neoplasms; Hypercalcemia.

Montenegro FLM, Lourenço DM Jr, Tavares MR, Arap SS, Nascimento Jr CP, Massoni Neto LM, et al. Total parathyroidectomy in a large cohort of cases with hyperparathyroidism associated with multiple endocrine neoplasia type 1: experience from a single academic center. Clinics. 2012;67(51):131-139.

E-mail: fabiomonte@uol.com.br

Tel.: 55 11 2661 6425

## INTRODUCTION

Primary hyperparathyroidism (HPT) is highly prevalent in patients with multiple endocrine neoplasia type 1 (MEN1), and its penetrance is almost complete by the age of 40 years (1–7). HPT associated with MEN1 (HPT/MEN1) is an asynchronous, asymmetric multiglandular and multifocal disorder; the vast majority of cases are benign tumors

and represented by parathyroid hyperplasia or adenoma (8); it occurs equally in males and females, and it frequently occurs at ages under 30 years (1,2). Despite relatively mild elevations in serum parathormone (PTH) and total/ionized calcium usually seen in HPT/MEN1, there have been recent reports of early onset, and progressive, frequent, extensive and severe bone and renal complications (7,9)

In recent years, routine genetic screening performed in at-risk family members of index MEN1 cases has significantly increased the recognition rate of young asymptomatic patients presenting at early metabolic stages of HPT in our and other institutions (10,11). Furthermore, in recent decades, the clinical picture of sporadic or familial HPT has changed dramatically and most cases are more frequently recognized and diagnosed early, at asymptomatic stages (12,13).

**Copyright** © 2012 CLINICS – This is an Open Access article distributed under the terms of the Creative Commons Attribution Non-Commercial License (<http://creativecommons.org/licenses/by-nc/3.0/>) which permits unrestricted non-commercial use, distribution, and reproduction in any medium, provided the original work is properly cited.

No potential conflict of interest was reported.

## Medical non-surgical strategies

The medical treatment of HPT associated with MEN1 is still under investigation. The experience with cinacalcet in HPT is limited to few cases, and no long-term follow-ups of disease end-points are available, despite short-term (up to 24 weeks) reductions of calcium and PTH (14–16).

Also, the use of percutaneous ethanol injection in cases of HPT recurrence after subtotal parathyroidectomy in HPT/MEN1 patients resulted in short-term eucalcemia. However, hypercalcemia recurred in 90% of cases after 32 months of therapy (17).

Furthermore, high-intensity focused ultrasound applied to sporadic, uniglandular HPT is under investigation, although temporary palsy of the recurrent laryngeal nerve in one out of four cases has been reported. Recovery was noted only 40 days after therapy (18), and the role of high-intensity focused ultrasound in multiglandular parathyroid disease is yet to be defined.

Long-term annual clinical follow-up has been recommended for selected sporadic cases of HPT, because bone mineral density may remain stable up to 10 years after diagnosis (19,20). To date, it is not clear whether this recommendation can be extended to HPT/MEN1.

## Surgical treatment

Surgery is the classic therapy for primary HPT in MEN1. However, the criteria to indicate parathyroidectomy in these cases remain under debate. The International Consortium/National Institutes of Health Consensus on MENs (1) recommended that indications for parathyroidectomy in MEN1 should follow the same criteria used for sporadic asymptomatic primary HPT (21,22).

Most HPT/MEN1 patients are younger than 50 years at diagnosis, and thus fulfill the indication for parathyroid surgery based solely on this criterion. However, it may not be easy to convince an asymptomatic patient that he/she will benefit from an operation that can be considered palliative, as recurrence rates are usually high (23). In some young asymptomatic cases, the treatment may be perceived as worse than the disease itself (24).

## Surgery in HPT/MEN1

The surgical treatment of HPT/MEN1 is a challenge to the surgeon for several reasons. First, in the vast majority of cases, HPT/MEN1 is a multiglandular disease that usually occurs asymmetrically and asynchronously. Second, the frequency of supernumerary parathyroid glands is considerable. Furthermore, the surgeon is frequently confronted with parathyroid glands with macroscopic features resembling normal characteristics and he/she must decide how much tissue should be taken, evaluating the risk for permanent hypoparathyroidism versus disease persistence or early recurrence. One parathyroid gland may appear normal macroscopically, but may cause persistent hypercalcemia (24). Finally, although questionable as a 100% effective preventive strategy for thymic carcinoid tumors (25,26), transcervical thymectomy has been recommended to be carried out during parathyroidectomy in HPT/MEN1 cases (27).

## Presurgical diagnosis of MEN1

As the first manifestation of MEN1 is usually HPT, and was found to increase >70% in one of our series (28), clinicians and surgeons must be strictly committed to

making or ruling out a diagnosis of MEN1 before neck exploration in each patient with apparently sporadic HPT. An adequate preoperative diagnosis may help the surgeon to choose the best surgical option (24,29,30). It is well documented that measurement of intraoperative PTH may fail in patients undergoing parathyroidectomy for whom MEN1 is not suspected (31). Moreover, early diagnosis of MEN1 is critical to the adequate management of other MEN1-related tumors that have a clinical impact (3). In this context, mutation analysis of the *MEN1* gene in apparently sporadic cases of HPT in which the patient is younger than 30 years of age may be helpful in the surgical management of HPT (1).

Genetic testing is crucial to confirm the familial character of HPT disease within clinically affected family members identified in MEN1 kindreds genetically characterized by a *MEN1* germline mutation. Although rare, relatives presenting primary HPT but not harboring a germline *MEN1* mutation have been reported. According to MEN1 clinical criteria, these patients would have been diagnosed as a MEN1 affected case (1). However, they are classified as sporadic HPT cases and should be surgically treated accordingly. Such cases represent MEN1 phenocopies, and do not need further surveillance for MEN1-related neoplasias.

Parathyroid hyperplasia or adenoma accounts for the vast majority of HPT cases in MEN1, as carcinoma seems to be an extremely rare event in this condition (32). The prevalence of parathyroid carcinomas in MEN1 tends to be much lower than in sporadic cases of HPT (33). Accordingly, we have seen no cases of parathyroid carcinoma in our HPT/MEN1 series, compared with higher frequencies observed in our sporadic HPT cases, in which we observed a 1.8–6.1% frequency of parathyroid carcinoma (34,35).

## What is the best surgical approach to HPT in MEN1?

The best surgical approach to HPT in MEN1 is under debate, and includes resection of tissues other than parathyroid glands themselves.

**Preventive thymectomy.** Presently, preventive thymectomy is highly recommended to be performed during either subtotal or total parathyroidectomy in HPT/MEN1 patients.

Since its proposal in 1997 (36), there is a general agreement that transcervical thymectomy should be performed during parathyroidectomy in all MEN1 cases, in order to: (a) detect supernumerary parathyroid glands, (b) prevent thymic carcinoids (occurrence in MEN1 ranges from 2.6% (37) to 8% (38)), and (c) to disclose intrathymic parathyroid tissue when less than four parathyroid glands are identified during neck exploration (39). It has been estimated that transcervical thymectomy usually excises only 30–40% of the thymus (39). Consequently, thymic carcinoids have developed in a few cases, even after preventive transcervical resection, and this has caused its value to be questioned (25).

Accordingly, we have adopted routine transcervical thymectomy during parathyroid intervention in HPT/MEN1 cases since 1997. To date, no thymic carcinoid has been detected in the thymic specimens, and none of our patients has developed thymic carcinoid after this procedure. However, before 1997, in a specific HPT/MEN1 patient submitted to parathyroidectomy not associated with transcervical thymectomy, a thymic carcinoid with metastases was

documented (27). Absence of thymic carcinoid with metastases in prophylactic thymectomy specimens has been reported in large series by others (30,39).

**Subtotal versus total parathyroidectomy.** Regarding the metabolic control of the HPT in MEN1, in the past many groups have favored more aggressive strategies, such as total parathyroidectomy followed by immediate parathyroid autotransplantation (40–43). However, in the last 20 years, several authors have advocated subtotal parathyroidectomy as the most suitable strategy in HPT/MEN1 cases (39,44–47). Currently, only a few authors recommend total parathyroidectomy with autotransplantation (30,48–50). In fact, for many years, it was claimed that only a prospective randomized trial would help to answer this issue; however, as far as we know, no such study has been published to date.

Data on this topic vary according to the group, but subtotal resection seems to be associated with a lesser risk of hypoparathyroidism. In 57 HPT/MEN1 cases, 34 were subjected to subtotal parathyroidectomy and 23 to total parathyroidectomy and autotransplantation. Rates of HPT persistency or recurrence were higher in the first group, while post-surgical hypoparathyroidism was more prevalent in the second group (51). In a large case series comprising 92 HPT/MEN1 patients treated over a period of 42 years, the 10-year actual recurrence-free interval data were 49% for subtotal parathyroidectomy and 84% for total parathyroidectomy and autotransplantation (47). In that series, post-surgical hypoparathyroidism rates were 26% for subtotal parathyroidectomy and 46% for total parathyroidectomy, but no significant difference was documented ( $p=0.18$ ). Notwithstanding, it was concluded that the high incidence of severe hypoparathyroidism after total parathyroidectomy with autotransplantation favored subtotal resection as the procedure of choice at the initial operation. It is worthwhile noting that a limited number of cases ( $n=16$ ) underwent total parathyroidectomy and parathyroid autotransplantation in that study (47). However, in another recent HPT/MEN1 series ( $n=47$ ), patients submitted to total parathyroidectomy and immediate autotransplantation presented with 22% postsurgical permanent hypoparathyroidism, whereas this rate was 45% in cases submitted to subtotal parathyroidectomy (30).

The rate of permanent hypoparathyroidism may be different in patients undergoing a first cervical exploration or a secondary cervical surgery. Thus, Tonelli et al. observed hypoparathyroidism in 10 out of 45 patients (22%) after the first surgery and in three out of six patients (50%) after a second cervical operation (48). Also, the rate of postsurgical hypoparathyroidism may be affected by the time of follow-up of the patient. Accordingly, there are reports of cryopreserved autografted parathyroid tissues achieving adequate PTH secretion only 2–4 years after implantation (45).

A recent meta-analysis suggested that subtotal parathyroidectomy is superior to total parathyroidectomy with immediate autotransplantation (52). Conversely, other authors favor a more aggressive initial operation (50,53). In this context, it has been claimed that further high-quality evidence for the best surgical approach for HPT in MEN1 is lacking.

**Experience from a single academic center**

In our experience, surgical treatment of HPT in MEN1 is a highly complex procedure, and the medical residents in our institution have been trained intensively in this technique (54,55). Despite improvements in imaging techniques and

intraoperative PTH sampling, the skillfulness of the surgeon is crucial. Therefore, parathyroidectomy in MEN1 patients is usually performed to a better standard in specialized tertiary academic centers where medical personnel and residents are highly trained (55,56). Moreover, it is also important that MEN1 patients can be followed-up in specialized outpatient services in order to receive support for both oncological and end-organ diseases (43,45,47,48,51, 57–59).

**Case series.** From 1987 to August, 2011, 83 HPT/MEN1 patients were submitted to 99 parathyroid interventions at the Hospital das Clínicas, University of São Paulo School of Medicine. There were 43 females and 40 males and the age at the parathyroid surgery varied from 17 to 74 years old (mean, 40.8 years). No difference in age distribution according to gender was noticed, as shown in Figure 1. Almost 75% of the patients were younger than 50 years of age and this finding may be related to the criteria used to indicate parathyroidectomy for these patients. In this HPT/MEN1 series, no child carrying the *MEN1* gene had an indication for parathyroidectomy, although young HPT cases have been operated on in our group for other reasons, such as neonatal HPT (60).

Figure 2 shows that there has been an increasing number of HPT/MEN1 patients in recent years, most probably due to the active clinical and biochemical search for MEN1 diagnosis, as well as to the routine familial genetic *MEN1* screening procedure performed by our group (3,6,7,10,11, 28,61). In a recent study, HPT/MEN1 accounted for 17% of all cases undergoing parathyroidectomy at our institution (62).

Seventy-five out of the 83 cases of HPT/MEN1 (90.4%) had their initial operation at our institution between 1987 and 2011. Of the other eight cases, two underwent

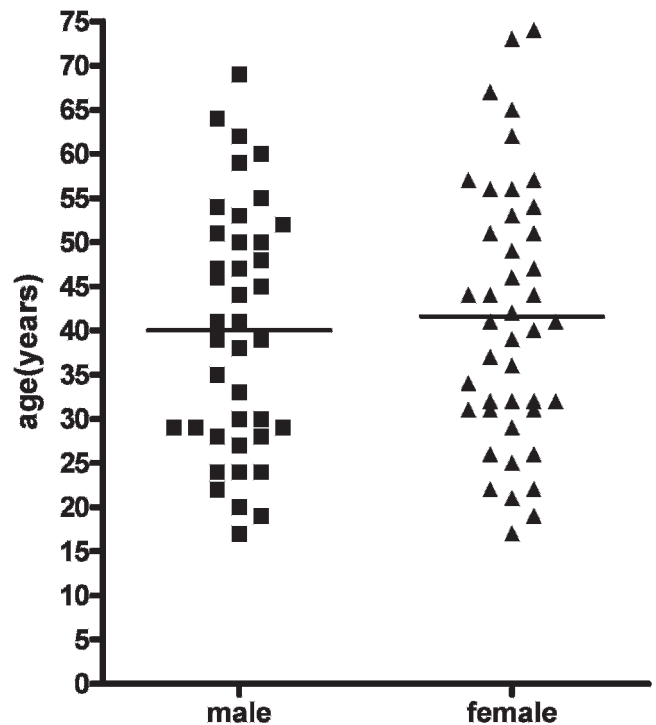
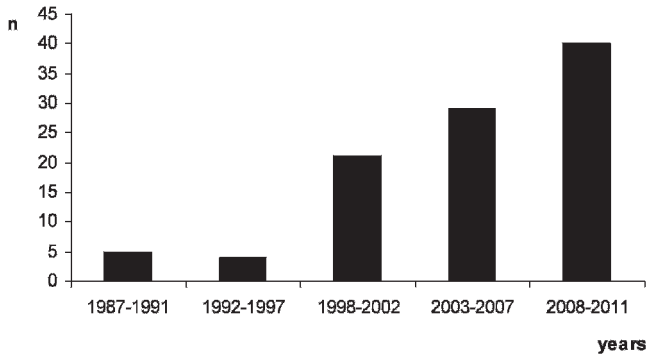


Figure 1 - Age distribution according to gender in 83 cases of hyperparathyroidism/multiple endocrine neoplasia type 1.



**Figure 2** - Emerging recognition and surgical treatment of patients with hyperparathyroidism/multiple endocrine neoplasia type 1 at our institution.

parathyroidectomy in our institution before 1987 and data from their first operation are unavailable. Surgeons initially involved in treating these two HPT/MEN1 cases might have been unaware of MEN1 at the time, excising only enlarged parathyroid glands. The remaining six cases underwent parathyroidectomy in other institutions, and their previous medical records were not available (Figures 3 and 4).

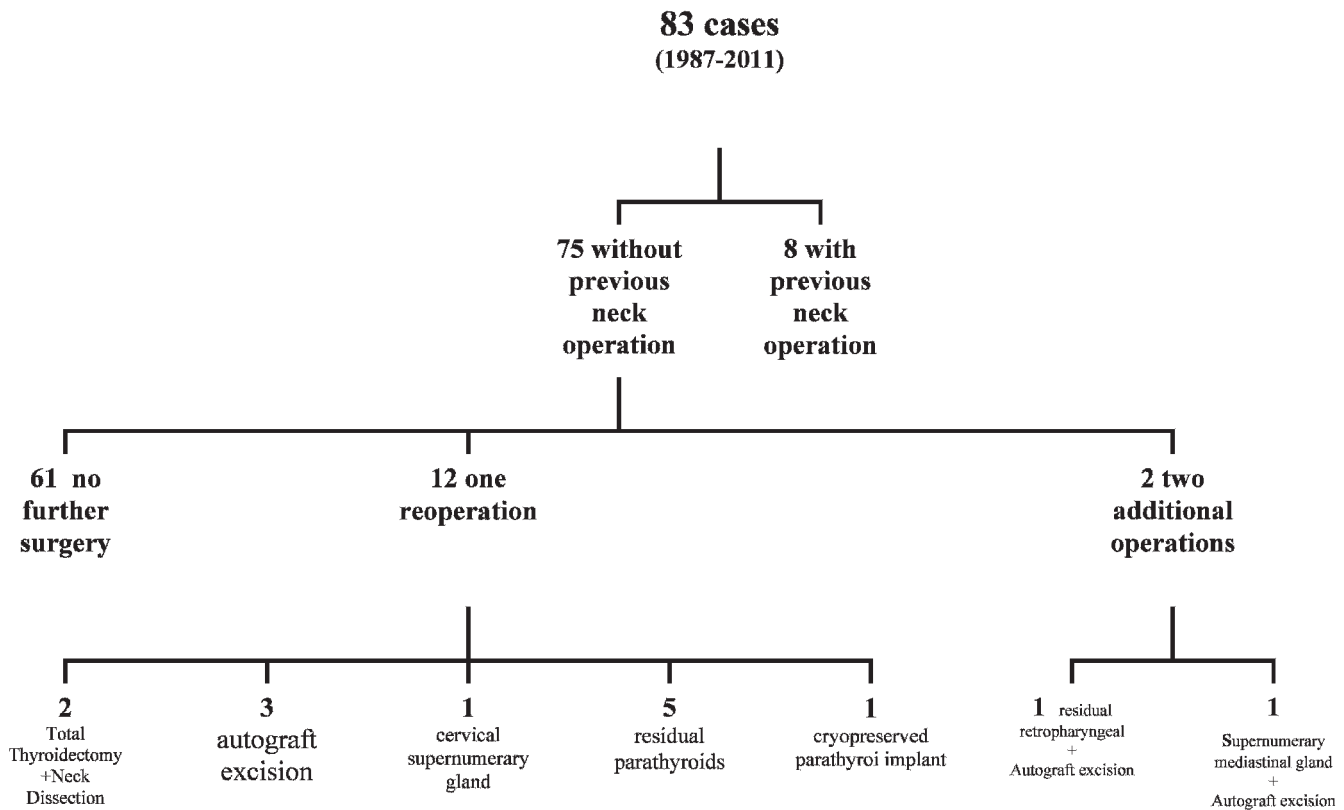
We had a reoperative rate due to HPT persistence of 8.0% (6/75) and an HPT recurrence rate of 6.75% (5/75), including all cases. However, taking into account only those patients with more than 5 years of follow-up (i.e., patients operated on up to 2006), the gross recurrence rate was 10.6%

(5/47). This latter rate may in fact be slightly higher because a longer period of follow-up could not be performed in a few cases.

**Total parathyroidectomy and autograft.** The standard initial operation for HPT/MEN1 cases at our institution has been total parathyroidectomy followed by immediate parathyroid autograft to the non-dominant forearm, associated with transcervical thymectomy. Of note, although other groups have abandoned cryopreservation of parathyroid fragments because of the good results obtained with subtotal parathyroidectomy (46), we continue to advise cryopreservation whenever this procedure is possible. Parathyroid cryopreservation may have some limiting factors (63), but it is recommended when available, irrespective of the type of parathyroid surgery, since subtotal resection involves also a significant risk of permanent hypoparathyroidism (24,30). Our experience with long-term cryopreserved tissue in secondary HPT (64) is similar to that reported by others in MEN1/HPT (30).

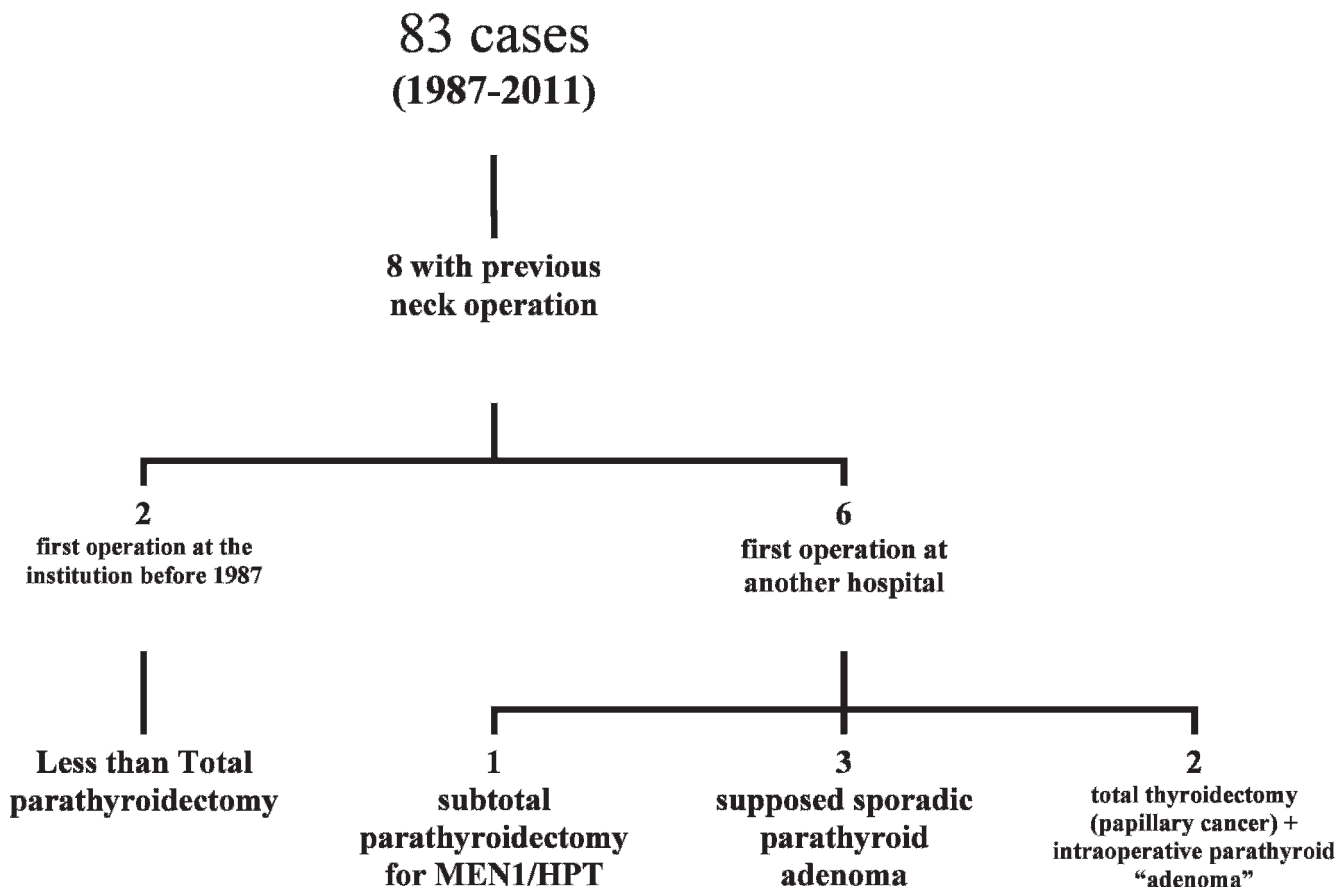
Initially, parathyroid autografts consisted of 20 fragments (each fragment was approximately 2x1 mm) that were transplanted in individual pockets. Presently, based in our experience in secondary HPT, 30 parathyroid gland fragments are usually implanted in a single pocket (65).

**Intra-operative PTH.** Intra-operative parathyroid hormone (ioPTH) measurements have been obtained in more recent cases, although in our protocol all glands should be searched and excised irrespective of their macroscopic appearance. In our experience, ioPTH in HPT/MEN1 cases has presented some limitations. Indeed, preoperative diagnosis of MEN1 is much more informative to the surgeon than imaging studies



**Figure 3** - Distribution of patients with hyperparathyroidism/multiple endocrine neoplasia type 1 who had not had a previous neck operation (1987 to 2011).





**Figure 4** - Distribution of patients with hyperparathyroidism/multiple endocrine neoplasia type 1 who had had a previous neck operation.

or ioPTH. Thus, it can inform: (a) whether additional high hyperfunctional parathyroid tissue was left behind (which has not happened yet in our group); or (b) whether the exploration can be finished, despite the fact that fewer than four glands have been identified after an extensive search.

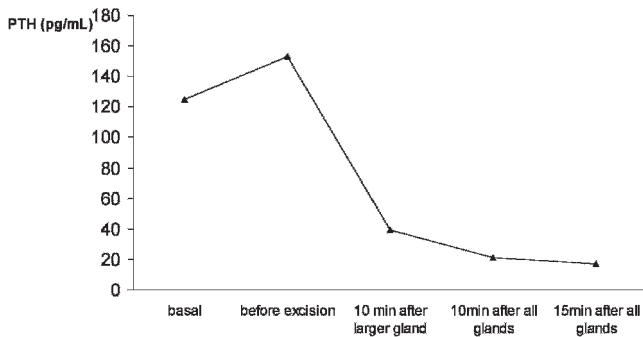
For academic purposes, we usually measure PTH at the following times: at the induction of anesthesia (basal), after identification of all parathyroid tissue (pre-excision), 10 min after the resection of the largest parathyroid gland, and again 10 min and 15 min after the excision of the remaining parathyroid tissue and thymus. In some circumstances, a decrease >50% of ioPTH has been observed after the excision of the largest parathyroid gland (Figure 5). This finding has been described previously (66), and may explain failures of ioPTH in the surgical management of HPT/MEN1 patients (31).

**Reoperations by the same team.** Fourteen out of the 75 HPT patients (18.7%) were reoperated in a total number of 16 reoperative procedures (Figure 3). Not all neck reoperations were related to HPT. Two consisted of total thyroidectomy and neck dissection for associated metastatic papillary thyroid carcinoma. In five cases, the parathyroid autograft at the forearm was excised due to recurrent HPT. One patient with non-functioning tumors was operated on due to goiter, and recurrence occurred later (see details of this case below). In five cases (6.7%), fewer than four glands could be initially identified at the first operation, and early HPT recurrence or persistence was

observed: two retropharyngeal right superior parathyroid glands (one patient with right thyroid lobe agenesis), one intrathyroidal gland, one superior gland, and one located at the aortic arch in medium mediastinum and excised by thoracoscopy. Two further cases presented with late HPT recurrence due supernumerary parathyroid glands. One was located at the cervical region and the other at the mediastinum and, in this latter case, total thymectomy was performed by sternotomy. A rate as high as 33% for supernumerary glands has been reported in MEN1/HPT cases, including intrathyroidal supernumerary glands in 2.5% of patients (8). In our current experience, no patient with MEN1/HPT has presented a supernumerary intrathyroidal gland; however, it has been observed in some patients with renal HPT at our center (67). Our rate of intrathyroidal supernumerary glands was 4.9% (unpublished data). This rate is rather inferior to the rate of almost 30% reported by others (8). However, in a large series of routine bilateral cervical thymectomy in renal HPT, the frequency of supernumerary thymic parathyroids was 6.5% (68). A similar rate of 6% has been described in MEN1/HPT (39).

Of note, two specific cases were called our attention, and they are commented on below.

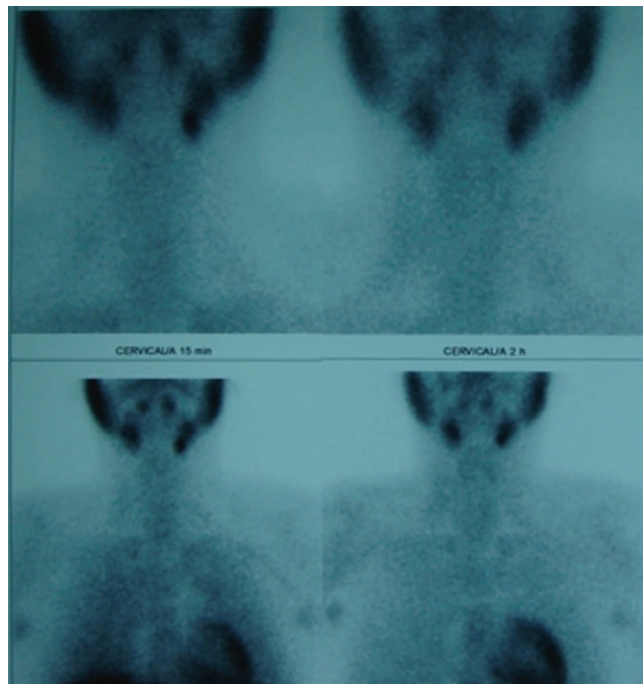
**Non-functional tumor progression.** The first case of non-functional tumor progression was a female patient who was initially submitted to cervical surgery in 1993 and presented MEN1-related tumors: a non-functioning pituitary adenoma, multiple pancreatic endocrine tumors, as well as a goiter. No



**Figure 5** - A marked decrease of intra-operative parathyroid hormone (ioPTH) after excision of the largest parathyroid gland only, in a case of hyperparathyroidism/multiple endocrine neoplasia type 1. Persistence or early hyperparathyroidism recurrence may occur if surgery is guided solely by ioPTH.

calcium abnormality was present at that time. During the partial thyroidectomy (lobectomy), an enlarged parathyroid was excised, although total parathyroidectomy was not performed at that time. She had no evidence of HPT until 13 years after parathyroid adenomectomy, when HPT ensued and she was subjected to reoperation. This case illustrates that hyperparathyroidism may ensue many years after an apparent non-functional enlargement of the parathyroid gland.

**Relative of a MEN1 patient, with HPT due to a phenocopy.** Another case, not included in the present series, is a person with HPT who was a relative of a MEN1 patient. This case came to the hospital with a clinical diagnosis of HPT/MEN1. However, after sequencing all *MEN1* and *p27*



**Figure 6** - Sestamibi scintigraphy after two previous neck interventions in a patient with hyperparathyroidism/multiple endocrine neoplasia type 1 who had been treated initially at another hospital. There was a focal radiopharmacological concentration close to the left submandibular gland due to an undescended left inferior parathyroid.

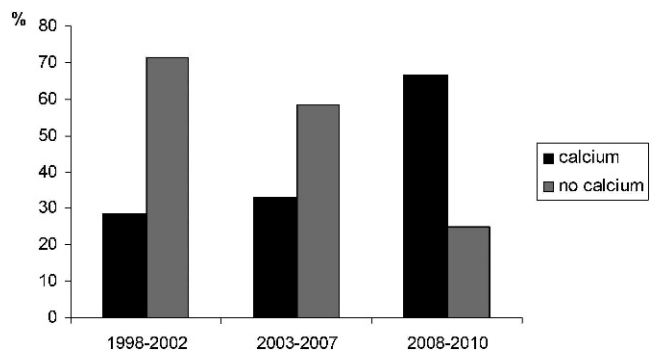
exons and their boundaries, no germline mutations were found characterizing a phenocopy, as previously reported in this condition (69). Thus, the surgical choice for this specific patient was a single parathyroid resection, with resolution of HPT. The patient is still under observation, without any sign of recurrence five years after the operation.

**Reoperations from other centers.** As mentioned, six of our HPT/MEN1 cases were initially operated on in other centers. Two were previously subjected to total thyroidectomy due to papillary thyroid carcinoma; a simultaneous intra-operative single parathyroid adenoma was found by the first surgeon. The two reoperations involved resection of the three additional parathyroid glands, central neck dissection and thymectomy. The third patient had been subjected to an intentional subtotal parathyroidectomy due to HPT/MEN1 at his primary center seven years before. His remnant was excised and partially autografted.

Three other cases had been subjected previously to surgery due to "a parathyroid adenoma"; in these cases, excision of the remaining parathyroid glands was carried out, followed by parathyroid autografts and thymectomy in one of the patients. One of these patients had been previously subjected to two cervical surgical explorations in another center; however, HPT persisted due an undescended left inferior parathyroid gland located close to the submandibular gland. This residual gland was discovered after a careful review of sestamibi scintigraphy. A first quick view may be misinterpreted as a negative result in planar projection (Figure 6). We excised this remaining parathyroid gland and part of it was immediately auto-implanted to the non-dominant forearm.

**Thyroid cancer in MEN1/HPT.** Papillary thyroid carcinoma was found in five out of 83 cases (6%). This frequency was similar to that observed in sporadic HPT cases (9%) and carcinomas incidentally found in compressive multinodular goiter (11%) treated at the same institution (70). In four out of five cases, pathological data were available: all cases had microcarcinomas, which were multicentric in two instances. Microscopic metastases were present in two cases, and one had unilateral neck lymph node metastasis. One of these patients had apparently been subjected to high-dose radiotherapy due to a pituitary tumor many years before the neck operation.

**Recurrence and hypoparathyroidism.** Recently, we attempted to contact 71 out of the 85 patients operated on from 1987 to 2010 in our institution, and information of 45



**Figure 7** - Numbers (%) of patients with hyperparathyroidism/multiple endocrine neoplasia type 1 requiring calcium supplements according to time elapsed since the initial treatment (1998 to 2010).

was available. As a first approach, a compact questionnaire was given to these patients in order to update the information on post-surgical therapy with the calcium supplement. Ten out of the 45 patients had died because of neoplasias other than MEN1-related tumors (22.2%). This observation might serve to re-emphasize the importance of early MEN1 detection and treatment, with the aim of decreasing morbidity and mortality, with reference to MEN1-related tumors in MEN1 (3). Five out of the 35 remaining cases (14.3%) had recurrent HPT disease; 14 others (40.0%) required calcium and/or calcitriol replacement therapy; and the remaining 16 cases did not take either calcium or calcitriol (45.7%). It is worthwhile noting that in HPT/MEN1 cases calcium requirement rates are impacted by the time elapsed since the parathyroidectomy. In Figure 7, the percentages of patients requiring calcium supplements were obtained at different periods after parathyroid intervention. We found that the longer the follow-up, the lower the frequency of patients requiring calcium supplement. Accordingly, in one of our HPT/MEN1 series, parathyroid auto-implants took from 6 to 15 months to secrete sufficient amounts of PTH in order to lead to normal calcemia (58).

For each individual HPT/MEN1 patient, it is necessary to decide which is the best operation to achieve the ultimate goal of maintaining normocalcemia and avoiding both iatrogenic hypocalcemia and operative complications; and facilitating future surgery for recurrent disease (71,72).

In many cases, calcium/calcitriol supplemental therapy could be stopped 15 months after total parathyroidectomy followed by parathyroid auto-implant, but not in all patients (58). A question to be addressed is the amount of calcium supplement required for each case. In our patients taking calcium supplement for more than one year, the mean intake was 1.6 g/day (range, 0.5–3.0 g/day), and 50% were taking 1.5 g/day or less.

Our present observations are in accordance with others: parathyroid autografts may take long periods, sometimes up to seven years, to achieve adequate function, and PTH levels increase with time (23,58).

Subtotal and total parathyroidectomy followed by immediate parathyroid autotransplantation are surgical approaches that are currently accepted to treat cases with HPT associated with MEN1. In our single academic center, total parathyroidectomy followed by parathyroid autotransplantation to the non-dominant forearm associated with preventive transcervical thymectomy has been the surgical approach of choice for cases of HPT/MEN1. This strategy has been successful in achieving low rates of HPT recurrence. The considerable number of calcium-dependent patients, who were mainly observed in the first nine months after operation, tended to decrease during long-term follow-up.

## ACKNOWLEDGMENTS

RAT is a recipient of FAPESP post-doctoral fellowships (2009/15386-6 and 11942/2009). SPAT is partially supported by a CNPq fellowship and a CNPq grant (401990/2010-9).

## AUTHOR CONTRIBUTIONS

Montenegro FLM, Lourenço DM Jr, Nascimento Junior CP, Arap SS, Massoni Neto LM, D'Alessandro A, Toledo RA, Coutinho FL, Cordeiro AC, and Toledo SPA conceived the study and were responsible for the

collection and analysis of data, the draft and critical review of the manuscript, and approval of the final version of the manuscript. Tavares MR, Brandão LG and Silva Filho GB conceived, drafted and critically reviewed the manuscript, and approved the final version of the manuscript.

## REFERENCES

- Brandi ML, Gagel RF, Angeli A, Bilezikian JP, Beck-Peccoz P, Bordi C, et al. Guidelines for diagnosis and therapy of MEN type 1 and type 2. *J Clin Endocrinol Metab.* 2001;86(12):5658–71, <http://dx.doi.org/10.1210/jc.86.12.5658>.
- Marx SJ. Molecular genetics of multiple endocrine neoplasia types 1 and 2. *Nat Rev Cancer.* 2005;5(2):367–75, <http://dx.doi.org/10.1038/nrc1610>.
- Lourenço DM Jr, Toledo RA, Coutinho FL, Margarido LC, Siqueira SA, dos Santos MA, et al. The impact of clinical and genetic screenings on the management of the multiple endocrine neoplasia type 1. *Clinics.* 2007;62(4):465–76, <http://dx.doi.org/10.1590/S1807-59322007000400014>.
- Lips CJM, Dreijerink K, Links TP, Höppener JWM. Multiple endocrine neoplasia type 1. *Exp Rev Endocrinol Metab.* 2009;4(4):371–88, <http://dx.doi.org/10.1586/eem.09.22>.
- Falchetti A, Marini F, Luzi E, Giusti F, Cavalli L, Cavalli T, Brandi ML. Multiple endocrine neoplasia type 1 (MEN1): Not only inherited endocrine tumors. *Genet Med.* 2009;11(12):825–35, <http://dx.doi.org/10.1097/GIM.0b013e31818e5c97>.
- Lourenço DM Jr, Toledo RA, Mackowiak II, Coutinho FL, Cavalcanti MG, Correia-Deur JE, et al. Multiple endocrine neoplasia type 1 in Brazil: MEN1 founding mutation, clinical features, and bone mineral density profile. *Eur J Endocrinol.* 2008;159(3):259–74, <http://dx.doi.org/10.1530/EJE-08-0153>.
- Lourenço DM Jr, Coutinho FL, Toledo RA, Montenegro FL, Correia-Deur JE, Toledo SP. Early-onset, progressive, frequent, extensive, and severe bone mineral and renal complications in multiple endocrine neoplasia type 1-associated primary hyperparathyroidism. *J Bone Miner Res.* 2010;25(11):2382–91, <http://dx.doi.org/10.1002/jbmr.125>.
- Arnalsteen LC, Alesina PF, Quiereux JL, Farrel SG, Patton FN, Carnaille BM, et al. Long-term results of less than total parathyroidectomy for hyperparathyroidism in multiple endocrine neoplasia type 1. *Surgery.* 2002;132(6):1119–24, <http://dx.doi.org/10.1067/msy.2002.128607>.
- Eller-Vainicher C, Chiodini I, Battista C, Viti R, Mascia ML, Massironi S, et al. Sporadic and MEN1-related primary hyperparathyroidism: differences in clinical expression and severity. *J Bone Miner Res.* 2009;24(8):1404–10, <http://dx.doi.org/10.1359/jbmr.090304>.
- Toledo RA, Lourenço DM, Coutinho FL, Quedas E, Mackowiack I, Machado MC, et al. Novel MEN1 germline mutations in Brazilian families with multiple endocrine neoplasia type 1. *Clin Endocrinol (Oxf).* 2007;67(3):377–84, <http://dx.doi.org/10.1111/j.1365-2265.2007.02895.x>.
- Lourenço DM Jr, Coutinho FL, Toledo RA, Gonçalves TD, Montenegro FL, Toledo SP. Biochemical, bone and renal patterns in hyperparathyroidism associated with multiple endocrine neoplasia type 1. *Clinics.* 2012;67(S1):99–108, [http://dx.doi.org/10.6061/clinics/2012\(Sup01\)17](http://dx.doi.org/10.6061/clinics/2012(Sup01)17).
- Heath H 3rd. Clinical spectrum of primary hyperparathyroidism: evolution with changes in medical practice and technology. *J Bone Miner Res.* 1991;6(Suppl 2):S63–70.
- Eastell R, Arnold A, Brandi ML, Brown EM, D'Amour P, Hanley DA, et al. Diagnosis of asymptomatic primary hyperparathyroidism: proceedings of the third international workshop. *J Clin Endocrinol Metab.* 2009;94(2):340–50, <http://dx.doi.org/10.1210/jc.2008-1758>.
- Peacock M, Bilezikian JP, Klassen PS, Guo MD, Turner SA, Shoback D. Cinacalcet hydrochloride maintains long-term normocalcemia in patients with primary hyperparathyroidism. *J Clin Endocrinol Metab.* 2005;90(1):135–41, <http://dx.doi.org/10.1210/jc.2004-0842>.
- Falchetti A, Cilotti A, Vaggelli L, Masi L, Amedei A, Cioppi F, et al. A patient with MEN1-associated hyperparathyroidism, responsive to cinacalcet. *Nat Clin Pract Endocrinol Metab.* 2008;4(6):351–7, <http://dx.doi.org/10.1038/ncpendmet0888>.
- Moyes VJ, Monson JP, Chew SL, Akker SA. Clinical use of cinacalcet in MEN1 hyperparathyroidism. *Int J Endocrinol.* 2010;2010:906163.
- Veldman MW, Reading CC, Farrell MA, Mullan BP, Wermers RA, Grant CS, et al. Percutaneous parathyroid ethanol ablation in patients with multiple endocrine neoplasia type 1. *AJR Am J Roentgenol.* 2008;191(6):1740–4, <http://dx.doi.org/10.2214/AJR.07.3431>.
- Kovatcheva RD, Vlahov JD, Shinkov AD, Borissova AM, Hwang JH, Arnaud F, et al. High-intensity focused ultrasound to treat primary hyperparathyroidism: a feasibility study in four patients. *Am J Roentgenol.* 2010;195(4):830–5, <http://dx.doi.org/10.2214/AJR.09.3932>.
- Silverberg SJ, Bilezikian JP. The diagnosis and management of asymptomatic primary hyperparathyroidism. *Nat Clin Pract Endocrinol Metab.* 2006;2(9):494–503, <http://dx.doi.org/10.1038/ncpendmet0265>.
- Rubin MR, Bilezikian JP, McMahon DJ, Jacobs T, Shane E, Siris E, et al. The natural history of primary hyperparathyroidism with or without parathyroid surgery after 15 years. *J Clin Endocrinol Metab.* 2008;93(9):3462–70, <http://dx.doi.org/10.1210/jc.2007-1215>.



21. Bilezikian JP, Potts JT Jr, Fuleihan Gel H, Kleerekoper M, Neer R, Peacock M, et al. Summary statement from a workshop on asymptomatic primary hyperparathyroidism: a perspective for the 21st century. *J Clin Endocrinol Metab.* 2002;87(12):5353–61, <http://dx.doi.org/10.1210/jc.2002-021370>.
22. Bilezikian JP, Khan A, Arnold A, Brandi ML, Brown E, Bouillon R, et al. Guidelines for the management of asymptomatic primary hyperparathyroidism: summary statement from the third international workshop. *J Clin Endocrinol Metab.* 2009;94(2):335–9, <http://dx.doi.org/10.1210/jc.2008-1763>.
23. Hellman P, Skogseid B, Oberg K, Juhlin C, Akerström G, Rastad J. Primary and reoperative parathyroid operations in hyperparathyroidism of multiple endocrine neoplasia type 1. *Surgery.* 1998;124(6):993–9, [http://dx.doi.org/10.1016/S0039-6060\(98\)70040-6](http://dx.doi.org/10.1016/S0039-6060(98)70040-6).
24. Hubbard JG, Sebag F, Maweja S, Henry JF. Primary hyperparathyroidism in MEN 1 – how radical should surgery be? *Langenbecks Arch Surg.* 2002;386(8):553–7, <http://dx.doi.org/10.1007/s00423-002-0275-0>.
25. Burgess JR, Giles N, Shepherd JJ. Malignant thymic carcinoid is not prevented by transcervical thymectomy in multiple endocrine neoplasia type 1. *Clin Endocrinol (Oxf).* 2001;55(5):689–93, <http://dx.doi.org/10.1046/j.1365-2265.2001.01348.x>.
26. Lim LC, Tan MH, Eng C, Teh BT, Rajasoorya RC. Thymic carcinoid in multiple endocrine neoplasia 1: genotype-phenotype correlation and prevention. *J Intern Med.* 2006;259(4):428–32, <http://dx.doi.org/10.1111/j.1365-2796.2006.01619.x>.
27. Montenegro FLM, Neves MC, Lourenço Jr DM, Arap SS, Nascimento Jr CP, Toledo SPA, et al. Thymectomy in the surgical approach to hyperparathyroidism in type 1 multiple endocrine neoplasia. *Rev Bras Cir Cab Pesc.* 2010;39(3):174–8.
28. Shepherd JJ. The natural history of multiple endocrine neoplasia type 1: highly uncommon or highly unrecognized? *Arch Surg.* 1991;126(8):935–52, <http://dx.doi.org/10.1001/archsurg.1991.01410320017001>.
29. Boguszewski CL, Bianchet LC, Raskin S, Nomura LM, Borba LA, Cavalcanti TC. Application of genetic testing to define the surgical approach in a sporadic case of multiple endocrine neoplasia type 1. *Arq Bras Endocrinol Metabol.* 2010;54(8):705–10, <http://dx.doi.org/10.1590/S0004-27302010000800007>.
30. Waldmann J, López CL, Langer P, Rothmund M, Bartsch DK. Surgery for multiple endocrine neoplasia type 1-associated primary hyperparathyroidism. *Br J Surg.* 2010;97(10):1528–34, <http://dx.doi.org/10.1002/bjs.7154>.
31. Westerdahl J, Bergenfelz A. Parathyroid surgical failures with sufficient decline of intraoperative parathyroid hormone levels: unobserved multiple endocrine neoplasia as an explanation. *Arch Surg.* 2006;141(6):589–94, <http://dx.doi.org/10.1001/archsurg.141.6.589>.
32. Shih RY, Fackler S, Maturro S, True MW, Brennan J, Wells D. Parathyroid carcinoma in multiple endocrine neoplasia type 1 with a classic germline mutation. *Endocr Pract.* 2009;15(6):567–72, <http://dx.doi.org/10.4158/EP09045.CRR1>.
33. Cordeiro AC, Montenegro FL, Kulcsar MA, Dellanegra LA, Tavares MR, Michaluart P Jr, et al. Parathyroid carcinoma. *Am J Surg.* 1998;175(1):52–5, [http://dx.doi.org/10.1016/S0002-9610\(97\)00228-6](http://dx.doi.org/10.1016/S0002-9610(97)00228-6).
34. Montenegro FL, Tavares MR, Durazzo MD, Cernea CR, Cordeiro AC, Ferraz AR. Clinical suspicion and parathyroid carcinoma management. *Sao Paulo Med J.* 2006;124(1):42–4, <http://dx.doi.org/10.1590/S1516-31802006000100009>.
35. Montenegro FM, Brandão LG, Ferreira GF, Lourenço DM Jr, Martin RM, Cunha-Neto MB, et al. Transitory increase in creatinine levels after parathyroidectomy: evidence of another action of the parathyroid glands? *Arq Bras Endocrinol Metabol.* 2011;55(4):249–55, <http://dx.doi.org/10.1590/S0004-27302011000400002>.
36. Teh BT, McArdle J, Chan SP, Menon J, Hartley L, Pullan P, et al. Clinicopathologic studies of thymic carcinoids in multiple endocrine neoplasia type 1. *Medicine (Baltimore).* 1997;76(1):21–9, <http://dx.doi.org/10.1097/00005792-199701000-00002>.
37. Goudet P, Murat A, Cardot-Bauters C, Emy P, Baudin E, du Boullay Choplin H, et al. Thymic neuroendocrine tumors in multiple endocrine neoplasia type 1: a comparative study on 21 cases among a series of 761 MEN1 from the GTE (Groupe des Tumeurs Endocrines). *World J Surg.* 2009;33(6):1197–207, <http://dx.doi.org/10.1007/s00268-009-9980-y>.
38. Gibril F, Chen YJ, Schrupp DS, Vortmeyer A, Zhuang Z, Lubensky IA, et al. Prospective study of thymic carcinoids in patients with multiple endocrine neoplasia type 1. *J Clin Endocrinol Metab.* 2003;88(3):1066–81, <http://dx.doi.org/10.1210/jc.2002-021314>.
39. Powell AC, Alexander HR, Pingpank JF, Steinberg SM, Skarulis M, Bartlett DL, et al. The utility of routine transcervical thymectomy for multiple endocrine neoplasia 1-related hyperparathyroidism. *Surgery.* 2008;144(6):878–83, <http://dx.doi.org/10.1016/j.surg.2008.08.031>.
40. Wells Jr SA, Gunnells JC, Shelburne JD, Schneider AB, Sherwood LM. Transplantation of the parathyroid glands in man: clinical indications and results. *Surgery.* 1975;78(1):34–44.
41. Wells Jr SA, Ellis GJ, Gunnells JC, Schneider AB, Sherwood LM. Parathyroid autotransplantation in primary parathyroid hyperplasia. *N Engl J Med.* 1976;295(2):57–62, <http://dx.doi.org/10.1056/NEJM197607082950201>.
42. Wells Jr SA, Farndon JR, Dale JK, Leight GS, Dilley WG. Long-term evaluation of patients with primary parathyroid hyperplasia managed by total parathyroidectomy and heterotopic autotransplantation. *Ann Surg.* 1980;192(4):451–8, <http://dx.doi.org/10.1097/0000658-198010000-00003>.
43. Malmæus J, Benson L, Johansson H, Ljunghall S, Rastad J, Akerström G, et al. Parathyroid surgery in the multiple endocrine neoplasia type I syndrome: choice of surgical procedure. *World J Surg.* 1986;10:668–72, <http://dx.doi.org/10.1007/BF01655552>.
44. Burgess JR, David R, Parameswaran V, Greenaway TM, Shepherd JJ. The outcome of subtotal parathyroidectomy for the treatment of hyperparathyroidism in multiple endocrine neoplasia type 1. *Arch Surg.* 1998;133(2):126–9, <http://dx.doi.org/10.1001/archsurg.133.2.126>.
45. Lambert LA, Shapiro SE, Lee JE, Perrier ND, Truong M, Wallace MJ, et al. Surgical treatment of hyperparathyroidism in patients with multiple endocrine neoplasia type 1. *Arch Surg.* 2005;140(4):374–82, <http://dx.doi.org/10.1001/archsurg.140.4.374>.
46. Hubbard JG, Sebag F, Maweja S, Henry JF. Subtotal parathyroidectomy as an adequate treatment for primary hyperparathyroidism in multiple endocrine neoplasia type 1. *Arch Surg.* 2006;141(3):235–9, <http://dx.doi.org/10.1001/archsurg.141.3.235>.
47. Elaraj DM, Skarulis MC, Libutti SK, Norton JA, Bartlett DL, Pingpank JF, et al. Results of initial operation for hyperparathyroidism in patients with multiple endocrine neoplasia type 1. *Surgery.* 2003;134(6):858–64, [http://dx.doi.org/10.1016/S0039-6060\(03\)00406-9](http://dx.doi.org/10.1016/S0039-6060(03)00406-9).
48. Tonelli F, Marcucci T, Fratini G, Tommasi MS, Falchetti A, Brandi ML. Is total parathyroidectomy the treatment of choice for hyperparathyroidism in multiple endocrine neoplasia type 1? *Ann Surg.* 2007;246(6):1075–82, <http://dx.doi.org/10.1097/SLA.0b013e31811f4467>.
49. Tonelli F, Marcucci T, Giudici F, Falchetti A, Brandi ML. Surgical approach in hereditary hyperparathyroidism. *Endocr J.* 2009;56(7):827–41, <http://dx.doi.org/10.1507/endocrj.K09E-204>.
50. Tonelli F, Giudici F, Cavalli T, Brandi ML. Surgical approach in patients with hyperparathyroidism in multiple endocrine neoplasia type 1: total versus partial parathyroidectomy. *Clinics.* 2012;67(S1):155–160, [http://dx.doi.org/10.6061/clinics/2012\(Sup01\)26](http://dx.doi.org/10.6061/clinics/2012(Sup01)26).
51. Hellman P, Skogseid B, Juhlin C, Akerström G, Rastad J. Findings and long-term results of parathyroid surgery in multiple endocrine neoplasia type 1. *World J Surg.* 1992;16(4):718–22, <http://dx.doi.org/10.1007/BF02067367>.
52. Schreinemakers JM, Pieterman CR, Scholten A, Vriens MR, Valk GD, Borel Rinkes IH. The optimal surgical treatment for primary hyperparathyroidism in MEN1 patients: a systematic review. *World J Surg.* 2011;35(9):1993–2005, <http://dx.doi.org/10.1007/s00268-011-1068-9>.
53. Piecha G, Chudek J, Więcek A. Primary hyperparathyroidism in patients with multiple endocrine neoplasia type 1. *Int J Endocrinol.* 2010;2010:928383.
54. Montenegro FLM, Smith RB, Arap SS, Turcano R, Michaluart Jr P, Tavares MR, et al. Teaching of parathyroid surgery and proposal of a complexity stratifying scale. *Rev Bras Cir Cabeça Pescoço.* 2008;37(1):71–5.
55. Montenegro FLM, Brandão LG, Arap SS, Durazzo MD, Nascimento Jr CP, Santos SRCL, et al. Parathyroidectomy as a model of learning evaluation of surgery residents: initial results of a prospective study. *Rev Bras Cir Cab Pesc.* 2009;38(4):4–9.
56. Goudet P, Cougard P, Vergès B, Murat A, Carnaille B, Calender A, et al. Hyperparathyroidism in multiple endocrine neoplasia type I: surgical trends and results of a 256-patient series from Groupe D'etude des Néoplasies Endocriniennes Multiples Study Group. *World J Surg.* 2001;25(7):886–90, <http://dx.doi.org/10.1007/s00268-001-0046-z>.
57. Goudet P, Murat A, Binquet C, Cardot-Bauters C, Costa A, Ruzsniowski P, et al. Risk factors and causes of death in MEN1 disease. A GTE (Groupe d'Etude des Tumeurs Endocrines) cohort study among 758 patients. *World J Surg.* 2010;34(2):249–55.
58. Coutinho FL, Lourenço DM Jr, Toledo RA, Montenegro FL, Correia-Deur JE, Toledo SP. Bone mineral density analysis in patients with primary hyperparathyroidism associated with multiple endocrine neoplasia type 1 after total parathyroidectomy. *Clin Endocrinol (Oxf).* 2010;72(4):462–8, <http://dx.doi.org/10.1111/j.1365-2265.2009.03672.x>.
59. Coutinho FL, Lourenço DM Jr, Toledo RA, Montenegro FL, Toledo SP. Post-surgical follow up of primary hyperparathyroidism associated with multiple endocrine neoplasia type 1. *Clinics.* 2012;67(S1):169–72, [http://dx.doi.org/10.6061/clinics/2012\(Sup01\)28](http://dx.doi.org/10.6061/clinics/2012(Sup01)28).
60. Damiani D, Aguiar CH, Bueno VS, Montenegro FL, Koch VH, Cocozza AM, et al. Primary hyperparathyroidism in children: patient report and review of the literature. *J Pediatr Endocrinol Metab.* 1998;11(1):83–6, <http://dx.doi.org/10.1515/JPEM.1998.11.1.83>.
61. Toledo RA, Sekiya T, Longuini VC, Coutinho FL, Lourenço DM Jr, Toledo SP. Narrowing the gap of personalized medicine in emerging countries: the case of multiple endocrine neoplasias in Brazil. *Clinics.* 2012;67(S1):3–6, [http://dx.doi.org/10.6061/clinics/2012\(Sup01\)02](http://dx.doi.org/10.6061/clinics/2012(Sup01)02).
62. Montenegro F, Martin RM, Lourenço Jr DM, Arap SS, Nascimento Jr CP, Brandão LG. Transient change of glomerular function rate after



- parathyroidectomy is not dependent on preoperative renal function. *Rev Bras Cir Cab Pesc.* 2010;39(4):99-102.
63. Barreira CE, Cernea CR, Brandão LG, Custódio MR, Caldini ET, de Menezes Montenegro FL. Effects of time on ultrastructural integrity of parathyroid tissue before cryopreservation. *World J Surg.* 2011;35(11):2440-4, <http://dx.doi.org/10.1007/s00268-011-1261-x>.
  64. de Menezes Montenegro FL, Custódio MR, Arap SS, Reis LM, Sonohara S, et al. Successful implant of long-term cryopreserved parathyroid glands after total parathyroidectomy. *Head Neck.* 2007;29(3):296-300, <http://dx.doi.org/10.1002/hed.20506>.
  65. Caliseo CT, Santos SR, Nascimento CP Jr, Arap SS, Brandão LG, Montenegro FL. Functional results of parathyroid autotransplantation in one single pocket for treatment of secondary hyperparathyroidism. *Rev Col Bras Cir.* 2011;38(2):85-9, <http://dx.doi.org/10.1590/S0100-69912011000200003>.
  66. Tonelli F, Spini S, Tommasi M, Gabbrilli G, Amorosi A, Brocchi A, et al. Intraoperative parathormone measurement in patients with multiple endocrine neoplasia type I syndrome and hyperparathyroidism. *World J Surg.* 2000;24(5):556-62, <http://dx.doi.org/10.1007/s002689910091>.
  67. Montenegro FL, Tavares MR, Cordeiro AC, Ferraz AR, Ianhez LE, Buchpigel CA. Intrathyroidal supernumerary parathyroid gland in hyperparathyroidism after renal transplantation. *Nephrol Dial Transplant.* 2007;22(1):293-5, <http://dx.doi.org/10.1093/ndt/gfl503>.
  68. Schneider R, Waldmann J, Ramaswamy A, Fernández ED, Bartsch DK, Schlosser K. Frequency of ectopic and supernumerary intrathyroid parathyroid glands in patients with renal hyperparathyroidism: analysis of 461 patients undergoing initial parathyroidectomy with bilateral cervical thymectomy. *World J Surg.* 2011;35(6):1260-5, <http://dx.doi.org/10.1007/s00268-011-1079-6>.
  69. Falchetti A, Brandi ML. Multiple endocrine neoplasia type I variants and phenocopies: more than a nosological issue? *J Clin Endocrinol Metab.* 2009;94(5):1518-20, <http://dx.doi.org/10.1210/jc.2009-0494>.
  70. Montenegro FLM, Smith RB, Castro IV, Tavares MR, Cordeiro AC, Ferraz AR. Association of papillary thyroid carcinoma and hyperparathyroidism. *Rev Col Bras Cir.* 2005;32:115-9, <http://dx.doi.org/10.1590/S0100-69912005000300003>.
  71. Stålberg P, Carling T. Familial parathyroid tumors: diagnosis and management. *World J Surg.* 2009;33(11):2234-43, <http://dx.doi.org/10.1007/s00268-009-9924-6>.
  72. Salmeron MD, Gonzelez JM, Sancho insenser J, Goday A, Perez NM, Zambudio AR, et al. Causes and treatment of recurrent hyperparathyroidism after subtotal parathyroidectomy in the presence of multiple endocrine neoplasia 1. *World J Surg.* 2010;34(6):1325-31.