

Case Report

Echocardiographic Demonstration of the Effect of Varying Paced A-V Intervals on Ventricular Filling Pattern

Damodar Kumbala MD,FAHA, Sony Jacob MD, Masoor Kamalesh MD, FACC, Mithilesh Das MD, MRCP, FACC.

Krannert Institute of Cardiology, Indiana University, Indianapolis IN 46202

Address for correspondence: M. Kamalesh MD, 1481 W 10th Street, VAMC, Indianapolis, IN 46202. E-mail: masoor.kamalesh/at/med.va.gov

Key Words: A-V interval; ventricular filling; echocardiography

Impaired relaxation of the left ventricle (LV) (diastolic dysfunction) invariably is associated with LV systolic dysfunction.¹ Atrial contribution to ventricular filling (second filling phase of diastole) is pivotal in the presence of impaired relaxation where early filling is reduced. Cardiac Resynchronization Therapy (CRT) has been shown to improve diastolic function in patients with heart failure.^{2,3} Optimization of atrioventricular (AV) synchrony in sinus rhythm for patients with biventricular ICD (BiV ICD) for CRT is crucial in maximizing hemodynamic improvements.^{4,5}

In this brief report we demonstrate the use of Spectral Doppler to assess effect of varying paced atrioventricular (AV) intervals on the mitral filling pattern in a patient with CRT for severe congestive heart failure with an ejection fraction of 15% and a wide QRS interval.

Case report

A class 3 NYHA patient who underwent a BiV ICD implant was evaluated for optimization of CRT one month after implantation. This was performed by adjusting the AV interval and the LV to right ventricular (RV) pacing interval. The device interrogation revealed a complete AV block. The aortic valve velocity time integral (VTI) was recorded for cardiac output measurement while Doppler recording of A and E waves demonstrated mitral valve inflow. The above mentioned parameters were recorded by increasing the A sensed-V pace interval from 80 ms to 260 ms at increments of 20-40ms (**Figures 1 and 2**)

After determining an optimal AV interval for the maximum aortic VTI and diastolic function (measured by finding the optimum E and A wave on Doppler recording), the paced LV to paced RV delay was tested. The optimum AV delay of 140 ms and an LV to RV paced delay was 30 ms to achieve the maximum cardiac output.

The effect of varying the AV interval on early and late diastolic filling of LV is shown in **figure 1**. At longer AV intervals (from 160-240 msec) there is relatively greater atrial contribution to ventricular filling as shown by E/A ratio of <1. At AV interval of 140 the ratio begins to normalize; 120 msec interval being normalized. Reducing the interval further to 80 msec and 60 msec diminished atrial contribution significantly. The aortic velocity and VTI increased from 0.7 m/sec (VTI 18 cms) at longer AV intervals to 0.9 m/sec (VTI 21.83) at optimal AV interval of 100-120 msec. (**Figure 2**) The increase in aortic VTI is 17.5% per cardiac cycle.

The patient's clinical symptoms improved during a two-week follow up. The NYHA class improved from III to II, with symptomatic improvement of shortness of breath as well as pedal edema.

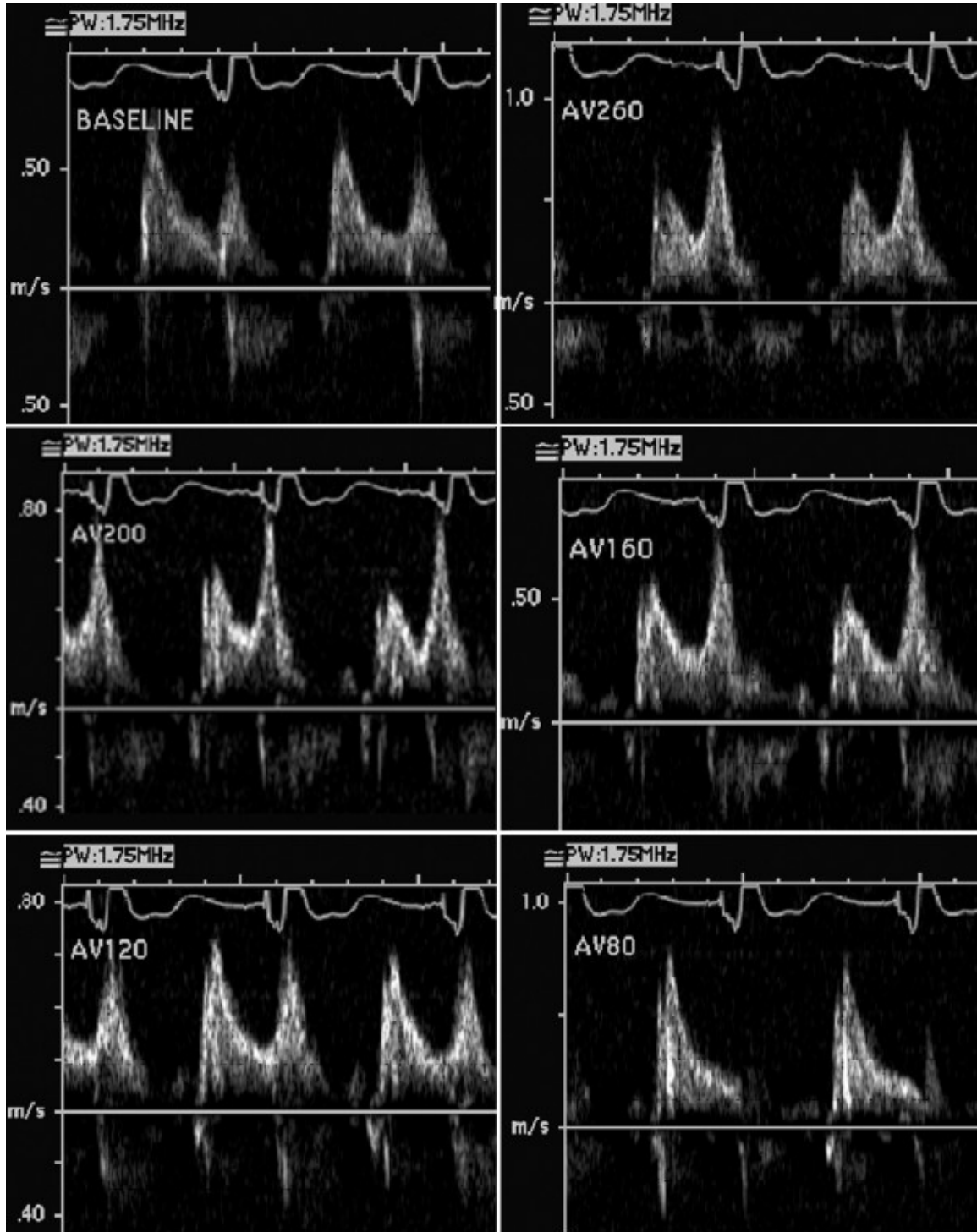


Figure 1: a-f. Mitral inflow pattern variation with changing AV intervals (in milliseconds). See text for details.

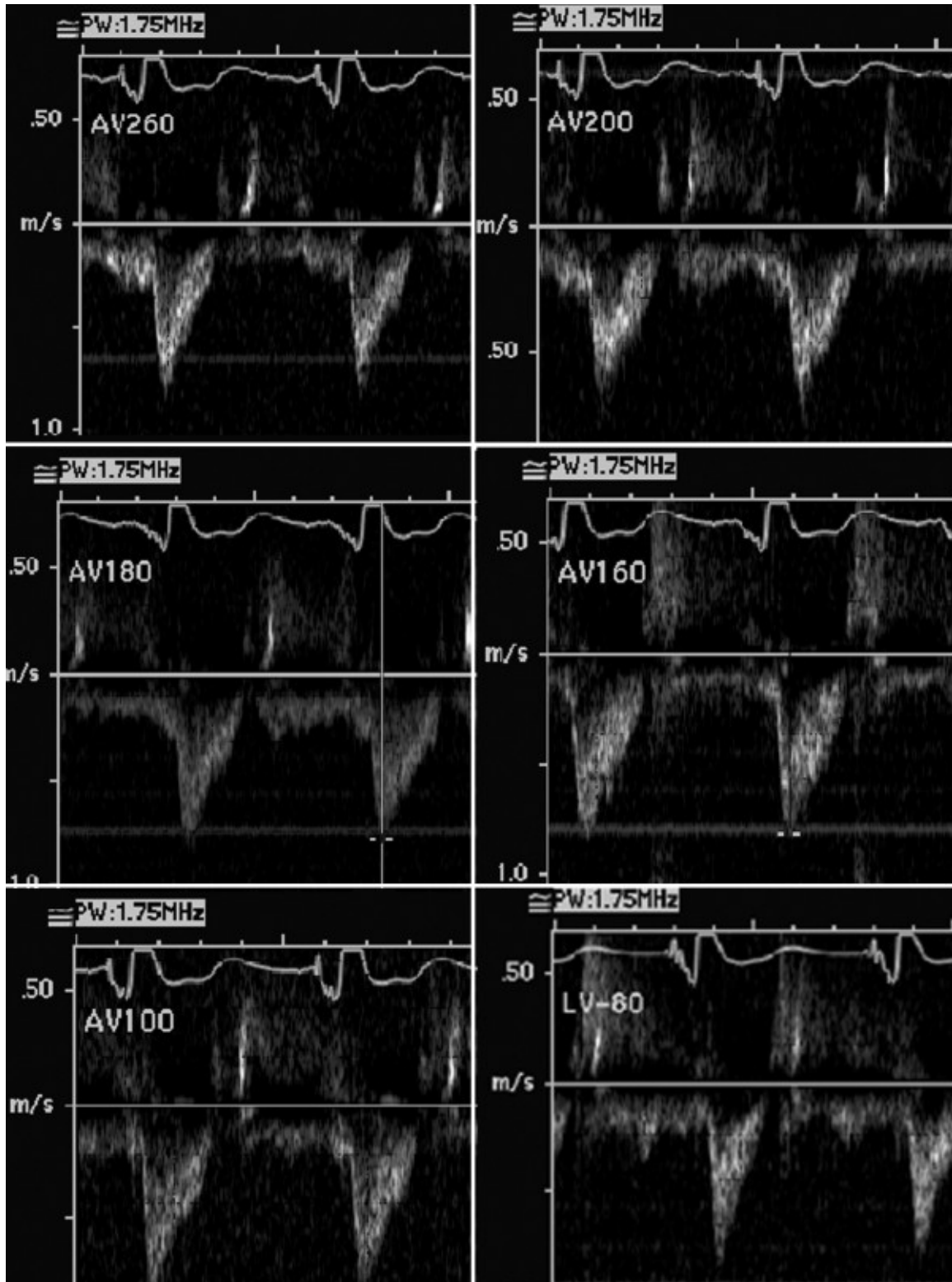


Figure 2: a-f. Left ventricular outflow Doppler profiles with changing A-V intervals (in milliseconds). See text for details.

Discussion

The use of spectral Doppler echocardiography to optimize the effects of AV intervals on cardiac output following implantation CRT device is demonstrated here. Spectral Doppler

interrogation of mitral inflow is easy to perform and is part of a routine echocardiographic study. The technique is widely available and easy to interpret. To maximize hemodynamic improvement, one should, not only maintain the AV synchrony but also optimize AV interval using echocardiography. This can ensure appropriate mitral filling.

Patients with diastolic dysfunction are particularly dependent on atrial contribution to ventricular filling. To prevent any atrial input compromise after pacemaker implantation, mitral inflow can be interrogated with spectral Doppler to set the optimum AV interval.

References

1. Oh JK, Hatle L, Tajik AJ, Little WC. Diastolic heart failure can be diagnosed by comprehensive two-dimensional and Doppler echocardiography. *J Am Coll Cardiol.* 2006;47:500-6.
2. Waggoner AD, Agler DA, Adams DB. Cardiac resynchronization therapy and the emerging role of echocardiography (part 1): indications and results from current studies. *J Am Soc Echocardiogr.* 2007;20:70-75.
3. Yu CM, Zhang Q, Yip GW, Chan YS, Lee PW, Wu LW, Lam YY, Kum LC, Chan HC, Chan S, Fung JW. Are left ventricular diastolic function and diastolic asynchrony important determinants of response to cardiac resynchronization therapy? *The American Journal of Cardiology.* 2006;98:1083-1087.
4. Melzer C, Borges AC, Knebel F, Richter WS, Combs W, Baumann G, Theres H. Echocardiographic AV-interval optimization in patients with reduced left ventricular function. *Cardiovascular ultrasound.* 2004;2:30.
5. Santos JF, Parreira L, Madeira J, Fonseca N, Soares LN, Ines L. Non invasive hemodynamic monitorization for AV interval optimization in patients with ventricular resynchronization therapy. *Rev Port Cardiol.* 2003;22:1091-1098.