

RESEARCH

Open Access



# Cemented vs uncemented megaprotheses in proximal femur metastases: a multicentric comparative study

Maria Serena Oliva<sup>1,2†</sup>, Francesco Muratori<sup>3†</sup>, Raffaele Vitiello<sup>1,2</sup>, Antonio Ziranu<sup>1,2\*</sup>, Lorenzo Foschi<sup>3</sup>, Giuseppe Rovere<sup>1,2</sup>, Cesare Meschini<sup>1,2</sup>, Domenico Andrea Campanacci<sup>3</sup> and Giulio Maccauro<sup>1,2</sup>

## Abstract

**Background:** Hip megaprotheses are a long known reconstructive method in the treatment of proximal femur metastases. The use of cemented or uncemented stems is still matter of debate. The aim of this study to compare cemented and uncemented megaprotheses on functional outcomes and complications, in order to establish the role of cementation.

**Methods:** We retrospectively analysed 51 metastatic patients with proximal femur metastases treated with endoprosthesis reconstruction by megaprotheses, 25 with cementless stems and 26 with cemented ones with different megaprosthesis implants. The primary endpoint was MSTs score, and the secondary endpoint was to state the incidence of surgical and clinical complications in the two groups. An un-paired T test was used to compare anthropometric, anamnestic data, and MSTs. Chi-square test was performed for evaluation of complication in the two group. Multiple linear regression was used to match the functional outcomes and complications' incidence in the population study. Logistic regression was performed to analyse the odds ratio of different parameters and their role in the incidence of complications.

**Results:** The mean follow-up was 50.1 months (+ 12.5). In thirty case right side was involved. No statistical differences were noticed between Group A and B regard the age, gender, active fracture/impending fracture. Comparing the MSTs results within the two groups at last follow-up, the score cemented group was higher than cementless one (17.9 + 7.8 vs 24.2 + 5.3; statistical significance  $p = 0.001$ ). Regarding surgical complications a logistic regression was performed to analyse the odds ratio of age, cementation and length of resection; cementation confirm and odds ratio of 11 times in the incidence of surgical complications.

**Conclusions:** Cementation seems to be more liable to complications onset, while improves functional score in metastatic patients compared to uncemented megaprotheses. More studies have to be conducted in order to create a protocol and establish criteria to use cemented or uncemented stems in a frail population like metastatic patients.

**Keywords:** Metastases, Proximal femur, Megaprotheses

## Background

Proximal femur is one of the most common bony location of metastatic disease [1, 2]. Proximal femur metastases develop in about 10% patients with primary malignant tumor [3, 4]. Impending or pathological fractures have to be surgically treated ensuring local control of the disease,

<sup>†</sup>Maria Serena Oliva and Francesco Muratori contributed equally to this work.

\*Correspondence: Antonio.ziranu@policlinicogemelli.it

<sup>1</sup>Fondazione Policlinico Universitario Agostino Gemelli – IRCCS, Largo Agostino Gemelli 8, 00168 Rome, Italy  
Full list of author information is available at the end of the article



pain control and good functional and clinical outcomes [5, 6].

The use of hip megaprotheses in the management of hip metastases has been largely known from years now [7]. Megaprotheses in solitary skeletal-related events can guarantee adequate surgical margins, pain relief and a stable joint situation allowing fast patient mobilisation after surgery [8].

Megaprosthesis implants can be either cemented or uncemented and implant-related complications [9], such as dislocation, infection and aseptic loosening have been described for both kinds of implant [10, 11].

Some authors prefer cementation because of lower rates of revision for loosening and no need of osteointegration for total weight bearing, so this condition allows patients to start chemotherapy as soon as possible [9, 12, 13].

On the other side cementation increases surgical time length and consequently infection risk [14], and in literature some authors described “bone cement implantation syndrome” with higher risk of developing intra-operative death and higher risk of pulmonary embolism [15, 16]. Lastly the presence of a cemented megaprosthesis could aggravate subsequent revision surgeries.

Some authors recommend cementation to be performed in patients who need postoperative radiotherapy and/or with additional metastases, while in all other cases cementation is not needed [17].

In literature cementless stem endoprotheses reported higher implant survival and infection survival compared to cemented ones, while the aseptic loosening rates were similar in the two groups [9].

Whether some authors compared cemented and cementless megaprosthesis implants about survival and infection rates others compared nail fixation with endoprosthesis reconstruction and their functional outcomes [3, 9]. The use of cemented or cementless stem prostheses is still matter of debate.

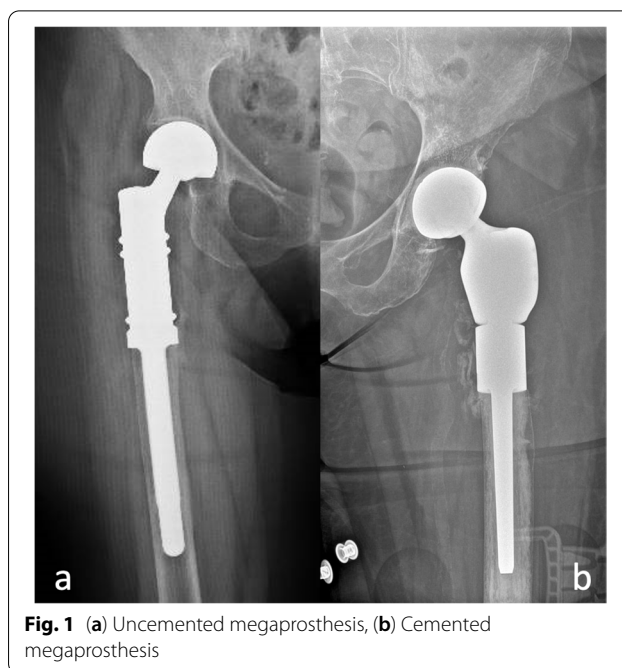
The aim of this multicentric retrospective study is to understand the role of cementation in patients affected by proximal femur metastasis treated with modular endoprotheses and to compare complication rates and functional outcomes.

## Methods

Metastatic patients treated with proximal femur resection and modular endoprosthesis reconstruction in two major oncological orthopaedic hospitals were retrospectively analysed.

Group A used cementless megaprotheses (Fig. 1a), while Group B used cemented megaprotheses (Fig. 1b).

Inclusion criteria were: metastatic disease in patients >18years old with proximal femur (from greater



**Fig. 1** (a) Uncemented megaprosthesis, (b) Cemented megaprosthesis

trochanter to sub-trochanteric area) resection and endoprosthesis reconstruction.

Exclusion criteria were: patients with follow up less than 6 months, patients with primary bone tumour of the proximal femur, distal or total femur resection/reconstruction.

## Surgical technique

All patients underwent hip endoprosthesis reconstruction by megaprosthesis.

In group A all the procedures were performed by fellowship-trained in oncological surgery orthopaedic surgeons.

General anesthesia was performed in all cases. All patients received Cephazoline 2g i.v. as antibiotic prophylaxis before surgery, if not contraindicated [18]. A urinary catheter was placed in all patients and removed within 72 hours after the surgery.

Patients were placed in lateral decubitus position. A lateral approach was used. After bone exposure, an en bloc resection was performed, cementless silver-coated megaprosthesis was implanted according to the manufacturer technique (Mutars, Implantcast) [19]. The surgery was completed by myodesis through the Trevira Tube© (Implantcast; GmbH, Buxtehude, Germany). One intra-articular closed-suction drainage was placed and then removed 48 hours after surgery.

In group B all the procedures were performed by fellowship-trained in oncological surgery orthopaedic surgeons.

General anesthesia was performed in all cases. All patients received antibiotic prophylaxis before surgery according to hospital's protocol, if not contraindicated.

Patients were placed in lateral decubitus position. A lateral approach was used. After bone exposure, an en block resection was performed, cemented endoprosthesis was implanted according to the manufacturer technique (Megsystem C Link) [20]. The surgery was completed by myodesis through pre-existing prosthetic holes. One intra-articular closed-suction drainage was placed and then removed 48 hours after surgery.

All patients followed the same post-operative rehabilitation protocol: at 48 hours after surgery patients were seated with their feet out of bed; at 72 hours, they were allowed to progressive weight bearing with walker frames.

### Clinical evaluation

Anthropometric and anamnestic data, primitive tumor, presence of impending or pathological fracture, surgery time were collected.

All patients restarted oncological cares 30 days after surgery according to oncological protocols.

Complications were divided into two groups: surgical and clinical ones. In the surgical complications group were included: wound dehiscence, deep infection, dislocation, aseptic loosening, revision rate.

Wound dehiscence or surgical site infection was defined as a delayed of normal healing of the surgical wound with presence of redness, edema and secretion in absence of deep tissue involvement or general symptoms [21].

In the clinical complication group pneumonia, pulmonary embolism, urinary tract infection, post-operative anemia, decubitus, development of deep vein thrombosis were included.

Self-assessed questionnaires were administered to all patients at the clinic at 6 months follow-up. Musculoskeletal Tumor Society scoring system (MSTS) the scale was given to all patients to evaluate their residual post-operative function [22]. The scale evaluates 6 parameters (Pain, Function, emotional, supports, walking, gait) in a scale from 0 to 5 (0 minimum score, 5 maximum).

### Radiological assessment

Fractures were diagnosed through a standard X-ray series in each case (AP and LL). Impending fractures were identified with standard X-ray series and in peculiar cases with the aid of TC scan and Mirels'score was used to stratify the fracture risk [23]. For a Mirels'score over 8 points surgical indication was confirmed. Affiliation was used to identify Femur MRI with radiocontrast has been used to assess the bone resection length.

An X-ray (AP and LL) was required at first, third and sixth postoperative month and then every year.

The patients underwent to a total body CT by oncologists' decision and came to the orthopaedic clinic to evaluate the disease's progression.

### Statistical analysis

GraphPad QuickCalcs (GraphPad Software, San Diego) was used for data analysis. The data were reported as mean and standard deviation (+ SD).

The asymmetry was calculated to evaluate the normality of the different parameters.

An un-paired T test was used to compare anthropometric, anamnestic data, and MSTS. Chi-square test was performed for evaluation of complication in the two group. Multiple linear regression was used to match the functional outcomes and complications' incidence in the population study. Logistic regression was performed to analyze the odds ratio of different parameters in the incidence of complication.

Significance was set for  $p < 0.05$ .

### Results

Fifty-one patients were considered eligible according to inclusion and exclusion criteria and were finally included in the study.

Twenty-five patients were assigned to Group A (uncemented) and twenty-six in Group B (cemented).

The primary outcome analyzed was the clinical outcomes at last follow-up (MSTS score). The secondary outcome was incidence of complications.

Breast cancer was the most common primary tumor (35%), followed by kidney (13%), lymphoma (13%), lung (9%), prostate (9%), myeloma (7%) and other (10%).

In Group B, preventive surgery was more frequent than Group A, but without statistical difference (44% vs 57%;  $p = 0.3$ ).

There were 18 male and 33 females, the mean age was 64,8 years old ( $\pm 2.4$ ). The mean follow-up was 50,1 months ( $\pm 12.5$ ). In thirty case right side was involved. No statistical differences were noticed between Group A and B regard the age, gender, active fracture/impending fracture (Table 1).

No difference was noticed among surgery duration time (Group A  $2.6 \pm 0.6$  hours vs Group B  $2.4 \pm 0.9$  hours;  $p = 0.7$ ) or resection length (Group A  $11.7 \pm 3$  cm vs Group B  $13.5 \pm 3.8$  cm;  $p = 0.08$ ) (Table 1).

Comparing the MSTS results within the two groups at last follow-up, the score in Group B was higher than Group A ( $17.9 \pm 7.8$  vs  $24.2 \pm 5.3$ ;  $p = 0.001$ ).

Globally fourteen complications were recorded.

In Group A, two urinary tract infection (2/25 patients; 8%), one pneumonia (1/25 patients; 4%) and

**Table 1** Baseline characteristics

	Total	Cementless	Cemented	P
Patients	51	25	26	
Sex	18M   33F	9M   16F	9M   17F	
Age (years)	64.8 ± 2.4	67.5 ± 10	62 ± 13	0.1
Active fracture	25	14	11	0.3
Impending fracture	26	11	15	0.3
Follow-up (months)	50.1 ± 12.5	39 ± 33	61 ± 51	0.1
Duration time of surgery (hours)	2.6 ± 0.2	2.7 ± 0.6	2.4 ± 0.9	0.7
Resection length (cm)	12.6 ± 0.5	11.8 ± 3.3	13.5 ± 3.8	0.08
MSTS	21.1 ± 1.8	17.9 ± 7.8	24.2 ± 5.2	0.001*

In brackets measurement unit; Data were reported as absolute value ± SD. \* underline statistical significance

**Table 2** Complications

	Total	Cementless	Cemented	P
Patients	51	25	26	
Surgical complications	10 (19%)	1 (4%)	9 (34%)	0.005
Dislocations	5 (9%)	1 (4%)	4 (15%)	0.15
Wound dehiscence	3 (5%)	0	3 (11%)	
Nerve palsy	1 (1%)	0	1 (3%)	
Aseptic loosening	1 (1%)	0	1 (3%)	
Clinical complications	4 (7%)	3 (12%)	1 (3%)	0.2
Urinary tract infections	2 (3%)	2 (8%)	0	
Pneumonia	1 (1%)	1 (4%)	0	
Deep vein thrombosis	1 (1%)	0	1 (3%)	

In brackets measurement unit; Data were reported as absolute value and percentage. \* Underline statistical significance

one dislocation (1/25 patients; 4%) were recorded. In Group B, one deep vein thrombosis (1/26 patients; 3%), three wound dehiscence (3/26 patients; 11%), one nerve paresis (1/26 patients; 3%), one aseptic loosening (1/26 patients; 3%) and four dislocations (4/26 patients; 15%) were recorded (Table 2).

Statistical difference was not noticed between the two groups regarding dislocation (1 vs 4;  $p = 0.15$ ) but grouping the surgical complication (1 vs 9;  $p = 0.005$ ) but not for clinical complication (3 vs 1;  $p = 0.2$ ).

All patients affected by infections were successfully treated by antimicrobial oral therapy with complete resolution, with no need of further surgery. Dislocation was treated by open reduction and implantation of acetabular bis mobility cup. Nerve injury was treated by orthopedic brace. Aseptic loosening needed an implant revision. Deep vein thrombosis was treated by anticoagulant therapy and evaluated at follow-up with a series of ultrasounds and doppler.

A multivariate model was performed matching gender, age, cementation and resection length regarding

**Table 3** Logistic regression of surgical complication

Descriptor	Odds ratio	95% Confidence interval	P
Age	1	0.9–1.1	0.3
Cementation	11	1.1–103.7	0.03*
Resection length	1	0.8–1.3	0.4

\* underline statistical significance

MSTS; only cementation confirms his statistical significance ( $p = 0.002$ ).

Regarding surgical complication a logistic regression was performed to analyze the odds ratio of age, cementation and length of resection; cementation confirm and odds ratio of 11 times in the incidence of surgical complications (Table 3).

## Discussion

Proximal femur is one of the most common bone metastases localization [3]. Often metastases develop subtly and give scarce signs of their presence and diagnosis is made when symptoms of pathological fracture are evident [24–26].

Endoprosthetic reconstruction is a widely used reconstructive technique in the treatment of proximal femur metastases [27]. This kind of surgery has implant-related complications, due to the large bone resections and soft tissue excision often needed to guarantee oncological radicality [10, 27–29].

The use of cemented or uncemented stems following megaprosthesis hip reconstruction is still matter of debate. Cemented stems surely guarantee immediate weight-bearing because the stem does not need osteointegration and cementation itself guarantees a better grip [9].

Bischel et al. in their paper demonstrate the validity and safety of uncemented stem positioning in metastatic femur [17, 30], while Griffin et al. stated how

cementless fixation may be advantageous because of bone ingrowth that may lead to very low aseptic loosening rate [28].

Moreover cementation needs longer surgical time that increased infection risk and in literature “bone cement implantation syndrome” was described, characterized by hypoxia, hypotension, cardiovascular collapse and an increased risk of pulmonary embolism [15, 16]. Lastly the presence of a cemented megaprosthesis could aggravate subsequent revision surgery.

We performed this retrospective study of metastatic patients treated with endoprosthetic reconstruction to evaluate the role of cementation on functionality and surgical complications onset.

Our result show how stem cementation positively affects patients’ functionality and restoring of daily activities compared to uncemented stems ( $24.2 \pm 5.2$  of the cemented group vs  $17.9 \pm 7.8$  of the uncemented one), while increases the surgical complications if compared to uncemented stems (9 vs 1 in the uncemented group).

The multivariate analysis in our study showed that cemented megaprotheses have functional better outcomes compared to the cementless. This result is in line with literature findings [30, 31], cementation allows immediate weight bearing and faster restoring of function. Angelini et al. showed in their study about cemented proximal femur replacements (PFR) that the mean MSTTS score in the post-operative period was 22.4 points, similar to our study findings in cemented group.

Ferrara et al. showed how also in uncemented PFR the MSTTS improves at 2 months post-operative controls and that these patients can improve their gait modalities and functional daily life outcomes until 3 months from surgery [32–34].

Another finding of this study is about complication rate. In the multivariate analysis cementation compared to age, sex, resection length appears to be the only variable influencing complications.

Dislocations represent another well know complication of hip megaprotheses in literature [35–38], we found it in this study. Prostheses dislocation are more frequent in cemented group compared to uncemented group. This can be related to the design of the prostheses, different in the two groups and to the presence of Trevira tube (only in cementless group). Literature data suggest that dislocation rate is 3–22% in this kind of surgery [9, 35–37, 39]. D’Adamo et al. in their study confirm the *in vitro* safety and efficacy, in terms of newly formed cells extension and adhesion pattern, of using an attachment tube made from Trevira fibers surrounding an oncological megaprosthesis [40, 41]. This factor could have improved the most anatomical reinsertion of remaining soft tissue following resection.

Furthermore, if Trevira Tube according to some authors can assure soft tissue adhesion [41], can on the other the other side impede a close reduction [17]. This means that dislocation in cases where Trevira tube has been used need an open reduction, and consequently a reintervention.

Also, infection rate is higher in cemented group compared to uncemented group. This result is in line with literature results [42]. Piccioli et al. involved 30 patients in their study about lower metastasis, but just 11 of them were treated for PFR [33]; in this case complications presented in 30% of the population with an infection rate of 16.7%. It is not specified if the proximal femurs were treated for primary tumor or metastatic disease and if complications occurred in PFR, due to the variously treated patients (total femur, proximal tibia, proximal humerus). Also, authors that used both techniques, cemented and cementless megaprotheses, presented delayed wound healing, infection and aseptic loosening. Pala is the only author that compares cemented and uncemented megaprotheses and reports that infections and aseptic loosening are higher in cemented megaprosthesis replacements [9, 43].

Besides Donati et al. reported in their study that silver coating of megaprotheses can decrease infection rate [44, 45], due to the release of silver ions, which produces a zone of growth inhibition for bacterial activities, and confirmed the protective role of silver coating in the first 6 months after surgery [10, 44, 45]. Cementless group in our study actually has been treated with silver-coated megaprotheses, and this can be considered a protective factor for the development of infections, which did develop as complication in cemented group.

In our study we reported one case of aseptic loosening in one patient with cemented stem. This result is confirmed by literature trend, in fact cementation seems to be a more frequent cause of aseptic loosening [46].

This study has some limitations, first its retrospective design and the examined population. Patients with femoral metastases in fact have a variable life expectancy [47, 48], that varies from weeks to years, and many patients die within 2 years after surgery [38, 49, 50]. Number and location of metastases, primitive tumor, presence of pathologic or impending fracture, age, can affect the prognosis [51–53]. Of course, the presence of pre-existing pathologies must be considered in the evolution of the prognosis, but these data are not disposable. All these data generate very large confidence intervals in an already small population. In light of these limitations, even in the presence of significant data, it is desirable in the future to prepare studies with the recruitment of more patients, so as to be able to carry out broader and more rigorous multivariate analyzes.



Another limit of the study is represented by the different prostheses used for limb reconstruction. Silver coating, as already said, literature agree to be a protection against early infection [33, 44, 54, 55]. Secondly, the presence of a different design to guarantee soft tissue adhesion: while Mutars (Implantcast) provides Trevira Tube to reattach tendons and muscular insertions, Megasystem C (LINK) provides pre-existing holes on the prostheses, through which tendons and muscles must be assured. This difference in design may play a role in dislocation onset.

Even if megaprotheses tend to dislocation because of the resection of muscular insertion and often the lack of capsular stability, there are also patient-related factors that can improve the onset of this condition, such as the presence of a coxa plana or the large soft tissue resection, which is not quantifiable. Both these factors have not been considered and/or reported for patients in cemented and cementless groups, and this represents another limit for the present study.

Despite the limitations, our study presents different strong points: first the considered population is screened for only proximal femur metastasis, differently from other studies in which also primary tumours or other bone locations were considered [9, 44]. All the patients underwent endoprosthetic replacement and reached a long-term follow-up of about 50 months. Only few studies in literature analysed functional outcomes like MSTs in proximal femur megaprosthesis replacement [3].

## Conclusions

Stem cementation in hip endoprosthetic reconstruction by megaprotheses in metastatic patients is still matter of debate. Whether cementation guarantees better functional results, it seems to be associated to higher complication rates. Future studies based on the use of the same kind of endoprosthetic implant have to be performed to confirm our results and to propose a universal guideline about the use of cemented or uncemented stems in tumoral endoprosthetic reconstructions.

## Abbreviations

PFR: proximal femur replacements; MSTs: Musculoskeletal Tumor Society scoring system.

## Supplementary Information

The online version contains supplementary material available at <https://doi.org/10.1186/s12891-022-05726-7>.

**Additional file 1: Supplementary Fig. 1.** Supplementary data reported with confidence interval. Follow-up reported in months, age in years old. Duration time of surgery in minutes. Resection length in cm. \* for statistical significance of  $p=0.001$ .

**Additional file 2: Supplementary Fig. 2.** Dispersion of the simple. Y-axis reported as log2 scale. Follow-up reported in months, age in years old. Duration time of surgery in minutes. Resection length in cm.

## Acknowledgements

None.

## About this supplement

This article has been published as part of BMC Musculoskeletal Disorders Volume 22 Supplement 2 2021: All about the hip. The full contents of the supplement are available at <https://bmc-musculoskeletal-disorders.biomedcentral.com/articles/supplements/volume-22-supplement-2>.

## Authors' contributions

G.M. and D.A.C. – design study. L.F. and C.M. and G.R. – data collecting. R.V. – data analysis. M.S.O. – preparing manuscript. F.M. and A. Z. – revising manuscript content. All authors have read and approved the final manuscript.

## Funding

Publication costs are funded by Orthopedic and Traumatology School of Università Cattolica del Sacro Cuore – Roma.

The funders did not play any role in the design of the study, the collection, analysis, and interpretation of data, or in writing of the manuscript.

## Availability of data and materials

The datasets used and/or analyzed during the current study are available from the corresponding author on reasonable request.

## Declarations

### Ethics approval and consent to participate

All procedures performed in the current study were in accordance with the 1964 Helsinki declaration and its later amendments. Written informed consent was obtained from all individual participants included in the study. The study design was approved by the Orthopedic and Traumatology Institute and School Council.

### Consent for publication

All patients signed an appropriate release to use their health and sensitive data and to be enrolled in the study.

### Competing interests

The authors declare no potential conflict of interest.

### Author details

<sup>1</sup>Fondazione Policlinico Universitario Agostino Gemelli – IRCCS, Largo Agostino Gemelli 8, 00168 Rome, Italy. <sup>2</sup>Università Cattolica Del Sacro Cuore, Rome, Italy. <sup>3</sup>Ortopedia Oncologica e Ricostruttiva Azienda Ospedaliera Universitaria Careggi, Florence, Italy.

Received: 1 August 2022 Accepted: 4 August 2022

Published online: 06 September 2022

## References

- Janssen SJ, Kortlever JTP, Ready JE, Raskin KA, Ferrone ML, Hornicek FJ, et al. Complications after surgical Management of Proximal Femoral Metastasis: a retrospective study of 417 patients. *J Am Acad Orthop Surg*. 2016;24:483–94.
- Capanna R, Piccioli A, Di Martino A, Daolio PA, Ippolito V, Maccauro G, et al. Management of long bone metastases: recommendations from the Italian Orthopaedic society bone metastasis study group. *Expert Rev Anticancer Ther*. 2014;14:1127–34.
- Guzik G. Oncological and functional results after surgical treatment of bone metastases at the proximal femur. *BMC Surg*. 2018;18:5.
- Spinelli MS, Ziranu A, Piccioli A, Maccauro G. Surgical treatment of acetabular metastasis. *Eur Rev Med Pharmacol Sci*. 2016;20(14):3005–10.

5. Piccioli A, Spinelli MS, Maccauro G. Impending fracture: a difficult diagnosis. *Injury*. 2014;45(Suppl 6):S138–41.
6. Perisano C, Scaramuzza L, De Santis V, Piccioli A, Ziranu A, Barone C, et al. Quality of life following surgical treatment of lower limb metastases in long bone. *J Biol Regul Homeost Agents*. 2015;29:501–7.
7. Calabrò T, Van Rooyen R, Piraino I, Pala E, Trovarelli G, Panagopoulos GN, et al. Reconstruction of the proximal femur with a modular resection prosthesis. *Eur J Orthop Surg Traumatol*. 2016;26:415–21.
8. Schmolders J, Koob S, Schepers P, Pennekamp PH, Gravius S, Wirtz DC, et al. Lower limb reconstruction in tumor patients using modular silver-coated megaprotheses with regard to perimegaprosthesis joint infection: a case series, including 100 patients and review of the literature. *Arch Orthop Trauma Surg*. 2017;137:149–53.
9. Pala E, Mavrogenis AF, Angelini A, Henderson ER, Douglas Letson G, Ruggieri P. Cemented versus cementless endoprostheses for lower limb salvage surgery. *J BUON*. 2013;18:496–503.
10. Gosheger G, Gebert C, Ahrens H, Streibuerger A, Winkelmann W, Harges J. Endoprosthetic reconstruction in 250 patients with sarcoma. *Clin Orthop Relat Res*. 2006;450:164–71.
11. Ahlmann ER, Menendez LR, Kermani C, Gotha H. Survivorship and clinical outcome of modular endoprosthetic reconstruction for neoplastic disease of the lower limb. *J Bone Joint Surg Br*. 2006;88:790–5.
12. Maccauro G, Cittadini A, Casarci M, Muratori F, De Angelis D, Piconi C, et al. Methotrexate-added acrylic cement: biological and physical properties. *J Mater Sci Mater Med*. 2007;18:839–44.
13. Rosa MA, Maccauro G, Sgambato A, Ardito R, Falcone G, De Santis V, et al. Acrylic cement added with antiblastics in the treatment of bone metastases. ultrastructural and in vitro analysis. *J Bone Joint Surg Br*. 2003;85:712–6.
14. Cheng H, Chen BP-H, Soleas IM, Ferko NC, Cameron CG, Hinoul P. Prolonged operative duration increases risk of surgical site infections: a systematic review. *Surg Infect (Larchmt)*. 2017;18:722–35.
15. Yang T-H, Yang R-S, Lin C-P, Tseng T-H. Bone cement implantation syndrome in bone tumor surgeries: incidence, risk factors, and clinical experience. *Orthop Surg*. 2021;13:109–15.
16. Hines CB. Understanding bone cement implantation syndrome. *AANA J*. 2018;86:433–41.
17. Bisichel OE, Suda AJ, Böhm PM, Lehner B, Bitsch RG, Seeger JB. En-bloc resection of metastases of the proximal femur and reconstruction by modular arthroplasty is not only justified in patients with a curative treatment option—an observational study of a consecutive series of 45 patients. *J Clin Med*. 2020;9(3):758.
18. Ziranu A, Lillo M, Fantoni M, Maffulli N, Maccauro G. Single dose cefazolin is safe and effective for pre-operative prophylaxis in orthopaedic oncology. *J Biol Regul Homeost Agents*. 2018;32(6 Suppl. 1):45–9.
19. Mutars femore. <http://taliafarma.com/wp-content/uploads/2017/10/MUTARS-Proximal-Femur.pdf>. Accessed 4 Sept 2021.
20. [https://linknederland.nl/\\_cache/link/media/kwasi94816/Link\\_Nederland\\_Mega\\_C\\_Implantaten\\_amp\\_instrumenten\\_amp\\_operatiectechniek\\_09\\_2019.pdf?hash=ed2ca4d74c1d605c](https://linknederland.nl/_cache/link/media/kwasi94816/Link_Nederland_Mega_C_Implantaten_amp_instrumenten_amp_operatiectechniek_09_2019.pdf?hash=ed2ca4d74c1d605c). Accessed 4 Sept 2021.
21. Horan TC, Andrus M, Dudeck MA. CDC/NHSN surveillance definition of health care-associated infection and criteria for specific types of infections in the acute care setting. *Am J Infect Control*. 2008;36:309–32.
22. Enneking WF, Dunham W, Gebhardt MC, Malawar M, Pritchard DJ. A system for the functional evaluation of reconstructive procedures after surgical treatment of tumors of the musculoskeletal system. *Clin Orthop Relat Res*. 1993;(286):241–6.
23. Mirels H. Metastatic disease in long bones: a proposed scoring system for diagnosing impending pathologic fractures. 1989. *Clin Orthop Relat Res*. 2003;415 Suppl:S4–13.
24. Hage WD, Abouafia AJ, Abouafia DM. Incidence, location, and diagnostic evaluation of metastatic bone disease. *Orthop Clin North Am*. 2000;31(515–28):vii.
25. Sherry HS, Levy RN, Siffert RS. Metastatic disease of bone in orthopedic surgery. *Clin Orthop Relat Res*. 1982;44–52.
26. Riccio AI, Wodajo FM, Malawar M. Metastatic carcinoma of the long bones. *Am Fam Physician*. 2007;76:1489–94.
27. Mittermayer F, Krepler P, Dominkus M, Schwameis E, Sluga M, Heinzl H, et al. Long-term followup of uncemented tumor endoprostheses for the lower extremity. *Clin Orthop Relat Res*. 2001:167–77.
28. Griffin AM, Parsons JA, Davis AM, Bell RS, Wunder JS. Uncemented tumor endoprostheses at the knee: root causes of failure. *Clin Orthop Relat Res*. 2005;438:71–9.
29. Sim I-W, Tse LF, Ek ET, Powell GJ, Choong PFM. Salvaging the limb salvage: management of complications following endoprosthetic reconstruction for tumours around the knee. *Eur J Surg Oncol*. 2007;33:796–802.
30. Bisichel OE, Böhm PM. The use of a femoral revision stem in the treatment of primary or secondary bone tumours of the proximal femur: a prospective study of 31 cases. *J Bone Joint Surg Br*. 2010;92:1435–41.
31. Potter BK, Chow VE, Adams SC, Letson GD, Temple HT. Endoprosthetic proximal femur replacement: metastatic versus primary tumors. *Surg Oncol*. 2009;18:343–9.
32. Xix Congresso Nazionale S.I.C.O.O.P. Societa' Italiana Chirurghi Ortopedici Dell'Ospedality Privata Accreditata, Ferrara PE, Salini S, Amabile E, Nigito C, Ferriero C, et al. Functional outcome and multidimensional evaluation of patients with Mutars® reconstructions post lower limb tumor resection and rehabilitation: preliminary results. *J Biol Regul Homeost Agents*. 2019;33(2 Suppl. 1):155–61.
33. Piccioli A, Donati F, Giacomo GD, Ziranu A, Careri S, Spinelli MS, et al. Infective complications in tumour endoprostheses implanted after pathological fracture of the limbs. *Injury*. 2016;47:S22–8.
34. Vitiello R, Bellieni A, Oliva MS, Di Capua B, Fusco D, Careri S, et al. The importance of geriatric and surgical co-management of elderly in musculoskeletal oncology: a literature review. *Orthop Rev (Pavia)*. 2020;12(Suppl 1):8662.
35. Steensma M, Boland PJ, Morris CD, Athanasian E, Healey JH. Endoprosthetic treatment is more durable for pathologic proximal femur fractures. *Clin Orthop Relat Res*. 2012;470:920–6.
36. Harvey N, Ahlmann ER, Allison DC, Wang L, Menendez LR. Endoprostheses last longer than intramedullary devices in proximal femur metastases. *Clin Orthop Relat Res*. 2012;470:684–91.
37. Houdek MT, Wyles CC, Labott JR, Rose PS, Taunton MJ, Sim FH. Durability of hemiarthroplasty for pathologic proximal femur fractures. *J Arthroplast*. 2017;32:3607–10.
38. Ruggieri P, Mavrogenis AF, Casadei R, Errani C, Angelini A, Calabrò T, et al. Protocol of surgical treatment of long bone pathological fractures. *Injury*. 2010;41:1161–7.
39. Angelini A, Trovarelli G, Berizzi A, Pala E, Breda A, Maraldi M, et al. Treatment of pathologic fractures of the proximal femur. *Injury*. 2018;49:577–83.
40. D'Adamo S, Ziranu A, Cazzato G, Sanguinetti M, Manicone PF, Rosa MA, et al. Antifungal properties of silver coating on tumour endoprostheses: an in vitro study. *Eur Rev Med Pharmacol Sci*. 2019;23(2 Suppl):252–7.
41. D'Adamo S, Cazzato G, Ziranu A, Sgambato A, Rosa MA, Maccauro G. Soft tissue adhesion patterns over Trevira tube on modular endoprosthesis for malignant bone tumours: an in vitro study. *J Biol Regul Homeost Agents*. 2017;31(4 suppl 1):37–42.
42. Graci C, Maccauro G, Muratori F, Spinelli MS, Rosa MA, Fabbriani C. Infection following bone tumor resection and reconstruction with tumoral prostheses: a literature review. *Int J Immunopathol Pharmacol*. 2010;23:1005–13.
43. Oliva MS, Vitiello R, Cauteruccio M, Pesare E, Rovere G, Meschini C, et al. Cemented versus cementless megaprosthesis in proximal femur metastatic disease: a systematic review. *Orthop Rev (Pavia)*. 2020;12(Suppl 1):8689.
44. Donati F, Di Giacomo G, D'Adamo S, Ziranu A, Careri S, Ma R, et al. Silver-coated hip Megaprosthesis in oncological limb salvage surgery. *Biomed Res Int*. 2016;20:1–6.
45. Donati F, Di Giacomo G, Ziranu A, Spinelli S, Perisano C, Rosa MA, et al. Silver coated prosthesis in oncological limb salvage surgery reduce the infection rate. *J Biol Regul Homeost Agents*. 2015;29(4 Suppl):149–55.
46. Meding JB, Ritter MA, Davis KE, Hillery M. Cemented and uncemented total hip arthroplasty using the same femoral component. *Hip Int*. 2016;26:62–6.
47. Mavrogenis AF, Pala E, Romagnoli C, Romantini M, Calabro T, Ruggieri P. Survival analysis of patients with femoral metastases. *J Surg Oncol*. 2012;105:135–41.
48. Piccioli A, Spinelli MS, Forsberg JA, Wedin R, Healey JH, Ippolito V, et al. How do we estimate survival? External validation of a tool for survival estimation in patients with metastatic bone disease—decision analysis

and comparison of three international patient populations. *BMC Cancer*. 2015;15:424.

49. Lane JM, Sculco TP, Zolan S. Treatment of pathological fractures of the hip by endoprosthetic replacement. *J Bone Joint Surg Am*. 1980;62:954–9.
50. Ward WG, Spang J, Howe D. Metastatic disease of the femur. Surgical management. *Orthop Clin North Am*. 2000;31:633–45.
51. Errani C, Mavrogenis AF, Cevolani L, Spinelli S, Piccioli A, Maccauro G, et al. Treatment for long bone metastases based on a systematic literature review. *Eur J Orthop Surg Traumatol*. 2017;27:205–11.
52. Schneiderbauer MM, von Knoch M, Schleck CD, Harmsen WS, Sim FH, Scully SP. Patient survival after hip arthroplasty for metastatic disease of the hip. *J Bone Joint Surg Am*. 2004;86:1684–9.
53. Ampil FL, Sadasivan KK. Prophylactic and therapeutic fixation of weight-bearing long bones with metastatic cancer. *South Med J*. 2001;94:394–6.
54. Xix Congresso Nazionale S.I.C.O.O.P. Società Italiana Chirurghi Ortopedici Dell'Ospedalita' Privata Accreditata, Oliva MS, Masci G, Vitiello R, De Santis V, Liuzza F, et al. Hip megaprosthesis in oncological surgery: open questions. *J Biol Regul Homeost Agents*. 2019;33(2 Suppl. 1):45–9.
55. El Ezzo O, Oliva MS, Cauteruccio M, Saracco M, Vitiello R, Maccauro G, et al. Innovations in prevention of infections in oncological megaprotheses: a narrative review. *J Biol Regul Homeost Agents*. 2020;34(4 Suppl. 3):275–8 Congress of the Italian Orthopaedic Research Society.

### Publisher's Note

Springer Nature remains neutral with regard to jurisdictional claims in published maps and institutional affiliations.

Ready to submit your research? Choose BMC and benefit from:

- fast, convenient online submission
- thorough peer review by experienced researchers in your field
- rapid publication on acceptance
- support for research data, including large and complex data types
- gold Open Access which fosters wider collaboration and increased citations
- maximum visibility for your research: over 100M website views per year

At BMC, research is always in progress.

Learn more [biomedcentral.com/submissions](https://biomedcentral.com/submissions)

