

# Percutaneous repair of iatrogenic subclavian artery injury by suture-mediated closure device

Rahul S Chivate, Suyash S Kulkarni, Nitin S Shetty, Ashwin M Polnaya, Kunal B Gala, Paresh G Patel

Department of Radiology/Interventional Radiology, Tata Memorial Hospital, Mumbai, Maharashtra, India

**Correspondence:** Dr. Suyash S Kulkarni, Department of Radiology/Interventional Radiology, Tata Memorial Hospital, Dr. E. Borges Road, Parel Mumbai - 400 012, Maharashtra, India. E-mail: suyashkulkarni@yahoo.com

## Abstract

Central venous catheterization through internal jugular vein is done routinely in intensive care units. It is generally safe, more so when the procedure is performed under ultrasound guidance. However, there could be inadvertent puncture of other vessels in the neck when the procedure is not performed under real-time sonographic guidance. Closure of this vessel opening can pose a challenge if it is an artery, in a location difficult to compress, and is further complicated by deranged coagulation profile. Here, we discuss the removal of an inadvertently placed catheter from subclavian artery with closure of arteriotomy percutaneously using arterial suture-mediated closure device.

**Key words:** Inadvertent puncture; percutaneous suture device; subclavian artery

## Introduction

Central venous catheterization is done routinely in intensive care units and involves the placement of a catheter through internal jugular vein. Although the procedure can be performed blindly at the bedside, safety of this procedure increases considerably when access is taken using real-time ultrasound guidance. However, unfortunate events can occur such as puncture and placement of the catheter in the left subclavian artery, as in this case. This report demonstrates removal of the catheter from the subclavian artery along with the closure of puncture site with the help of percutaneous arterial suture device. Few cases have been reported using this device.

## Case History

A 46-year-old obese lady who was operated for carcinoma breast developed cardiogenic shock while undergoing chemotherapy and was shifted to the intensive care unit for management. Her blood parameters showed hemoglobin 8.0 mg/dl, platelet count of 52000/L, and International Normalized Ratio (INR) of 1.2. A 7Fr triple lumen central venous catheter (Arrow, Teleflex Inc, USA) was placed through the left internal jugular vein under ultrasound guidance. Although percutaneous entry point was identified on sonography, venous puncture was not monitored real-time and the back flow of blood was used to confirm the entry of needle into the vein. However, anesthesiologist

### Access this article online

#### Quick Response Code:



Website:  
www.ijri.org

DOI:  
10.4103/0971-3026.184425

This is an open access article distributed under the terms of the Creative Commons Attribution-NonCommercial-ShareAlike 3.0 License, which allows others to remix, tweak, and build upon the work non-commercially, as long as the author is credited and the new creations are licensed under the identical terms.

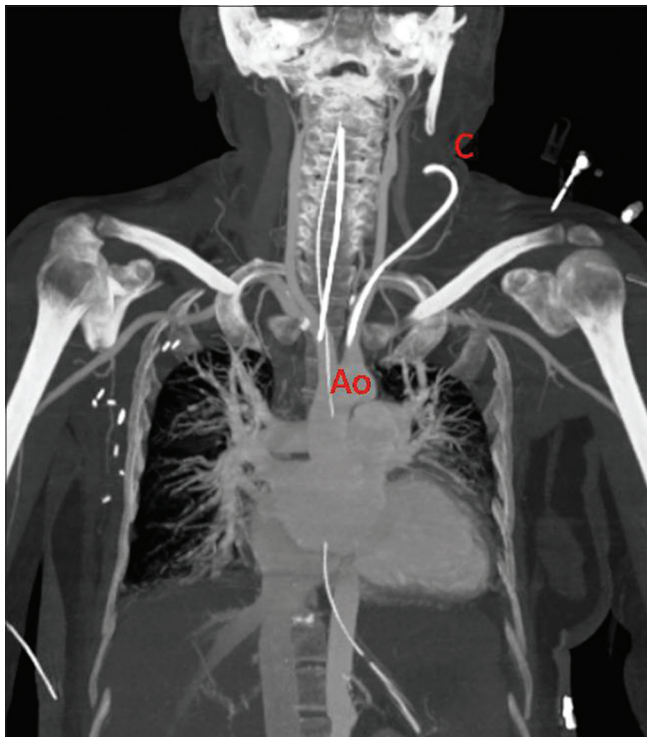
**For reprints contact:** reprints@medknow.com

**Cite this article as:** Chivate RS, Kulkarni SS, Shetty NS, Polnaya AM, Gala KB, Patel PG. Percutaneous repair of iatrogenic subclavian artery injury by suture-mediated closure device. Indian J Radiol Imaging 2016;26:262-6.

noted that tracing from the catheter was arterial, which was further confirmed by blood gas analysis. Catheter was immediately clamped and reference was given to interventional radiology for access site management.

Bedside ultrasonography color Doppler of the neck was performed because there was a suspicion of accidental placement of catheter in carotid artery or iatrogenic caroticojugular fistula. Sonoimaging was suboptimal because of the obese neck, hematoma, and overlying dressing. Catheter was not seen intraluminally in the visualized portion of the internal jugular vein. However, Doppler showed normal flow and waveform in the left carotid artery and jugular vein. Left subclavian and vertebral arteries were not visualized.

Computed tomography (CT) angiography was performed to identify the location of the catheter tip and to know the status of vessels in the neck. It showed that the catheter had brushed along the wall of the left internal jugular vein without puncturing it and had entered the subclavian artery just distal to the origin of the left vertebral artery and its tip was seen at the origin of the left subclavian artery. No pseudoaneurysm was seen at the arterial puncture site. Carotid artery, vertebral artery, internal jugular vein, and subclavian artery distal to puncture site were normal [Figure 1]. The puncture site was more than 1.0 cm away from the origin of vertebral artery and 7.0 cm from the skin surface.

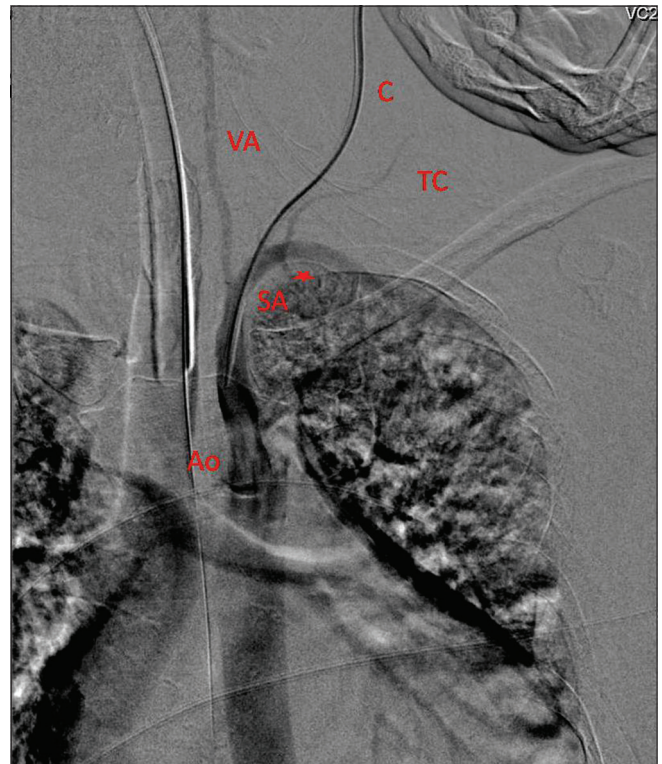


**Figure 1:** Computed tomography angiography with coronal reconstructed image shows placement of catheter tip in subclavian artery. Ao - Aorta, C- Catheter

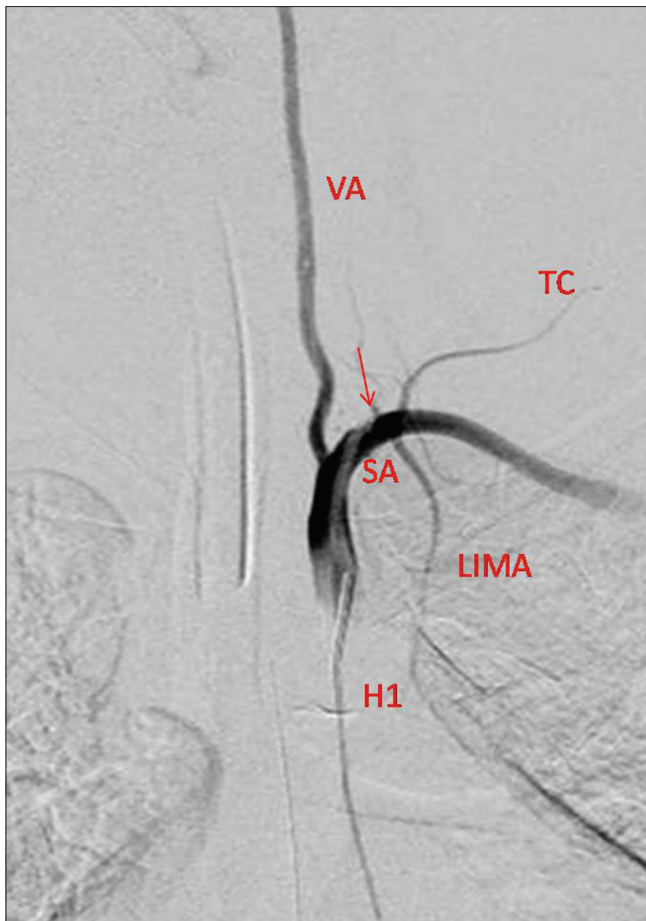
In view of low platelet count and inaccessible location of arterial puncture site for manual compression, it was decided to close the puncture site by mechanical device. Because the use of this device was unconventional for subclavian arteriotomy, we planned to have a femoral access also for endovascular salvage procedure in any event of failure to close by percutaneous route.

In the interventional radiology suite, angiogram was performed through the catheter to confirm its patency and intraluminal location [Figure 2]. Using 4Fr H1 head hunter catheter (Tempo, Cordis Corp, Miami, FL, USA), subclavian angiogram done through transfemoral access revealed a small dissection flap close to the entry site of the catheter [Figure 3]. No thrombus was seen around the catheter and antegrade flow was normal with no filling defect in distal arteries till the palmar arch. There was no active contrast extravasation, pseudoaneurysm, or arteriovenous fistula at the puncture site.

Perclose ProGlide Suture Mediated Closure (SMC) System (Abbott Laboratories, Illinois, USA) is generally used for closing common femoral artery puncture site, and the instruction manual states that this device should not be used if the puncture site is located less than 1.0 cm



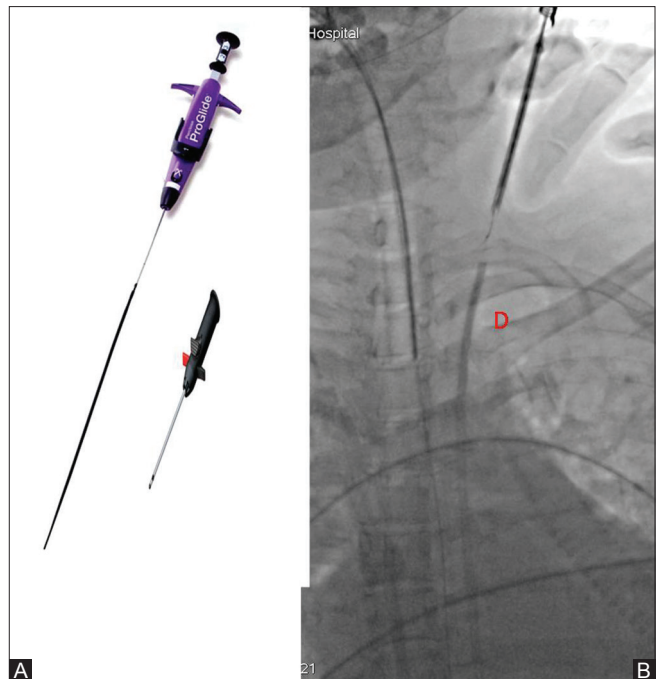
**Figure 2:** Digital subtraction angiography image of contrast injected through catheter confirms its tip in subclavian artery. C - Catheter, SA - Subclavian artery, VA - Vertebral artery, Ao - Aorta, TC - Thyrocervical trunk, \*Left internal mammary artery



**Figure 3:** Subclavian artery angiography performed using H1 catheter shows subtracted catheter tip between vertebral artery and internal mammary artery. Small suspicious filling defect seen at the puncture site (arrow). SA - Subclavian artery, VA - Vertebral artery, TC - Thyrocervical trunk, LIMA - Left internal mammary artery, H1 - Head hunter catheter H1 4Fr

close to the bifurcation of vessels or close to the origin of major branch because such puncture sites may result in a pseudoaneurysm, intimal dissection, or an acute vessel closure (thrombosis of small artery lumen).

A 0.035" angled Amplatz stiff wire (Cook Medical, Bloomington, IN, USA) was passed through the central venous catheter and was placed across descending aorta. Catheter was exchanged with 6Fr percutaneous suture closing device, Perclose ProGlide Suture Mediated Closure System (Abbott Laboratories, IL, USA) [Figure 4A and B]. Before placement, soft tissue from skin to artery was adequately dilated for smooth passage of this device. Suture was deployed with wire still *in situ* and the knot was tightened with the help of knot pusher. At this time, angiography was performed to confirm the adequate sealing of the rent [Figure 5]. Wire was removed and compression was continued with the help of knot pusher of this device. The suture was cut after confirming that there was no contrast extravasation or aneurysm at the



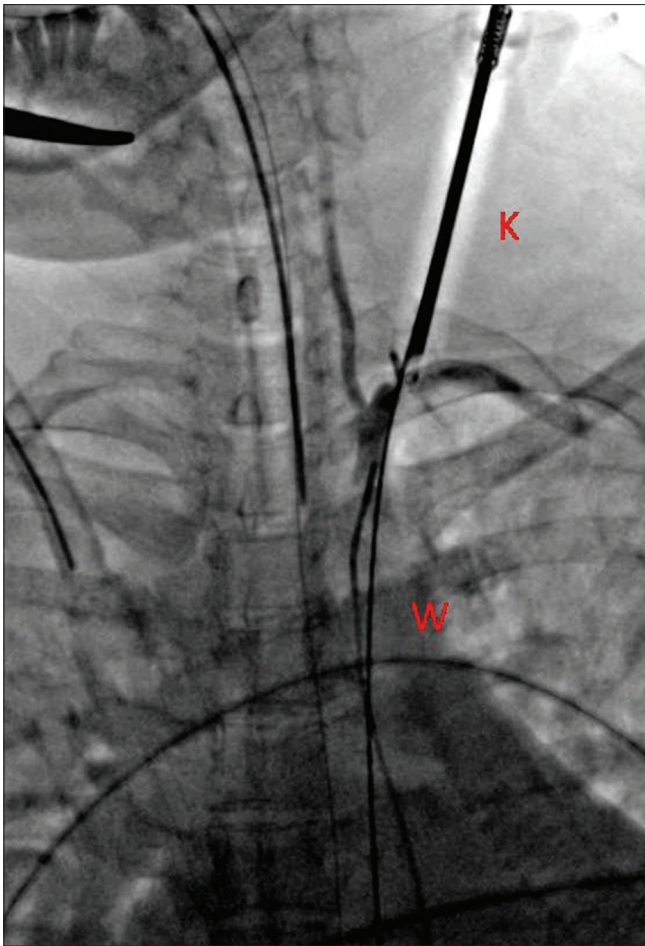
**Figure 4 (A and B):** (A) 6 Fr. Perclose ProGlide Suture Mediated Closure System (Abbott); (B) Radiographic image of device (D) over wire

arteriotomy site [Figure 6]. Check angiography of cerebral and left upper limb arteries was done to rule out embolic phenomena, dissection, or thrombus formation. A small filling defect was seen at the site of the closure with mild luminal narrowing possibly due to dissection or small thrombus. Patient was started on low molecular weight heparin which was continued for a week to prevent any thromboembolic phenomena. Check ultrasound after 2 and 6 h of procedure revealed no hematoma at the puncture site and normal Doppler waveforms in subclavian and distal arteries. A CT angiogram done 1 week after the closure showed normal caliber of artery with no thrombus or dissection at the closure site [Figure 7].

## Discussion

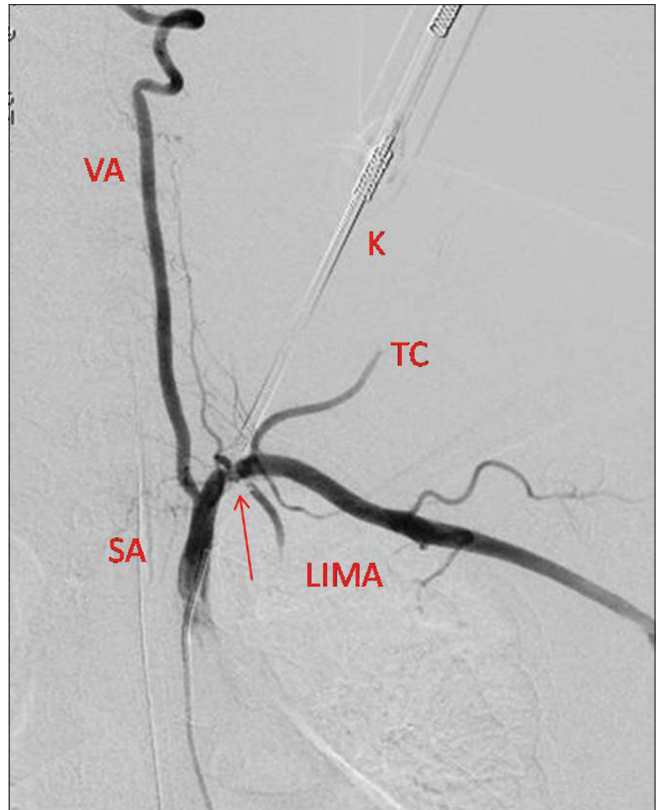
Accidental arterial puncture occurs in 1% and 2.7% of jugular and subclavian venous approaches.<sup>[1,2]</sup> When an artery is punctured at a compressible site, catheter can be easily removed and hemostasis can be achieved by manual compression. We could successfully close the accidental puncture of subclavian artery using suture-mediated closure device. We also stress that the safety of placing jugular vein catheters can be increased by performing the procedure using real-time sonographic guidance. Before inserting the needle, distance from the skin surface to the vessel wall should be measured. If the jugular vein is not punctured at the measured distance, effort should be made to check the tip of the needle before advancing it. In addition, ultrasound training of a nonradiologist who is performing the procedure at the bedside is a must to avoid





**Figure 5:** Perclose device removed and knot tightened with the help of knot tightener. Wire still kept *in situ*. W - 0.035" Amplatz stiff wire, K - Knot tightener

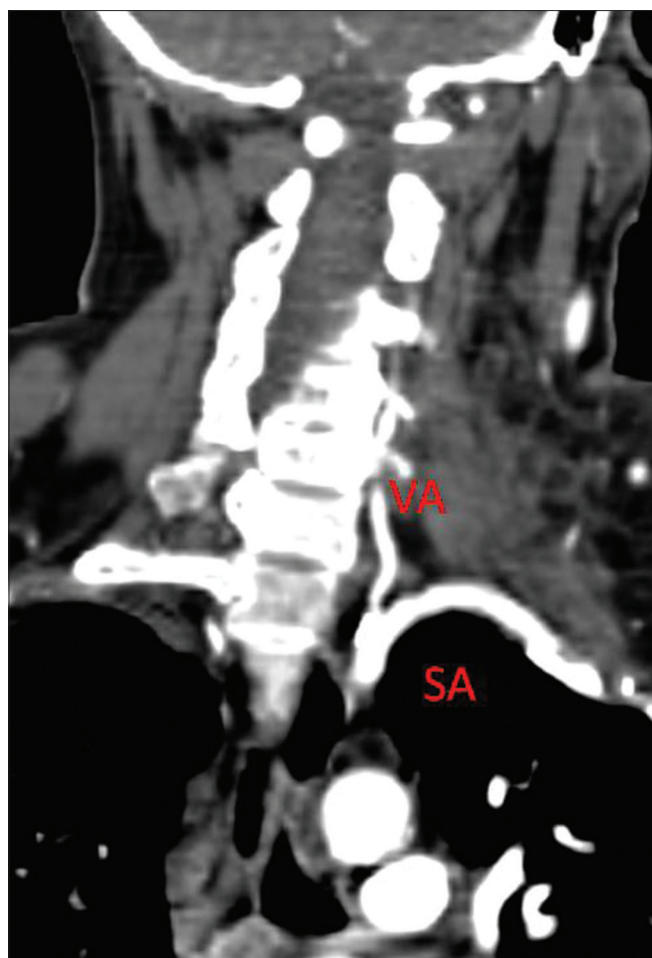complications. Because the subclavian artery lies deep within the soft tissue and behind the clavicle at a noncompressible site, it is difficult to achieve hemostasis with a high risk of developing hematoma or pseudoaneurysm. Inadvertent subclavian artery punctures could be treated with surgery such as sternotomy or thoracotomy, which would lead to significant morbidity.<sup>[3]</sup> Placement of endovascular stent graft from ipsilateral axillary artery or femoral artery can be performed. However, there is risk of occlusion of vertebral artery, stent stenosis, stent fracture, stent thrombosis, and thromboembolic phenomena; the patients would have to be on antiplatelets life-long to keep the stent patent. A good and easy alternative is percutaneous arterial closure devices that are often used for the closure of common femoral artery puncture site closure. Various devices such as ProGlide PerClose, and Angioseal are available and have been used in similar situations previously, as described in the literature. In our case, we selected Perclose ProGlide (SMC) system as vascular access can still be maintained in an unfortunate event of failure to deploy suture or if the course is unfavorable. The entire system can be removed



**Figure 6:** Subclavian artery angiogram shows no extravasation of contrast. Small filling defect (arrow) seen close to puncture site could be thrombus or dissection flap. SA - Subclavian artery, VA - Vertebral artery, TC - Thyrocervical trunk, LIMA - Left internal mammary artery, K - Knot tightener

over a wire and vascular sheath can be introduced, which would temporarily seal the arteriotomy site until alternate treatment is performed.

Possible complications associated with these devices are infection, arteriovenous fistula formation, pseudoaneurysm, and bleeding. Serious complication such as limb ischemia may occur due to embolization, thrombosis, and occlusion of vessel by the device itself which requires surgical intervention.<sup>[3-5]</sup> However, percutaneous suture device (Perclose) technique has an almost 99% of success rate for repair of femoral artery after catheterization with 12-16Fr catheters and less than 2% for late complications.<sup>[6]</sup> Failure of this technique was observed by Pikwer *et al.* which was caused by angulation and obesity.<sup>[7]</sup> For Perclose ProGlide (SMC) IFU, the angle at which the device should be inserted for femoral artery puncture site should not be more than 45°. We inserted this system over wire and it was monitored real-time under fluoroscopy to avoid kinks and undue angulations. Distance from the skin surface to puncture was measured and knot pusher was optimally inserted again under real-time fluoroscopy to ensure its straight course. There are various studies reporting the successful use of this device in subclavian artery injury.<sup>[8,9]</sup>



**Figure 7:** Postprocedure reformatted image of computed tomography angiography shows patent left subclavian artery. No thrombus or dissection flap seen. VA - Vertebral artery

## Conclusion

Inadvertent arterial punctures can be comfortably avoided by using real-time ultrasound guidance by a trained

professional. Accidental subclavian artery puncture during central venous catheterization is an uncommon situation, but can be effectively managed by using percutaneous vascular closure device, and should be considered before morbid surgery and stenting.

## Financial support and sponsorship

Nil.

## Conflicts of interest

There are no conflicts of interest.

## References

1. Eisen LA, Narasimhan M, Berger JS, Mayo PH, Rosen MJ, Schneider RF. Mechanical complications of central venous catheters. *J Intensive Care Med* 2006;21:40-6.
2. Iovino F, Pittiruti M, Buononato M, Lo Schiavo F. Central venous catheterization: Complications of different placements. *Ann Chir* 2002;126:1001-6.
3. Szkup PL. A minimally invasive technique for closing an iatrogenic subclavian artery cannulation using the Angio-Seal closure device: Two case reports. *J Med Case Rep* 2012;6:82.
4. Witz M, Yahel J, Lehmann J. Subclavian artery aneurysms. A report of 2 cases and a review of the literature. *J Cardiovasc Surg* 1998;39:429-32.
5. Burbridge B, Stoneham G, Szkup P. Percutaneous subclavian artery stent-graft placement following failed ultrasound guided subclavian venous access. *BMC Med Imaging* 2007;6:3.
6. Lee WA, Brown MP, Nelson PR, Huber TS, Seeger JM. Midterm outcomes of femoral arteries after percutaneous endovascular aortic repair using the Perclose technique. *J Vasc Surg* 2008;47:919-23.
7. Pikwer A, Acosta S, Kolbel T, Malina M, Sonesson B, Akeson J. Management of inadvertent arterial catheterization associated with central venous access procedures. *Eur J Vasc Endovasc Surg* 2009;38:707-14.
8. Wallace MJ, Ahrar K. Percutaneous closure of subclavian artery injury after inadvertent catheterization. *J Vasc Interv Radiol* 2001;12:1227-30.
9. Shetty SV, Kwolek CJ, Garasic JM. Percutaneous closure after inadvertent subclavian artery cannulation. *Catheter Cardiovasc Interv* 2007;69:1050-2.