



The role of computed tomography and Glasgow Coma Scale in detecting spinal injury associated with traumatic brain injuries

Fadia Abdul-Ameer Merza¹, Ghazwan Alwan Lafta²

1) Department of Emergency Medicine, Al-Hussain Medical City, Karbala, Iraq

2) Department of Neurosurgery, Faculty of Medicine, University of Al-Ameed, Karbala, Iraq

Abstract

Objectives. The aim of this study is to identify the role of computed tomography scan (CT scan) of the cervical spine and Glasgow Coma Scale (GCS) in detecting spinal injuries associated with head injury.

Methods. This cross sectional study was conducted in the emergency department of Baghdad teaching hospital prospectively from October 2016 to October 2017. A total of 469 patients were included in this study, 59 of them with spine injury. All patients were examined promptly and were treated accordingly; all were subjected to X-rays and CT-scan of the skull and cervical spine for evaluation of head and cervical spinal injury, respectively.

Results. A total of 469 patients were enrolled in this study, mean age of 42.6 ± 13.7 years. The majority of patients were male (383/469) representing 81.7%. There was a significant correlation between Severity of TBI and cervical injury ($P < 0.001$). There was a significant association between cervical injury and the presence of clinical and radiographic findings and associated injuries ($P < 0.001$). It was found that cervical injury was more frequent in patients who were exposed to fall from a height.

Conclusion. CT scan and Glasgow coma scale are highly specific, sensitive, and accurate, with positive and negative predictive values.

Keywords: CT scan, Glasgow Coma Scale, cervical spine injury, fall from height, traumatic brain injury

Introduction

Traumatic brain injury (TBI) is the dysfunction of the brain resulting from external forces [1]. The pathology ranges from transient changes in ionic concentrations of cells to permanent structural damage, therefore the clinical symptoms may vary from short period of confusion to loss of consciousness and death [2]. TBI is classified according to the severity of injury and the conscious level. Glasgow Coma Scale (GCS) is the dependable classification system with a score ranging from 3-15, dividing TBI into mild (14 to 15), moderate (9 to 13), and severe (3 to 8) [3,4].

The presence of a TBI can delay cervical spine injury (SCI) recovery

and because the head trauma itself often warrants clinical care [5-7]. The severity of the head injury tends to positively correlate with the likelihood of a spine injury. The chance of associated spine injuries is raised in patients with moderate or severe head injury [8,9].

Cervical spine injuries are still a major cause of disability although their diagnosis and treatment have become more advanced and standardized over the past three decades, however, it is essential to focus knowledge about location, type of injury and associations [10]. Traumatic spinal cord injury is most frequently associated with vehicle crashes (42%), falls (27%), violence, primarily, gunshot wounds (15%), sports (8%) and other

DOI: 10.15386/mpr-2117

Manuscript received: 18.03.2021

Received in revised form: 15.05.2021

Accepted: 31.05.2021

Address for correspondence:
ghazwan_altayy@yahoo.com

This work is licensed under a Creative Commons Attribution-NonCommercial-NoDerivatives 4.0 International License

mechanisms (8%) [11]. It is important to consider any multiple injured patient to have cervical injury until proven otherwise, so that the emergency doctor should concentrate on his job regarding how to deal with such cases to minimize disability and death [12]. The utility of imaging of the cervical spine in patients who are alert, oriented, and have no neck or back pain or tenderness is negligible. One clinical decision rule has been defined, to avoid unnecessary radiography. These rules are intended for alert, stable adult trauma patients who have no neurologic deficits. Conventional radiography is limited as a result of the nature of equipment, difficulties in positioning, lack of patient cooperation, and the often-critical status of trauma patients. The incidence of an inadequate lateral cervical view, specifically visualization of C7 to T1, is as high as 25% [13]. The CT scan effectively deals with these limitations and in many cases it is the technique of choice for the definitive evaluation of acute cervical spine trauma [14-17]. CT scan also permits examination without moving the patient from the supine position and is thus preferable in terms of fracture stabilization, airway control, and other life-support measures. In fact, practice guidelines from the Eastern Association for the Surgery of Trauma (EAST) recommend that CT from the occiput to T1 be used as the primary screening method in blunt cervical trauma patients [18].

The aim of our study is to assess the role of CT scan and GCS in identifying cervical spine injuries in patients suffering from traumatic brain injuries.

Patients and method

Study design

It is a prospective cross sectional study including 59 patients with cervical spine injury out of 469 adult patients with a history of traumatic brain injury.

Data collection

The patients were received and treated at the surgical emergency department of Baghdad teaching hospital from the 1st of October 2016 to the 30th of October 2017.

The informed consent was taken from all patients, while for unconscious patients the consent was taken from their first degree relatives.

Patients

The TBI patients presented to emergency department

were rapidly assessed and resuscitated, then stabilized. The assessment of the patient's neurological status was carried out by doing full neurological examination. Focusing on GCS for all patients was at the top of priorities. The TBI was considered mild if GCS was 13-15) moderate if GCS was 9-12, while severe if GCS was 3-8 [3]. A checking for a probability of cervical injury was done by obtaining cervical spine x-ray and CT scan once the clinical decision was taken. To avoid unnecessary exposure to radiation, alert, stable adult trauma patients who had no neurological deficits were ruled out. Conservative treatment was decided for patients with cervical spine injury on the assumption that there was no neural compression requiring operative relief; however, cervical collar, skull traction, bed rest and analgesia were initiated. Laminectomy was done for patients with symptoms and signs of neural compression documented by CT scan and magnetic resonance image (MRI) with different pathologies like fracture, hematoma. Post operatively, an external support of cervical collar for patients with laminectomy was established.

Statistical analysis

The patients' data were analyzed using the statistical package for social sciences (SPSS) software for windows, version 24. Prior to analysis all data were checked for possible errors and inconsistency. Descriptive statistics presented as frequencies (No.), proportions (%), mean and standard deviation. Variables were checked for normal distribution and parametric tests were used for analysis and assessment of significance. Level of significance was set at ≤ 0.05 . Finally, findings were presented in tables and figures with an explanatory paragraph for each table or figure using the Microsoft Office (Word 2013) for windows.

Results

A total number of 469 patients were included in our study, the mean age of 42.6 ± 13.7 years. The vast majority of the patients were males (383/469), which represented 81.7%. The male to female ratio was 4.45 to 1. Regarding to the severity of injury, 241 patients (51.4%) had mild traumatic brain injury, 99 (21.1%) moderate and 129 (27.5%) had severe TBI. There is a significant correlation between Severity of TBI and cervical injury ($P < 0.001$) (Table I).

Table I. Relationship between severity of traumatic brain injury and cervical injury.

Cervical injury	Traumatic brain injury type						Total	
	Mild		Moderate		Severe			
	No.	%	No.	%	No.	%	No.	%
Yes	6	10.2	24	40.7	29	49.2	59	12.6
No	235	57.3	75	18.3	100	24.4	410	87.4
Total	241	51.4	99	21.1	129	27.5	469	100.0

Chi square test is significant at $P < 0.001$.

The level of cervical injury among the 59 patients revealed that 24 patients had injuries in lower cervical levels (40.7%), 17 patients had upper levels injuries (28.8%), while 18 patients had combined injuries (30.5%). It was significantly found that patients with combined level cervical injuries were more likely to have severe TBI ($P<0.001$) (Table II). The presentation and the findings of clinical examination of the patients were cervical pain in 72 patients (15.4%), cervical tenderness in 60 patients (12.8%), weakness and paralysis in 98 (20.9%) of the patients, numbness and paresthesia in 94 (20%) and hypotension in 48 patients (10.2%), over

and above, findings in some patients were difficult to assess. The associated injuries among the studied group were facial injuries in 133 (28.4%), skull fracture in 150 (32%), and thoracolumbar fracture in 51 (10.9%). The associated injuries were more frequent in the extremities, 112/469 (23.9%), combined injuries in 112 (23.9%), chest and abdomen injuries were reported in only 6% and 6.8%, respectively. There is a significant association between cervical injury and the presence of clinical and radiographic findings and associated injuries ($P<0.001$) except with the thoracolumbar fracture ($P>0.05$), as shown in table III.

Table II. Relationship between severity of traumatic brain injury and level of cervical injury.

Level of injury	Traumatic brain injury type						Total	
	Mild		Moderate		Severe		No.	%
	No.	%	No.	%	No.	%		
Upper	0	0.0	7	41.2	10	58.8	17	28.8
Lower	6	25.0	13	54.2	5	20.8	24	40.7
Combined	0	0.0	4	22.2	14	77.8	18	30.5
Total	6	10.2	24	40.7	29	49.2	59	100

Chi square test is significant at $P<0.001$.

Table III. The relationship between cervical injury and clinical findings, radiology, and associated injuries.

		Cervical injury				Total		P value
		Yes		No		No.	%	
		No.	%	No.	%			
Cervical pain	Yes	28	38.9	44	61.1	72	15.4	< 0.001
	No	0	0.0	243	100.0	243	45.5	
	Difficult to assess	39	29.2	115	78.8	154	39.1	
Cervical tenderness	Yes	28	46.7	32	53.3	60	12.8	< 0.001
	No	0	0.0	255	100.0	255	48.1	
	Difficult to assess	39	29.2	115	78.8	154	39.1	
Weakness+ paralysis	Yes	37	37.8	61	62.2	98	20.9	< 0.001
	No	17	4.9	331	95.1	348	74.2	
	Difficult to assess	5	21.7	18	78.3	23	4.9	
Numbness +paresthesia	Yes	33	35.1	61	64.9	94	20	< 0.001
	No	16	4.6	331	95.4	347	74	
	Difficult to assess	10	35.7	18	64.3	28	6	
Hypotension	Yes	14	29.2	34	70.8	48	10.2	< 0.001
	No	45	10.7	376	89.3	421	89.8	
Facial injury	Yes	38	28.6	95	71.4	133	28.4	< 0.001
	No	21	6.3	315	93.8	336	71.6	
Skull fracture	Yes	40	26.7	110	73.3	150	32	< 0.001
	No	19	6.0	300	94.0	319	68	
Thoracolumbar fracture	Yes	7	13.7	44	86.3	51	10.9	0.79
	No	52	12.4	366	87.6	418	89.1	
Associated injury	Chest	6	21.4	22	78.6	28	6	< 0.001
	Abdomen	3	9.4	29	90.6	32	6.8	
	Extremity	20	17.9	92	82.1	112	23.9	
	Combined	30	26.8	82	73.2	112	23.9	
	None	0	0.0	185	100.0	185	39.4	
X-ray finding	Yes	21	100.0	0	0.0	21	4.5	< 0.001
	No	38	8.5	410	91.5	448	95.5	

Table IV. Relationship between cervical injury and the mechanism of injury.

Mechanism of injury	Cervical injury			
	Yes		No	
	No.	%	No.	%
Road traffic accident	27	15.5%	147	84.5%
Bullet injury	0	0.0%	61	100.0%
Blast injury	7	8.9%	72	91.1%
Fall from height	23	20.5%	89	79.5%
Other	2	4.7%	41	95.3%
Total	59	12.6	410	87.4

P. value = < 0.001, significant

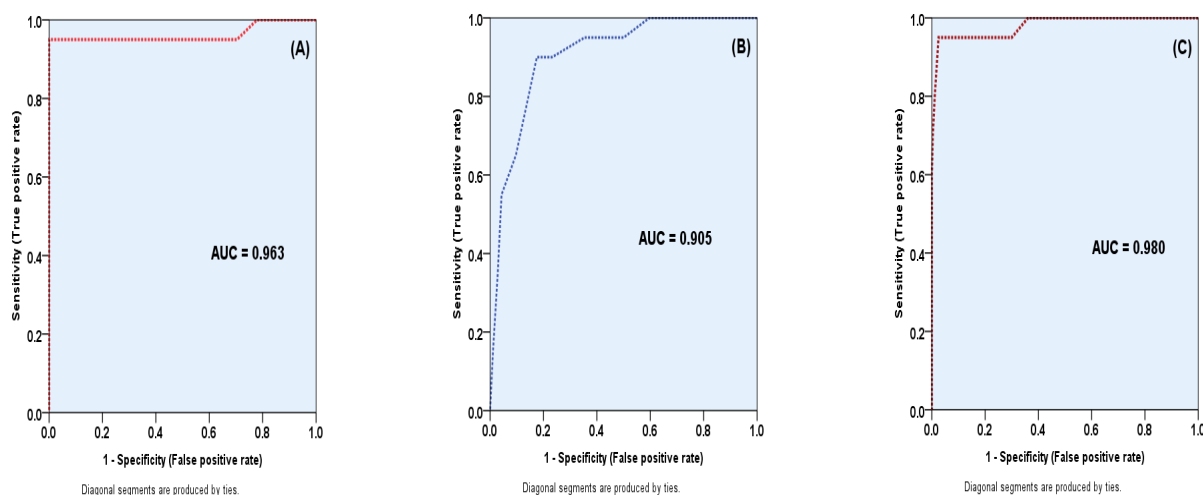


Figure 1. Receiver operating characteristics (ROC) curves for the validity of CT scanning (A), GCS (B) and combined CT & GCS (C), in prediction of cervical injuries. AUC: (Area Under Curve).

The mechanism of injuries among the studied group were RTA which was the most frequent (37.1%) of the cases, followed by fall from height (23.9%), blast injury (16.8%), bullet injury (13%) and other mechanisms represented only 9.2% (Table IV). X-ray and CT were positive in 21 (4.5%) and 59 (12.6%) patients, respectively. The prevalence of cervical injury was (12.6%), which represented 59 patients among the studied group. It had been significantly found that cervical injury was more frequent in patients who were exposed to fall from height (20.5%) followed by road traffic accident (15.5%), compared to those who were exposed to bullet injuries, blast injuries and other mechanism of injuries with 0% and 8.9% and 4.7%, respectively ($P < 0.001$) (Table V).

Table V. Comparison of AUCs of the CT scan, GCS and combined CT and GCS.

AUC	
CT	0.963
GCS	0.905
Combined	0.980
Multiple comparisons	
CT vs. GCS	Z = 1.94, P. value = 0.031
Combined vs. CT	Z = 2.38, P. value = 0.018
Combined vs. GCS	Z = 0.998, P. value = 0.001

Table VI. Validity parameters of CT and GCS and combined (GCS and CT) in prediction of cervical injuries.

Parameter	GCS	CT	Combined (CT and GCS)
Sensitivity	91.0%	95.0%	97.0%
Specificity	81.0%	100.0%	100.0%
Accuracy	86.0%	97.5%	98.5%
PPV	82.7%	100.0%	100.0%
NPV	90.0%	95.2%	97.1%

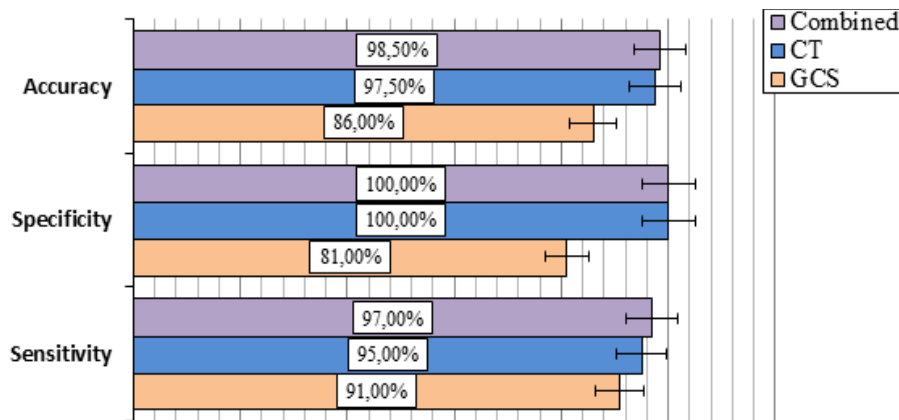


Figure 2. Comparison of validity parameters (sensitivity, specificity and accuracy) of CT, GCS and combined in prediction of cervical injuries among 469 patients with traumatic brain injury.

Discussion

The association between injury to cervical spine and simultaneous head injury was firstly described by Sir Geoffrey Jefferson in 1920 [19]. Our study aimed to collect and process data to test the validity of CT scan in confirmation of this association.

In our study the majority of patients were male (82.9%) with a male to female ratio of (4.45:1). This result is as close as possible to Nayeabghayee et al. in India (2016) [20], Eaton et al. in Africa [21], Munivenkatappa et al. 2016 [22], in India and Bruns and Hauser in United States [23], as most of the patients were male (80-85%). There is an intimate relationship regarding severe traumatic brain injuries and cervical injuries. Therefore patients that presented with mild traumatic brain injury had cervical injuries in only 10.2%, while moderate and severe traumatic brain injury had cervical injuries in 40.7% and 49.2% respectively.

On the other hand, when cervical spine injury occurred concomitantly with traumatic brain injury and other associated injuries, it might result in increased morbidity, impaired quality of life, and hindered the rehabilitation process.

In a study of Thesleff et al. [24], about one third of their cervical spine injured patients had a concomitant moderate or severe head injury. In contrast, in head injured patients; the incidence of concomitant cervical spine injury has generally ranged from 4 to 8% as described in Paiva et al. [25] and Holly et al. 2002 [26], while our research and Nazir et al. [27] reported percentages of 12.6% and 11.3% respectively.

Holly et al. showed an association between GCS score-related head injury severity and the risk of accompanied cervical injury. Bailly et al. [28] showed that the risk of injury to cervical spines was higher in patients

with TBI (4.5%) than in those with no head injury (1.1). In light of these recent reports (including our study) and in accordance with their experience with flexion-extension (F-E) studies, their use was limited to patients with high-risk, those with severe injury according to GCS score (3-8), those involved in trauma related to vehicles and those with severe associated injuries. Because the analysis of our data and the above studies suggested that patients with mild and moderate GCS score with non-vehicular-related trauma and no or less severe associated injuries have significantly low risk of having an unstable injury to cervical spine, we can limit the use of F-E studies in patients meeting these criteria. Sees et al. [29] demonstrated that the (F-E) radiography failed to reveal the cervico-thoracic junction in up to 30% of patients. The above conclusions are analogous to our study, as plain radiography diagnosed only 21/59 with cervical spine injury, on the other hand; cervical CT scan evidenced the injuries in 59/59 patients.

Using the Receiver operating characteristic (ROC) curve analysis to assess the validity of GCS, CT and combination of both, revealed that CT and GCS were excellent predictors of cervical injury; however the comparison of the area under the curve (AUC) (in ROC) indicated that CT was superior to GCS in prediction of cervical injury, the AUC for CT was 0.963 while for GCS it was 0.905, on the other hand, when CT and GCS combined and tested with ROC the AUC was increased to 0.980 which indicated that using CT and GCS together will lead to more valid and accurate prediction for cervical injury (Figure 1), nonetheless, AUCs were compared using Z statistics (Table V), the differences were statistically significant between CT vs. GCS, Combined vs. CT and combined vs. GCS, ($P < 0.05$), in all the three comparisons. The validity parameters of CT, GCS or combined, as shown in Table VI, we notice that CT and GCS are highly specific, sensitive,

accurate, with a positive and negative predictive values, however, all validity parameters are higher in CT than GCS, from other point of view, all these validity parameters more increased when CT and GCS combined together (Figure 2). The advantage of using MRI is to assess the condition of soft tissue of the cervical region in the patients with head injury [30]. The disadvantages of spine MRI use include the long time of the study, the difficulty in transporting unconscious intubated patients, and choosing the best images related to the insult [31]. According to Holly et al. [26] the region above C-3 is most likely to be injured (58% of the injuries), while our study showed that upper cervical injury 28.8%, while the lower levels are about 40.7%. Sport and motor vehicular accident resulted in severe cervical spine injury and the level of spine injured was different between a front and a rear seat occupant in motor vehicular accident.

Conclusions

CT scan and GCS have high accuracy, specificity, sensitivity, and predictive values; however, all validity parameters were higher in CT than GCS, from other point of view, all these validity parameters are more increased when CT and GCS are combined together. It is important to realize the direct relationship between cervical and head injuries. Keeping health care institutions outside the main cities well equipped with the needed machines (as CT scan) is vital to discover such injuries and save the time of transportation in order to lessen the deleterious complications.

Ethical approval

Approval was taken from the Arab Board for Health Specializations in September 2016.

References

- Menon DK, Schwab K, Wright DW, Maas AI; Demographics and Clinical Assessment Working Group of the International and Interagency Initiative toward Common Data Elements for Research on Traumatic Brain Injury and Psychological Health. Position statement: definition of traumatic brain injury. *Arch Phys Med Rehabil.* 2010;91:1637-1640.
- Tator C, Bray G, Morin D. The CBANCH report--the burden of neurological diseases, disorders, and injuries in Canada. *Can J Neurol Sci.* 2007;34:268-269.
- Lafta GA, Dolachee AA, Al-Zubaidi AK. Factors affecting outcomes of surgically treated patients with cranial extradural hematoma: A cross-sectional study. *J Acute Dis.* 2020;9:105-108.
- Dewall J. The ABCs of TBI. Evidence-based guidelines for adult traumatic brain injury care. *JEMS.* 2010;35:54-61; quiz 63.
- Bradbury CL, Wodchis WP, Mikulis DJ, Pano EG, Hitzig SL, McGillivray CF, et al. Traumatic brain injury in patients with traumatic spinal cord injury: clinical and economic consequences. *Arch Phys Med Rehabil.* 2008;89(12 Suppl):S77-S84.
- Macciocchi S, Seel RT, Warshowsky A, Thompson N, Barlow K. Co-occurring traumatic brain injury and acute spinal cord injury rehabilitation outcomes. *Arch Phys Med Rehabil.* 2012;93:1788-1794.
- Mayer AR, Quinn DK, Master CL. The spectrum of mild traumatic brain injury: a review. *Neurology.* 2017;89:623-632.
- Moppett IK. Traumatic brain injury: assessment, resuscitation and early management. *Br J Anaesth.* 2007;99:18-31.
- Chi YC, Wu HL, Chu CP, Huang MC, Lee PC, Chen YY. Traumatic brain injury and affective disorder: a nationwide cohort study in Taiwan, 2000-2010. *J Affect Disord.* 2016;191:56-61.
- Mulligan RP, Friedman JA, Mahabir RC. A nationwide review of the associations among cervical spine injuries, head injuries, and facial fractures. *J Trauma.* 2010;68:587-592.
- National Spinal Cord Injury Statistical Center, Spinal Cord Injury: Facts & Figures at a Glance 2009. Available from: <https://www.nscisc.uab.edu/>
- MacDonald RL, Schwartz ML, Mirich D, Sharkey PW, Nelson WR. Diagnosis of cervical spine injury in motor vehicle crash victims: how many X-rays are enough? *J Trauma.* 1990;30:392-397.
- Mann FA, Wilson AJ, McEnergy KW, et al. Supine oblique views of the cervical spine: A poor proxy for the lateral view. *Emergency Radiology.* 1995;2:214-220.
- Murphey MD, Batnitzky S, Bramble JM. Diagnostic imaging of spinal trauma. *Radiol Clin North Am.* 1989;27:855-872.
- Domenicucci M, Preite R, Ramieri A, Osti MF, Ciappetta P, Delfini R. Three-dimensional computed tomographic imaging in the diagnosis of vertebral column trauma: experience based on 21 patients and review of the literature. *J Trauma.* 1997;42:254-259.
- Acheson MB, Livingston RR, Richardson ML, Stimac GK. High-resolution CT scanning in the evaluation of cervical spine fractures: comparison with plain film examinations. *AJR Am J Roentgenol.* 1987;148:1179-1185.
- Schleehauf K, Ross SE, Civil ID, Schwab CW. Computed tomography in the initial evaluation of the cervical spine. *Ann Emerg Med.* 1989;18:815-817.
- Como JJ, Diaz JJ, Dunham CM, Chiu WC, Duane TM, Capella JM, et al. Practice management guidelines for identification of cervical spine injuries following trauma: update from the eastern association for the surgery of trauma practice management guidelines committee. *J Trauma.* 2009;67:651-659.
- Mead LB 2nd, Millhouse PW, Krystal J, Vaccaro AR. C1 fractures: a review of diagnoses, management options, and outcomes. *Curr Rev Musculoskelet Med.* 2016;9:255-262.
- Nayebaghayee H, Afsharian T. Correlation between Glasgow Coma Scale and brain computed tomography-scan findings in head trauma patients. *Asian J Neurosurg.* 2016;11:46-49.

21. Eaton J, Hanif AB, Grudziak J, Charles A. Epidemiology, management, and functional outcomes of traumatic brain injury in Sub-Saharan Africa. *World Neurosurg.* 2017;108:650-655.
22. Munivenkatappa A, Agrawal A, Shukla DP, Kumaraswamy D, Devi BI. Traumatic brain injury: Does gender influence outcomes? *Int J Crit Illn Inj Sci.* 2016;6:70-73.
23. Bruns J Jr, Hauser WA. The epidemiology of traumatic brain injury: a review. *Epilepsia.* 2003;44 (s10):2-10.
24. Thesleff T, Kataja A, Öhman J, Luoto TM. Head injuries and the risk of concurrent cervical spine fractures. *Acta Neurochir (Wien).* 2017;159:907-914.
25. Paiva WS, Oliveira AM, Andrade AF, Amorim RL, Lourenço LJ, Teixeira MJ. Spinal cord injury and its association with blunt head trauma. *Int J Gen Med.* 2011;4:613-615.
26. Holly LT, Kelly DF, Counelis GJ, Blinman T, McArthur DL, Cryer HG. Cervical spine trauma associated with moderate and severe head injury: incidence, risk factors, and injury characteristics. *J Neurosurg.* 2002;96(3 Suppl):285-291.
27. Nazir M, Khan SA, Raja RA, Bhatti SN, Ahmed E. Cervical spinal injuries in moderate to severe head injuries. *J Ayub Med Coll Abbottabad.* 2012;24:100-102.
28. Bailly N, Laporte JD, Afquir S, Masson C, Donnadiou T, Delay JB, et al. Effect of helmet use on traumatic brain injuries and other head injuries in alpine sport. *Wilderness Environ Med.* 2018;29:151-158.
29. Sees DW, Rodriguez Cruz LR, Flaherty SF, Ciceri DP. The use of bedside fluoroscopy to evaluate the cervical spine in obtunded trauma patients. *J Trauma.* 1998;45:768-771.
30. Martínez-Pérez R, Cepeda S, Paredes I, Alen JF, Lagares A. MRI prognostication factors in the setting of cervical spinal cord injury secondary to trauma. *World Neurosurg.* 2017;101:623-632.
31. Pajewski TN, Arlet V, Phillips LH. Current approach on spinal cord monitoring: the point of view of the neurologist, the anesthesiologist and the spine surgeon. *Eur Spine J.* 2007;16 Suppl 2(Suppl 2):S115-S129.