

Minimally Invasive Distal Chevron Osteotomy for Symptomatic Bunionette: Clinical and Radiologic Results of a 31-Case Retrospective Study

Juan Carlos Benavente Valdivia, MD¹ , and Daniel M. Thull, MD¹ 

Abstract

Background: Bunionette is a common forefoot deformity that usually leads to significant discomfort. Multiple surgical techniques have been described for correcting bunionette. The purpose of this study is to analyze the clinical and radiologic outcomes of a new surgical technique via minimally invasive distal Chevron osteotomy of the fifth metatarsal without fixation, trying to find an effective technique with fewer complications.

Methods: We retrospectively analyzed the data of 28 patients (31 feet) who presented with symptomatic bunionette that was resistant to conservative treatment and who underwent surgery at our center from February 2018 to February 2020. A minimum follow-up of 20 months was obtained (mean follow-up 26 months, range 20–37). Clinical results were evaluated using the visual analog scale (VAS) and the American Orthopaedic Foot & Ankle Society (AOFAS) score; 5 different radiologic parameters were analyzed.

Results: After surgery, the mean AOFAS score increased by 29 points ($P < .001$) and the mean VAS scores decreased by 6 points ($P < .001$). An adequate radiologic correction was observed with a decrease in the M4–M5 intermetatarsal angle from 10.3 to 4.8 degrees ($P < .001$), metatarsophalangeal angle by a mean of 16.05 degrees ($P < .001$), and lateral deviation angle of the fifth metatarsal from 8.5 to 0.97 degrees ($P < .001$). Moreover, the length of the fifth metatarsal and the forefoot width was reduced ($P < .001$). The only complication was an asymptomatic delay in bone healing, but a complete bone consolidation was achieved after therapy.

Conclusion: The proposed surgical technique shows a good correction capacity with excellent clinical and radiologic results and low complication rates.

Level of Evidence: Level IV, retrospective case series.

Keywords: minimally invasive surgery, bunionette, Taylor's bunion, fifth metatarsal, surgical technique, percutaneous metatarsal osteotomy, combined forefoot surgery

Introduction

Taylor's bunion or bunionette is a painful prominence of the head of the fifth metatarsal and is comparable to hallux valgus. Coughlin introduced a classification based on DuVries's work.³ In this classification, a dorsoplantar radiograph is evaluated and the findings are classified into 3 types. Type I is defined by the size of the fifth metatarsal head and its lateral projection, type II is identified by a marked lateral concavity of the fifth metatarsal metaphysis, and type III is characterized by an increase in the intermetatarsal angle

between the fourth and fifth metatarsals. Several open surgical techniques have been proposed for treating symptomatic bunionette¹⁵; however, since the development of minimally invasive surgery described by de Prado,²³ many

¹Cologne Foot and Ankle Surgery Center, Fußzentrum Köln, Cologne, Germany

Corresponding Author:

Juan Carlos Benavente Valdivia, MD, Cologne Foot and Ankle Surgery Center, Fußzentrum Köln, Vorgebirgstraße 118, Köln, 50969, Germany.
Email: jc_benavente@yahoo.com



Table 1. Minimally Invasive Chevron Osteotomy for Bunionette.

Surgery Type		Cases
Single surgery		16
Combined with	Chevron osteotomy first metatarsal	9
	Modified Lapidus arthrodesis	5
	Metatarsophalangeal arthrodesis D1	1
	Total	31

surgeons have opted for percutaneous surgery owing to its lower number of complications,^{2,5,8,9,12,14-17} in addition to maintaining the same satisfactory results. Hence, this retrospective study aimed to analyze the clinical and radiologic results of a new minimally invasive surgical treatment in patients with symptomatic bunionette in order to find an effective technique with fewer complications.

Materials and Methods

This retrospective study was conducted in accordance with the Declaration of Helsinki and local legislation, and informed consent was obtained from all individual participants included in this study.

Subjects

A total of 28 patients (31 feet) who came to our center between February 2018 and February 2020 were included in this study. Among all patients, 26 (92.9%) were women and 2 (7.1%) were men and their mean age was 41.4 years (range 17-79). The mean follow-up period was 26 months (range 20-37). Patients with symptomatic bunionette confirmed by radiologic study that was resistant to conservative treatment for at least 6 months were included in the study. Patients who had undergone foot surgery or fractures were diagnosed with rheumatoid arthritis or other inflammatory/collagen diseases, had inappropriate radiographic imaging, or were diagnosed with significant osteoporosis were excluded.

Minimally invasive Chevron osteotomy of the fifth metatarsal was performed in all 31 cases included in this study by 3 surgeons with expert certification in foot and ankle surgery. In 16 cases, the procedure was performed as a single surgery and in 15 cases, it was performed in combination with other forefoot correction surgeries (Table 1). As per Coughlin's bunionette classification, 8 (26%) patients had type I, 12 (39%) had type II, and 11 (35%) had type III bunionette.

Clinical Examination

Clinical diagnosis was made based on the presence of pain over the head of the fifth metatarsal or around the fifth

metatarsophalangeal joint. The presence of painful calluses or bursitis was also considered.

Radiologic Evaluation

All participants underwent barefoot weightbearing radiographs using Dunlee DU304 radiograph machine (Arlington, TX, USA). Anteroposterior radiography was performed separately for each foot. Moreover, lateral radiography was performed separately, focusing on the medial cuneiform.

Five measurements were performed in this study^{8,20,24,25}: the M4-M5 intermetatarsal angle (IMA), between the fourth and fifth metatarsal shafts; the fifth metatarsophalangeal angle (MPA); the lateral deviation angle (LDA), one axis is tangent to the proximal-medial cortex of the fifth metatarsal and the other axis bisects the fifth metatarsal head and neck; the fifth metatarsal length (FML), from the most distal point to the most proximal point of the fifth metatarsal; and the forefoot width (FW), measured as the widest point between the first and fifth metatarsal heads (Figure 1). A radiologic diagnosis was made according to Coughlin's classification.³

Clinical Outcomes

Clinical outcomes were measured both pre- and postoperatively using the Lesser Toe Metatarsophalangeal-Interphalangeal Scale scoring system of the American Orthopaedic Foot & Ankle Society (AOFAS)¹⁰ and visual analog scale (VAS) for pain.⁶ Within the most frequent complications taken into account are the nonunion of the osteotomy, the delay of consolidation, recurrence of deformity, and the damages of the skin and soft tissues produced by the burr.^{15,18}

Surgical Technique

The patient was first placed in the supine position on the operating table. The C-arm was placed perpendicular to the foot to be operated on. Total anesthesia was used in all cases. Tourniquet was used only in combined surgery cases. A perpendicular incision was made over the lateral condyle of the fifth metatarsal with a Beaver scalpel no. 64, as described by de Prado.²³ Soft tissues were then released toward both the dorsal and plantar directions to protect the tendon structures. Using a bone awl, the ideal point for the osteotomy was located near the base of the metatarsal head with fluoroscopic control, and the lateral cortex was perforated perpendicularly. This maneuver facilitates the correct positioning of the osteotomy and avoids the accidental sliding of the burr. Then, a 2.0 × 12-mm Shannon burr was also inserted perpendicularly until the medial cortex was perforated (Figure 2A). V-shaped Chevron osteotomy of 60 to 80 degrees was then performed, first in the dorsal direction and

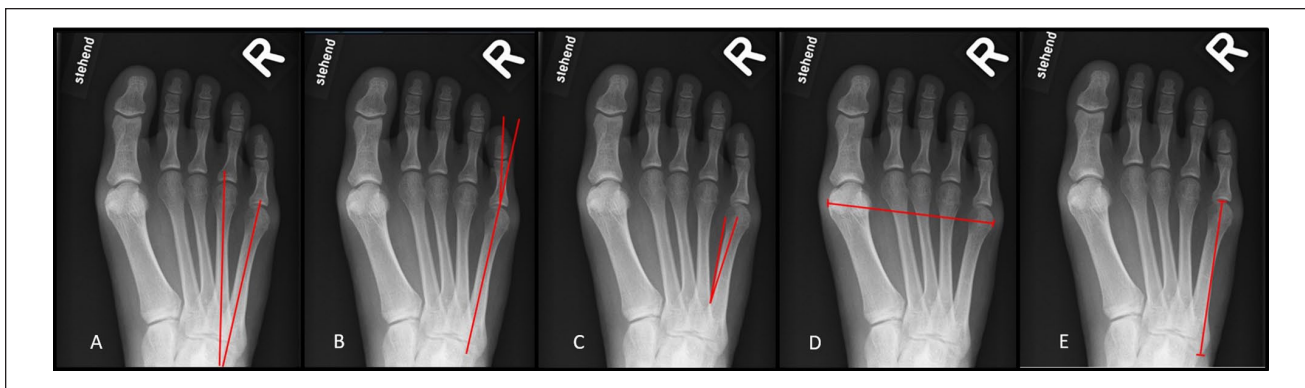


Figure 1. Radiologic evaluation. (A) IMA, intermetatarsal angle; (B) MPA, metatarsophalangeal angle; (C) LDA, lateral deviation angle; (D) FW, forefoot width; (E) FML, fifth metatarsal length.

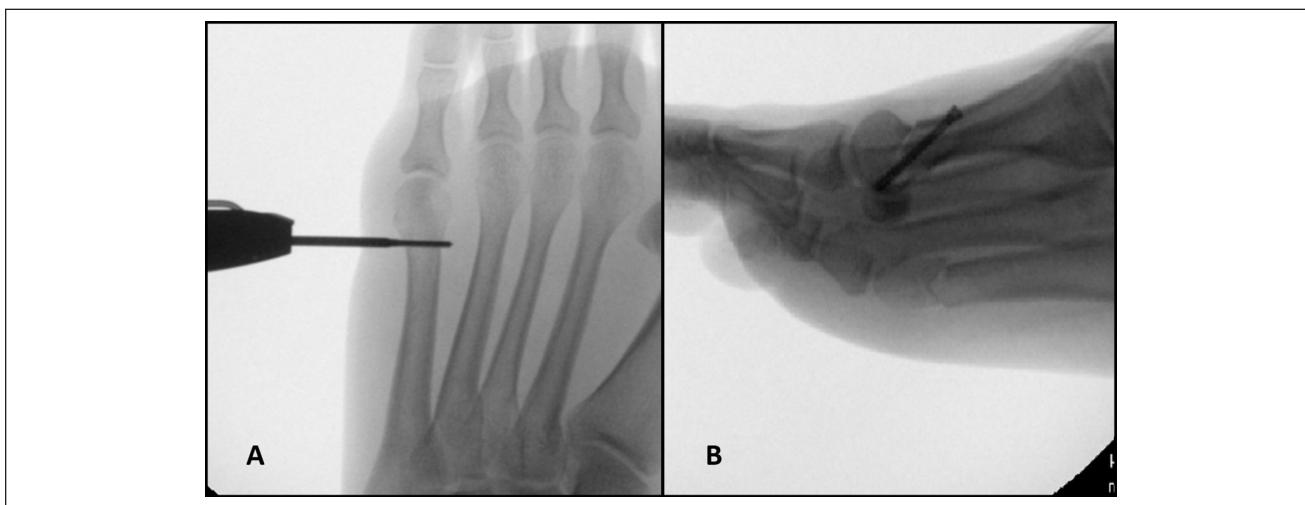


Figure 2. Surgical technique. (A) Shannon burr is also inserted perpendicularly until the medial cortex is perforated. (B) Fifth metatarsal Chevron osteotomy.

then starting from the initial point in the plantar direction (Figure 2B). Once osteotomy was completed, the toe was pulled and the distal metatarsal fragment was pressed medially. This maneuver manages to displace the head by approximately 50% of the diameter of the metatarsal bone. In some cases, the displacement of the distal fragment can be facilitated by inserting an awl or mosquito forceps into the medullary canal and using it as a lever (Figure 3A). Osteosynthesis was not performed (Figure 3B). The osteotomy site was irrigated to remove bone chips, and the incision was sutured. Finally, a nonflexible tape was placed transversely at the level of the metatarsal head to maintain the correction and medialization of the distal fragment, and the fifth toe was fixed in a moderate valgus position so that the base of the proximal phalanx slightly compresses the osteotomy medially and prevents possible displacement (Figure 3C).

Postoperative Care

After surgery, all patients were allowed to start full weight-bearing using an orthopaedic shoe with a rigid sole (Darco MedSurg) for the subsequent 6 weeks. Suture threads were removed after 12 days, and the tapes were changed every 2 weeks in our center up to 6 weeks. A control radiograph was performed at 6 weeks in all cases, the shoe was removed, and the patients were allowed to use any type of footwear. Additional radiographs were made in all patients between 12 and 24 weeks to verify correct consolidation of the osteotomy¹⁹ (Figure 4).

Statistical Analysis

Statistical analyses were performed using IBM SPSS Statistics version 24.0 (IBM Corp, NY, USA). Data distribution for normality was tested using the Shapiro-Wilk test.

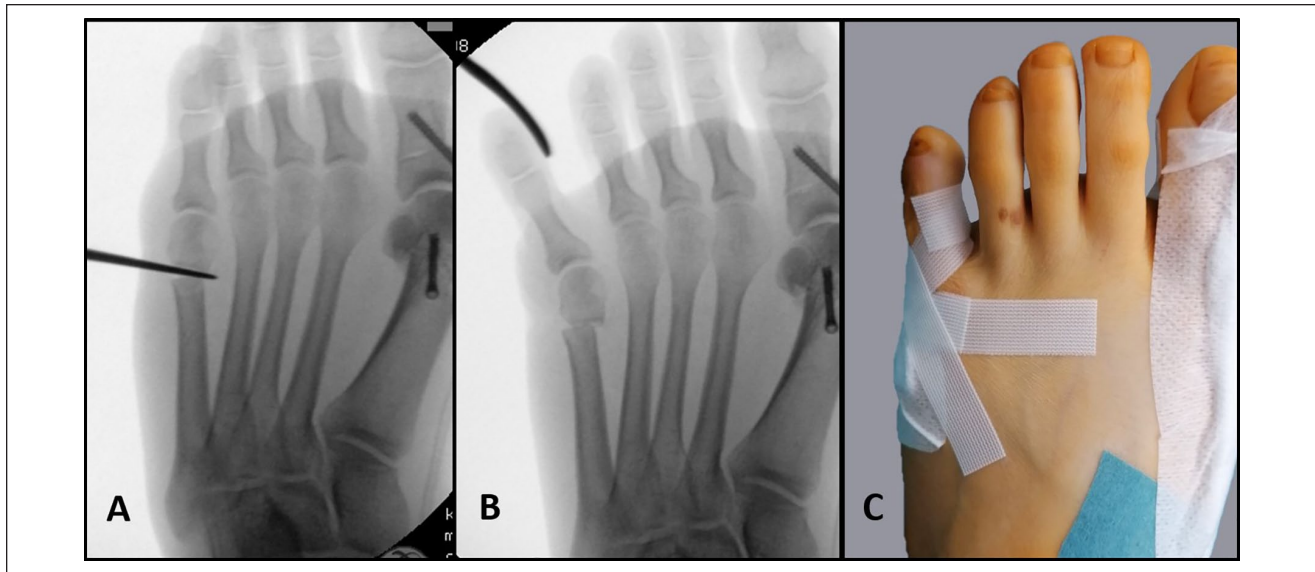


Figure 3. Surgical technique. (A) Using a bone awl as a lever. (B) Final position. (C) Nonflexible tape to fix the fifth toe in a moderate valgus position.

Data are presented as means \pm SDs. Student *t* test was used to compare the pre- and postoperative outcomes. A *P* value of $\leq .05$ was considered statistically significant.

Results

Radiologic Evaluation

The mean of the postoperative radiologic outcomes showed a statistically significant reduction compared with the preoperative values ($P < .001$). The IMA showed a reduction of 5.5 degrees, and the LDA decreased from 8.52 to 0.97 degrees. The MPA decreased from 16.51 to 0.45 degrees, as well as the length of the fifth metatarsal reduced by a mean of 2.7 mm. The forefoot width was measured only in patients who underwent percutaneous osteotomy of the fifth metatarsal (single surgery) and showed a mean reduction of 6 mm ($P < .001$) (Table 2).

Clinical Outcomes

After surgery, the mean AOFAS score increased from 65.8 (SD 12.6) to 95 (SD 6.1) and the mean VAS score decreased from 6.6 (SD 1.6) to 0.23 (SD 0.6); both results were significant ($P < .001$). To avoid confounding factors, clinical outcomes were measured separately in 2 groups: single-surgery group and combined-surgery group. Clinical results and pain reduction were comparable and significant in both groups (Table 3).

In one case, a delayed consolidation was observed in a radiologic control at 10 weeks, but the patient did not experience any pain. Following 5 sessions of focal shock wave

therapy, total consolidation was achieved at 16 weeks.¹⁹ No thermal injuries or infections were observed. A clinical examination was performed in all patients at least 20 months after surgery and no residual pain or recurrence of the deformity were observed.

Discussion

Bunionette correction by minimally invasive chevron osteotomy of the fifth metatarsal without fixation has not been previously published. The use of open distal Chevron osteotomy for treating bunionette was initially described by Throckmorton and Bradlee²⁷ and later by others.^{1,11} Owing to the good stability conferred by the shape of osteotomy, a good medial displacement can be achieved⁴; our results confirmed this and showed that the use of osteosynthesis was not necessary to maintain a good correction. Kitaoka et al¹¹ described forefoot width as a radiologic result after open chevron osteotomy for bunionette correction with a mean reduction of 3 mm. In our study, forefoot width was described only in patients who underwent percutaneous osteotomy of the fifth metatarsal (single surgery) and showed a significant mean reduction of 6 mm. This is the first time that forefoot width has been described in minimally invasive bunionette correction.

Our results showed a significant decrease in IMA of 5.5 degrees similar to that described by Michels et al¹⁶ and Nunes et al²¹ after minimally invasive distal correction with 5.7 and 5.8 degrees, respectively. Ferreira et al⁸ reported the largest reduction in IMA after distal percutaneous correction with 7.7 degrees. The LDA is an important measurement parameter, particularly for type II

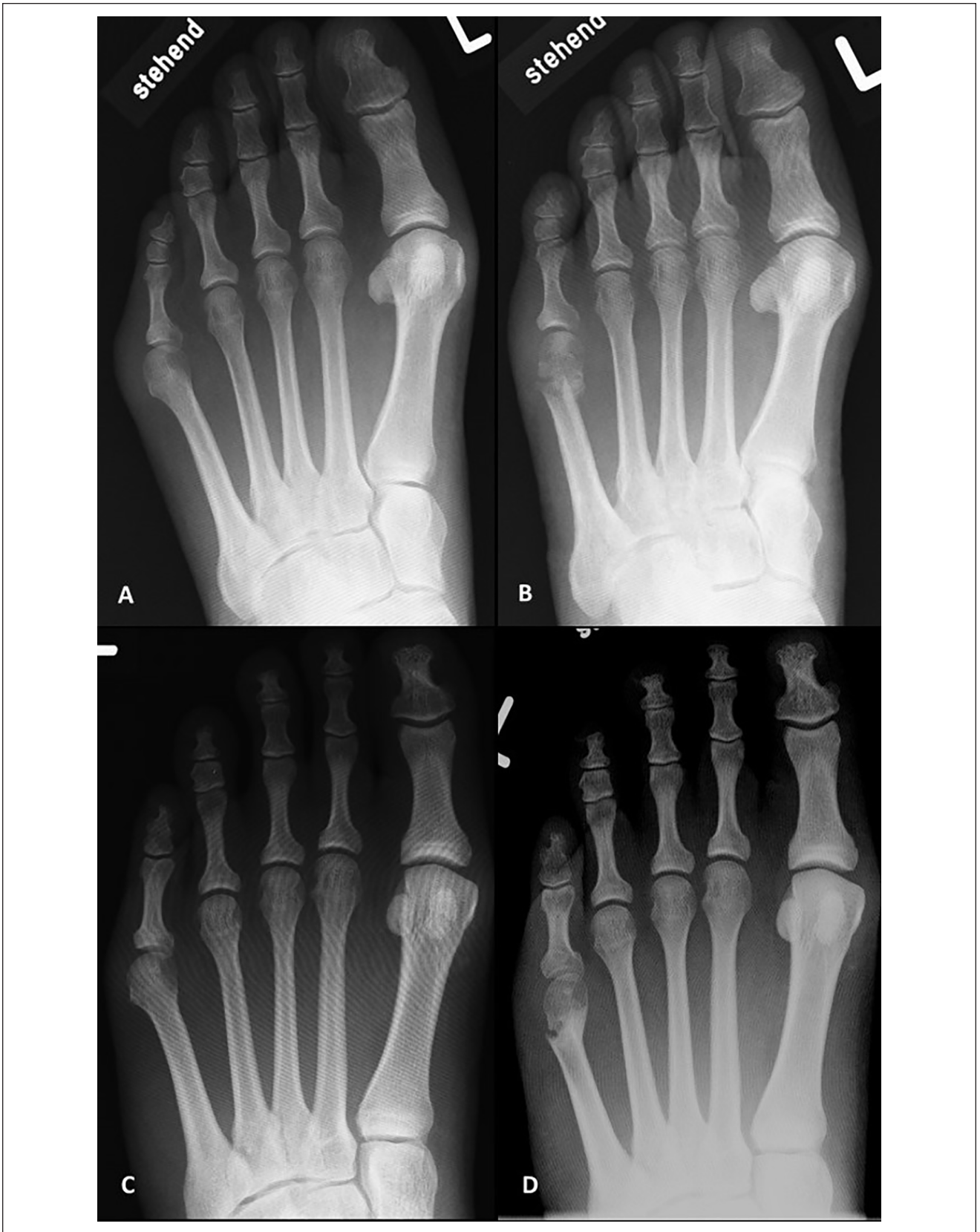

Figure 4. Postoperative care. (A, B) Control after 6 weeks. (C, D) Control after 24 weeks.

Table 2. Radiologic Outcomes.

Variables	Feet (n)	Preoperative Mean (SD)	Postoperative Mean (SD)	Difference Mean	P Value
IMA	31	10.3 (1.9)	4.8 (2.2)	5.5	<.001
LDA	31	8.52 (1.4)	0.97 (2.2)	7.55	<.001
MPA	31	16.51 (6)	0.45 (6.7)	16.06	<.001
FML	31	76 (5.6)	73.3 (5.4)	2.7	<.001
FW ^a	16	92.6 (5.3)	86.6 (5.3)	6	<.001

Abbreviations: FML, fifth metatarsal length; FW, forefoot width; IMA, intermetatarsal angle; LDA, lateral deviation angle; MPA, metatarsophalangeal angle.

^aMeasured only in patients underwent single surgery.

Table 3. Clinical Outcomes.

Variables	Feet (n)	Preoperative Mean (SD)	Postoperative Mean (SD)	Difference Mean	P Value
Single surgery					
AOFAS	16	61.9 (12.9)	96.3 (4.5)	34.4	<.001
VAS	16	7.6 (0.9)	0.3 (0.6)	7.3	<.001
Combined surgery					
AOFAS	15	69.9 (11.4)	93.6 (7.3)	23.7	<.001
VAS	15	5.6 (1.6)	0.2 (0.6)	5.4	<.001
Single and combined surgery					
AOFAS	31	65.8 (12.6)	95 (6.1)	29.2	<.001
VAS	31	6.6 (1.6)	0.23 (0.6)	6.37	<.001

Abbreviations: AOFAS, American Orthopaedic Foot & Ankle Society lesser metatarsophalangeal–interphalangeal scale; VAS, visual analog scale.

bunionette, because the diaphysis is curved laterally.^{7,18,26} There are no data about LDA after minimally invasive correction. In the present study, a significant reduction in LDA was observed. Some authors have suggested diaphyseal and proximal osteotomies to correct types II and III.^{22,28} The results of the present study showed a significant reduction in IMA, foot width, and LDA, suggesting that our technique is sufficient to correct all types of bunionette. In our opinion and according to what was published by Ferreira et al,⁸ the reduction of the lateral prominence of the fifth metatarsal generates great satisfaction in patients after surgery. We also observed a mean decrease of 2.7 in the length of the fifth metatarsal. This finding has also been described by Michels et al¹⁶ and by Ferreira et al,⁸ both reporting values similar to those found in our study. Considering that about a third of bunionette patients have metatarsalgia²⁵ and according to the publication by Ferreira et al,⁸ the shortening of the length could reduce the load on the plantar area and would be essential in the treatment of cases associated with metatarsalgia.

Our clinical outcomes showed a significant increase in the AOFAS score, reaching a mean of 95 points on 28 patients (31 feet), these results were superior to those reported by Molenaers et al¹⁷ (91.6) on 16 patients (20 feet) and Nunes et al²¹ (92.4) on 18 patients (25 feet). Lima et al¹³ and Ferreira et al⁸ found a postoperative mean AOFAS score of 94 (13 patients/14 feet) and 93.7 (28 patients/36

feet) and a postoperative VAS score of 1.1 and 1.0, respectively. Both results were comparable with those described in our study, however their mean follow-up was considerably lower than ours. Laffenêtre et al¹² reported a postoperative VAS score of 0.3, similar to ours of 0.23 with a mean follow-up of 34 months. The longest follow-up after a minimally invasive correction was described by Del Vecchio et al⁵ with a mean of 49 months. All the comparisons between our clinical and radiologic outcomes and those of the different authors who performed a minimally invasive correction of the bunionette are detailed in Table 4.

In a meta-analysis of different osteotomies to treat symptomatic bunionette, Martijn et al¹⁵ observed a total of 48 major complications (6%), and after subdividing the complications by the osteotomy site, a greater number of complications were observed in proximal and diaphyseal osteotomies than in distal osteotomies. These results suggest that distal osteotomies are safer and produce a lower number of complications. In the present study, delayed bone healing was observed in one patient, which was eventually resolved after 5 sessions of focal shock wave therapy. We did not observe thermal damage to the skin because osteotomies were performed in 3 stages with a pause and radiologic control; this considerably reduced the temperature of the burr. However, in all cases, appropriate irrigation was performed to cool the surgical area. Ferreira et al⁸ performed distal oblique percutaneous osteotomy with significant clinical and radiologic

Table 4. Comparison With Other Studies With Minimally Invasive Technique.

Authors	Year	Osteotomy Site	Patients/ Feet	Mean Clinical Outcomes				Mean Radiographic Outcomes							
				AOFAS score		VAS		4-5 IMA		LDA		MPA		FML - Mean Shortening	
				Preop.	Postop.	Preop.	Postop.	Preop.	Postop.	Preop.	Postop.	Preop.	Postop.	Preop.	Postop.
Michels et al ¹⁶	2013	Distal	20/21	54.4	96.5	ND	ND	10.5	4.8	ND	ND	17.1	2.9	2.38 mm	29
Laffenêtre et al ¹²	2015	Distal	38/49	58	97	8	0.3	9.98	5.51	ND	ND	16.2	4.26	ND	34
Molenaers et al ¹⁷	2017	Distal	16/20	51	91.6	5	0.68	9.8	5.05	ND	ND	20.7	9.1	ND	27
Del Vecchio et al ⁵	2019	Distal	32/38	ND	ND	8.29	1.05	10.9	7.1	ND	ND	14.7	6.47	ND	49
Ferreira et al ⁸	2020	Distal	28/36	58.8	93.7	7.7	1.0	11.4	3.7	ND	ND	16.5	4.8	2.7 mm	13
Nunes et al ²¹	2022	Diaphysis	18/25	49.6	92.4	7.7	1.2	9.1	3.3	ND	ND	15	2.7	ND	15
Lima et al ¹³	2020	Diaphysis	13/14	51.3	94.0	7.5	1.1	9.8	3.6	ND	ND	11.5	2.3	ND	12
Current series		Distal	28/31	65.8	95	6.6	0.23	10.3	4.8	8.5	0.97	16.5	0.45	2.7 mm	26

Abbreviations: AOFAS, American Orthopaedic Foot & Ankle Society lesser metatarsophalangeal–interphalangeal scale; VAS, visual analog scale; IMA, intermetatarsal angle; LDA, lateral deviation angle; MPA, metatarsophalangeal angle; FML, fifth metatarsal length; FU, follow-up; ND, no data.

results. However, a superficial wound infection was observed in 1 case and nonunion was observed in 2 cases. Lima et al¹³ described diaphyseal percutaneous osteotomy with good clinical and radiologic results, but they reported 3 cases with a hypertrophic callus formation.

The present study has some limitations such as its retrospective design, the lack of a control group and the use of a nonvalidated outcome measure tool, such as the AOFAS Lesser Toe Metatarsophalangeal–Interphalangeal scale, for the final follow-up. Despite these limitations, this study suggests that minimally invasive Chevron osteotomy of the fifth metatarsal is a safe and effective technique for the surgical management of bunionette.

Conclusions

The minimally invasive distal Chevron osteotomy described in the present study showed good corrective capacity for all types of bunionette with extremely significant clinical and radiologic results that were comparable with those of other techniques of conventional and minimally invasive surgery with a lower complication rate.

Our results as well as those of other similar studies suggest that it is possible to combine this technique with other forefoot correction procedures, thereby maintaining good clinical and radiologic results without increasing the risk of complications. However, additional studies are needed to confirm this.

Owing to good clinical and radiologic results, the low complication rate, short intervention time, and absence of osteosynthesis material, it is possible that percutaneous distal osteotomies will become the preferred treatment for bunionette in the next years.


Declaration of Conflicting Interests

The author(s) declared no potential conflicts of interest with respect to the research, authorship, and/or publication of this article. ICMJE forms for all authors are available online.

Funding

The author(s) received no financial support for the research, authorship, and/or publication of this article.

ORCID iDs

Juan Carlos Benavente Valdivia, MD,  <https://orcid.org/0000-0001-8752-7830>

Daniel M. Thull, MD,  <https://orcid.org/0000-0001-8535-0373>

References

1. Boyer ML, Deorio JK. Bunionette deformity correction with distal chevron osteotomy and single absorbable pin fixation. *Foot Ankle Int.* 2003;24(11):834-837. doi:10.1177/107110070302401105
2. Cazeau C, Stiglitz Y. Minimally invasive and percutaneous surgery of the forefoot current techniques in 2018. *Eur J Orthop Surg Traumatol.* 2018;28(5):819-837. doi:10.1007/s00590-018-2137-7
3. Coughlin MJ. Treatment of bunionette deformity with longitudinal diaphyseal osteotomy with distal soft tissue repair. *Foot Ankle.* 1991;11(4):195-203. doi:10.1177/107110079101100402
4. Coughlin MJ, Saltzman CL, Anderson RB. *Mann's Surgery of the Foot and Ankle.* Saunders; 2014.
5. del Vecchio JJ, Ghioldi ME, Dalmau-Pastor M, Uzair AE, Chemes L. Sliding distal metatarsal minimally invasive osteotomy (S-DMMO) for the treatment of tailor's bunion. *Tech Foot Ankle Surg.* 2019;18(1):37-42. doi:10.1097/BTF.0000000000000195
6. Downie WW, Leatham PA, Rhind VM, Wright V, Branco JA, Anderson JA. Studies with pain rating scales. *Ann Rheum Dis.* 1978;37(4):378-381. doi:10.1136/ard.37.4.378
7. Fallat LM, Buckholz J. An analysis of the tailor's bunion by radiographic and anatomical display. *J Am Podiatry Assoc.* 1980;70(12):597-603. doi:10.7547/87507315-70-12-597
8. Ferreira GF, Dos Santos TF, Oksman D, Pereira Filho MV. Percutaneous oblique distal osteotomy of the fifth metatarsal for bunionette correction. *Foot Ankle Int.* 2020;41(7):811-817. doi:10.1177/1071100720917906
9. Giannini S, Faldini C, Vannini F, Digennaro V, Bevoni R, Luciani D. The minimally invasive osteotomy "S.E.R.I." (simple, effective, rapid, inexpensive) for correction of bunionette deformity. *Foot Ankle Int.* 2008;29(3):282-286. doi:10.3113/FAI.2008.0282
10. Kitaoka HB, Alexander IJ, Adelaar RS, Nunley JA, Myerson MS, Sanders M. Clinical rating systems for the ankle-hindfoot, midfoot, hallux, and lesser toes. *Foot Ankle Int.* 1994;15(7):349-353. doi:10.1177/107110079401500701
11. Kitaoka HB, Holiday AD, Campbell DC. Distal Chevron metatarsal osteotomy for bunionette. *Foot Ankle.* 1991;12(2):80-85. doi:10.1177/107110079101200204
12. Laffenêtre O, Millet-Barbé B, Darcel V, Lucas Y, Hernandez J, Chauveaux D. Percutaneous bunionette correction: results of a 49-case retrospective study at a mean 34 months' follow-up. *Orthop Traumatol Surg Res.* 2015;101(2):179-184. doi:10.1016/j.otsr.2014.11.017
13. Lima AF de V, Baumfeld TS, Maciel BM, Baumfeld DS, Cordier G, Nunes GA. Minimally invasive bunionette treatment: clinical and radiographic results. *J Foot Ankle.* 2020;14(2):148-152. doi:10.30795/jfootankle.2020.v14.1160
14. Lui TH. Percutaneous osteotomy of the fifth metatarsal for symptomatic bunionette. *J Foot Ankle Surg.* 2014;53(6):747-752. doi:10.1053/j.jfas.2014.07.016
15. Martijn HA, Sierevelt IN, Wassink S, Nolte PA. Fifth metatarsal osteotomies for treatment of bunionette deformity: a meta-analysis of angle correction and clinical condition. *J Foot Ankle Surg.* 2018;57(1):140-148. doi:10.1053/j.jfas.2017.08.006
16. Michels F, Van Der Bauwhede J, Guillo S, Oosterlinck D, de Lavigne C. Percutaneous bunionette correction. *Foot Ankle Surg.* 2013;19(1):9-14. doi:10.1016/j.fas.2012.06.003
17. Molenaers B, Vanlommel J, Deprez P. Percutaneous hardware free corrective osteotomy for bunionette deformity. *Acta Orthop Belg.* 2017;83(2):284-291.
18. Morawe GA, Schmieschek MHT. Minimally invasive bunionette correction. *Oper Orthop Traumatol.* 2018;30(3):184-194. doi:10.1007/s00064-018-0542-z

19. Morshed S. Current options for determining fracture union. *Adv Med.* 2014;2014:708574. doi:10.1155/2014/708574
20. Nestor BJ, Kitaoka HB, Ilstrup DM, Berquist TH, Bergmann AD. Radiologic anatomy of the painful bunionette. *Foot Ankle.* 1990;11(1):6-11. doi:10.1177/107110079001100102
21. Nunes G, Baumfeld T, Nery C, Baumfeld D, Carvalho P, Cordier G. Percutaneous bunionette correction: retrospective case series. *Foot Ankle Spec.* 2022;15(1):36-42. doi:10.1177/1938640020937501
22. Paterson R, Saragas NP, Ferrao PNF. Comparison of 2 oblique fifth metatarsal osteotomies for the management of a bunionette. *Foot Ankle Orthop.* 2021;6(1):2473011421993793. doi:10.1177/2473011421993793
23. Prado M de, Ripoll PL, Golanó P. *Cirugía percutánea del pie: técnicas quirúrgicas, indicaciones, bases anatómicas* [Minimally invasive Foot Surgery: Surgical Techniques, Indications, Anatomical Basis]. Masson; 2005.
24. Shelton TJ, Singh S, Bent Robinson E, et al. The influence of percentage weight-bearing on foot radiographs. *Foot Ankle Spec.* 2019;12(4):363-369. doi:10.1177/1938640018810412
25. Shi GG, Humayun A, Whalen JL, Kitaoka HB. Management of bunionette deformity. *J Am Acad Orthop Surg.* 2018;26(19):e396-e404. doi:10.5435/JAAOS-D-17-00345
26. Shofler DW, McKenna B, Huang J, Christman RA. Reproducibility and reliability of the radiographic angles used to assess tailor's bunions. *J Am Podiatr Med Assoc.* 2018;108(3):205-209. doi:10.7547/16-164
27. Throckmorton JK, Bradlee N. Transverse V sliding osteotomy: a new surgical procedure for the correction of tailor's bunion deformity. *J Foot Surg.* 1978;18(3):117-121.
28. Waizy H, Jastifer JR, Stukenborg-Colsman C, Claassen L. The reverse ludloff osteotomy for bunionette deformity. *Foot Ankle Spec.* 2016;9(4):324-329. doi:10.1177/1938640016640886