



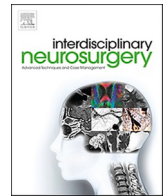
Since January 2020 Elsevier has created a COVID-19 resource centre with free information in English and Mandarin on the novel coronavirus COVID-19. The COVID-19 resource centre is hosted on Elsevier Connect, the company's public news and information website.

Elsevier hereby grants permission to make all its COVID-19-related research that is available on the COVID-19 resource centre - including this research content - immediately available in PubMed Central and other publicly funded repositories, such as the WHO COVID database with rights for unrestricted research re-use and analyses in any form or by any means with acknowledgement of the original source. These permissions are granted for free by Elsevier for as long as the COVID-19 resource centre remains active.



Contents lists available at ScienceDirect

# Interdisciplinary Neurosurgery: Advanced Techniques and Case Management

journal homepage: [www.elsevier.com/locate/inat](http://www.elsevier.com/locate/inat)

Case Reports &amp; Case Series

## Awake craniotomy in a Covid-19 positive patient: The challenges and outcome

Abiodun Idowu Okunlola

Department of Surgery, Federal Teaching Hospital, Ido-Ekiti/Afe Babalola University, Ado-Ekiti, Nigeria



## ARTICLE INFO

## Keywords:

Awake craniotomy  
 COVID-19  
 Pandemic

## ABSTRACT

**Background:** The SARS-COV-2 is a novel coronavirus which is the etiological agent of the COVID-19 infection. The neurosurgical practice is not exempted from the impact of the COVID-19 pandemic. Awake craniotomy in a COVID-19 positive patient pose a significant risk for theatre staff but intubation of a COVID-19 positive patient for surgery under general anesthesia also pose similar risk.

**Method:** Federal Teaching Hospital Ido Ekiti is a tertiary hospital in suburban community in Southwest Nigeria with 300-bed capacity. The hospital is a designated COVID-19 treatment centre. A 69-year-old female patient was referred from a nearby COVID-19 treatment hospital on account of left parieto-occipital high grade glioma. She had awake craniotomy and gross total tumor excision.

**Result:** There was no need to convert to general anesthesia and she had immediate post-operative neurological improvement. Repeat COVID-19 test on post-operative day 4 was negative and she was discharged home. Thirty-day post-operative review confirmed progressive motor gain.

**Conclusion:** Awake craniotomy in COVID-19 positive patient with appropriate use of necessary PPEs is achievable.

### 1. Introduction

The SARS-COV-2 virus is a novel coronavirus which is the etiological agent of the COVID-19 infection [1]. It is an infectious disease and the virus biology is not fully understood [2,3]. Though, the infection started in late 2019 at the Wuhan province of China, it has spread globally leading to one of the most dreaded pandemic in human history [1,2]. There is a double jeopardy as regards the impact of the novel coronavirus- 1) the direct mortalities and morbidities associated with it and 2) the impact of its pandemic on health care delivery system leading to indirect mortalities and morbidities on patients who could not access adequate and prompt medical attention [4,5].

The neurosurgical practice is not exempted from the impact of the COVID-19 pandemic [6,7]. Awake craniotomy facilitate maximum tumor excision in eloquent brain region with optimal outcome and at the same time reduces the patient exposure to general anesthetic agents and its sequelae [7,8]. There are several guidelines for surgical practice during COVID-19 pandemic to prevent exposure of uninfected patient to infected asymptomatic hospital staff and vice versa [6,9]. This involved the use of various levels of Personal Protective Equipment (PPE). The use of PPE can be easily tolerated by patient under general anesthesia but

this may be a challenge in awake patient during awake craniotomy. Awake craniotomy in a COVID-19 positive patient pose a significant risk to theatre staff but intubation of a COVID-19 positive patient for general anesthesia also pose similar risk because of high concentration of the virus in the respiratory tract [4,5,10]. The objective of this review is to document the challenges and outcome of our first awake craniotomy in a COVID-19 positive patient.

### 2. Method

Federal Teaching Hospital Ido Ekiti is a tertiary hospital in suburban community in Southwest Nigeria with 300-bed capacity. The hospital is a designated COVID-19 treatment centre. There is a holding ward for suspected COVID-19 patients and a COVID-19 treatment ward for confirmed COVID-19 positive patients. The hospital management recruited the existing personnel including the consultant neurosurgeon as a frontline doctor.

A 69-year-old female patient was referred from a nearby COVID-19 treatment hospital with 6-year history of recurrent seizures associated with 2-week history of progressive right hemibody weakness. She had history of contact and screening test was positive. She was a known

E-mail address: [okunlolaai@abuad.edu.ng](mailto:okunlolaai@abuad.edu.ng).

<https://doi.org/10.1016/j.inat.2020.101064>

Received 2 September 2020; Received in revised form 29 October 2020; Accepted 14 December 2020

Available online 21 December 2020

2214-7519/© 2020 The Author(s).

Published by Elsevier B.V. This is an open access article under the CC BY-NC-ND license

(<http://creativecommons.org/licenses/by-nc-nd/4.0/>).

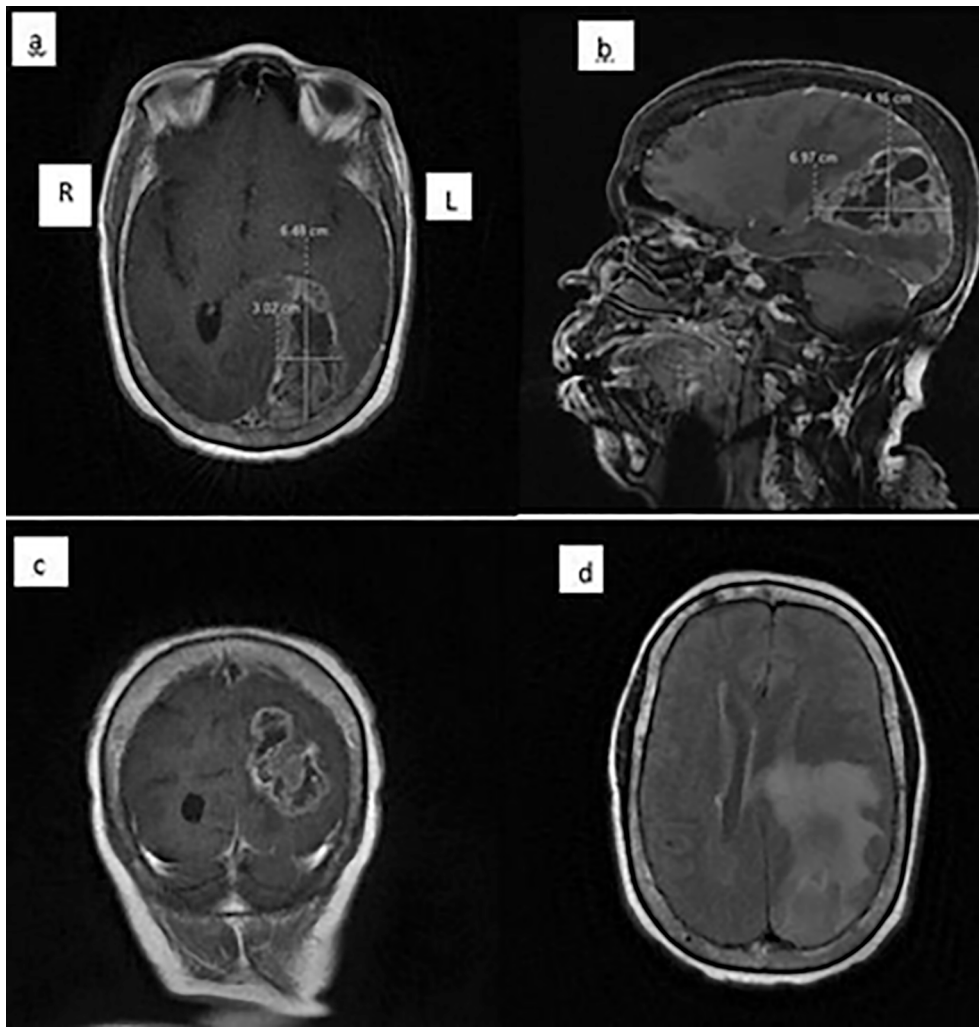


Fig. 1. Pre-operative brain MRI; a. T1C axial image, b. T1C sagittal image c. T1C coronal image and d. FLAIR image.

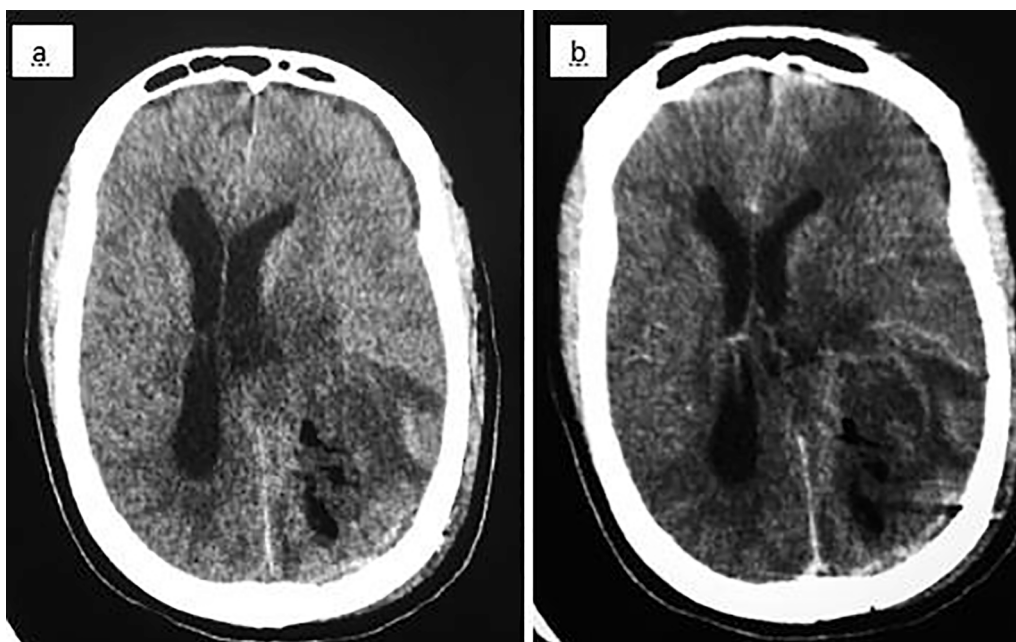


Fig. 2. Post-operative cranial CT images; a. pre-contrast image, b. post-contrast image.

hypertensive patient with good drug compliance.

Examination revealed an elderly woman with normal vital signs. She was awake and alert. There was right supra-nuclear facioparesis and right hemiplegia but detailed ophthalmic examination was not conducted to limit exposure. The examination of other systems was normal. Clinical diagnosis of left hemispheric deficit secondary to left supratentorial space occupying lesion was made. Brain MRI showed left parieto-occipital intra-axial tumor measuring 70 mm by 42 mm by 30 mm, extending from the ventricular lining to the cortical surface with irregular peripheral contrast enhancement and extensive perilesional edema extending to the motor strip (Fig. 1) Radiological diagnosis of glioblastoma was made and family desire surgery to improve quality of life and histological confirmation. Repeat COVID-19 screening was not possible in our hospital at the time of admission because of none availability of the testing kits.

She was admitted and scheduled for awake craniotomy and tumor excision. The surgery was scheduled for 8.00am but it was delayed till 11.00am because some staff declined participation in the surgery. The participation was voluntary and the hospital management provided full PPE for the 6-man team who participated in the surgery. All team members were on full Personal Protective Equipment including face shield and KN 95. The theatre positions were maintained which gave adequate distancing except the surgeon and assistant surgeon. The scrub nurse with the instrument tray was positioned on the far left, anesthetist machine was positioned on the far right with the anesthetist and technician on either side of the machine. The circulating nurse was at the corner offering assistance when needed. She was sedated with intravenous 1% propofol (60 mg bolus) for scalp nerve block with local anesthetic solution containing 0.5% xylocaine with adrenaline and 0.125% bupivacaine and she was thereafter awake throughout the procedure [8,11]. Limited intraoperative clinical observation was conducted to limit exposure of the personnel to COVID-19 and the patient applied the face mask throughout the procedure. Intra-operative communication with the patient was difficult and limited.

### 3. Result

The duration of surgery was 2 h. There was no need to convert to general anesthesia and she had immediate post-operative improvement in the motor function. Power improved from grade 0 to grade 3 on post-operative day one. Post-operative cranial CT scan showed gross total tumor excision (Fig. 2) and histology report showed glioblastoma. She was treated with Tab azithromycin 500 mg daily, and Tab Augmentin 1 g 12-hourly. Nasal swab for RT-PCR test was repeated on post-operative day 4. She also had a short course of intravenous dexamethasone which was tailed-off over a week. Result of the repeat RT-PCR test was negative and she was discharged home. Thirty-day post-operative review confirmed progressive motor gain. She was standing with minimal support.

### 4. Discussion

COVID-19 pandemic has lasted beyond six months. The effect is being felt in both developed and developing countries like ours. It poses challenges to patients care, both the COVID-19 positive and negative patients [4,12]. There are controversies about the peri-operative care with many suggesting routine COVID-19 screening for all surgical patients to prevent unnecessary exposure of the health care workers to this dreaded virus [7,9]. Some proposed the use of full PPEs for all surgical patients but this is not feasible due to inadequate supply which has affected almost all countries of the world. The initial attempt to postpone all elective neurosurgical cases is no longer feasible and we should modify our practice to optimize patients' outcome [7,9,13].

Neurosurgical procedure in COVID-19 patient is challenging since the operation field is close to the respiratory tract which has the highest concentration of the virus in the body [6]. There is also a high chance of

the virus spreading during intubation and awake craniotomy with no need for endotracheal intubation may be safer [7]. Major surgery like neurosurgical procedure in awake patient has its own challenges ranging from the possible anxiety generated by the sight of theatre equipment and unfamiliar faces to the stigmatization of the COVID-19 positive patients which may reflect in hospital staff attitudes. There is fear of contracting COVID-19 infection worldwide, healthcare workers are also inclusive knowing fully well that full PPE is not 100% protective [5]. It is reasonable, therefore, that some hospital staff may decline participation in surgical procedure in COVID-19 positive patient [13].

The index patient had high grade glioma in eloquent brain region and family desired surgery which require awake craniotomy in pre-COVID-19 period and we were able to achieve optimal tumor resection without additional morbidity using awake craniotomy in COVID-19 era. The intraoperative monitoring was a major challenge because the use of the face mask by the patient limits clinical observation.

The COVID-19 pandemic may last longer than previously predicted and we should adapt and modify our practice to optimize patients' care in the face of this deadly viral infection.

### 5. Conclusion

Awake craniotomy in COVID-19 positive patient with appropriate use of necessary PPE is achievable.

### Ethical approval

Institutional ethical approval was obtained.

### Declaration of Competing Interest

The authors declare that they have no known competing financial interests or personal relationships that could have appeared to influence the work reported in this paper.

### References

- [1] S. Khan, R. Siddique, A. Shereen, A. Ali, J. Liu, Q. Bai, et al., Emergence of a novel coronavirus, severe acute respiratory syndrome coronavirus 2: biology and therapeutic options, *J. Clin. Microbiol.* 58 (5) (2020) 1–11.
- [2] S. Anastasopoulou, A. Mouzaki, The biology of SARS-CoV-2 and the ensuing COVID-19, *Achaiki Iatriki* 39 (1) (2020) 29–35.
- [3] K.A. Adedokun, A.O. Olarinmoye, J.O. Mustapha, R.T. Kamarudeen, A close look at the biology of SARS-CoV-2, and the potential influence of weather conditions and seasons on COVID-19 case spread, *Infect. Dis. Poverty* 9 (77) (2020) 1–5.
- [4] G. Tsermoulas, A. Zisakis, G. Flint, A. Belli, Challenges to neurosurgery during the Coronavirus Disease 2019 (COVID-19) pandemic, *World Neurosurgery* 139 (2020) 519–525, <https://doi.org/10.1016/j.wneu.2020.05.108>.
- [5] D.W. Healy, B.H. Cloyd, M.J. Brenner, R.A. Kupfer, K.S. Anam, S.A. Schechtman, The COVID-19 pandemic: implications for the head and neck anesthesiologist, *J. Head Neck Anesth.* 4 (e26) (2020) 1–8.
- [6] A. Germanò, G. Raffa, F.F. Angileri, S.M. Cardali, F. Tomasello, Coronavirus Disease 2019 (COVID-19) and neurosurgery: literature and neurosurgical societies recommendations update, *World Neurosurgery* 139 (2020) e812–e817, <https://doi.org/10.1016/j.wneu.2020.04.181>.
- [7] P. Gupta, N. Muthukumar, V. Rajsheshkar, M. Tripathi, S. Thomas, S.K. Gupta, V. Lal, P. Pal, M. Abraham, S. Behari, V. Paliwal, D. Singh, S. Pandey, L. Narasimhan, D. Srinivas, S. Panda, S.S. Kale, P.S. Chandra, Neurosurgery and neurology practices during the novel COVID-19 Pandemic: a consensus statement from India, *Neurol. India* 68 (2) (2020) 246, <https://doi.org/10.4103/0028-3886.283130>.
- [8] Okunlola AI, Babalola OF, Okunlola CK, Akinmade A, Abiola P, Olayinka T. Awake craniotomy in neurosurgery : Shall we do it more often ? *Interdiscip Neurosurg* [Internet]. Elsevier; 2020;21(March):100770. Available from: <https://doi.org/10.1016/j.inat.2020.100770>.
- [9] B. Ozoner, A. Gungor, T. Hasanov, Z.O. Toktas, T. Kilic, Neurosurgical practice during Coronavirus Disease 2019 (COVID-19) pandemic, *World Neurosurgery* 140 (2020) 198–207, <https://doi.org/10.1016/j.wneu.2020.05.195>.
- [10] C.C. Snacc, A.M. Flexman, A.S. Abcejo, R. Avitsian, S.V. De, D. Highton, et al., Neuroanesthesia practice during the COVID-19 pandemic: recommendations from society for neuroscience, *J. Neurosurg. Anesth.* 32 (3) (2020) 202–209.
- [11] A.I. Okunlola, C.K. Okunlola, O.F. Babalola, P. Olowoyo, T.O. Orewole, A. P. Aremu, et al., Challenges and prospects of awake craniotomy in a resource-poor

setting, *Int. J. Neuro Brain Dis.* [Internet] 6 (1) (2019) 17–20. Available from: [www.omegaonline.org](http://www.omegaonline.org). Downloaded on 10/19/2019.

- [12] Y.-T. Tan, J.-W. Wang, K. Zhao, L. Han, H.-Q. Zhang, H.-Q. Niu, K. Shu, T. Lei, Preliminary recommendations for surgical practice of neurosurgery department in the central epidemic area of 2019 Coronavirus infection, *Curr. Med. Sci.* 40 (2) (2020) 281–284, <https://doi.org/10.1007/s11596-020-2173-5>.
- [13] C. Hojaij, I.L.A. Chinelatto, I.I. Gustavo, H. Pereira, Surgical practice in the current COVID-19 pandemic: a rapid systematic review, *Clinics* 75 (e1923) (2020) 1–6.