

Customized maxillary incisor position relative to dentoskeletal and soft tissue patterns in Chinese women: A retrospective study

Xueman Zhou 
Yingcheng Zheng 
Zhenzhen Zhang
Zihan Zhang
Lina Wu
Jiaqi Liu
Wenke Yang
Jun Wang 

State Key Laboratory of Oral Diseases,
National Clinical Research Center
for Oral Diseases, Department of
Orthodontics, West China Hospital
of Stomatology, Sichuan University,
Chengdu, Sichuan, China

Objective: To provide reliable prediction models based on dentoskeletal and soft tissue variables for customizing maxillary incisor positions and to optimize digitalized orthodontic treatment planning. **Methods:** This study included 244 Chinese women (age, 18–40 years old) with esthetic profiles after orthodontic treatment with fixed appliances (133 in group I: $1^\circ \leq$ The angle between the nasion [N]-A point [A] plane and the N-B point [B] plane [ANB] $\leq 4^\circ$; 111 in group II: $4^\circ < \text{ANB} \leq 7^\circ$). Dental, skeletal, and soft tissue measurements were performed on lateral cephalograms of the participants. Correlation and multiple linear regression analyses were used to determine the influence of dentoskeletal and soft tissue variables on maxillary incisor position. **Results:** The ideal anteroposterior position of the maxillary incisor varied between sagittal skeletal patterns. The position of the maxillary incisor correlated with the sagittal discrepancy between the maxilla and the mandible (ANB), protrusion of the midface, nasal tip projection, development of the chin, and inclination of both the maxillary and mandibular incisors. Distance from the maxillary central incisor to nasion-pogonion plane predicted using multiple linear regression analysis was accurate and could be a practical measurement in orthodontic treatment planning. **Conclusions:** Instead of using an average value or norm, orthodontists should customize a patient's ideal maxillary incisor position using dentoskeletal and soft tissue evaluations.

[Korean J Orthod 2022;52(2):150–160]

Key words: Customized maxillary incisor position, Dentoskeletal and soft tissue patterns, Cephalometrics, Mathematical approach

Received August 27, 2021; Revised October 21, 2021; Accepted November 13, 2021.

Corresponding author: Jun Wang.

Professor, Department of Orthodontics, West China Hospital of Stomatology, Sichuan University, No.14, 3rd section, Renmin South Road, Chengdu 610041, China.

Tel +86-18628146916 e-mail wangjunv@scu.edu.cn

Xueman Zhou and Yingcheng Zheng contributed equally to this work (as co-first authors).

How to cite this article: Zhou X, Zheng Y, Zhang Z, Zhang Z, Wu L, Liu J, Yang W, Wang J. Customized maxillary incisor position relative to dentoskeletal and soft tissue patterns in Chinese women: A retrospective study. Korean J Orthod 2022;52:150–160.

© 2022 The Korean Association of Orthodontists.

This is an Open Access article distributed under the terms of the Creative Commons Attribution Non-Commercial License (<http://creativecommons.org/licenses/by-nc/4.0>) which permits unrestricted non-commercial use, distribution, and reproduction in any medium, provided the original work is properly cited.

INTRODUCTION

Improving facial esthetics is critical in orthodontic treatment. Many cephalometric analyses have been proposed to standardize facial evaluation and orthodontic treatment planning and to develop cephalometric norms or analyses in order to define the dentoskeletal and soft tissue characteristics of a “good face.” The positions of the maxillary and mandibular incisors are important in determining the soft tissue profile.¹ In particular, the sagittal position and inclination of the incisors are highly relevant to lip and chin prominence.^{1,2} Thus, orthodontists must determine the ideal position of the incisors when formulating the treatment plan, selecting the extraction vs. non-extraction approach, and adopting an anchorage design.

Tweed³ indicated that the angle between the inclination of the mandibular incisors and the mandibular plane was essential for facial esthetics and tooth stability, but this supposition was only appropriate for treatment planning for patients with a normal sagittal skeletal relationship. With the advent of digitized and visualized orthodontic techniques, more emphasis has been placed on the ideal position of the maxillary incisors at the beginning of treatment planning. Researchers such as Downs,⁴ Steiner,⁵ McNamara,⁶ and Arnett et al.⁷ have all recommended evaluation methods for determining the ideal maxillary incisor sagittal position based on the relationship between the maxillary incisor and certain reference lines, such as U1-APog distance, U1-NA distance, U1-Np, and U1-Sn vert (see Fig. 1 and Table 1 for definitions of abbreviations mentioned in the text), but the accuracy of such indicators has not been evaluated in the Chinese population. Andrews and Andrews⁸ proposed the use of forehead position and angulation to determine the ideal sagittal position of the maxillary incisor in Element II of “The Six Elements of Orofacial Harmony,” but methods for acquiring a reproducible natural head position remain unsatisfactory.⁹ In addition, a small discrepancy in determining the goal anterior-limit line can result in a significant deviation in maxillary incisor positioning. Moreover, even patients with “normal” cephalometric values do not necessarily have perfect facial esthetics. Many perception studies determining the incisor position have shown that the ideal position of the maxillary incisors is related to dentoskeletal variables and soft tissue parameters.^{10,11}

With the emergence of the digital era of orthodontics, artificial intelligence (AI)-assisted digitalized orthodontic treatment planning has come into focus. However, almost all AI-assisted treatment planning programs still depend on the personal experience of orthodontists in terms of maxillary incisor position.¹² Therefore, accurately and objectively predicting the ideal position of the

maxillary incisors is a key challenge to be addressed in the development of systematic treatment planning.

To this end, the current study aimed to obtain reliable predictions of appropriate maxillary incisor positions through comprehensive evaluations of skeletal, dental, and soft tissue measurements on cephalometric graphs of participants with esthetic facial profiles and to optimize digitalized orthodontic treatment planning.

MATERIALS AND METHODS

Study participants and design

This retrospective observational study was approved by the Ethics Committee of the West China Hospital of Stomatology, Sichuan University (WCHSIRB-2021-166). The participants were recruited from among Chinese women who had completed orthodontic treatment between January 2018 and December 2020, according to the following inclusion criteria: (1) young women (age, 18–40 years old) who had received orthodontic treatment with fixed appliances; (2) $1^\circ \leq \text{ANB} \leq 7^\circ$; (3) an esthetic lateral profile according to the esthetic plane (EP): $-4 \text{ mm} \leq \text{UL-EP} \leq 0 \text{ mm}$ and $\text{LL-EP} \leq 1 \text{ mm}$ ^{13,14}; (4) no crowding and spacing, normal or totally distal occlusion, and normal overjet and overbite; and (5) good facial symmetry. The exclusion criteria were as follows: history of (1) functional orthopedic treatment; (2) surgery on the maxilla, mandible, or chin; (3) facial plastic surgeries; and (4) craniofacial defects or syndromes, e.g., cleft lip and palate.

The collected data included age at the beginning and completion of treatment, intraoral and facial photographs, and panoramic and lateral radiographic images. Participants with incomplete data were excluded. Profile photographs of the selected women were evaluated by three Chinese orthodontic specialists (professional group) and three Chinese laypersons (layperson group) to determine whether the facial profile is well-balanced. The evaluators had 3 response options (1, unpleasant; 2, acceptable; and 3, pleasant). Patients who were evaluated as “pleasant” by more than two evaluators in each evaluation group, with no “unpleasant”, were selected. In total, 498 patients who satisfied the inclusion criteria were included initially, while 254 were excluded; finally, 244 individuals were selected for further study after esthetic evaluation. The selected participants were divided into two groups: group I (skeletal Class I, $1^\circ \leq \text{ANB} \leq 4^\circ$) and group II (skeletal Class II, $4^\circ < \text{ANB} \leq 7^\circ$).

Data collection

The lateral cephalograms of the selected participants were acquired using a cephalometer (Veraviewepocs; Morita, Kyoto, Japan) with the head in a natural position, the teeth in centric occlusion, and the lips in the

resting position. Thereafter, Uceph software (version 4.3.2; Uceph, Chengdu, China) was used to adjust the cephalograms with the Frankfort plane parallel to the horizontal plane and to perform cephalometric tracing and analysis.

The radiographic magnification of the cephalograms was standardized at 100% actual size with a 200 mm metal ruler image captured in the digital film as the reference. Sixteen hard and nine soft tissue landmarks were identified on each digitized cephalogram (Figure 1). The skeletal, dental, and soft tissue measurements (Table 1) were then computed according to the reference lines.

First, differences in all measurements between two groups based on the sagittal skeletal pattern (ANB angle) were compared. Thereafter, indicators related to the sagittal position of maxillary incisor were analyzed with the others via linear correlation. The indicators directly

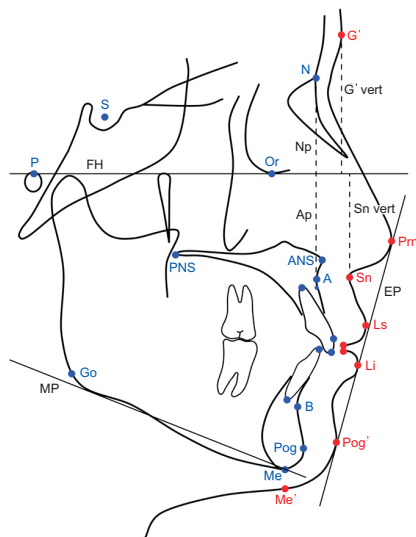


Figure 1. Reference planes and landmarks used in this study. Reference planes: Frankfort horizontal plane (FH), a plane passing through the porion and orbitale; Esthetic plane (EP), a plane passing through the pronasale and tangent to the chin; Mandibular plane (MP), a plane passing through the menton and tangent to the posterior portion of the lower border of the mandible; Np, a line passing through the nasion and perpendicular to the FH plane; Ap, a line passing through the A point and perpendicular to the FH plane; G' vert, a line passing through the glabella and perpendicular to the FH plane; Sn vert, a line passing through the subnasale and perpendicular to the FH plane. Landmarks: S, sella; N, nasion; Or, orbitale; P, porion; Go, gonion; A, A point; B, B point; Pog, pogonion; Me, menton; ANS, anterior nasal spine; PNS, posterior nasal spine; Prn, pronasale; Sn, subnasale; Ls, labrale superius; Li, labrale inferius; G', glabella; Pog', pogonion of soft tissue; Me', menton of soft tissue.

related to the sagittal position of maxillary incisor were then screened out and used to obtain prediction models via stepwise multiple linear regression analysis. Finally, the prediction models were tested on a new sample of 30 women who had completed orthodontic treatment between January 2021 and April 2021, and satisfied the inclusion criteria. The esthetic evaluations of these new women were also performed by the same evaluators. Radiographs acquired before and after treatment were all measured and analyzed. The outcomes were compared with the actual values on the posttreatment cephalograms to estimate the accuracy of the regression models.

Both intraexaminer and interexaminer reliabilities were evaluated using the Bland–Altman method and intraclass correlation coefficients. Thirty randomly selected lateral cephalograms were digitized and measured twice by two independent examiners. Each examiner repeated the measurements after an interval of 2 weeks. The intraexaminer correlation coefficient of the cephalometric analysis was excellent, ranging from 0.90 to 0.97. The interexaminer reliability was also excellent, ranging from 0.91 to 0.94.

Statistical analysis

All statistical analyses were performed using IBM SPSS Statistics for Windows, Version 26.0 (IBM Corp., Armonk, NY, USA). Statistical analyses demonstrated a normal distribution of the data according to the Kolmogorov–Smirnov test ($p > 0.05$). The independent *t*-test was used to compare the mean values of the measurements between the two groups. Pearson correlation analysis was performed to identify the relationships between the skeletal, dental, and soft tissue variables and the sagittal maxillary incisor position. Stepwise multiple linear regression analysis was used to detect whether the variables were helpful in predicting the sagittal location of the maxillary central incisor. A *p*-value less than 0.05 was considered statistically significant.

RESULTS

In total, 244 women were included in this study: 133 in group I (mean age, 26.6 ± 6.7 years) and 111 in group II (mean age, 27.1 ± 6.4 years). The anteroposterior position of the maxillary incisors in group II was more protruded than that in group I. The L1–NB values (distance and angle) were significantly lower in group I than in group II. The maxillary incisor showed more lingual tipping (U1–NA angle and U1–SN) and the mandibular incisors (L1–NB angle and FMIA) showed significantly more labial tipping in group II than in group I. Interestingly, no significant difference in the U1–L1 angle was found between two groups (Table 2).

Pearson correlation analysis showed that the ideal

Table 1. Definitions of measurements used in the cephalometric analysis

Cephalometric analysis index	Definition
ANB (°)	The angle between the NA plane and the NB plane
SNA (°)	The angle between the NA plane and the SN plane
SNB (°)	The angle between the NB plane and the SN plane
A-Np (mm)	Distance from A point to Np
Pog-Np (mm)	Distance from pogonion to Np
Pog-NB (mm)	Distance from pogonion to NB plane
FMA (°)	The angle between the FH plane and the MP
SN-MP (°)	The angle between the MP and the SN plane
S-Go/N-Me (%)	The ratio of S-Go and N-Me
U1-APog (mm)	Distance from upper central incisor (U1) to APog plane
U1-Np (mm)	Distance from the most prominent labial point of U1 to Np
U1-Ap (mm)	Distance from the most prominent labial point of U1 to Ap
U1-NA (mm)	Distance from U1 to NA plane
U1-NPog (mm)	Distance from U1 to NPog plane
U1-G' vert (mm)	Distance from the most prominent labial point of U1 to G' vert
U1-Sn vert (mm)	Distance from U1 to Sn vert
L1-APog (mm)	Distance from lower central incisor (L1) to APog plane
L1-NB (mm)	Distance from L1 to NB plane
L1-NPog (mm)	Distance from L1 to NPog plane
U1-L1 (°)	The intersection angle of the long axis of U1 and L1
U1-APog (°)	The intersection angle of the long axis of U1 and APog plane
U1-NA (°)	The intersection angle of the long axis of U1 and NA plane
U1-SN (°)	The intersection angle of the long axis of U1 and SN plane
L1-APog (°)	The intersection angle of the long axis of L1 and APog plane
L1-NB (°)	The intersection angle of the long axis of L1 and NB plane
IMPA (°)	The intersection angle of the long axis of L1 and MP
FMIA (°)	The intersection angle of the long axis of L1 and FH plane
U1 exposure (mm)	Vertical distance from U1 to the lowest point of the upper lip (Stms) perpendicular to the FH plane
UL-EP (mm)	Distance from labrale superius to EP
LL-EP (mm)	Distance from labrale inferius to EP
Basic upper lip thickness (mm)	Distance from 3 mm below A point to subnasale
Upper lip thickness (mm)	Distance from the most prominent labial point of U1 to labrale superius
Upper lip length (mm)	Vertical distance from subnasale to Stms perpendicular to the FH plane
Pog-Pog' (mm)	Distance from pogonion to its sagittal projection on the soft tissue
Stmi-Me' (mm)	Vertical distance from the highest point of the lower lip (Stmi) to the menton of soft tissue perpendicular to the FH plane
Sn-Me' (mm)	Vertical distance from subnasale to the menton of soft tissue perpendicular to the FH plane
Prn-Sn vert (mm)	Distance from pronasale to Sn vert
UL-Sn vert (mm)	Distance from labrale superius to Sn vert
Pog'-Sn vert (mm)	Distance from pogonion of soft tissue to Sn vert

See Figure 1 for definitions of each landmark.

Table 2. Dentoskeletal and soft tissue measurements (means and standard deviations) for all participants

Measurement	Group I		Group II		p-value
	Mean	Standard deviation	Mean	Standard deviation	
Skeletal measurements					
ANB (°)	2.62	0.80	5.01	0.64	< 0.001***
SNA (°)	80.83	2.75	82.52	3.69	< 0.001***
SNB (°)	78.21	2.74	77.54	3.85	0.111
A-Np (mm)	-0.12	1.09	1.79	0.89	< 0.001***
Pog-Np (mm)	-3.00	1.66	-4.59	1.91	< 0.001***
Pog-NB (mm)	2.11	1.00	1.50	0.96	< 0.001***
FMA (°)	24.49	3.89	25.24	3.92	0.136
SN-MP (°)	33.53	4.74	34.51	5.45	0.134
S-Go/N-Me (%)	66.81	3.67	66.11	4.11	0.161
Dental measurements					
U1-APog (mm)	4.93	1.26	5.22	1.48	0.104
U1-Np (mm)	3.61	1.25	4.37	1.20	< 0.001***
U1-Ap (mm)	3.73	1.17	2.60	1.27	< 0.001***
U1-NA (mm)	3.78	1.35	2.08	1.27	< 0.001***
U1-NPog (mm)	5.82	1.51	7.73	1.64	< 0.001***
U1-G' vert (mm)	-4.61	1.81	-3.10	1.54	< 0.001***
U1-Sn vert (mm)	-9.15	1.73	-9.17	1.71	0.918
L1-APog (mm)	1.53	1.33	1.66	1.73	0.510
L1-NB (mm)	3.99	1.43	5.31	1.51	< 0.001***
L1-NPog (mm)	2.59	1.40	4.27	1.89	< 0.001***
U1-L1 (°)	128.86	7.36	127.86	7.73	0.305
U1-APog (°)	27.03	4.76	29.39	5.10	< 0.001***
U1-NA (°)	23.72	4.48	20.16	4.56	< 0.001***
U1-SN (°)	104.56	5.04	102.69	6.30	0.011*
L1-APog (°)	24.11	4.81	22.75	4.15	0.020*
L1-NB (°)	24.80	4.80	26.99	4.28	< 0.001***
IMPA (°)	93.80	6.67	94.86	5.58	0.185
FMIA (°)	61.71	5.04	59.90	4.56	0.004**
U1 exposure (mm)	2.31	1.31	2.32	1.43	0.951
Soft tissue measurements					
UL-EP (mm)	-2.32	1.09	-1.94	1.09	0.008**
LL-EP (mm)	-1.06	0.99	-0.61	1.07	0.001**
Basic upper lip thickness (mm)	14.80	1.48	14.06	1.27	< 0.001***
Upper lip thickness (mm)	13.06	1.88	13.05	1.47	0.989
Upper lip length (mm)	20.06	1.65	20.92	1.61	< 0.001***
Pog-Pog' (mm)	11.42	1.43	12.16	1.39	< 0.001***
Stmi-Me' (mm)	41.81	2.68	41.92	3.22	0.767
Sn-Me' (mm)	67.28	3.76	68.97	4.18	0.001**
Prn-Sn vert (mm)	12.36	1.49	12.66	1.59	0.128
UL-Sn vert (mm)	2.97	1.08	2.82	1.12	0.285
Pog'-Sn vert (mm)	-4.52	1.93	-6.10	2.08	< 0.001***

* $p < 0.05$; ** $p < 0.01$; *** $p < 0.001$.

See Figure 1 and Table 1 for definitions of each landmark or measurement.

position of the maxillary incisor was most correlated with the sagittal discrepancy between the maxilla and mandible (ANB), protrusion of the midface (A-Np), nasal tip projection (Prn-Sn vert), and development of the chin (Pog-NB and Pog'-Sn vert). Additionally, U1-APog distance, U1-NPog, and U1-G' vert showed positive correlations with SN-MP and FMA. In addition, U1-APog distance and U1-NPog positively correlated with most of the soft tissue variables, including upper and lower lip lengths (Stmi-Me'), lower facial height (Sn-Me'), and the thickness of the soft tissue of the chin (Pog-Pog'). Moreover, the anteroposterior position of the maxillary incisors showed a close correlation with the inclination of both the maxillary and mandibular incisors (Table 3). Notably, among all measurements evaluating the sagittal position of the maxillary incisor, only the distance of U1-Sn vert showed a correlation with upper lip thickness, even though the distances of U1-Ap, U1-NA, and U1-Sn

vert correlated with basic upper lip thickness (Table 4).

Multivariate regression analysis revealed that the sagittal position of the maxillary incisors was generally influenced by Prn-Sn vert, A-Np, and U1-L1. Moreover, U1-Ap, U1-NA distance, and U1-Sn vert were associated with U1-NA angle and L1-APog angle. Among all the multivariate regression analyses related to maxillary incisor position, analysis of U1-NPog showed the highest adjusted R² value (Table 5). The multiple correlation analysis between predicted U1-NPog value (Y) and the skeletal, dental, and soft tissue variables was $Y = 12.812 - 0.542^* (Pog-Np) + 0.496^* (A-Np) - 0.086^* (U1-L1) + 0.206^* (Prn-Sn\ vert)$. The multivariable prediction equation for U1-NPog could explain 76.4% of the variability. In addition, the adjusted R² values in the analysis for U1-Sn vert, U1-NA distance, U1-Ap, and U1-APog distance were all above 0.5, indicating a goodness-of-fit.

Finally, the regression models were tested on 30 new

Table 3. Pearson correlation coefficients between the maxillary incisor position and skeletal and dental variables

Measurement	U1-APog (mm)	U1-Np (mm)	U1-Ap (mm)	U1-NA (mm)	U1-NPog (mm)	U1-G' vert (mm)	U1-Sn vert (mm)
Skeletal measurements							
ANB (°)	0.100	0.326**	-0.512**	-0.646**	0.596**	0.453**	-0.083
SNA (°)	0.039	0.227**	-0.054	-0.152*	0.133*	-0.049	0.075
SNB (°)	-0.005	0.092	0.160*	0.117	-0.118	-0.239**	0.110
A-Np (mm)	-0.168**	0.489**	-0.560**	-0.732**	0.306**	0.435**	-0.107
Pog-Np (mm)	-0.533**	0.078	0.040	0.037	-0.720**	-0.112	-0.045
Pog-NB (mm)	-0.315**	-0.276**	0.131*	0.232**	-0.561**	-0.165*	-0.060
FMA (°)	0.293**	0.113	0.003	-0.027	0.424**	0.215**	0.030
SN-MP (°)	0.158*	0.088	-0.107	-0.114	0.321**	0.309**	-0.052
S-Go/N-Me (%)	-0.127*	-0.054	0.028	0.016	-0.206**	-0.277**	0.004
Dental measurements							
L1-APog (mm)	0.848**	0.491**	0.628**	0.530**	0.717**	0.255**	0.403**
L1-NB (mm)	0.763**	0.554**	0.346**	0.213**	0.844**	0.435**	0.307**
L1-NPog (mm)	0.733**	0.541**	0.214**	0.067	0.901**	0.402**	0.261**
U1-L1 (°)	-0.581**	-0.390**	-0.451**	-0.368**	-0.525**	-0.224**	-0.354**
U1-Apog (°)	0.510**	0.390**	0.232**	0.143*	0.627**	0.294**	0.263**
U1-NA (°)	0.404**	0.142*	0.616**	0.630**	0.143*	-0.021	0.322**
U1-SN (°)	0.365**	0.253**	0.491**	0.445**	0.199**	-0.046	0.317**
L1-APog (°)	0.396**	0.212**	0.488**	0.449**	0.175**	0.045	0.293**
L1-NB (°)	0.483**	0.382**	0.239**	0.130*	0.517**	0.246**	0.260**
IMPA (°)	0.235**	0.167**	0.187**	0.133*	0.184**	0.053	0.182**
FMIA (°)	-0.527**	-0.314**	-0.234**	-0.143*	-0.568**	-0.238**	-0.250**
U1 exposure (mm)	-0.035	-0.133*	-0.042	-0.011	-0.090	-0.054	0.082

Variables showing significant correlation coefficients are shown in the table.

p* < 0.05; *p* < 0.01.

See Figure 1 and Table 1 for definitions of each landmark or measurement.

Table 4. Pearson correlation coefficients between the maxillary incisor position and soft tissue variables

Measurement	U1-APog (mm)	U1-Np (mm)	U1-Ap (mm)	U1-NA (mm)	U1-NPog (mm)	U1-G' vert (mm)	U1-Sn vert (mm)
Soft tissue measurements							
UL-EP (mm)	0.027	0.096	-0.188**	-0.266**	0.199**	0.201**	-0.086
LL-EP (mm)	0.272**	0.185**	0.010	-0.063	0.391**	0.294**	0.132*
Basic upper lip thickness (mm)	0.068	-0.064	0.219**	0.250**	-0.074	-0.104	-0.658**
Upper lip thickness (mm)	-0.052	-0.047	-0.035	-0.044	-0.036	-0.116	-0.370**
Upper lip length (mm)	0.223**	0.096	-0.046	-0.088	0.323**	0.114	-0.010
Pog-Pog' (mm)	0.416**	0.215**	0.087	0.047	0.511**	0.030	-0.022
Stmi-Me' (mm)	0.261**	0.092	0.205**	0.209**	0.216**	-0.108	0.058
Sn-Me' (mm)	0.345**	0.130*	0.096	0.067	0.401**	0.013	-0.049
Prn-Sn vert (mm)	0.375**	0.151*	0.238**	0.237**	0.314**	0.110	0.231**
UL-Sn vert (mm)	0.168**	0.150*	0.177**	0.143*	0.094	0.023	0.450**
Pog'-Sn vert (mm)	-0.187**	-0.079	0.194**	0.249**	-0.422**	-0.256**	0.490**

Variables showing significant correlation coefficients are shown in the table.

* $p < 0.05$; ** $p < 0.01$.

See Figure 1 and Table 1 for definitions of each landmark or measurement.

women who had completed treatment. The measurement values of pretreatment skeletal and soft tissue variables were entered into the regression equations, using the means of incisor inclination from Table 2. Some variations were found between the actual and predicted values of the regression models. The differences between the actual and predicted mean values of the variables are shown in Table 6.

DISCUSSION

The position of the maxillary incisors is crucial for achieving an esthetic facial profile, and the concept of a planned incisor position has become indispensable to orthodontists.^{15,16} Previous studies demonstrated that certain variables associated with the incisor position, such as the distance from the maxillary and mandibular incisors to the AP-line or NA-line, significantly correlated with subjective facial evaluation.^{5,6,17} However, since dental and skeletal structures and soft tissues vary between individuals, orthodontists must formulate customized treatment plans rather than try to achieve normal mean values. By using multiple linear regression, this study aimed to provide accurate predictions of appropriate maxillary incisor positions based on individual dentoskeletal and soft tissue cephalometric measurements to facilitate treatment planning.

The interrelationships of the nose, lip, and chin play an important role in the perception of facial esthetics, and several reference lines have been introduced for this purpose. One of the most well-known analyses is the E-line described by Ricketts,¹⁸ as part of his computerized

cephalometric analysis. The esthetic plane developed by Ricketts has been found sensitive in facial esthetic assessments and is recommended for discerning beautiful profiles.¹⁷⁻²⁰ Huang and Li¹⁷ assessed Chinese patients and found that retraction of their lips in relation to the E-line correlated with an improvement in attractiveness ratings. Therefore, we applied this finding as a reference and included patients whose upper and lower lips were at the normal distance from Ricketts' E-line, as indicated by previous studies.¹⁴

In this study, group II showed a more protruded maxilla (a significantly greater SNA degree and A-Np distance) and retrusive chin (significantly lower Pog-Np and Pog-NB distance) features than did group I. The anteroposterior position of the lips in group II was significantly more protrusive than that in group I, indicating that in accordance with a previous study, a protrusive lower lip could achieve facial balance with retrusive chin morphology in skeletal Class II malocclusion.¹⁷ The upper lip length between skeletal Class I and Class II malocclusions showed no significant difference, as previously reported.²¹ However, we found that the characteristics of some soft tissue measurements, such as basic upper lip thickness, soft tissue chin thickness, and upper lip length, according to the sagittal skeletal pattern were distinct with significant differences (Table 2). Basic upper lip thickness in group II was significantly lower than that in group I, while soft tissue chin thickness in group II was greater than that in group I. These observations can be explained as a natural effort of the soft tissues to compensate for the protruded maxilla and a retrusive chin to mask the condition and to provide a more bal-

Table 5. Results of multiple linear regression

Dependent variable	Adjusted R ²	Independent variable	B	SE	Beta	t	p-value
U1-APog (mm)	0.541	constant	18.428	2.376		7.756	< 0.001***
		U1-L1 (°)	-0.105	0.011	-0.576	-9.641	< 0.001***
		Pog-Np (mm)	-0.200	0.034	-0.283	-5.821	< 0.001***
		Prn-Sn vert (mm)	0.249	0.040	0.280	6.155	< 0.001***
		IMPA (°)	-0.039	0.013	-0.177	-3.113	0.002**
U1-Np (mm)	0.421	constant	13.061	1.071		12.195	< 0.001***
		A-Np (mm)	0.486	0.045	0.524	10.704	< 0.001***
		U1-L1 (°)	-0.074	0.008	-0.433	-8.841	< 0.001***
U1-Ap (mm)	0.728	constant	1.363	0.510		2.671	0.008**
		L1-APog (°)	0.461	0.035	0.524	13.089	< 0.001***
		ANB (°)	-0.447	0.036	-0.465	-12.391	< 0.001***
		U1-NA (°)	0.060	0.012	0.217	5.185	< 0.001***
		Prn-Sn vert (mm)	0.116	0.030	0.134	3.825	< 0.001***
U1-NA (mm)	0.694	constant	-2.443	0.593		-4.122	< 0.001***
		A-Np (mm)	-0.581	0.046	-0.516	-12.690	< 0.001***
		U1-NA (°)	0.107	0.014	0.331	7.848	< 0.001***
		Prn-Sn vert (mm)	0.182	0.036	0.180	5.013	< 0.001***
		L1-APog (°)	0.054	0.013	0.157	4.026	< 0.001***
U1-NPog (mm)	0.764	constant	12.812	1.163		11.019	< 0.001***
		Pog-Np (mm)	-0.542	0.032	-0.573	-16.803	< 0.001***
		A-Np (mm)	0.496	0.042	0.374	11.916	< 0.001***
		U1-L1 (°)	-0.086	0.008	-0.354	-10.697	< 0.001***
		Prn-Sn vert (mm)	0.206	0.039	0.173	5.343	< 0.001***
U1-G' vert (mm)	0.251	constant	3.877	1.757		2.207	0.028*
		A-Np (mm)	0.610	0.074	0.456	8.193	< 0.001***
		U1-L1 (°)	-0.064	0.014	-0.262	-4.698	< 0.001***
U1-Sn vert (mm)	0.722	constant	-2.936	0.819		-3.587	< 0.001***
		Basic upper lip thickness (mm)	-0.910	0.042	-0.763	-21.759	< 0.001***
		U1-NA (°)	0.159	0.013	0.448	11.876	< 0.001***
		Prn-Sn vert (mm)	0.165	0.038	0.148	4.330	< 0.001***
		L1-APog (°)	0.059	0.014	0.156	4.233	< 0.001***

p* < 0.05; *p* < 0.01; ****p* < 0.001.

See Figure 1 and Table 1 for definitions of each landmark or measurement.

Table 6. Result of testing the mean prediction equations on 30 new participants

	U1-NPog (mm)	U1-Ap (mm)	U1-Sn vert (mm)	U1-NA (mm)	U1-APog (mm)
Real values	6.96	2.33	-9.87	1.98	4.60
Regression model	7.44	2.95	-9.12	2.59	5.32
Difference	-0.48	-0.62	-0.75	-0.61	-0.72

Real values of the posttreatment cephalograms and predicted values on pretreatment cephalograms.

See Figure 1 and Table 1 for definitions of each landmark or measurement.

anced facial appearance.^{21,22}

For incisor positioning, Tweed³ emphasized the mandibular incisors while Andrews²³ and Steiner⁵ focused on maxillary incisor position. However, contradictions often occur between treatment goals estimated using different analysis methods and meeting all the standards is unreasonable for most patients treated. Thus, the treatment goal should be set with proper compensation according to the dentoskeletal pattern and soft tissue morphology.

The position and angulation of the maxillary and mandibular incisors have been proposed to compensate for skeletal discrepancy.²⁴ Meanwhile, the labiolingual inclination of the maxillary and mandibular incisors is a key factor influencing facial attractiveness.^{11,16,25} Orthodontists must balance the anteroposterior position and the inclination of the incisors to achieve harmonious facial profiles in patients undergoing orthodontic treatment.²⁶ Previous studies have shown that normal and slightly proclined mandibular incisors were acceptable, whereas greater proclination resulted in a disruption of facial esthetics.²⁷ In this study, we found that the maxillary incisors were more retracted and lingually tipped while the mandibular incisors were more proclined in skeletal Class II malocclusion than in skeletal Class I malocclusion for the benefit of the esthetic profile (Table 2), and a close correlation existed between maxillary incisor anteroposterior position and inclination (Table 3).

An esthetic profile feature with proper labial position and the underlying incisor position depends on coordination among different facial parts, mainly nose and chin morphology and lip thickness.²⁸ In fact, both the depth and prominence of the nose are unaffected by orthodontic treatment. Additionally, soft tissues around the chin region and upper lip thickness have been reported to be relatively stable.^{2,29} In this study, Pearson correlation analysis showed that variables associated with ideal maxillary incisor position generally showed strong correlations with nose and chin morphology. The distances of U1-APog, U1-Ap, U1-NA, U1-NPog, and U1-Sn vert positively correlated with the prominence of the nose; moreover, U1-APog distance, U1-Np, and U1-Sn vert showed positive correlations with soft tissue chin thickness. Taken together, these results suggest that nose and chin morphology should be considered variants to predict ideal upper incisor position and that a more protrusive maxillary incisor position is more harmonious with a prominent nose and chin.³⁰ For the upper lip, our results showed that only the distance of the U1-Sn vert correlated with maxillary lip thickness, and the distances of U1-Ap, U1-NA, and U1-Sn correlated with basic upper lip thickness. However, the ideal sagittal positions of maxillary incisors relative to the planes of A-Pog, Np, N-Pog, and G' vert showed no correlations with upper lip thickness. These findings indicated that although the

thickness of the upper lip affects the profile, the ideal sagittal position of the maxillary incisor need not be predicted in every evaluation method.

In the stepwise multiple linear regression analysis, the independent variables used in each regression model test were selected according to the results of the correlation tests (Tables 3 and 4). The adjusted R² value indicated that the multivariable prediction equation for U1-NPog distance could explain 76.4% of the variability (72.2% for U1-Sn vert). Additionally, in the comparison of means between the results derived from the prediction equations of the pretreatment cephalograms and actual results of the posttreatment cephalograms, the prediction accomplished using multivariable regression analysis was fairly accurate, especially for U1-NPog (Table 6). Therefore, the obtained regression equation can be used for forecasting outcomes to a satisfactory degree, and in the future, these models might benefit from improvements in software programs that would enable better maxillary incisor positioning, treatment planning, and setting visual treatment objectives.

The major limitation of the study is the subjectivity. The conclusions of this study are limited to women with skeletal Class I and skeletal Class II malocclusions. Therefore, further studies should expand the sample size to include all the groups representing a specific category. Additionally, the growth and development of skeletal and soft tissues are complete in adults. Therefore, growth was not considered in this study. Hence, future studies are warranted to determine whether the current findings are applicable to adolescent patients with growth and development potential during orthodontic treatment. In addition, in the regression equations, the values of the independent variables are the pretreatment measurements. Therefore, in orthodontic camouflage treatment for patients with severe skeletal deformity, where the Pog-point and A-point might change considerably after a large amount of tooth movement or mandibular rotation, these models require appropriate adjustments.

CONCLUSION

The appropriate position of the maxillary incisor is distinct in different sagittal skeletal patterns. The ideal position of the maxillary incisor correlated with the sagittal discrepancy between the maxilla and mandible, nose and chin morphology, and inclination of the maxillary and mandibular incisors. With the regression models, the ideal maxillary incisor position could be feasibly predicted using the U1-NPog distance calculated using dentoskeletal and soft tissue variables. Therefore, instead of using average values or norms, orthodontists must predict ideal, customized maxillary incisor positions

based on a thorough consideration of dentoskeletal and soft tissue patterns.

CONFLICTS OF INTEREST

No potential conflict of interest relevant to this article was reported.

ACKNOWLEDGEMENTS

This work was supported by the National Natural Science Foundation of China (No. 81771114 and No. 81970967).

REFERENCES

- Hayashida H, Ioi H, Nakata S, Takahashi I, Counts AL. Effects of retraction of anterior teeth and initial soft tissue variables on lip changes in Japanese adults. *Eur J Orthod* 2011;33:419-26.
- Lu W, Zhang X, Mei L, Wang P, He J, Li Y, et al. Orthodontic incisor retraction caused changes in the soft tissue chin area: a retrospective study. *BMC Oral Health* 2020;20:108.
- Tweed CH. The Frankfort-mandibular plane angle in orthodontic diagnosis, classification, treatment planning, and prognosis. *Am J Orthod Oral Surg* 1946;32:175-230.
- Downs WB. Variations in facial relationships; their significance in treatment and prognosis. *Am J Orthod* 1948;34:812-40.
- Steiner C. The use of cephalometrics as an aid to planning and assessing orthodontic treatment: report of a case. *Am J Orthod* 1960;46:721-35.
- McNamara JA Jr. A method of cephalometric evaluation. *Am J Orthod* 1984;86:449-69.
- Arnett GW, Jelic JS, Kim J, Cummings DR, Beress A, Worley CM Jr, et al. Soft tissue cephalometric analysis: diagnosis and treatment planning of dentofacial deformity. *Am J Orthod Dentofacial Orthop* 1999;116:239-53.
- Andrews LF, Andrews WA. The six elements of orofacial harmony. *Andrews J* 2000;1:13-22.
- Tian K, Li Q, Wang X, Liu X, Wang X, Li Z. Reproducibility of natural head position in normal Chinese people. *Am J Orthod Dentofacial Orthop* 2015;148:503-10.
- El Asmar R, Akl R, Ghoubril J, El Khoury E. Evaluation of the ideal position of the maxillary incisor relative to upper lip thickness. *Am J Orthod Dentofacial Orthop* 2020;158:264-72.
- Zarif Najafi H, Oshagh M, Khalili MH, Torkan S. Esthetic evaluation of incisor inclination in smiling profiles with respect to mandibular position. *Am J Orthod Dentofacial Orthop* 2015;148:387-95.
- Zhang X, Mei L, Yan X, Wei J, Li Y, Li H, et al. Accuracy of computer-aided prediction in soft tissue changes after orthodontic treatment. *Am J Orthod Dentofacial Orthop* 2019;156:823-31.
- Gu Y, McNamara JA Jr, Sigler LM, Baccetti T. Comparison of craniofacial characteristics of typical Chinese and Caucasian young adults. *Eur J Orthod* 2011;33:205-11.
- Chong HT, Thea KW, Descallar J, Chen Y, Dalci O, Wong R, et al. Comparison of White and Chinese perception of esthetic Chinese lip position. *Angle Orthod* 2014;84:246-53.
- Kuhn M, Markic G, Doulis I, Göllner P, Patcas R, Hänggi MP. Effect of different incisor movements on the soft tissue profile measured in reference to a rough-surfaced palatal implant. *Am J Orthod Dentofacial Orthop* 2016;149:349-57.
- Cao L, Zhang K, Bai D, Jing Y, Tian Y, Guo Y. Effect of maxillary incisor labiolingual inclination and anteroposterior position on smiling profile esthetics. *Angle Orthod* 2011;81:121-9.
- Huang YP, Li WR. Correlation between objective and subjective evaluation of profile in bimaxillary protrusion patients after orthodontic treatment. *Angle Orthod* 2015;85:690-8.
- Ricketts RM. Cephalometric synthesis: an exercise in stating objectives and planning treatment with tracings of the head roentgenogram. *Am J Orthod* 1960;46:647-73.
- Khosravanifard B, Rakhshan V, Raeesi E. Factors influencing attractiveness of soft tissue profile. *Oral Surg Oral Med Oral Pathol Oral Radiol* 2013;115:29-37.
- Ricketts RM. Esthetics, environment, and the law of lip relation. *Am J Orthod* 1968;54:272-89.
- Lee YJ, Park JT, Cha JY. Perioral soft tissue evaluation of skeletal Class II Division 1: a lateral cephalometric study. *Am J Orthod Dentofacial Orthop* 2015;148:405-13.
- Blanchette ME, Nanda RS, Currier GF, Ghosh J, Nanda SK. A longitudinal cephalometric study of the soft tissue profile of short- and long-face syndromes from 7 to 17 years. *Am J Orthod Dentofacial Orthop* 1996;109:116-31.
- Andrews WA. AP relationship of the maxillary central incisors to the forehead in adult white females. *Angle Orthod* 2008;78:662-9.
- Scott Conley R, Jernigan C. Soft tissue changes after upper premolar extraction in Class II camouflage therapy. *Angle Orthod* 2006;76:59-65.
- Ghaleb N, Bouserhal J, Bassil-Nassif N. Aesthetic evaluation of profile incisor inclination. *Eur J Orthod* 2011;33:228-35.

26. Chirivella P, Singaraju GS, Mandava P, Reddy VK, Neravati JK, George SA. Comparison of the effect of labiolingual inclination and anteroposterior position of maxillary incisors on esthetic profile in three different facial patterns. *J Orthod Sci* 2017;6:1-10.
27. Hernández-Sayago E, Espinar-Escalona E, Barrera-Mora JM, Ruiz-Navarro MB, Llamas-Carreras JM, Solano-Reina E. Lower incisor position in different malocclusions and facial patterns. *Med Oral Patol Oral Cir Bucal* 2013;18:e343-50.
28. Soh J, Chew MT, Wong HB. A comparative assessment of the perception of Chinese facial profile esthetics. *Am J Orthod Dentofacial Orthop* 2005;127:692-9.
29. Alkadhi RM, Finkelman MD, Trotman CA, Kanavakis G. The role of lip thickness in upper lip response to sagittal change of incisor position. *Orthod Craniofac Res* 2019;22:53-7.
30. Schlosser JB, Preston CB, Lampasso J. The effects of computer-aided anteroposterior maxillary incisor movement on ratings of facial attractiveness. *Am J Orthod Dentofacial Orthop* 2005;127:17-24.