



***Leishmania mexicana* in a central Texas cat: clinical presentation, molecular identification, sandfly vector collection and novel management**

Journal of Feline Medicine and Surgery Open Reports
1–6

© The Author(s) 2021

Article reuse guidelines:

sagepub.com/journals-permissions

DOI: 10.1177/2055116921999595

journals.sagepub.com/home/jfmsopenreports

This paper was handled and processed by the American Editorial Office (AAFP) for publication in *JFMS Open Reports*



Kaitlin Hopke¹, Alyssa Meyers², Lisa Auckland², Sarah Hamer², David Florin³, Alison Diesel¹ and Adam Patterson¹

Abstract

Case summary This case report documents the clinical appearance, diagnosis and novel treatment of a central Texas cat with cutaneous leishmaniosis. The cat presented with a linear erosion on the right pinnal margin, an ulcerated exophytic nodule on the right hock and a swelling in the right nostril. Cytological and histopathological findings were consistent with leishmaniosis. PCR confirmed the presence of *Leishmania mexicana*, a species endemic to Texas. An epidemiological investigation was conducted by trapping sandflies from the cat's environment. Sandflies collected were identified as *Lutzomyia* species, known vectors of *Leishmania* species. Given the lack of validated medical therapies for *L. mexicana* in cats, treatments typically prescribed for canine leishmaniosis were administered. Allopurinol achieved clinical success but was discontinued due to suspected drug-related neutropenia. Topical imiquimod also improved lesional skin but was not sustainable due to application difficulty. Oral administration of artemisinin resulted in significant clinical improvement of cutaneous lesions without reported adverse events. Nearly 8 months after the initiation of artemisinin therapy, the cat remained systemically healthy with stable lesions.

Relevance and novel information This case report demonstrates endemic feline leishmaniosis in central Texas and provides the clinician with alternative therapeutic options for medical management.

Keywords: Leishmaniosis; cutaneous leishmaniosis; *Leishmania mexicana*; *Lutzomyia*; sand flies; artemisinin; imiquimod

Accepted: 14 December 2020

Introduction

Leishmaniosis is caused by intracellular protozoal parasites that rely on insect vectors for transmission into their vertebrate hosts.^{1,2} Infection caused by species of the *Leishmania donovani* complex (especially *L. infantum*) has a wide geographical distribution and is characterized by both visceral and cutaneous manifestations.¹ *Leishmania mexicana*, the species endemic to Texas (USA), has been reported to cause primarily cutaneous lesions in cats.² Clinical signs include nodules, scale and erosions/ulcers typically located on the pinnae and muzzle.^{1,2} Diagnosis

¹Department of Small Animal Clinical Sciences, College of Veterinary Medicine, Texas A&M University, College Station, TX, USA

²Department of Veterinary Integrative Biosciences, College of Veterinary Medicine, Texas A&M University, College Station, TX, USA

³Independent Medical Entomologist, New York, USA

Corresponding author:

Kaitlin Hopke DVM, Department of Small Animal Clinical Sciences, College of Veterinary Medicine, Texas A&M University, 4474 TAMU, College Station, TX 77843-4472, USA
Email: khopke@cvm.tamu.edu



Creative Commons Non Commercial CC BY-NC: This article is distributed under the terms of the Creative Commons

Attribution-NonCommercial 4.0 License (<https://creativecommons.org/licenses/by-nc/4.0/>) which permits non-commercial use, reproduction and distribution of the work without further permission provided the original work is attributed as specified on the SAGE and Open Access pages (<https://us.sagepub.com/en-us/nam/open-access-at-sage>).

of feline leishmaniosis can be accomplished through cytology, histopathology or PCR. Feline-specific serological testing is not commercially available.^{1–3} Although immunofluorescence antibody testing has been useful for cases of *L infantum* infection, it has not been validated for the detection of specific *L mexicana* antibodies.^{4,5} The lack of validated treatments for cats with leishmaniosis has forced clinicians to extrapolate therapies used for canine leishmaniosis, particularly allopurinol and meglumine antimoniate.^{1,6} An additional challenge is the inability to procure commonly reported anti-leishmanial medications such as meglumine antimoniate and miltefosine in the USA. Therefore, treatment options are limited to extra-label use of allopurinol, surgical excision of lesions or alternative/novel therapies.

This case describes the clinical presentation and diagnosis of a central Texas cat infected with *L mexicana* and the successful use of novel treatments such as imiquimod cream and herbal artemisinin for feline leishmaniosis. In addition, it confirms local vector presence through identification of *Lutzomyia* sandflies at the cat's residence.

Case description

A 6-year-old neutered male domestic shorthair cat was presented to the primary veterinarian for evaluation of pruritic, non-healing wounds on the right pinna and the right tarsus. The lesions were noticed several weeks prior to examination. The cat was initially found as a stray in Bryan, Texas, at approximately 3 months of age. Since being obtained by the owner, the cat had remained primarily indoors with only infrequent exposure to the outdoor patio (approximately once a year). There was no known travel history outside of Texas prior to presentation. Clinical signs appeared to respond partially to prescribed therapies such as cephalexin, amoxicillin–potassium clavulanate, prednisolone and topical nitrofurazone. However, the lesions never entirely resolved, prompting the primary veterinarian to biopsy the pinnal lesion. Histopathology was consistent with focally extensive granulomatous dermatitis with intralesional amastigotes. A diagnosis of leishmaniosis was made and a course of marbofloxacin was administered for 40 days prior to referral.

At presentation to the dermatology service, the right pinna had an irregular lateral margin with an erythematous, crusted edge. Dermal thickening of the tissue with overlying ulceration was noted at the proximolateral aspect of the pinna. The caudal right tarsus had an ulcerated exophytic nodule with a thin overlying crust (Figure 1).

Impression cytology of the lesions revealed intracellular amastigotes with rounded nuclei and perpendicularly oriented kinetoplasts, consistent with *Leishmania* species organisms (Figure 2). The cat tested negative for feline leukemia virus (FeLV) antigen and feline immunodeficiency virus (FIV) antibodies using a SNAP FIV/FeLV

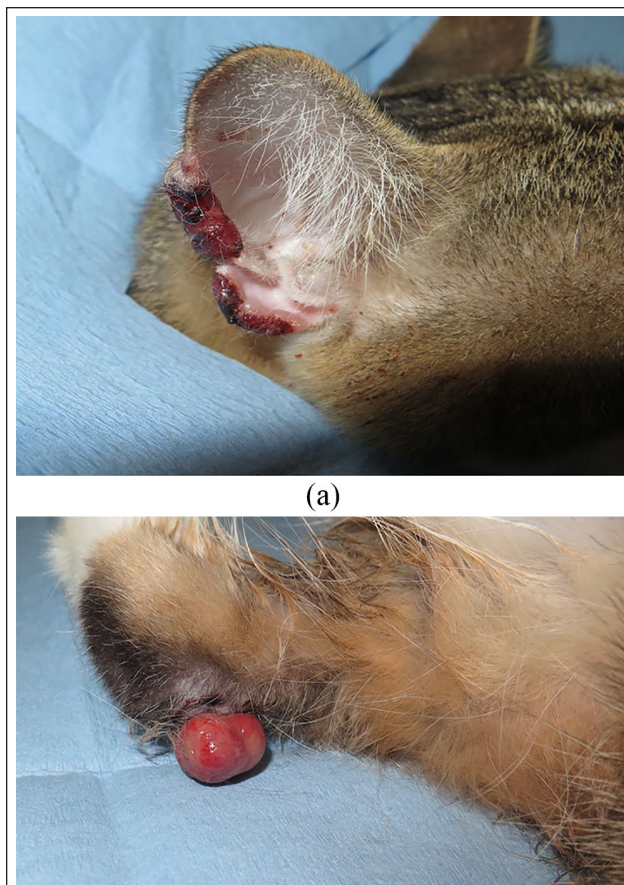


Figure 1 (a) Irregular margin of the right pinna with an erythematous, crusted edge at presentation. (b) Ulcerated, exophytic nodule on the caudal right tarsus at presentation

Combo Test (IDEXX). A moderate leukopenia (3500/ μ l; reference interval [RI] 5500–19,500) and mild thrombocytopenia (232,000/ μ l; RI 300,000–800,00) were noted on complete blood count (CBC) with mild hyperglobulinemia (3.9 g/dl; RI 2.3–3.8) and marginally elevated creatinine (1.83 mg/dl; RI 0.8–1.8) on serum chemistry. A recently voided bladder precluded urinalysis. The owner was instructed to have this performed with the primary veterinarian as soon as possible. A precautionary in-house consultation with the Ophthalmology Service confirmed no ocular abnormalities.

DNA was extracted from fresh frozen tissue of the tarsal lesion using the EZNA. Tissue Extraction Kit (Omega Bio-Tek). Primers R221 and R332 were used to amplify a 604 base pair (bp) segment of the small subunit ribosomal RNA gene of *Leishmania* species using previously described protocols.^{3,7} Amplicons were sequenced in forward and reverse, and compared to sequences in the National Center for Biotechnology Information Genbank database using the basic local alignment search tool (BLAST), resulting in $\geq 99\%$ sequence homology with *L mexicana* in both directions.

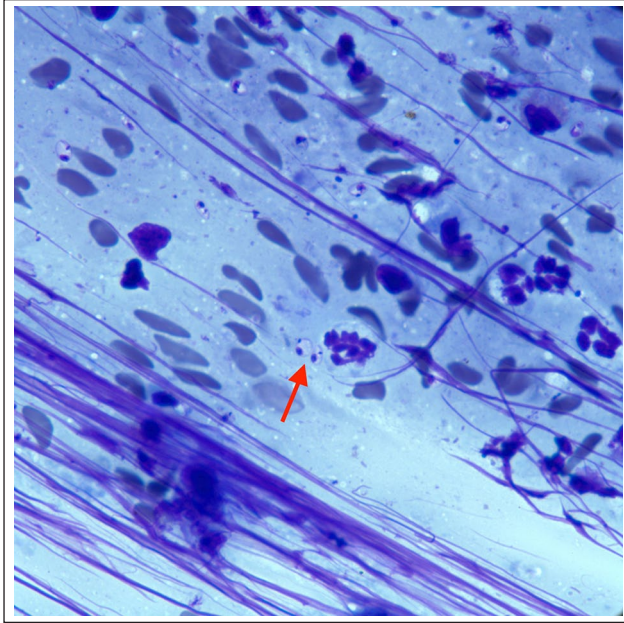


Figure 2 Impression cytology of the right pinnal and tarsal lesions, revealing amastigotes with rounded nuclei present in macrophages consistent with *Leishmania* species (arrow)

Initial treatment recommendations included application of 5% imiquimod cream applied as a thin layer to lesions three times weekly. Marbofloxacin was continued (3.5 mg/kg q24h) owing to its presumptive anti-leishmanial activity. It has demonstrated clinical efficacy in dogs by enhancing macrophage killing of amastigotes through the nitric oxide synthase pathway.^{8–11} Surgical excision of the pinnal lesion via pinnectomy and surgical de-bulking of the tarsal lesion were discussed but declined by the owner. In an attempt to repel potential *Leishmania* vectors (sandflies), a collar comprised of 4.5% flumethrin/10% imidacloprid (Seresto; Bayer) was recommended.

A few weeks after the cat's initial visit, four Centers for Disease Control and Prevention miniature light traps (BioQuip Products) baited with dry ice were set on the owner's residential property to survey for sandflies. The residence was surrounded by brushy habitat and debris, with chickens, dogs and cats present outside. Light traps were set in the brush and by the chicken coop in the evening for three consecutive nights with insects collected each morning. Three female sandflies were collected and stored individually in vials containing 100% ethanol (Figure 3). One sandfly was morphologically identified as *Lu shannoni* and the other two were not identified owing to poor body condition. DNA was extracted from each individual sandfly for confirmation of species identification based on sequencing of two different genetic regions: a 416bp fragment of the *CO1* gene and an approximate 450bp fragment of the *ITS2* region using



Figure 3 *Lutzomyia shannoni* sandflies collected in Bryan, Texas, from the residence of a cat infected with *Leishmania mexicana*. Courtesy of Gabriel Hamer/TAMU Entomology and Alyssa Meyers

previously described protocols.¹² Following amplification, sequencing and the BLAST protocol, two sandflies had >97–100% nucleotide sequence identity to *Lu shannoni* for both genetic regions, and the third sandfly had 100% identity to *Lu anthophora* at the *CO1* region and 79% sequence identity to (*Lutzomyia*) *Nyssomyia umbratilis* at the *ITS2* region. The *Leishmania* species PCR described above was used to test sandflies for infection, and all were negative.

Unfortunately, the cat did not return for recommended recheck appointments and the owners did not reply to requests for updates. Ten months after the cat's last appointment, it presented to the emergency service for a nasal swelling in its right nostril resulting in intermittent epistaxis with sneezing. The pinnal and tarsal lesions had not improved despite continued marbofloxacin administration. Imiquimod application had not been performed and a flumethrin/imidacloprid collar had not been applied. Baseline blood work and clotting times (prothrombin time/partial thromboplastin time) were normal. The owner was instructed to follow-up with the dermatology service to determine if the nasal mass was related to *L mexicana* prior to pursuing additional diagnostics such as CT or rhinoscopy.

The cat returned to the dermatology service approximately 8 weeks later for re-evaluation. The right pinnal margin was irregular with ulceration and adhered black crusts. The right tarsal nodule remained unchanged. A fleshy pink, slightly eroded mucosal mass, partially occluding the right nostril, was observed (Figure 4) with no purulent exudate. Impression cytology of all three lesions revealed amastigotes within macrophages. DNA was extracted from the cytology slide and run on the *Leishmania* species PCR described above, again yielding

sequences with $\geq 99\%$ homology to *L mexicana*. A FeLV/FIV test was negative (SNAP FIV/FeLV Combo Test; IDEXX) and CBC/chemistry was unremarkable. A precautionary *Cryptococcus* antigen latex test was performed owing to the new nasal lesion but was negative. Nasal mass biopsy under general anesthesia was recommended, to determine if there was a *Leishmania*-infected mass, but was declined by the owner. Allopurinol was initiated at 15 mg/kg PO q24h and a flumethrin/imidacloprid collar was once again recommended (but not actually applied by the owner until months later).

Within 6 weeks of allopurinol administration, the lesions of all three locations improved in size and degree of ulceration and epistaxis ceased to exist. However, blood work performed 8 weeks into allopurinol treatment revealed marked neutropenia (740/ μ l from 3408/ μ l at initiation of treatment; RI: 2500–12,500), despite the cat systemically doing well, as per the owner's report. Allopurinol was immediately discontinued and a course of pradofloxacin was prescribed owing to the high risk

of infection (8 mg/kg/day PO for 7 days).^{13,14} The neutrophil count rebounded from 740/ μ l to 3328/ μ l within 1 week of allopurinol discontinuation; however, cutaneous and nasal lesions also deteriorated.

The need for an alternative treatment that would effectively and safely manage cutaneous leishmaniasis led to a trial of artemisinin. The cat received capsules containing extracts of the plant *Artemisia annua* (~8 mg/kg q24h) in the following repeated cycles: 50 mg capsule by mouth every 12h for 11 days, followed by discontinuation for 3 days, then commencing again for another 11 day cycle (ArteMin; Holly Pharmaceuticals).¹⁵ After three cycles, there was marked clinical improvement of the nasal and pinnal lesions, while the tarsal mass remained static. The artemisinin was continued and topical imiquimod at the previously advised dosing was prescribed for the pinnal and tarsal lesions.

Eight months later, the cat remained solely on artemisinin with both clinical and cytological improvement (Figure 5). Imiquimod cream appeared initially to improve the appearance of the lesions but was discontinued shortly after first use owing to difficulty with application. There was marked reduction in the size of the nostril mass, to the point that it was barely detectable. The right pinna only had a minimally irregular margin with a normal surface. The right caudal tarsus had a pedunculated, exophytic lobulated mass that was smaller and less ulcerated. No amastigotes could be found cytologically from any affected, albeit improved, site. Although the size of the tarsal mass made it more amenable to potential surgical excision or cryotherapy, the owner declined any changes to the treatment protocol due to satisfaction with artemisinin.

Discussion

This case describes cutaneous and nasal mucosa leishmaniasis, owing to *L mexicana*, in a cat, and its successful response to novel therapy. Because there are no validated



Figure 4 Mucosal mass partially occluding the right nostril

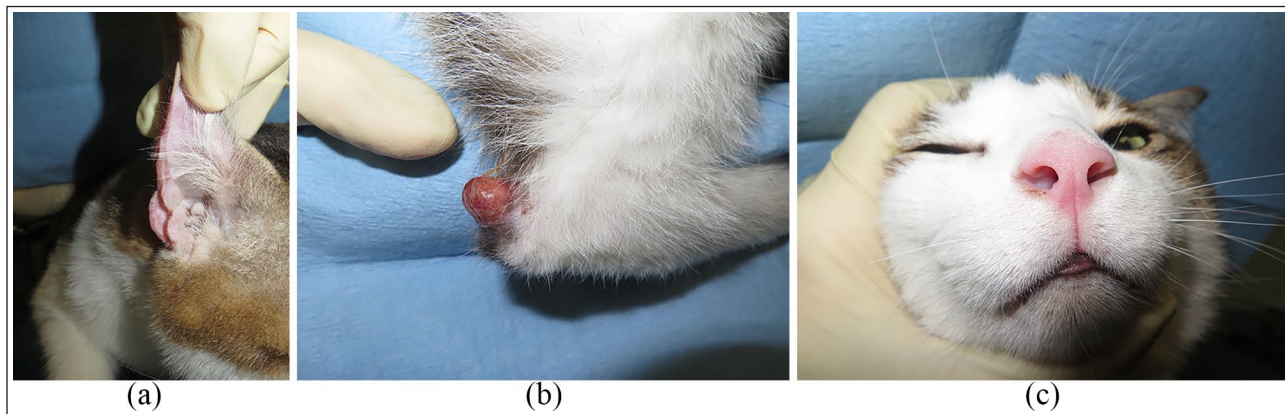


Figure 5 (a) Right pinnal margin was only minimally irregular with a normal surface. (b) The right tarsal mass was smaller and less ulcerated. (c) There was marked reduction in the size of the nostril mass, to the point that it was barely detectable

studies on treatments for feline leishmaniosis, protocols established for canine leishmaniosis are typically implemented. Allopurinol is the most commonly prescribed medication owing to its anecdotal efficacy.^{16,17} This xanthine oxidase inhibitor interrupts protozoal protein synthesis by affecting the ability to make purines.¹³ Clinical improvement of cutaneous lesions was noted with allopurinol, but a suspected drug-induced neutropenia occurred and necessitated discontinuation. Allopurinol-induced agranulocytosis has been reported in people, with neutrophil counts improving rapidly following drug discontinuation.¹³ This rebound effect was also noted in this case once allopurinol was withdrawn. If the neutropenia had failed to resolve so quickly, additional diagnostics for detection of other infectious diseases or primary bone marrow disease would be warranted.

The allopurinol adverse reaction, along with the inability to obtain meglumine antimoniate or miltefosine in the USA, prompted exploration of alternative therapies. Meglumine has been commonly prescribed to *Leishmania*-infected dogs and cats in Europe owing to its ability to reduce parasite load and enhance the immune response.¹⁸ Miltefosine has also been used outside the USA for its ability to affect parasite metabolism.¹⁶ One alternative therapy prescribed was topical imiquimod. Imiquimod is an immune-response modifier, approved for actinic keratoses, basal cell carcinoma and genital warts in people, that has effectively treated people with cutaneous leishmaniosis.^{19,20} This drug induces the release of proinflammatory cytokines and stimulates macrophages, thereby triggering protozoal killing. Clinical improvement of the cat's lesions was appreciated with this treatment, but it was ultimately discontinued owing to the owner's difficulty with application.

Another alternative treatment prescribed in this case was artemisinin. This derivative of the *Artemisia* plant species (*A annua*) has traditionally been used in Asia to treat people with visceral leishmaniosis and malaria.^{21,22} In addition to having direct parasitocidal activity, artemisinin also increases nitric oxide production within macrophages and improves host protection by favoring a T-helper cell 1 response.²² Although there is a paucity of studies involving artemisinin use in animals, in vitro, as well as in vivo, murine models have demonstrated artemisinin's cytotoxic effect on amastigotes.²³ Artemisinin was well tolerated by the cat and significantly improved its lesions, both clinically and cytologically. This therapy should be considered a viable option for cats affected with leishmaniosis, especially if 'traditional' treatments have failed or are not tolerated.

To our knowledge, this is also the first case in which sandfly vectors were identified in the infected cat's environment. Vector trapping at the cat's property revealed two species of sandflies *Lu shannoni* and *Lu anthophora*. *Lu anthophora* is a known competent vector

of *L mexicana* in the USA, and experimental transmission of *L mexicana* has been demonstrated in *Lu shannoni*.^{24,25} *L mexicana* was not identified in the samples collected, but the sample size was small. Furthermore, *Leishmania* species are highly focal over space and time, and sample collection took place months after the cat's initial clinical signs.

The confirmed presence of vectors in the immediate environment indicated the need for infection prevention; therefore, a flumethrin/imidacloprid collar was recommended. This product has proven to reduce significantly the risk of *Leishmania* infection in cats in endemic areas.²⁶ To further prevent vectors, it is also beneficial to clear brushy habitat and minimize outdoor light usage.

Nearly 8 months after the initiation of artemisinin, the cat's lesions remain well-controlled. The nasal and pinna lesions are barely detectable, while the tarsal mass remains markedly reduced in size. Surgical excision of this mass was discussed with the owner but was declined. The cyclic dosing of artemisinin and application of a flumethrin/imidacloprid collar have successfully managed this cat's cutaneous leishmaniosis.

Conclusions

This case demonstrates endemic leishmaniosis in central Texas. It reminds clinicians in this geographic region to consider leishmaniosis as a differential for cutaneous lesions in a cat, particularly when on the pinnae. It also provides alternative therapeutic options to manage this zoonotic disease.

Acknowledgements The authors would like to thank Karen F Snowden DVM, PhD, DACVM (Parasitology), for her contribution to the molecular identification of *L mexicana*. This case was displayed as a poster in the virtual World Congress of Veterinary Dermatology in October 2020.

Conflict of interest The authors declared no potential conflicts of interest with respect to the research, authorship, and/or publication of this article.

Funding The authors received no financial support for the research, authorship, and/or publication of this article.

Ethical approval This work involved the use of non-experimental animals only (including owned or unowned animals and data from prospective or retrospective studies). Established internationally recognized high standards ('best practice') of individual veterinary clinical patient care were followed. Ethical approval from a committee was therefore not necessarily required for publication in *JFMS Open Reports*.

Informed consent Informed consent (either verbal or written) was obtained from the owner or legal custodian of all animal(s) described in this work (either experimental or non-experimental animals) for the procedure(s) undertaken (either prospective or retrospective studies). For any animals

or humans individually identifiable within this publication, informed consent (either verbal or written) for their use in the publication was obtained from the people involved.

References

- Pennisi MG, Hartmann K, Lloret A, et al. **Leishmaniosis in cats. ABCD guidelines on prevention and management.** *J Feline Med Surg* 2013; 15: 638–642.
- Minard HM, Daniel AK, Pool RR, et al. **Pathology in practice.** *J Am Vet Med Assoc* 2017; 251: 57–59.
- Trainor KE, Porter BF, Logan KS, et al. **Eight cases of feline cutaneous leishmaniasis in Texas.** *Vet Pathol* 2010; 47: 1076–1081.
- Iatta R, Trerotoli P, Lucchese L, et al. **Validation of a new immunofluorescence antibody test for the detection of *Leishmania infantum* infection in cats.** *Parasitol Res* 2020; 119: 1381–1386.
- Chatzis MK, Leontides L, Athanasiou LV, et al. **Evaluation of indirect immunofluorescence antibody test and enzyme-linked immunosorbent assay for the diagnosis of infection by *Leishmania infantum* in clinical normal and sick cats.** *Exp Parasitol* 2014; 147: 54–59.
- LeishVet. **Therapies of feline leishmaniosis.** <http://www.leishvet.org/fact-sheet-feline-leishmaniosis/feline-leishmaniosis-treatment/> (accessed February 19, 2021).
- Lachaud L, Marchergui-Hammami S, Chabbert E, et al. **Comparison of six PCR methods using peripheral blood for detection of canine visceral leishmaniasis.** *J Clin Microbiol* 2002; 40: 210–215.
- Vouldoukis I, Rougier S, Dugas B, et al. **Canine visceral leishmaniasis: comparison of in vitro leishmanicidal activity of marbofloxacin, meglumine antimoniate and sodium stibogluconate.** *Vet Parasitol* 2006; 135: 137–146.
- Rougier S, Housseine L, Delaunay P, et al. **One-year clinical and parasitological follow-up of dogs treated with marbofloxacin for canine leishmaniosis.** *Vet Parasitol* 2012; 186: 245–253.
- Oliva G, Roura X, Crotti A, et al. **Guidelines for treatment of leishmaniasis in dogs.** *J Am Vet Med Assoc* 2010; 236: 1192–1198.
- Rougier S, Vouldoukis I, Fournel S, et al. **Efficacy of different treatment regimens of marbofloxacin in canine visceral leishmaniasis: a pilot study.** *Vet Parasitol* 2008; 153: 244–254.
- Florin DA, Davies SJ, Olsen C, et al. **Morphometric and molecular analyses of the sand fly species *Lutzomyia shannoni* (Diptera: Psychodidae: Phlebotominae) collected from seven different geographical areas in the southeastern United States.** *J Med Entomol* 2011; 48: 154–166.
- Mari E, Ricci F, Imberti D, et al. **Agranulocytosis: an adverse effect of allopurinol treatment.** *Ital J Med* 2011; 5: 120–123.
- Couto GC. **Leukocytes: do normal numbers means normal patients?** <https://vvma.org/resources/Documents/Leukocytes2017.pdf> (accessed February 19, 2021).
- A Path with Paws. **Artemisinin – when cancer cells kill themselves.** <https://pathwithpaws.com/blog/2011/03/26/artemisinin-when-cancer-cells-kill-themselves> (2011, accessed February 19, 2021).
- Leal RO, Pereira H, Cartaxeiro C, et al. **Granulomatous rhinitis secondary to feline leishmaniosis: report of an unusual presentation and therapeutic complications.** *JFMS Open Rep* 2018; 4. DOI: 10.1177/2055116918811374.
- Brianti E, Celi N, Napoli E, et al. **Treatment and long-term follow-up of a cat with leishmaniosis.** *Parasit Vectors* 2019; 12: 121. DOI: 10.1186/s13071-019-3388-9.
- Miller WH, Griffin CE and Campbell KL. *Muller Kirk's small animal dermatology.* 7th ed. St Louis, MO: Elsevier Press, 2013.
- Buates S and Matlashewski G. **Treatment of experimental leishmaniasis with the immunomodulators imiquimod and s-28463: efficacy and mode of action.** *J Infec Dis* 1999; 179: 1485–1494.
- Seeberger J, Daoud S and Pammer J. **Transient effect of topical treatment of cutaneous leishmaniasis with imiquimod.** *Int J Dermatol* 2003; 42: 576–579.
- Islamuddin M, Farooque A, Dwarakanath BS, et al. **Extracts of *Artemisia annua* leaves and seeds mediate programmed cell death in *Leishmania donovani*.** *J Med Microbiol* 2012; 61: 1709–1718.
- Sen R, Ganguly S, Saha P, et al. **Efficacy of artemisinin in experimental visceral leishmaniasis.** *Int J Antimicrob Agents* 2010; 36: 43–49.
- Ghaffarifar F, Heydarai FE, Dalimi A, et al. **Evaluation of apoptotic and antileishmanial activities of artemisinin on promastigotes and BALB/C mice infected with *Leishmania major*.** *Iran J Parasitol* 2015; 10: 259–267.
- McHugh CP, Grogl M and Kreutzer RD. **Isolation of *Leishmania mexicana* (Kinetoplastida: trypanosomatidae) from *Lutzomyia anthophora* (Diptera: Psychodidae) collected in Texas.** *J Med Entomol* 1993; 30: 631–633.
- Lawyer PG and Young DG. **Experimental transmission of *Leishmania mexicana* to hamsters by bites of phlebotomine sand flies (Diptera: Psychodidae) from the United States.** *J Med Entomol* 1987; 24: 458–462.
- Brianti E, Falsone L, Napoli E, et al. **Prevention of feline leishmaniosis with an imidacloprid 10%/flumethrin 4.5% polymer matrix collar.** *Parasit Vectors* 2017; 10: 334. DOI: 10.1186/s13071-017-2258-6.