



Case report

The impact of intravenous dobutamine on spirometry with bronchodilator test

Jan Romantowski^{a,*}, Piotr Janowiak^b, Elzbieta Wabich^c, Krzysztof Kuziemski^b

^a Department of Allergology, Medical University of Gdansk, Poland

^b Department of Pulmonology, Medical University of Gdansk, Poland

^c Department of Cardiology and Electrotherapy, Medical University of Gdansk, Poland



ARTICLE INFO

Keywords:

COPD

Pulmonary function tests

Heart failure

Vasopressor

Bronchodilator

1. Background

Spirometry bronchodilator test is widely used for diagnosis of asthma and Chronic Obstructive Pulmonary Disease (COPD) [1]. The patient is required to perform the spirometry and in case of airway obstruction, inhaled bronchodilator is administered. After 20 minutes spirometry is repeated. In case of significant improvement of Force Expiratory Volume in 1 second (FEV1) asthma might be confirmed. Additionally, if airway obstruction persists, COPD might be diagnosed.

Performing proper bronchodilator test might prove difficult in some cases. It requires both technically sound spirometry performance and proper bronchodilator wash-out [1]. Though not mentioned directly in spirometry describing literature, exacerbated heart failure is considered a relative contraindication to this test. These patients are usually in not acceptable general condition for pulmonary function tests. Also, administration of vasopressors might affect the test results due to their possible bronchodilating effect. Due to these limitations the relation of intravenous dobutamine and bronchodilator test so far remains unknown.

We present a unique case description of dobutamine impact on spirometry results that may improve practicing physicians approach to pulmonary function tests in patients with heart failure decompensation.

2. Case report

A 76-year old female patient (Caucasian, 1.59m height, weight 40kg)

was diagnosed in Department of Cardiology and Electrotherapy for follow-up diagnostics. Three months before that heart catheterization was performed revealing precapillary pulmonary hypertension (mPAP 30 mmHg, PVR 8.3 Wood Unit, Cardiac Output 2.86l/min). Though no embolic material was found in lower limb vein ultrasonography, the interview with incident of pulmonary embolism (intermediate risk) strongly suggested thromboembolic pulmonary hypertension. The decision was made to repeat heart catheterization after 3 months of proper therapy including anticoagulants with consideration of percutaneous coronary artery intervention. At that point, the patient received standard doses of rivaroxaban, torasemide and potassium supplementation.

Three months later patient was hospitalized for follow up diagnostics. With her status significantly worse (arterial pressure 90/60 mmHg, and lower exercise tolerance) heart catheterization was performed revealing worse parameters (mPAP 40 mmHg, PVR 11.66 Wood Unit, Cardiac Output 2.57l/min). Apart from that, serum BNP level was significantly elevated 1639 pg/ml. The initial high sensitive troponin I was insignificant (0.018 ng/ml). Three days after the procedure hypotension (80/60 mmHg) and increased peripheral edema were observed indicating heart failure decompensation. At that stage patient complained about breathlessness at any exertion. In laboratory tests Troponin I and CK-MB increased (0.13ng/ml, 8.2 ng/ml respectively) as well as BNP (up to 2461 pg/ml). In chest X-Ray no significant changes were observed apart from increased heart size as expected in chronic heart failure (no hydrothorax nor sings of pulmonary edema). The exacerbation prompted treatment with continuous administration of

* Corresponding author. Department of Allergology ul, Smoluchowskiego 17, 80-214, Gdańsk, Poland.

E-mail address: jromant@gumed.edu.pl (J. Romantowski).

<https://doi.org/10.1016/j.rmcr.2020.101264>

Received 15 July 2020; Accepted 10 October 2020

Available online 15 October 2020

2213-0071/© 2020 The Author(s).

Published by Elsevier Ltd.

This is an open access article under the CC BY-NC-ND license

(<http://creativecommons.org/licenses/by-nc-nd/4.0/>).

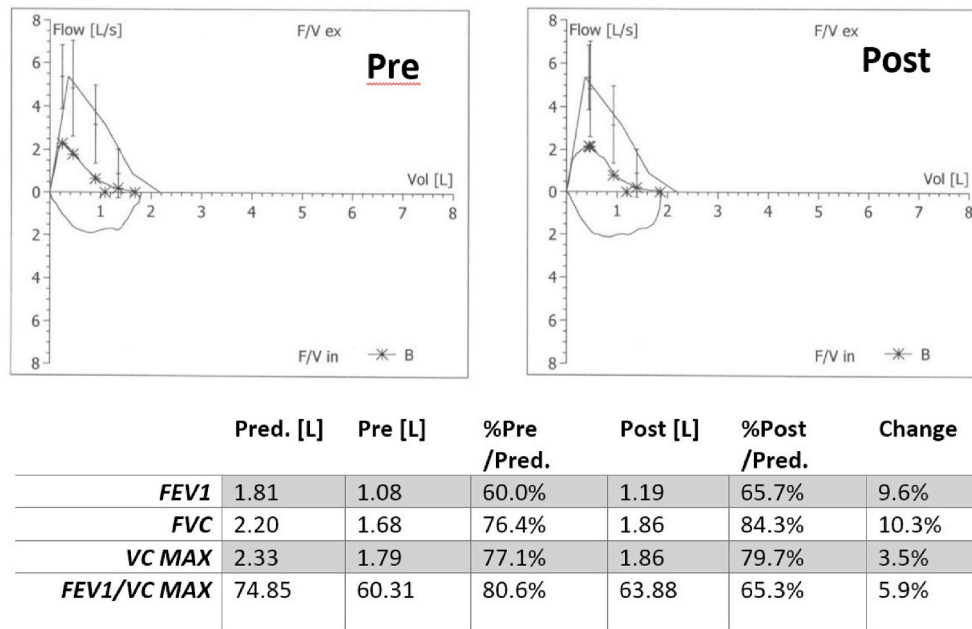


Fig. 1. Spirometry bronchodilator test during dobutamine administration. Pred., predicted values; Pre, initial assessment; Post, assessment after salbutamol administration; FEV1, Forced Expiratory Volume in 1 Second; VC, Vital Capacity; FVC, Forced Vital Capacity.

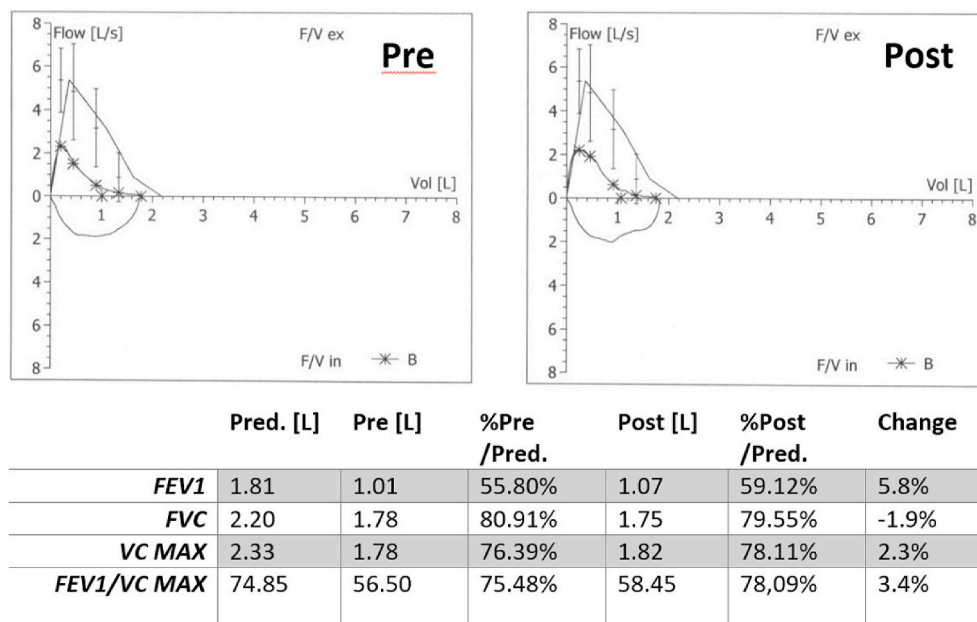


Fig. 2. Spirometry bronchodilator test with adequate bronchodilators wash-out. Pred., predicted values; Pre, initial assessment; Post, assessment after salbutamol administration; FEV1, Forced Expiratory Volume in 1 Second; VC, Vital Capacity; FVC, Forced Vital Capacity.

intravenous dobutamine (15mg/h) and torasemide (1mg/h) for 2 weeks with simultaneous fluid restriction to 1.5l/day and low-flow oxygen supplementation (1–2l/min under oxygen saturation control). After initial stabilization high resolution computed chest (HR CT) tomography revealed milky glass areas around pulmonary vessels which was suspected to be manifestation of pulmonary hypertension. Also, a few focal lesions were observed (up to 25mm of diameter in right lung) that might be signs of pulmonary embolism in the past.

After significant peripheral edema recession and patients clinical status improvement the decision was made to perform spirometry. Because of 40 pack year history of smoking COPD was suspected. Despite the need for continuous dobutamine administration (15mg/h)

patient’s condition was surprisingly good and allowed for participation in pulmonary function test. Spirometry revealed moderate airflow obstruction (Fig. 1). The bronchodilator reversibility test [1] was negative with persisting obturation 20 minutes after inhaled salbutamol administration which confirmed COPD diagnosis. No bronchodilator positive response [1] was observed. The heart status was stabilized and BNP levels dropped to 386 pg/ml. Dobutamine administration was withdrawn and patient was prescribed tiotropium inhalation for home therapy. One month after first assessment, pulmonary function tests were repeated at out-patient department. Spirometry with bronchodilator test was performed after adequate wash-out of bronchodilators still revealing persisting obturation. Though results were notably worse, the

change was non-significant [1] (Fig. 2). All in all, the impact of dobutamine on FEV1 was increase by 70ml (7% of corresponding value without dobutamine) on first assessment and by 120ml (11%) post salbutamol administration.

Additionally thrombophilia was diagnosed – namely antiphospholipid syndrome (with positive lupus anticoagulant) along with factor V heterozygotic mutation. Final diagnosis included COPD, pulmonary hypertension and heart failure decompensation.

3. Discussion

Although dobutamine is considered selective beta 1 agonist, still it may bind beta2 receptors. Williams et al. performed a thorough study on rats and proved that dobutamine binds 5 times more likely in heart tissue than in lung. Though small, the effect on beta 2 receptors was still measurable [2]. In animal models it was observed that (+)-isomer of dobutamine has significantly higher affinity to beta 2 lung receptors and may partially mask vasoconstricting dobutamine effect mediated by alfa receptors. Namely, smooth muscle relaxation mediated by beta 2 receptors might be observed both in pulmonary vessels and bronchi [3,4].

Its association with spirometry results was not described to date, mostly due to the fact that dobutamine is administered in patients who not able to perform technically sound pulmonary function tests [5]. Dobutamine being a vasopressor is indicated in impairment of cardiac muscle contractility in the course of cardiogenic or septic shock [6]. Such patients are usually unable to sit and their weakness makes it impossible to even consider spirometry.

Though no data of dobutamine impact on spirometry is available, comparison with usually used bronchodilators is worth mentioning. Beta agonists have significant impact on asthmatic patients. Bjermer et al. administrated 2.5mg of salbutamol to asthmatic patients, which resulted in increase of mean FEV1 by 712ml (18%) [7]. However, such effects are not observed in COPD patients. Calverley et al. performed bronchodilator test on 990 patients aged 40–75, suffering from COPD with no coexisting asthma [8]. The mean change of FEV1 post salbutamol was 128ml (around 10%). As expected being selective beta2 agonist, salbutamol increases FEV1 more than dobutamine. In our point of view, different routes of administration (intravenous vs. inhaled)

should not have significant impact on spirometry outcome. Salbutamol shows similar effect in both routes of administration [9]. However, to our surprise we found out that the difference is actually not that high in COPD patients. It must be noted though that comparing a single case result to mean values of vast group of patient is uncertain.

4. Conclusions

As shown in this case impact of dobutamine at therapeutic doses on spirometry was minor and did not significantly affect its results. This fact should be considered by physicians in interpreting the results especially in borderline values.

Declaration of competing interest

The study did not require funding.
The authors declare no conflict of interests.

References

- [1] R. Pellegrino, G. Viegi, V. Brusasco, R.O. Crapo, F. Burgos, R. Casaburi, et al., Interpretative strategies for lung function tests, *Eur. Respir. J.* 26 (2005) 948–968.
- [2] R.S. Williams, T. Bishop, Selectivity of dobutamine for adrenergic receptor subtypes: in vitro analysis by radioligand binding, *J. Clin. Invest.* 67 (1981) 1703–1711.
- [3] R.R.J. Ruffolo, T.A. Spradlin, G.D. Pollock, J.E. Waddell, P.J. Murphy, Alpha and beta adrenergic effects of the stereoisomers of dobutamine, *J. Pharmacol. Exp. Therapeut.* 219 (1981) 447–452.
- [4] R.J. Shebuski, T. Fujita, R.R.J. Ruffolo, Interaction of dopamine, (+/-)-dobutamine and the (-)-enantiomer of dobutamine with alpha- and beta-adrenoceptors in the pulmonary circulation of the dog, *Pharmacology* 34 (1987) 201–212.
- [5] J.C. Jentzer, J.C. Coons, C.B. Link, M. Schmidhofer, Pharmacotherapy update on the use of vasopressors and inotropes in the intensive care unit, *J. Cardiovasc. Pharmacol. Therapeut.* 20 (2015) 249–260.
- [6] J.A. Russell, Vasopressor therapy in critically ill patients with shock, *Intensive Care Med.* 45 (2019) 1503–1517.
- [7] L. Bjermer, K. Abbott-Banner, K. Newman, Efficacy and safety of a first-in-class inhaled PDE3/4 inhibitor (ensifentrine) vs salbutamol in asthma, *Pulm. Pharmacol. Therapeut.* 58 (2019) 101814.
- [8] P.M.A. Calverley, P.S. Burge, S. Spencer, J.A. Anderson, P.W. Jones, Bronchodilator reversibility testing in chronic obstructive pulmonary disease, *Thorax* 58 (2003) 659. LP – 664.
- [9] S.G. Nogrady, W.V. Evans, B.H. Davies, Reversibility of airways obstruction in bronchiectasis, *Thorax* 33 (1978) 635–637.