

EFFECT OF REMOVAL OF CHOLESTEROL DIET UPON SERUM SICKNESS-CHOLESTEROL-INDUCED ATHEROSCLEROSIS

BY M. VAN WINKLE, PH.D., AND L. LEVY, PH.D.

(From the Biological Sciences Section of Riker Laboratories,
Northridge, California 91326)

(Received for publication 3 May 1968)

Vascular injuries have been shown to enhance or potentiate the pathogenesis of experimental atherosclerosis. Clinical evidence also indicates that atherosclerosis frequently develops in areas of the vasculature which have been subjected to injury as a result of various disease processes. Recently, immunologically induced vascular injury (resulting from active production of antibody to foreign protein) of the serum sickness type has been shown to potentiate atherogenesis in lipemic rabbits (1-4). In one of these studies (1), it was reported that microscopic lesions were detectable after a single antigenic challenge plus feeding of a cholesterol-supplemented diet for only 2 wk. This was a shorter and less severe induction regimen than used in the other studies (2-4) and the question arose concerning the fate of such early lesions if no further immunological or lipid insult were to be forthcoming. The following study was undertaken in an attempt to investigate this question by examining the incidence of atheromatous lesions in rabbits subjected to varying exposures of foreign protein and cholesterol-supplemented diet.¹

Materials and Methods

The various control and experimental treatments used here are presented in Table I. 111 male, New Zealand white rabbits (Adams Caviary, San Gabriel, Calif.) weighing from 1.5 to 2.0 kg were divided into 12 groups of 8-10 animals each and treated as follows: 75 animals (groups 1-8) received a single intravenous injection of bovine serum albumin (crystallized 2 X, Nutritional Biochemicals Corp., Cleveland, Ohio, 250 mg/kg body weight) in order to induce serum sickness according to a technique used by Germuth (6). 47 of these serum-sickness animals (groups 1-5) were immediately transferred from ad lib. Purina rabbit pellets to a 100 g/day diet consisting of the same pellets coated with sufficient cholesterol (Merck & Co., Rahway, N. J.) to effect a 1% (by weight) concentration. These were considered to be experimental animals, since they received combined treatment with cholesterol and foreign protein. Groups 1, 4, and 5 were maintained on the cholesterol diet for 2, 3, and 4 wk, respectively, and sacrificed. Animals of groups 2 and 3 received the special diet for 2 wk only, and were then transferred back to regular chow and sacrificed after 1 and 2 additional wk, respectively.

¹ Reported in part at the 1967 Meeting of the Federated Societies for Experimental Biology and Medicine (5).

Control animals were either untreated (group 9) or exposed to only one of the treatments used in combination above, i.e., injected with bovine serum albumin and fed regular diet for 2, 3, or 4 weeks (Groups 6-8) or exposed only to cholesterol diet for similar periods of time (groups 10-12).

At the close of each study period, animals were sacrificed with excess sodium thiopental. Hearts were removed, fixed with either 10% formalin or Bouin's fixative, and subsequently sectioned on a cryostat or after being imbedded in paraffin blocks. Each heart was cross-sectioned at 6-8 μ throughout that section of the ascending aorta which included the tricuspid

TABLE I
Experimental and Control Treatments Used in Study

Bovine serum albumin (BSA)*	Group	Cholesterol diet†	Regular diet	N‡
		<i>wk</i>	<i>wk</i>	
Yes	1	2	0	10
	2	2	1	8
	3	2	2	9
	4	3	0	10
	5	4	0	10
	6	0	2	9
	7	0	3	9
	8	0	4	10
Total.....				75
No	9	0	4	10
	10	2	0	9
	11	3	0	9
	12	4	0	8
Total.....				36

* I.v., 250 mg/kg body weight.

† 1% cholesterol by weight.

‡ Number of rabbits per group.

valves and coronary ostia. Tissues were stained with either hematoxylin and eosin, or Weigert-Van Gieson stains for routine lesion scanning. Pollak's trichrome, or Oil red "O" stains were used on selected tissue sections in order to demonstrate special effects. Tissues of both experimental and control animals were examined with the light microscope for evidence of lesions, and only intimal lesions which were present in at least three consecutive serial sections were counted.

Lesions fell into three descriptive categories: (a) fatty, (b) proliferative, and (c) fatty-proliferative. Fatty lesions were identified by the presence of intra- and extracellular lipid deposits. These deposits were detectable by direct lipid staining (i.e., Oil red "O" stain) or by the empty, foamy appearance of cells within the lesion after paraffin block sectioning and hematoxylin and eosin staining. In contrast, proliferative lesions were free of lipid inclusions. Cells of these lesions had stainable cytoplasm, and darkly stained nuclei (with frequent

mitotic figures) when stained by the hematoxylin and eosin technique. Fatty-proliferative lesions were combinations of the first two types.

Serum samples were obtained from each rabbit at the beginning and end of each study period, and at weekly intervals during the experiments for total cholesterol levels.

RESULTS

Consistent with earlier studies, all lesions detected were intimal in nature and occurred within the valvular areas of ascending aortas, and/or the coronary arteries. Fig. 9–14 depict lesions typical of those encountered in the study.

Fig. 9 shows a lesion found in a rabbit which was treated with BSA plus 2 wk of cholesterol diet, and was sacrificed after an additional 1 wk rest period (group 2). This lesion occluded approximately 50% of the lumen of a coronary artery. Fig. 10 is an oil immersion magnification of the same lesion. Both tissue sections were stained with an elastic tissue stain (i.e., Weigert–Van Gieson) which stains the elastic tissue black.

It may be seen in Fig. 10 that the internal elastic membrane has been separated or broken in several places (arrows), a common feature of lesions seen in this study. The lesions shown in Figs. 11 and 12 occurred in the valvular areas of the ascending aortas of two different rabbits which were rested for 2 wk after receiving the 2 wk BSA-cholesterol diet combined treatment (group 3). The section shown in Fig. 11 was prepared from paraffin blocks and stained with hematoxylin and eosin; it demonstrates the presence of numerous foam cells (arrows). The appearance of other cells with darkly staining nuclei and stainable cytoplasm show this lesion to be of the fatty-proliferative type. Fig. 12 is an oil immersion picture of a lesion stained with Oil red “O” lipid stain. The arrows point to areas within the lesion which have taken on the red, lipophilic stain. This section gives direct evidence of the presence of lipid in such lesions at the end of the 2 wk rest period.

An aortic lesion found in a rabbit sacrificed after treatment with BSA and 3 wk of cholesterol diet (group 4) is shown in Fig. 13. In this hematoxylin and eosin-stained section, a mitotic figure is clearly visible near the center of the lesion. Mitotic figures were frequently seen in lesions resulting from treatment with BSA (alone or in combination with cholesterol diet), indicating that these lesions were highly proliferative. In addition, foam cells may be noted near the base of the lesion shown in Fig. 13, identifying it as being of the fatty-proliferative type.

Fig. 14 shows an aortic lesion caused by treatment with cholesterol diet alone for 2 wk (group 10). This photograph, stained with a Pollak’s rapid trichrome stain, clearly shows swelling and reduplication of the internal elastic membrane, which stains pale green due to the hyaline elements contained there. Large foam cells were the predominant cellular elements seen in lesions of this type, and mitotic figures were rarely seen.

With respect to the incidence of lesions noted in the different experimental

and control groups, the following data were obtained. As shown in Fig. 1, serum-sickness control animals (groups 6-8) revealed 77% lesions (predominantly proliferative) 2 wk after BSA challenge (group 6), which decreased to 44% after 3 wk (group 7), and to 30% 4 wk after antigen (group 8). Foam cells were occasionally observed in lesions of these animals. The lesion incidence at 4 wk was significantly lower than at 2 wk ($P < 0.05$).

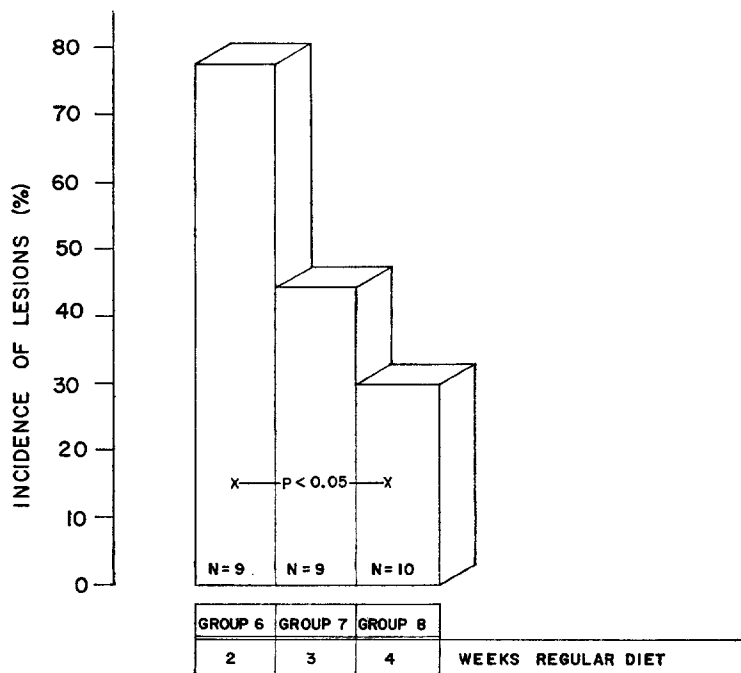


FIG. 1. Incidence of serum sickness lesions in the hearts of control rabbits of Groups 6, 7, and 8. Animals received a single intravenous injection of BSA (250 mg/kg body weight), and were fed untreated Purina Rabbit Chow for 2, 3, or 4 wk. N, number of rabbits in group.

Cholesterol-diet controls (animals of groups 10-12) showed predominantly fatty lesions in 33%, 11%, and 63% of animals maintained on the supplemented diet for 2, 3, and 4 wk, respectively (Fig. 2). However, at least one foam cell lesion contained a cell in mitosis. The increase in lesion incidence from wk 2 to wk 4 was not significant at the 5% level.

One of ten untreated controls (group 9) showed a single intimal proliferation in the wall of the ascending aorta. No foam cells were found in this lesion, and the rest of these animals were free of intimal disturbance.

Experimental animals, i.e. those receiving the combined treatment of BSA injection and cholesterol diet, exhibited a high percentage of predominantly

fatty-proliferative lesions as early as 2 wk after beginning treatment. As shown in Fig. 3, 6 of 10 animals (60%) of group 1 had lesions after a single BSA injection and 2 wk of cholesterol feeding. The incidence seemed to increase when the animals were subsequently transferred to regular chow for 1 wk (75% incidence, group 2) or 2 wk (88% incidence, group 3). Interestingly, a change in incidence was not detected when serum sickness animals were fed cholesterol diet for 3 wk (60%, group 4) or 4 wk (50%, group 5), as shown in Fig. 4. The lesion incidence in animals of group 3 (serum sickness, cholesterol

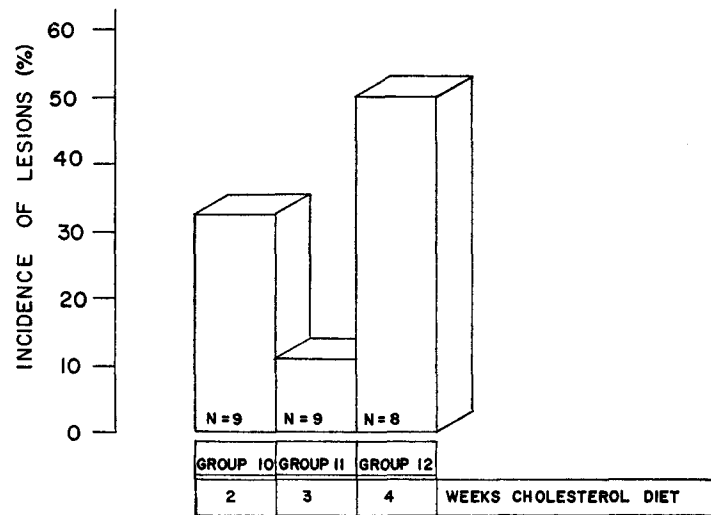


FIG. 2. Incidence of atheromatous lesions in the hearts of cholesterol control rabbits of Groups 10, 11, and 12. These rabbits received no BSA, but were maintained on 100 g/day of 1% (by weight) cholesterol-coated Purina Rabbit Chow for 2, 3, or 4 wk.

diet for 2 wk, and return to regular diet for 2 wk) was significantly higher ($P < 0.01$, chi-square test) than that of group 8 (the 4 wk serum sickness control animals).

The mean cholesterol levels of the animals studied here are presented in Fig. 5-8. As noted in Fig. 5, the 29 animals of groups 1, 2, and 3 developed mean total blood cholesterols which were 4-5 times as high as base line values after 2 wk of cholesterol diet. At 2 wk, 10 animals were sacrificed (group 1) and the remainder (17, 2 animals died) were transferred to regular food (groups 2 and 3). Cholesterol values had returned to base line levels when the last nine rabbits were sacrificed at the end of wk 4 (group 3). Cholesterol levels of serum sickness animals maintained on cholesterol diet until sacrificed at 3 or 4 wk (groups 4 and 5, respectively) showed the same 2 wk rise as mentioned above (Fig. 6). With continued lipid feeding, mean levels showed no significant change.

Weight and food consumption data indicated that some of the animals may have become "bait shy" of the cholesterol-coated food. It will be noted, however, that mean values were 3-4 times as high as base line levels during the entire study period.

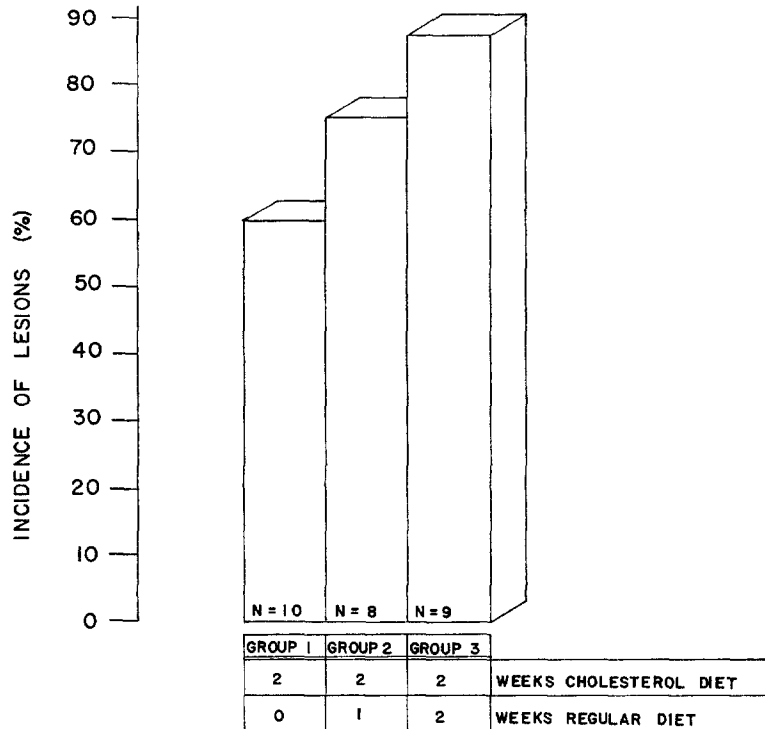


FIG. 3. Incidence of atheromatous lesions in the hearts of experimental Groups 1, 2, and 3, the animals of which received a BSA injection (250 mg/kg i.v.) and 2 wk feeding of 1% (by weight) cholesterol diet. Animals of group 1 were sacrificed at the end of the 2 wk induction period, and those of groups 2 and 3 were fed regular feed for an additional 1 and 2 wk, respectively, and sacrificed.

Cholesterol levels of animals injected with BSA, but maintained on regular chow (groups 6-8), remained within the base line range during the study (Fig. 7). Levels of lipid-diet controls (groups 10-12) remained 2-3 times as high as base line values (Fig. 8) after reaching a peak level by the end of wk 1. Weight and food consumption data again indicated that bait shyness may have been responsible for this apparent stability.

DISCUSSION

The identities of the factors which initiate atherosclerosis are in much debate (7-9). Vascular injury is one possible factor, and has been shown to increase the susceptibility of several animal species to the development of atherosclerosis. For example, the adult rabbit, which rarely develops atherosclerosis spontaneously (10-12), has an earlier susceptibility to atherosclerosis when diet-induced hyperlipemia is superimposed upon vessel injury than when either

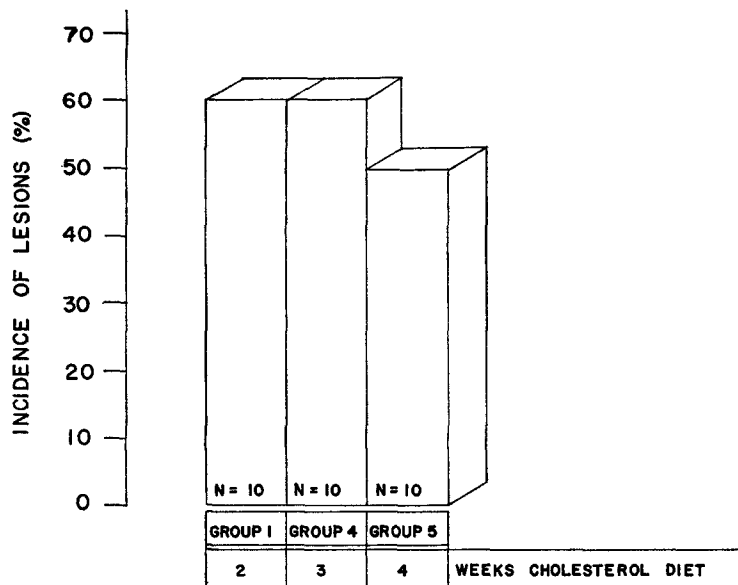


FIG. 4. Incidence of atheromatous lesions in the hearts of experimental rabbits maintained on 1% cholesterol diet (100 g/day) until time of sacrifice after an i.v. injection of BSA (250 mg/kg). As noted in Fig. 3, group 1 was sacrificed after 2 wk of treatment. Groups 4 and 5 were sacrificed at the end of 3 and 4 wk, respectively.

condition prevails by itself (8, 13, 14). For this reason, vascular injury (when combined with hyperlipemia) has become a useful tool in the induction and study of model atherosclerotic disease. Of the many methods available for initiating vascular damage, the most frequently used have consisted of local or systemic application of exogenous chemical, hormonal, enzymic, or physical vessel irritants (8, 13, 15-18).

Less commonly studied, at least with respect to the potentiation of atherogenesis, has been the role of naturally occurring body processes, such as hypersensitivities, which result in vascular damage. It is known that hypersensitivity reactions may cause vascular lesions in man and animal (19). Serum sickness is

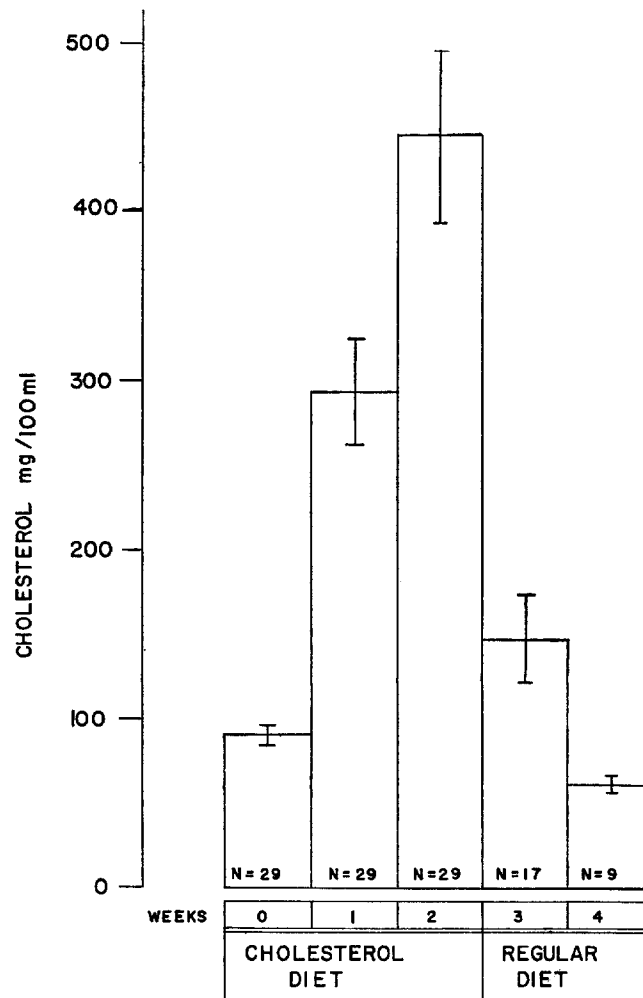


FIG. 5. Total blood cholesterol values (mg/100 ml) of experimental rabbits of Groups 1, 2, and 3, which received an injection of BSA (250 mg/kg body weight) and were maintained on cholesterol supplemented diet (100 g/day, 1% cholesterol by weight) for 2 wk. Animals of group 1 were sacrificed at this time, and those of groups 2 and 3 were changed to regular diet for 1 and 2 wk, respectively, and sacrificed. Mean values, \pm the standard error of the means, are given.

one of these hypersensitivities, and has been extensively studied, especially in the rabbit. This disease develops as the result of the production of antibody to certain foreign proteins, and is characterized by the appearance of lesions in kidney glomeruli and a few well-defined areas of the cardiovascular system. The lesions are characterized by endothelial proliferation, leukocyte infiltration,

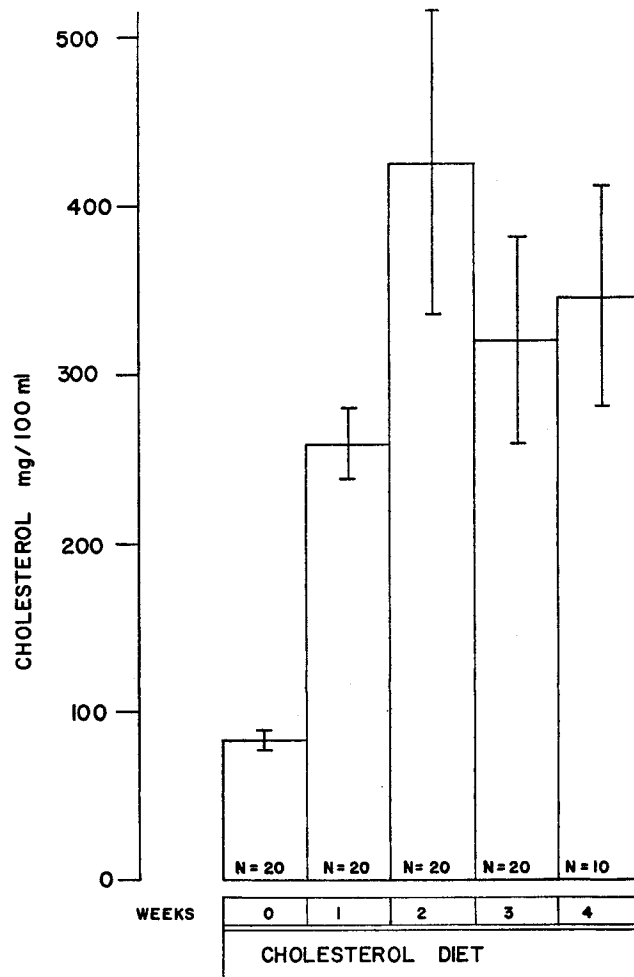


Fig. 6. Total blood cholesterol levels (mg/100 ml) of experimental rabbits of groups 4 and 5, which received a BSA injection (250 mg/kg body weight) and cholesterol supplemented diet (100 g/day, 1% cholesterol by weight) up to time of sacrifice (i.e. after 3 and 4 wk, respectively). Mean values, \pm standard error of the means, are presented.

and sometimes necrosis, and are thought to be mediated by subendothelial accumulations of antigen-antibody complexes (6, 20-25). In one of the most definitive of these studies, Germuth (6) showed that serum sickness lesions appeared in rabbits as early as 8 days after a single administration of foreign protein (BSA), reached a peak incidence by about the 14th day, and tended to heal spontaneously by day 28.

At least three workers have investigated the possibility that a hypersensitive

response of the serum sickness type might potentiate atherosclerosis in the rabbit (1-4). All have independently reported that such potentiation does occur. Two of these studies combined multiple injections of either BSA (4) or horse serum (2, 3) with prolonged (up to 3 months) feeding of cholesterol-supplemented diet. Levy (1), however, was able to detect early atherosclerosis after a single injection of BSA followed by only 2 wk of cholesterol-diet feeding.

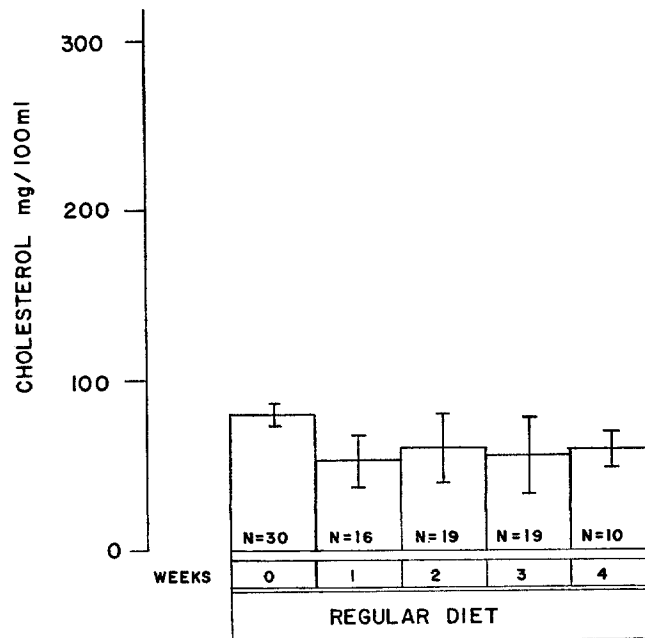


FIG. 7. Total blood cholesterol values (mg/100 ml) for serum sickness control rabbits of groups 6, 7, and 8. These animals received an intravenous injection of BSA (250 mg/kg body weight) and untreated chow for 2, 3, and 4 wk, respectively. Values presented are mean \pm standard errors of the means.

The lack of severity of the lesions noted by Levy (1) raised the question as to their eventual fate if (a) there were no further immune or lipid insult, or (b) if both treatments were to be continued for longer periods of time. The latter question has been answered by Minick et al. (3) who have shown that the more intensive treatment may result in a worsening of the atherosclerotic process. In the present study, we have investigated the former question by following the initial procedure of Levy (1) and subsequently varying the degree of exposure to cholesterol. The present data indicate that animals receiving the combined treatment showed a lesion incidence after 2 or 3 wk of treatment (groups 1, 2, 4)

which was markedly higher than that found in animals fed cholesterol diet only for similar periods (groups 10 and 11). Only after 4 wk of diet alone (group 12) did lesion incidence occur which was comparable with that of the 2 wk dual-treatment animals (group 1). This would seem to be good evidence of the po-

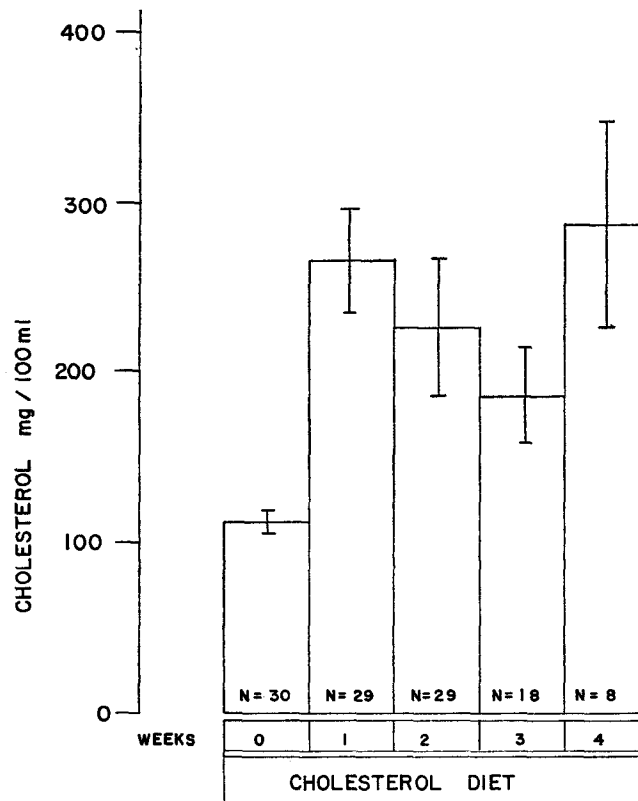


FIG. 8. Total cholesterol levels (mg/100 ml) in sera from control rabbits which received cholesterol diet (100 g/day 1% cholesterol by weight) for 2 (group 10), 3 (group 11), and 4 (group 12) wk. No BSA injection was given. Values represent means \pm standard errors of the means.

tentiation of atherogenesis by serum sickness; it is in agreement with Levy's work (1) and correlates well with the studies of Minick (2), Minick et al. (3), and Roberts (4).

With respect to the ultimate fate of lesions which were present after only 2 wk of combined treatment, the data may indicate that they had advanced to an irreversible stage of development by this time. The main evidence for this is the fact that removal of the animals from high cholesterol diet, with sub-

sequent rapid fall in blood cholesterol levels, did not result in a decrease of lesion incidence. In fact, the incidence seemed to increase in these animals as the period of time after return to regular diet lengthened (groups 2 and 3). In contrast to this pattern, animals which received BSA only (Groups 6-8) showed a definite decrease in number of lesions from wk 2 to 4 which was statistically significant at the 5% level, indicating that lesion healing could have been detected within this period of time if it had been occurring. This latter data is in good agreement with Germuth's (6) study which showed regression of uncomplicated serum sickness lesions.

In partial confirmation of this apparent irreversibility is the report of Minick et al. (3), which noted that lesions found in rabbits subjected to multiple injections of foreign protein and prolonged cholesterol diet did not appear to regress in incidence during subsequent rest periods as long as 2 months in duration. Our data would indicate that very early (i.e., by 2 wk after the initiation of combined treatment) incorporation of lipid was the reason for the persistence of these lesions. It is not known how much lipid is necessary to make a lesion irreversible (8, 13), and the situation is further complicated by evidence indicating that different species, as well as different areas of the vascular tree within the same species, vary in their abilities to handle lipid deposits. Constantinides (8, 13, 26) has reported irreversibility of foam cell lesions in rabbit vessels, while Rodbard et al. (27) have shown that chickens can reverse aortic, but not coronary artery atherosclerosis. Of course, the results of the present study, with respect to lesion regression, will remain inconclusive at least until an experiment has been performed in which longer rest periods have been allowed for reversal of pathology. Such a study is currently underway in this laboratory.

If immunologically induced vascular injury can potentiate rabbit atherosclerosis, it does not seem unreasonable to hypothesize that such might also be the case in humans. Several human diseases of allergic nature, or with allergic overtones, generate vascular lesions similar to those found in serum sickness (28). It would appear that cardiovascular lesions of syphilis or rheumatic fever may evolve into athero- or arteriosclerotic disease (29, 30), and this would be consistent with the above hypothesis. In addition, at least one group has found good correlation between the incidence of coronary arteriosclerosis and history of hypersensitivity of the type known to cause vasculitis (31).

With respect to this hypothesis, it is obvious that the opportunities for the sensitization of man are legion. Not only is he constantly exposed to parental challenges such as artificial immunizations, infections, and drug therapy, but there is growing experimental and clinical evidence that the ingestion of certain antigens may lead to detectable immunoresponsiveness. Induction of immune tolerance (32) and production of circulating antibodies (33, 34) are two responses which have been experimentally evoked as a result of BSA inges-

tion. This is consistent with evidence indicating that many normal humans have circulating anti-BSA antibodies, acquired presumably as a result of ingestion of beef or beef products (33-35). Interestingly, it appears that people with allergic histories tend to develop BSA antibodies more frequently than do nonallergic or normal humans (36). Moreover, data from this laboratory² have indicated that orally induced antibodies may have biological activities similar to those of their parenterally induced counterparts, namely, ability to mediate passive cutaneous anaphylaxis (PCA) and active and passive Arthus phenomena. It is not known whether this *in vivo* activity is correlated with the ability of these antibodies to induce vasculitis of the serum sickness type.

SUMMARY

In this report, the role of vascular allergy (i.e., hypersensitivity) in the potentiation of atherogenesis has been studied. In order to accomplish this, bovine serum albumin (BSA) was administered to rabbits in quantities sufficient to cause the occurrence of serum sickness (a type of hypersensitivity known to cause injury to the endothelial linings of certain blood vessels). This was immediately followed by the feeding of a special cholesterol-supplemented diet, which is known to be capable of initiating a high incidence of atheromatous disease in rabbits after prolonged feeding. Results indicated that those animals which received the combined treatment developed an incidence of pathology after only 2 wk of special diet which was not equaled in the diet-only control groups until they had been treated for 4 wk. This indicated that vascular allergy could potentiate lipemia-induced atherogenesis in the rabbit, and was in confirmation of an earlier study of a similar nature. Indeed, because of the relatively mild vascular injury caused by a single injection of BSA, it would seem as though vascular hypersensitivity was extremely effective in the potentiation of atherogenesis.

In addition, these results may have given some indication of the degree of vascular injury necessary for the induction of irreversible atheromatous disease. While the incidence of lesions in serum sickness controls was seen to decrease with passage of time after BSA challenge, it appeared to increase after cessation of treatment in those animals which received the combined treatment of BSA plus 2 wk of cholesterol-supplemented diet. It would therefore appear that the atheromatous lesions seen as early as 2 wk after initiation of the experiment may already have been irreversible in terms of the resolution of established pathology.

The authors wish to acknowledge the excellent technical assistance provided by the Mrs. H. Gergely, L. Seifert, P. Cohen, J. Eboch, F. Johnston, and H. Kennedy in the completion of this study.

² Van Winkle, M., and L. Levy. Unpublished data.

BIBLIOGRAPHY

1. Levy, L. 1967. A form of immunological atherosclerosis. *In* Advances in Experimental Medicine and Biology. N. R. Di Luzio and R. Paoletti, editors. Plenum Press, New York. **1**:426.
2. Minick, C. R. 1966. The induction of atheroarteriosclerosis in rabbits by repeated injections of foreign serum and diets rich in lipids. *Bull. N. Y. Acad. Med.* **42**:159.
3. Minick, C. R., G. E. Murphy, and W. G. Campbell. 1966. Experimental induction of atheroarteriosclerosis by the synergy of allergic injury to arteries and lipid-rich diet. *J. Exptl. Med.* **124**:635.
4. Roberts, J. C., Jr. 1960. The effects of serum sickness on cholesterol atherosclerosis in the rabbit. *Circulation.* **22**:657.
5. Van Winkle, M., and L. Levy. 1967. Temporal aspects of serum sickness induced atherosclerosis. *Federation Proc.* **26**:432.
6. Germuth, F. G., Jr. 1953. A comparative histologic and immunologic study in rabbits of induced hypersensitivity of the serum sickness type. *J. Exptl. Med.* **97**:257.
7. Brown, A. L. 1965. Pathogenesis of atherosclerosis. *Mayo Clin. Proc.* **40**:815.
8. Constantinides, P. 1965. Experimental Atherosclerosis. Elsevier, Amsterdam, London, New York.
9. Pickering, G. 1964. Pathogenesis of myocardial and cerebral infarction: nodular arteriosclerosis. *Brit. Med. J.* **1**:517.
10. Haust, M. D., and R. H. More. 1965. Spontaneous lesions of the aorta in the rabbit. *In* Comparative Atherosclerosis. J. C. Roberts, Jr., and R. Strauss, editors. Harper and Row, New York and London. 255.
11. Schenk, E. A., E. Gaman, and A. S. Feigenbaum. 1966. Spontaneous aortic lesions in rabbits. I. Morphologic characteristics. *Circulation Res.* **19**:80.
12. Schenk, E. A., E. Gaman, and A. S. Feigenbaum. 1966. Spontaneous aortic lesions in rabbits. II. Relationship to experimental atherosclerosis. *Circulation Res.* **19**:89.
13. Constantinides, P. 1961. Production of experimental atherosclerosis in animals. *J. Atherosclerosis. Res.* **1**:374.
14. Gresham, G. A., and A. N. Howard. 1966. Comparative pathology of spontaneously occurring and experimentally induced atherosclerotic lesions. *In* Methods and Achievements in Experimental Pathology. E. Bajusz and G. Jasmin, editors. S. Karger, Basel. 314.
15. Friedman, M., and S. O. Byers. 1961. Experimental thrombo-atherosclerosis. *J. Clin. Invest.* **40**:1139.
16. Murray, M., G. R. Schrodt, and H. F. Berg. 1965. The enzymatic induction of atherosclerosis. *Arch. Pathol.* **79**:144.
17. Pollak, O. J. 1965. Experimental arteriopathies in the rabbit. *In* Experimental Atherosclerosis. J. C. Roberts, Jr., and R. Strauss, editors. Harper and Row, New York and London. 291.
18. Still, W. J. S., and S. M. Dennison. 1967. Reaction of the arterial intima of the rabbit to trauma and hyperlipemia. *Exptl. Mol. Pathol.* **6**:245.

19. Harkavy, J. 1963. *Vascular Allergy and its Systemic Manifestations*. Butterworths, Washington.
20. Cochrane, C. G. 1963. Studies on the localization of circulating antigen-antibody complexes and other macromolecules in vessels. I. Structural studies. *J. Exptl. Med.* **118**:489.
21. Cochrane, C. G. 1963. Studies on the localization of circulating antigen-antibody complexes and other macromolecules in vessels. II. Pathogenetic and pharmacodynamic studies. *J. Exptl. Med.* **118**:503.
22. Dixon, F. J., J. J. Vasquez, W. O. Weigle, and C. G. Cochrane. 1958. Pathogenesis of serum sickness. *A.M.A. Arch. Pathol.* **65**:18.
23. Kniker, W. T., and C. G. Cochrane. 1965. Pathogenic factors in vascular lesions of serum sickness. *J. Exptl. Med.* **122**:83.
24. Kniker, W. T., and C. G. Cochrane. 1966. Localization of circulating Ag-Ab complexes in serum sickness. *Federation Proc.* **25**:474.
25. Weigle, W. O. 1961. Fate and biological action of antigen-antibody complexes. *Advan. Immunol.* **1**:283.
26. Constantinides, P. 1965. Experimental atherosclerosis in the rabbit. *In Comparative Atherosclerosis*. Harper and Row. New York and London. 276.
27. Rodbard, S., R. Pick, and L. N. Katz. 1954. The rate of regression of hypercholesterolemia and atherosclerosis in chicks: Effects of diet, pancreatectomy, estrogens and thyroid. *Circulation.* **10**:597.
28. Rich, A. R. 1946. Hypersensitivity in disease. *Harvey Lectures, Ser. 42*. 106.
29. Leary, T. 1940. Syphilitic aortitis as a cause of sudden death. *New Engl. J. Med.* **789**:223.
30. Murphy, G. E., and H. F. Swift. 1950. The induction of rheumatic-like cardiac lesions in rabbits by repeated focal infections with Group A streptococci. *J. Exptl. Med.* **91**:485.
31. Saphir, O., M. Telischi, and L. Ohringer. 1962. Rabbit sulfa drug hypersensitivity and lesions resembling early arteriosclerosis. *Arch. Pathol.* **73**:414.
32. Filipp, G., and B. v. Boros. 1967. The induction of immunological tolerance by antigen feeding. The effect of thymectomy on orally induced tolerance. *J. Allergy.* **39**:167.
33. Minden, P., R. T. Reid, and R. S. Farr. 1966. A comparison of some commonly used methods for detecting antibodies to bovine albumin in human serum. *J. Immunol.* **96**:180.
34. Rothberg, R. M., S. C. Kraft, and R. S. Farr. 1967. Similarities between rabbit antibodies produced following ingestion of bovine serum albumin and following parenteral immunization. *J. Immunol.* **98**:386.
35. Kraft, S. C., R. M. Rothberg, C. M. Knauer, A. C. Svobodo, L. A. Monroe, and R. S. Farr. 1967. Gastric acid output and circulating anti-bovine serum albumin in adults. *Clin. Exptl. Immunol.* **2**:321.
36. Barrick, R. H., and R. S. Farr. 1965. The increased incidence of circulating anti-beef albumin in the sera of allergic persons and some comments regarding the possible significance of this occurrence. *J. Allergy.* **36**:374.

FIG. 9. Lesion in the coronary artery of a rabbit from group 2 which received one BSA injection (250 mg/kg, i.v.) plus 2 wk feeding of a 1% (by weight) cholesterol diet (100 g/day). The rabbit then received regular (untreated) feed for 1 wk, and was sacrificed. Note the narrowing of the artery lumen by the lesion (arrow). Weigert's resorcin fuchsin elastic stain. $\times 100$.

FIG. 10. Oil immersion magnification of a section of the lesion shown in Fig. 9. Note the breaks in the internal elastic membrane (arrows). $\times 1000$.

FIG. 11. Lesion in the valvular area of the ascending aorta of a rabbit which received regular diet for 2 wk following treatment with intravenous injection of BSA (250 mg/kg) and feeding of 1% cholesterol diet for 2 wk (group 3). Note the presence of foam cells (arrows). Hematoxylin and eosin stain. $\times 1000$.

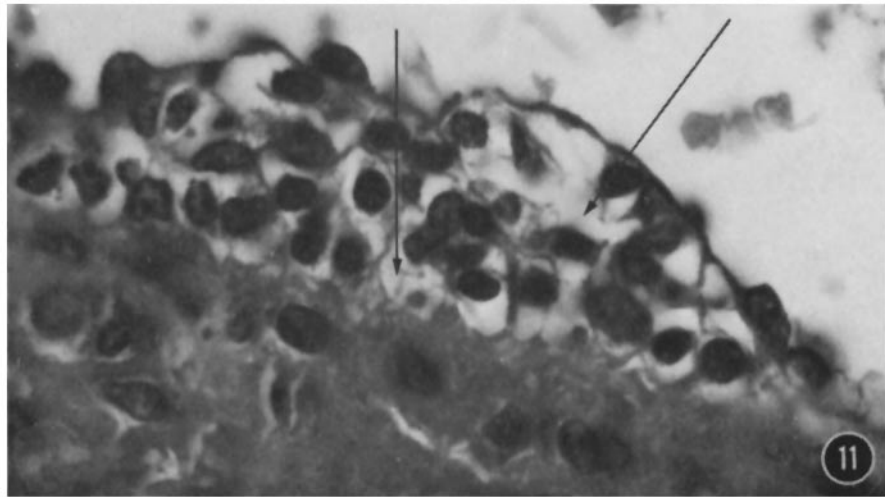
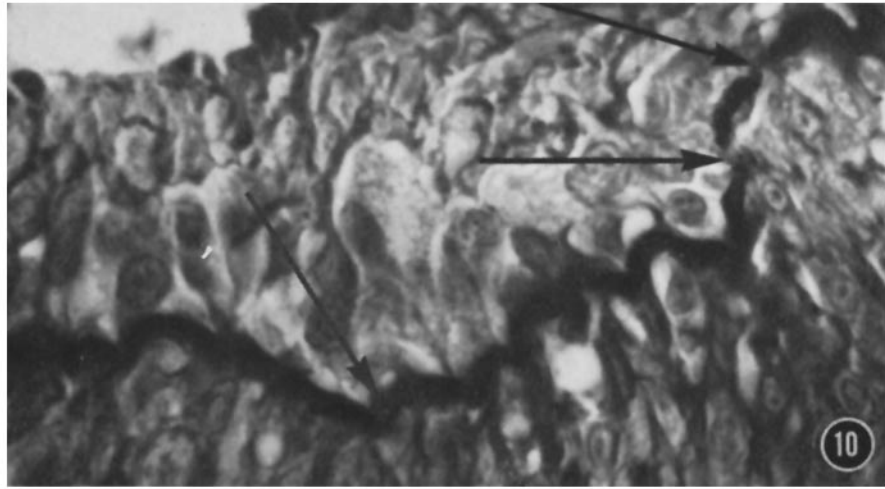
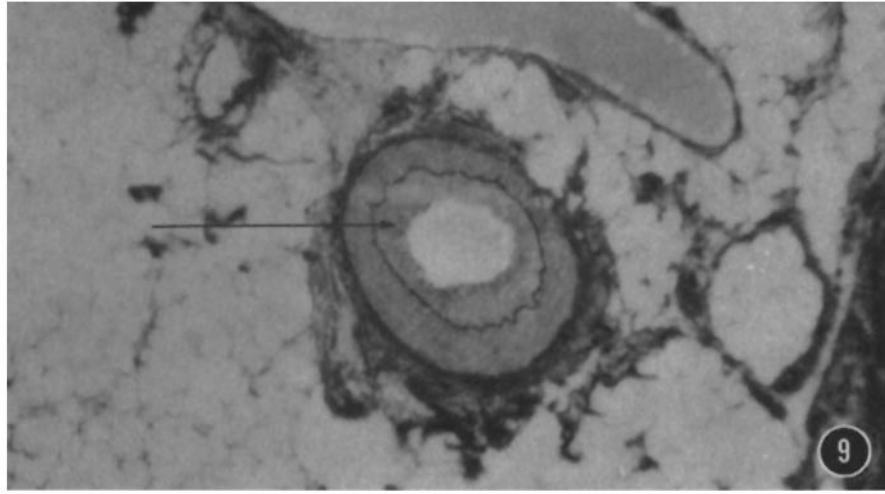


FIG. 12. Lesion found in the ascending aorta of a rabbit treated as noted in Fig. 11 (i.e., BSA and 2 wk cholesterol diet and 2 wk regular diet, group 3). Lipid inclusions may be noted here (arrows). Oil red "O" lipid stain. $\times 1000$.

FIG. 13. Lesion (ascending aorta) showing a cell in mitosis (arrow). This animal received BSA and cholesterol diet for 3 wk (group 4). Hematoxylin and eosin stain. $\times 1000$.

FIG. 14. Lesion found in the ascending aorta of a rabbit treated with cholesterol diet only for 2 wk (group 10). Note swelling and reduplication of the internal elastic membrane (arrows). Pollak's rapid trichrome stain. $\times 1000$.

