

Single Case

Leukoderma Induced by Rotigotine Patch, a Transdermal Dopamine Agonist

Ronan Talty^{a, b} Goran Micevic^{a, b} Alice Wang^{a, c} Christine J. Ko^a
William Damsky^{a, b}

^aDepartment of Dermatology, Yale School of Medicine, New Haven, CT, USA; ^bDepartment of Pathology, Yale School of Medicine, New Haven, CT, USA; ^cMedical Scientist Training Program, Renaissance School of Medicine at Stony Brook University, New York, NY, USA

Keywords

Leukoderma · Rotigotine · Dopamine · Parkinson's disease · Melanin · Tyrosinase

Abstract

Leukoderma, or hypomelanosis of the skin, can occur in response to various chemical and pharmacologic substances ranging from topical medications to optic preparations and systemic medications. In this case report, we present a 78-year-old man with a history of restless leg syndrome (RLS) who had been using rotigotine transdermal patches once daily for 1 year and developed leukoderma on the bilateral anterior shoulders in the area of patch application. Histopathologic examination showed an absence of melanocytes at the dermal-epidermal junction confirmed by Melan A stain. While the patient was not bothered by the depigmentation and elected to continue the rotigotine patch for his RLS, this case highlights leukoderma as a potential side effect of dopamine transdermal patches and offers insight into the potential mechanism of hypopigmentation in response to dopamine agonism.

© 2022 The Author(s).

Published by S. Karger AG, Basel

Introduction

Leukoderma, or hypomelanosis of the skin, can be induced by a variety of chemical and pharmacologic substances, including topical medications (i.e., corticosteroids and imiquimod), optic preparations, or systemic medications, such as imatinib. The mechanism of chemically

induced leukoderma is generally due to either a decreased number of melanocytes (melanocytopenia) or a decreased production of melanin (melanopenia) [1]. For example, phenol derivatives (e.g., hydroquinone) and monobenzyl ether of hydroquinone (MBEH) are purposely used to induce reversible and permanent hypomelanosis in pigmentation disorders, respectively. Hydroquinone causes melanopenia through reversibly inhibiting tyrosinase, while MBEH is selectively melanocytotoxic, causing irreversible cell death [2]. The mechanism is thought to involve generation of reactive oxygen species, triggering an unfolded protein response, and in some cases autophagy [3].

Rotigotine is a dopamine agonist used to treat Parkinson disease (PD) and restless leg syndrome (RLS). It is available as a transdermal patch (Neupro) that is available at various doses ranging from 1 to 8 mg per 24 h. Application site reactions are common, and patients are instructed to rotate application sites, not using any single site more than once every 14 days [4]. Application site reactions are dose-dependent, characterized by erythema and/or edema limited to the patch area, and are thought to be primarily irritant in nature [5]. Herein, we present a case of rotigotine-induced melanocytopenic leukoderma.

Case Report

A 78-year-old man with a history of restless leg syndrome has been using rotigotine transdermal patches (2 mg/24 h) once daily for the past 1 year. Over the past 4 months, the patient noted lightening of the skin on the bilateral anterior shoulders in the area of patch application. He denied any erythematous lesions or symptoms in these areas. He had been rotating patch application within this area but had not applied to other areas of skin. His other medical history included polymyalgia rheumatica, depression, chronic idiopathic pruritus, hypertension, hyperlipidemia, atrial fibrillation, as well as cutaneous squamous cell carcinoma and basal cell carcinoma. He was also taking prednisone 10 mg daily, oxycodone, dabigatran, lisinopril, pregabalin, furosemide, atorvastatin, and fluoxetine.

Physical exam showed sharply demarcated depigmented patches on the bilateral anterior shoulders (shown in Fig. 1). Wood's lamp exam showed bright fluorescence throughout most of the lesion with a thin border of dimmer fluorescence that merged into the unaffected surrounding skin. Lentigines were nearly absent as compared to the surrounding skin. No other lesions were noted, and no suspicious melanocytic lesions were identified on a complete mucocutaneous examination. Shave biopsy was performed on the left shoulder at the edge of

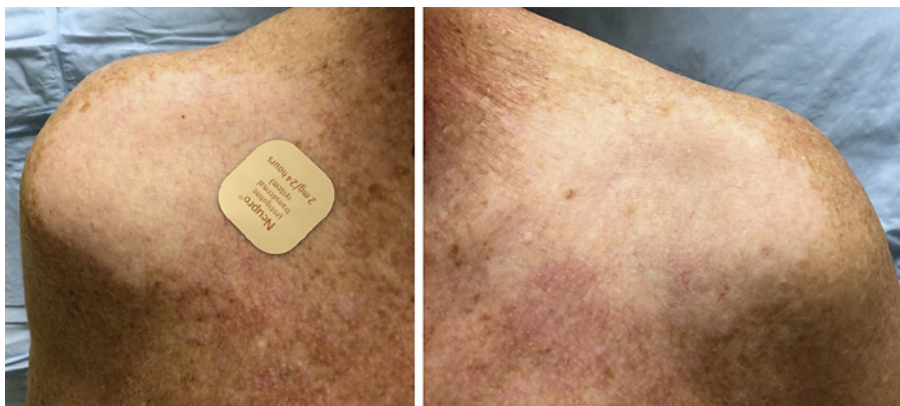

Fig. 1. Sharply demarcated depigmented patches on the bilateral anterior shoulders, where rotigotine patch was applied.

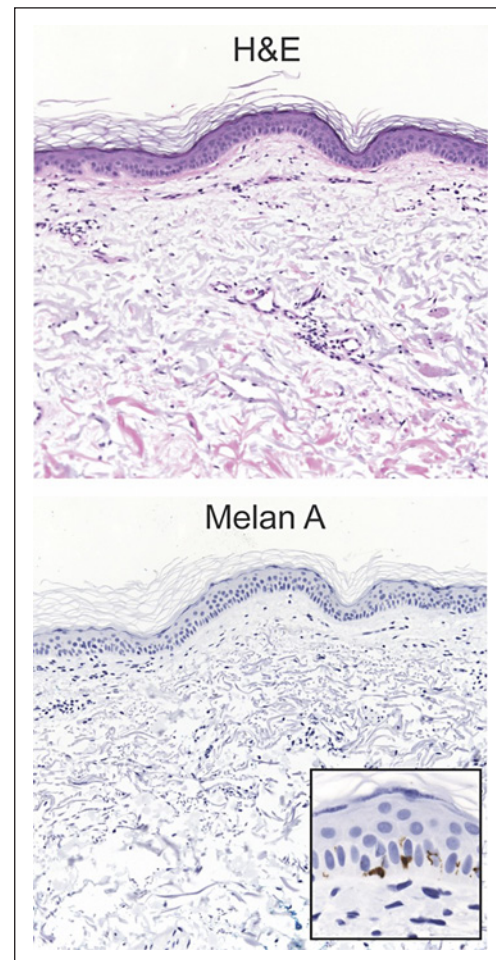


Fig. 2. **a** H&E and **b** Melan A immunohistochemistry showed a nearly complete loss of melanocytes. Focal Melan A-positive melanocytes were retained at one edge of the biopsy (**inset**).

the depigmented area. Histopathologic examination showed an absence of melanocytes at the dermal-epidermal junction (shown in Fig. 2). A Melan A stain was performed and also showed a near complete absence of melanocytes; Melan A-positive melanocytes were retained at the edge of the biopsy (shown in Fig. 2, inset). The patient was not bothered by the depigmentation and chose to continue the rotigotine patch for his RLS. He was instructed to rotate the patch among other areas (abdomen, thigh, hip, flank, shoulder, or upper arm), as recommended in the rotigotine package insert.

Discussion

Here we report a patient who developed depigmentation at the application sites of a rotigotine transdermal patch. Although the histopathologic differential diagnosis would include vitiligo, the clinical history and limited distribution of lesions support a drug-related etiology. Rotigotine is a non-ergolinic dopamine agonist with the highest potency for the dopamine D₃ receptor and is commonly used in PD and RLS. There is a single prior report in non-dermatologic literature describing apparent depigmentation in the setting of rotigotine use [6]. However, no histologic studies were performed, and the mechanism of hypomelanosis was not further investigated. A review of the literature lends potential support to both melanopenic and melanocytopenic mechanisms for dopamine-induced depigmentation. Dopamine was shown

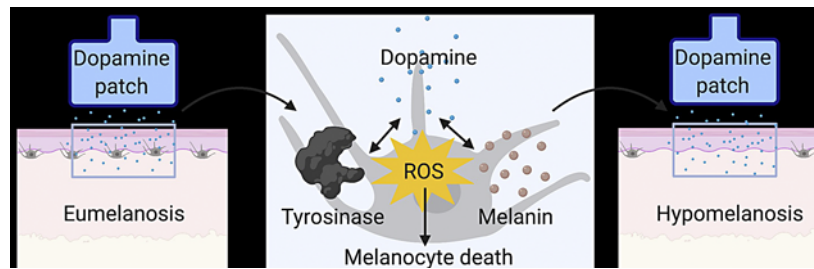


Fig. 3. Potential mechanism of melanotoxicity seen with dopamine agonists. Dopamine, through an interaction with melanin or generation of dopaquinone intermediates by tyrosinase, may generate reactive oxygen species (ROS) that lead to melanocyte death and hypomelanosis.

to decrease pigmentation of hair follicle melanocytes *in vitro* by generating reactive oxygen species, a phenotype which could be rescued by treatment with the reducing agent N-acetylcysteine [7]. Similarly, dopamine agonists have been reported to directly inhibit tyrosinase activity of hair follicular melanocytes in mice [8]. In both studies, the leukoderma was reversible and did not cause apparent melanocyte death. Others have demonstrated that dopamine can induce melanocyte apoptosis by triggering oxidative damage and activation of the c-Jun N-terminal kinase [9, 10]. Chlorpromazine, a D2 receptor antagonist, has been shown to increase melanin production, further suggesting a relevant role for dopamine agonists and antagonists in skin pigmentation [10]. Preclinical evaluation of rotigotine in rats and monkeys demonstrated drug binding to melanocyte-containing tissue after a single dose, and the accumulation gradually cleared over a 2-week period [4].

Our observation of the histopathologic absence of melanocytes is more compatible with melanocyte death, albeit based on a single tissue time point. Dopamine-induced leukoderma may be both melanopenic and melanocytopenic, depending on the tissue concentration, overall cytosolic oxidative status of the melanocyte, and length of exposure. Further studies are needed to elucidate the mechanisms of dopamine agonist-mediated hypomelanosis (shown in Fig. 3).

Interestingly, the loss of melanin-expressing dopaminergic neurons in the substantia nigra seen in PD is also thought to occur via dopamine-induced ROS and activation of c-Jun N-terminal kinase. Parkin, an E3 ubiquitin ligase that is commonly lost in PD, protects against dopamine toxicity by increasing cytosolic glutathione levels and abrogating oxidative stress and apoptosis. Parkin loss is also associated with melanoma, which has a nearly four-fold elevated incidence in patients suffering from PD [1].

With this report, we hope to aid in the recognition of leukoderma as a potential side effect of dopamine transdermal patches. PD patients, who may often be seen in dermatology practices due to a higher risk of melanoma development, are the likely patient population to wear a dopamine transdermal patch and should be educated regarding the potential cosmetic and UV sensitivity implications. Rotating the placement of the patch on sites frequently covered by clothing, such as the bilateral thighs, may minimize both of these effects.

Statement of Ethics

This study is a medical case report, and ethical approval was not required for this study in accordance with local and national guidelines. Written informed consent was obtained from the patient for publication of the details of their medical case and any accompanying images.

Conflict of Interest Statement

Ronan Talty, Goran Micevic, Alice Wang, and Christine J. Ko have no conflicts of interest to declare. William Damsky has research funding from Pfizer, is a consultant for Eli Lilly and Twi Biotechnology, and receives licensing fees from EMD/Sigma/Millipore in unrelated work.

Funding Sources

There were no funding sources for this work. Ronan Talty is supported by NIH F30CA254246-01A1. William Damsky is supported by a Career Development Award from NIAMS K08AI159229-01.

Author Contributions

Ronan Talty, Goran Micevic, Alice Wang, Christine J. Ko, and William Damsky were involved in the conception and preparation of this manuscript. Ronan Talty and Goran Micevic drafted the manuscript and figures. Alice Wang, Christine J. Ko, and William Damsky critically revised the manuscript for important intellectual content. Goran Micevic and William Damsky were directly involved in the care of this patient. Ronan Talty, Goran Micevic, Alice Wang, Christine J. Ko, and William Damsky have all provided final approval for this version of the manuscript to be published.

Data Availability Statement

All data generated or analyzed during this study are included in this article. Further inquiries can be directed to the corresponding author.

References

- 1 Bologna JL, Schaffer JV, Cerroni L. *Dermatology*. Elsevier Limited; 2018.
- 2 Hariharan V, Klarquist J, Reust MJ, Koshoffer A, McKee MD, Boissy EF, et al. Monobenzyl ether of hydroquinone and 4-tertiary butyl phenol activate markedly different physiological responses in melanocytes: relevance to skin depigmentation. *J Invest Dermatol*. 2010;130(1):211–20.
- 3 Harris JE. Chemical-induced vitiligo. *Dermatol Clin*. 2017;35(2):151–61.
- 4 Frampton JE. Rotigotine transdermal patch: a review in Parkinson's disease. *CNS Drugs*. 2019;33(7):707–18.
- 5 In brief: transdermal rotigotine (Neupro). *Med Lett Drugs Ther*. 2012; 54(1397): 68.
- 6 Prakash N, Chand P. Chemical leukoderma: a rare adverse effect of the rotigotine patch. *Mov Disord Clin Pract*. 2017;4(5):781–3.
- 7 Chu CY, Liu YL, Chiu HC, Jee SH. Dopamine-induced apoptosis in human melanocytes involves generation of reactive oxygen species. *Br J Dermatol*. 2006;154(6):1071–9.
- 8 Burchill SA, Thody AJ. Dopaminergic inhibition of tyrosinase activity in hair follicular melanocytes of the mouse. *J Endocrinol*. 1986;111(2):233–7.
- 9 Park ES, Kim SY, Na JI, Ryu HS, Youn SW, Kim DS, et al. Glutathione prevented dopamine-induced apoptosis of melanocytes and its signaling. *J Dermatol Sci*. 2007;47(2):141–9.
- 10 Lin M, Lu SS, Wang AX, Qi WY, Zhao D, Wang ZH, et al. Apigenin attenuates dopamine-induced apoptosis in melanocytes via oxidative stress-related p38, c-Jun NH2-terminal kinase and Akt signaling. *J Dermatol Sci*. 2011;63(1):10–6.