

Case Report

Depression Associated with Dysembryoblastic Neuroepithelial Tumor

Anand Lingeswaran, Deepak Barathi¹

ABSTRACT

Dysembryoblastic neuroepithelial tumor (DNET), a benign, rare tumor of the brain, commonly presents with generalized or partial epilepsy, post-epilepsy sequelae of psychotic, depressive or anxiety symptoms or disorders, or is usually asymptomatic. We report the first case in scientific literature of temporal lobe DNET presenting with only major depressive disorder, without epilepsy. A 24-year-old single male, presented with pervasive sadness, easy fatigability, loss of interest in his daily activities, decreasing appetite associated with poor of quality sleep, poor attention and concentration, pessimism about the future, and headaches. He was diagnosed with severe depression, without psychotic symptoms. Magnetic resonance imaging of the brain showed a lobulated hyperintense temporal lobe mass of 2.7×2.2 mm in the hippocampus region suggestive of a DNET. Electroencephalography, thyroid function tests, blood sugar, and electrocardiogram were normal. The depression responded well to tablet Escitalopram 10 mg once daily initially, with no adverse effects reported.

Key words: Depression, dysembryoblastic neuroepithelial tumor, electroencephalogram, escitalopram, temporal lobe

INTRODUCTION

According to the World Health Organization (WHO) classification of tumors (2000), Dysembryoblastic neuroepithelial tumor (DNET) are Grade I, neuronal, and mixed neuronal glial tumors.^[1] They are benign, rare, low-grade, mixed neuronal, and glial tumors, with a supratentorial cortical location, preferentially involving, in decreasing order, the temporal, frontal, parietal, and occipital lobes, and the extracortical areas such as, the

cerebellum, pons, caudate nucleus, lateral ventricle, septum pellucidum, and fornix.^[2]

They usually occur in children and young adults commonly with a longstanding history of drug-resistant, intractable, generalized or complex partial seizures. If the tumor involves the cerebral hemispheres, seizures occur in at least 50% of the cases. These slow-growing tumors usually show an indolent course and are clinically and radiologically stable for many years of one's life, with a favorable prognosis, and complete resection is the treatment of choice, without any need for chemotherapy and / or radiation therapy. The ages of DNET patients' requiring neurosurgical resection ranged from 3 to 30 years, and those of patients who presented with a longstanding history of symptoms, ranged from 2 to 18 years. DNET are the most common curable causes of complex partial seizures and epilepsy surgery, usually resulting in complete recovery from seizures.^[3]

Access this article online	
Website: www.ijpm.info	Quick Response Code 
DOI: 10.4103/0253-7176.106028	

Department of Psychiatry, Indira Gandhi Medical College and Research Institute, Puducherry, ¹Department of Radiology, JIPMER, Puducherry, India

Address for correspondence: Dr. Anand Lingeswaran
Department of Psychiatry, Indira Gandhi Medical College and Research Institute, Vazhudavur Road, Puducherry - 605009, India.
E-mail: anafonix@gmail.com

To date, there is only one case report of the association of DNET and schizophreniform features of paranoia, depression, and psychosis; the latter occurring as postoperative complications.^[4] Such symptoms have been speculated to occur as a consequence of intractable epilepsy leading to 'forced normalization' preoperatively. This is the first ever clinical report of DNET presenting atypically, with major depression, in the absence of any other neuropsychiatric problems, including epilepsy.

CASE REPORT

Our patient was a 24-year-old, single male, working as an accountant in a bank. He presented initially to a physician with complaints of nonspecific diffuse headaches, which had started one year before. In view of working on computers, an ophthalmologist's evaluation was advised, which was reported as normal. An otorhinolaryngologist's opinion ruled out the possibility of other causes for headache. A neurologist consultation ruled out any intracranial causes for his headache. He was prescribed pain relief medications that provided transient relief, for few minutes only. Subsequently, he was referred to us for psychiatric assessment of the headache. A thorough clinical history revealed the concurrent presence of pervasive sadness, easy fatigability, lack of interest in his daily activities, decreasing appetite associated with poor quality of sleep, poor attention and concentration, pessimism about the future, along with the presenting symptom of headache. There were no life stressors, suicidal ideas, or psychotic symptoms. His birth and developmental history was normal and there was no past history of alcohol or other substance-use disorders, epilepsy, head injury, or any dental problems. He was not a known hypertensive and not on any medications for other medical illnesses, which could adversely produce headache-like symptoms. Hence, a diagnosis of severe depression without psychotic symptoms was made, according to ICD-10. As the headache was the presenting symptom, a magnetic resonance imaging (MRI) brain scan was carried out, to rule out the possibility of any intracranial space-occupying lesion. Surprisingly, the MRI of the brain showed a lobulated hyperintense temporal lobe mass of size 2.7×2.2 mm, in the hippocampus region, which the radiologist reported as suggestive of DNET [Figures 1 and 2].

A repeat neurologist opinion was sought to rule out the possibility of temporal lobe epilepsy as the etiology of the headache. Electroencephalography was obtained and it showed a normal EEG pattern. A neurosurgery consultation recommended no surgical intervention due to the absence of epilepsy and any intracranial

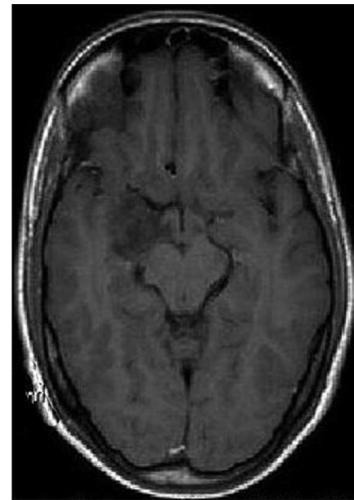


Figure 1: The MRI of the brain showing a cortical-based mass lesion at the medial aspect of the right temporal lobe, involving the Amygdala and part of the head of the hippocampus

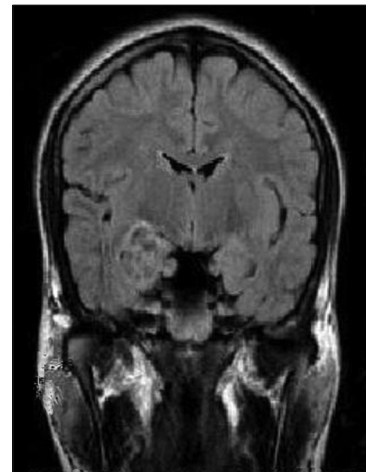


Figure 2: The MRI of the brain showing a hypointense mass lesion on T1, hyperintense on T2, giving a 'bubbly' appearance, and a mixed signal, with a bright rim in the Fluid attenuated inversion recovery images

compression effects of the brain or ventricles. Further investigations like blood sugar, electrolytes, hemogram, liver function tests, and thyroid profile, were all within normal limits. In this background, we started him on Tablet Escitalopram 10 mg once daily. After four weeks of this treatment, the Hamilton Depression Rating score dropped from 29 at baseline to 12 after treatment, with no adverse effects of medications reported. Subjectively, the patient reported complete relief of headache and improved mood levels. His attention and concentration was better at work. He has been maintained on the same dose of Escitalopram for the past four months, and the initial improvement has not worsened. There is no evidence of epilepsy or evidence of raised intracranial tension now. A repeat MRI brain revealed absolutely no change in the DNET tumor diagnosed initially.

DISCUSSION

It is not surprising to find that temporal lobe DNET in this case has presented with depression, while enough evidence exists that links the hippocampus with depression. Neuroimaging studies in patients with depression show volume loss in the hippocampus. Depressed patients have hippocampal volume loss,^[5,6] and bilateral reduction in hippocampal gray matter, which may be worse with more bouts of major depression. The response to treatment with selective serotonin reuptake inhibitors (SSRI) is explainable based on the implication of serotonin in depression. As commonly thought, although headaches can also be the sole or most predominant clinical manifestation of latent epileptic seizures, this occurrence is a relatively rare situation.^[7] Distinguishing the symptoms of a seizure disorder from those of psychiatric illness may be difficult, because of the occasional similarity in presentation for these conditions. Clinicians rely on the patient's presenting diagnosis when treating psychiatric disorders and often assume that psychiatric symptoms such as panic or anxiety result from psychiatric disorders. Neurologic referral is highly dependent on a psychiatrist's ability to detect subtle signs and symptoms of a neurological disorder.

Complex partial seizures (CPS) are the most common form of epilepsy in adults. Patients with CPS may manifest a wide variety of symptoms, including affective, behavioral, and cognitive symptoms, stereotyped movements or behavior, paroxysmal anxiety or somatic symptoms, bizarre or incongruous affect, and changes in cognition. On account of these, patients with CPS are frequently misdiagnosed with psychiatric illnesses. Some characteristic differentiating features of CPS that are atypical for primary psychiatric syndromes include gustatory and olfactory hallucinations, micropsia or macropsia, and intense delusions involving bodily harm, déjà vu, or 'out-of-body' experiences. As none of these typical symptoms were noted in our case, a primary psychiatric diagnosis was certain.

Surgical intervention is indicated in DNET with intractable seizures^[8] but fortunately our case did not necessitate any such invasive surgical intervention indicating a good prognosis for the patient. Henceforth,

it is important to thoroughly investigate such patients before considering psychiatric evaluation and it can be hypothesized that DNET presenting with only psychiatric symptoms or disorders may carry a favorable outcome.

ACKNOWLEDGMENT

I wish to thank the co-author of this article for providing expert opinion on the radiological content of the material. I owe special thanks to the participation of the patient and his carers, without whom this article would not be possible.

Organization: Department of Psychiatry, Indira Gandhi Medical College and Research Institute, Puducherry - 605009, India.

REFERENCES

1. Daumas-Duport C, Pietsch T, Lantos PL. Dysembryoplastic neuroepithelial tumour. In: Kleihues P, Cavenee WK (eds): World Health Organization Classification of Tumours: Pathology and Genetics of Tumours of the Nervous System. Lyon: IARC Press, 2000; 103-06.
2. Stanesco Cosson R, Varlet P, Beuvon F, Daumas Duport C, Devaux B, Chassoux F, et al. Dysembryoplastic neuroepithelial tumors: CT, MR findings and imaging follow-up: a study of 53 cases. *J Neuroradiol* 2001; 28:230-40.
3. Lee MC, Kang JY, Seol MB, Kim HS, Woo JY, Lee JS, et al. Clinical features and epileptogenesis of Dysembryoplastic neuroepithelial tumor. *Childs Nerv Syst* 2006;22:1611-8.
4. Andermann LF, Savard G, Meencke HJ, McLachlan R, Moshé S, Andermann F. Psychosis after resection of ganglioglioma or DNET: Evidence for an association. *Epilepsia* 1999;40:83-7.
5. Bremner JD, Narayan M, Anderson ER, Staib LH, Miller HL, Charney DS. Hippocampal volume reduction in major depression. *Am J Psychiatry* 2000a;157:115-8.
6. MacQueen GM, Campbell S, McEwen BS, Macdonald K, Amano S, Joffe RT, et al. Course of illness, hippocampal function, and hippocampal volume in major depression. *Proc Natl Acad Sci* 2003;100:1387-92.
7. Laplante P, Saint JH, Bouvier G. Headache as an epileptic manifestation. *Neurology* 1983;33:1493-5.
8. Daumas-Duport C, Scheithauer BW, Chodkiewicz JP, Laws ER Jr, Vedrenne C. Dysembryoplastic neuroepithelial tumor: A surgically curable tumor of young patients with intractable partial seizures; Report of thirty-nine cases. *Neurosurgery* 1988;23:545-56.

How to cite this article: Lingeswaran A, Barathi D. Depression associated with dysembryoplastic neuroepithelial tumor. *Indian J Psychol Med* 2012;34:273-5.

Source of Support: Nil, **Conflict of Interest:** None.