

# Dexamethasone implant for immunogammopathy maculopathy associated with IgA multiple myeloma

Constantine D. Georgakopoulos, Panagiotis Plotas, Angelos Angelakis, Konstantinos Kagkellaris, Evangelia Tzouvara and Olga E. Makri 

*Ther Adv Ophthalmol*

1–6

DOI: 10.1177/  
2515841418820441

© The Author(s), 2019.  
Article reuse guidelines:  
sagepub.com/journals-  
permissions

## Abstract

**Background:** We describe a case where hyperviscosity retinopathy and immunogammopathy maculopathy were the presenting features of IgA multiple myeloma and report the response of maculopathy to intravitreal injection of dexamethasone implants.

**Case presentation:** A 56-year-old man presented at the Department of Ophthalmology with the chief complain of reduced vision for the past 10 days in both eyes. Ophthalmic examination revealed central retinal vein occlusion resembling signs with severe macular edema in both eyes with prominent serous macular detachment. After comprehensive evaluation, an IgA type kappa multiple myeloma was diagnosed complicated with hyperviscosity-associated retinopathy and immunogammopathy maculopathy. Patient was treated with multiple sessions of plasmapheresis, systemic chemotherapy, and finally intravitreal implants of dexamethasone with complete restoration of macular edema and serous macular detachment in both eyes. The visual function and the hyperviscosity-associated retinopathy were partially restored.

**Conclusion:** Ocular manifestation might be the only presenting sign of a life-threatening disease such as IgA multiple myeloma. A high level of suspicion is required to diagnose and treat such cases promptly and effectively.

**Keywords:** chemotherapy, dexamethasone implants, hyperviscosity syndrome, hyperviscosity syndrome-associated retinopathy, IgA multiple myeloma, immunogammopathy maculopathy, plasmapheresis

Received: 26 August 2018; revised manuscript accepted: 29 November 2018.

## Background

Bilateral, simultaneous central retinal vein occlusion (CRVO) is a rare feature with a prevalence rate of 0.41%–7.7% of all patients with CRVO. It occurs in the context of an underlying systemic pathologic condition such as coagulopathy, dysproteinemia, and hyperviscosity syndrome (HVS) due to Waldenström's macroglobulinemia (WM) or multiple myeloma (MM), inflammatory condition, malignant hypertension, or infection.<sup>1</sup> In such cases, an extensive systemic investigation with interdisciplinary collaboration is warranted to evaluate the patient for an underlying possible life-threatening pathology.

Multiple myeloma (MM) is a hematologic malignancy characterized by infiltration of bone

marrow by immature atypical plasma cells that produce monoclonal abnormal immunoglobulins. The most common is IgG MM, characterized by excess of serum IgG, followed by IgA MM characterized by IgA overproduction.<sup>2,3</sup> Bilateral CRVO-resembling image is extremely rare as the presenting sign of MM.<sup>4</sup>

We describe a patient who presented with retinal changes resembling bilateral CRVO with macular edema (ME) and prominent serous macular detachment (SMD). The patient was diagnosed with IgA MM and was successfully treated with plasmapheresis, chemotherapy, and dexamethasone implant. A written informed consent has been obtained from the patient for the case report to be published.

Correspondence to:

**Olga E. Makri**  
Consultant  
Ophthalmologist,  
Department of  
Ophthalmology, Medical  
School, University of  
Patras, 265 04 Patras,  
Greece.

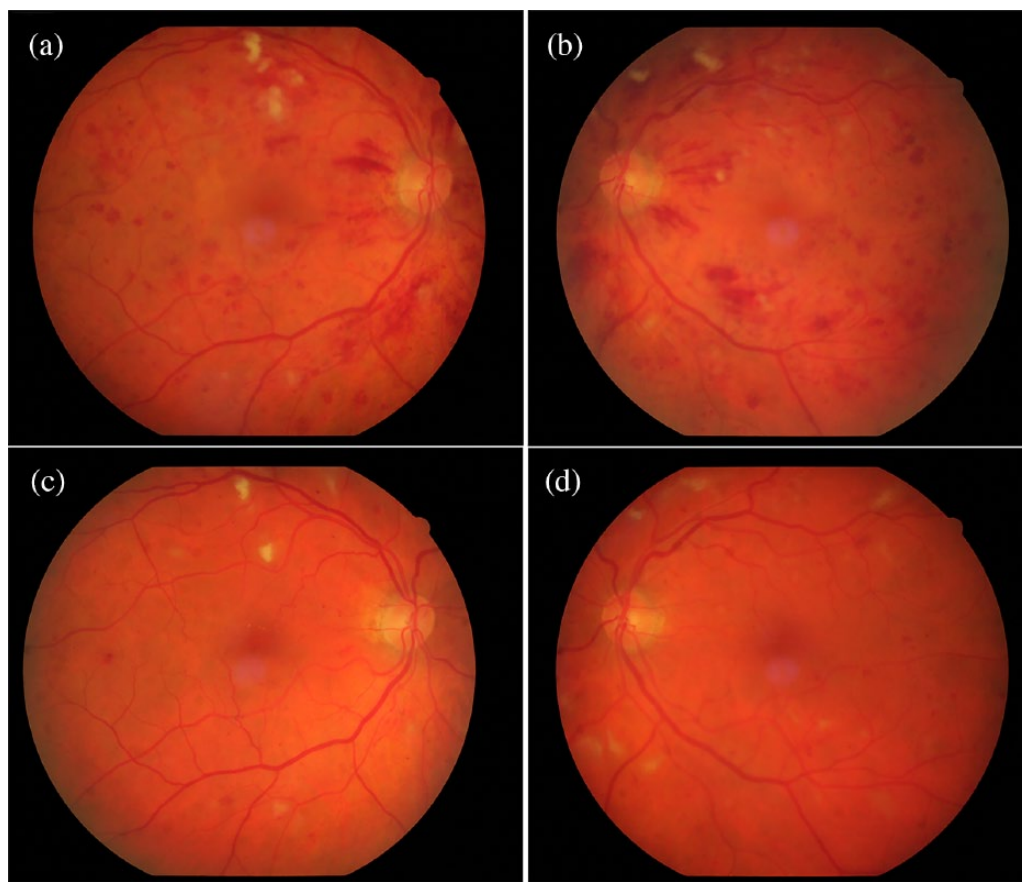
[makriolga@upatras.gr](mailto:makriolga@upatras.gr)

**Constantine D.  
Georgakopoulos  
Panagiotis Plotas  
Angelos Angelakis  
Konstantinos Kagkellaris**

Department of  
Ophthalmology, Medical  
School, University of  
Patras, Patras, Greece

**Evangelia Tzouvara**  
Department of Internal  
Medicine, Medical School,  
University of Patras,  
Patras, Greece

**Olga E. Makri**  
Department of  
Ophthalmology, Medical  
School, University of  
Patras, Patras, Greece



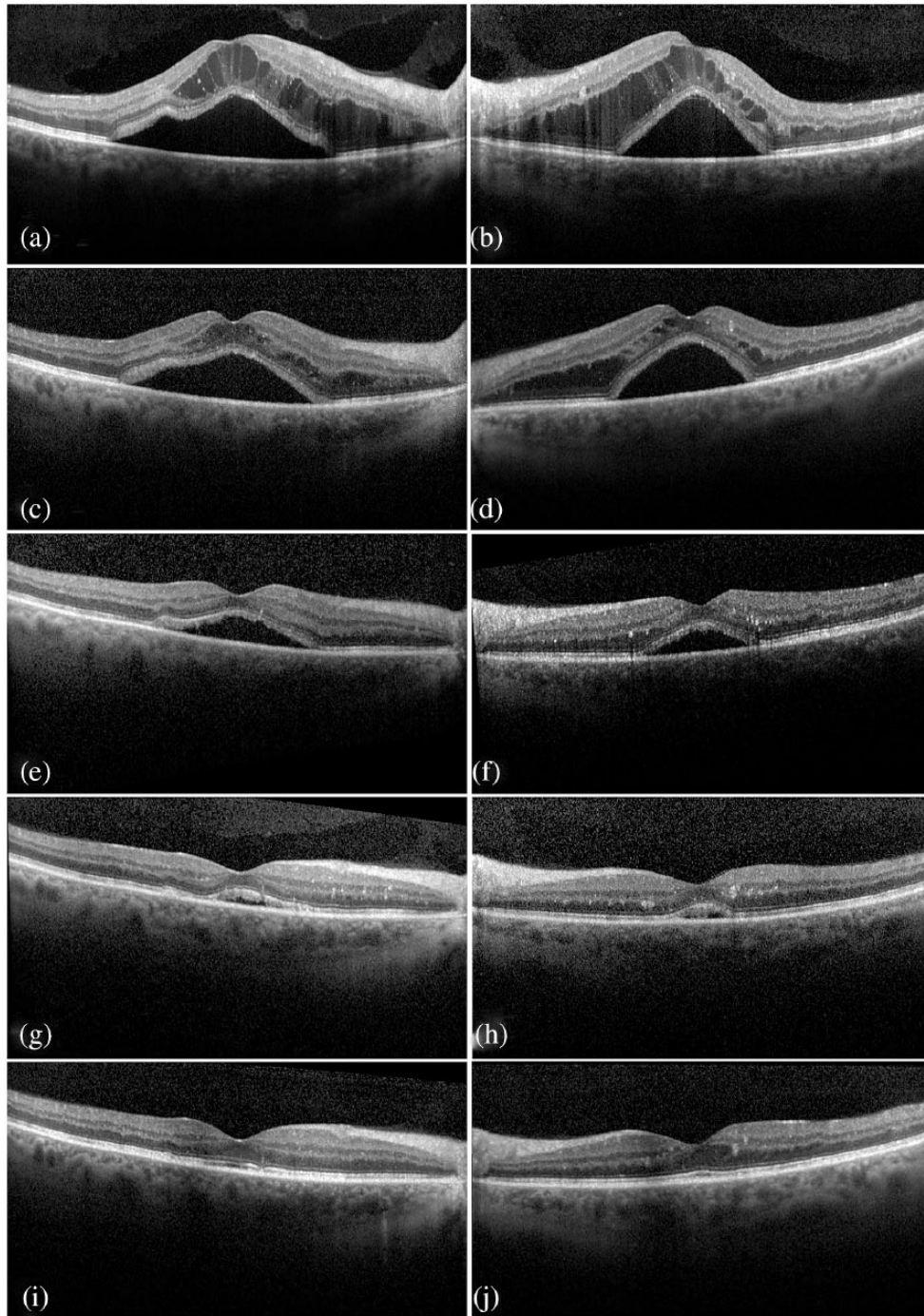
**Figure 1.** (a, b) Dilated fundus examination at presentation revealed moderate dilatation and tortuosity of the central retinal vein branches, multiple flame-shaped and dot-blot hemorrhages at the posterior pole and throughout the four quadrants of the fundus and macular edema OU. In addition, scatter cotton-wool spots and Roth's spots were observed in the mid-periphery. A few yellowish subretinal precipitates could also be observed at the posterior pole. (c, d) Eleven months after diagnosis, and 9 months after dexamethasone implant, a significant improvement in retinopathy can be observed OU with reduction in dilatation and tortuosity of the veins and reduction in the hemorrhages. Cotton-wool spots slightly subsided, while yellowish deposits could be observed in the macula OD (c).

### Case presentation

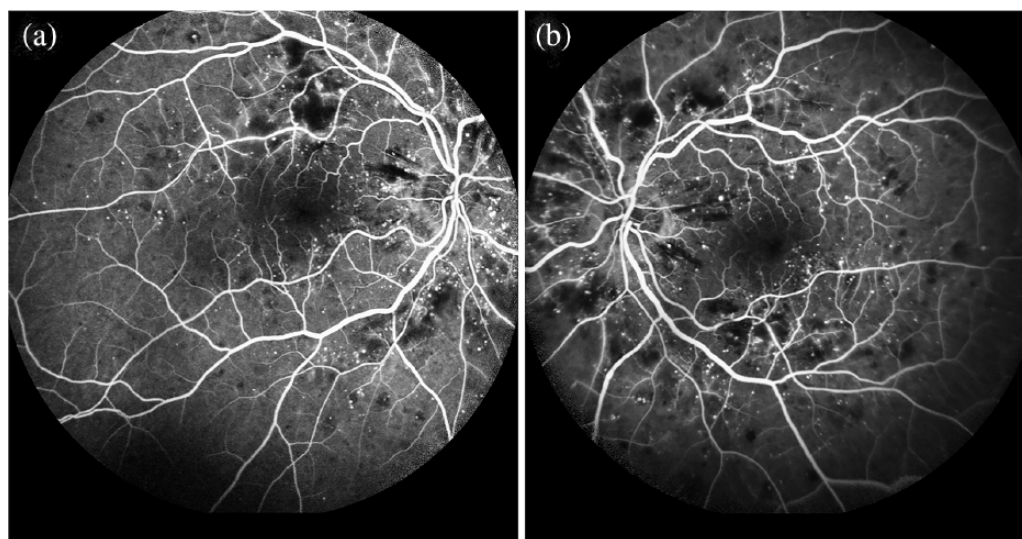
A 56-year-old Caucasian male presented at the Department of Ophthalmology, University Hospital of Patras, complaining of blurred vision for the past 10 days in both eyes. Patient's medical history included diabetes mellitus and arterial hypertension under control with medical treatment while he reported generalized weakness for the last month. His ocular history was unremarkable. Patient's best corrected visual acuity (BCVA) was 20/66 in the right eye (OD) and 20/200 in the left eye (OS), and there was no relative afferent pupillary defect. Slit-lamp examination of the anterior segment was normal. Dilated fundus examination revealed features of bilateral CRVO (Figure 1(a) and (b)). Optical coherence tomography (OCT) demonstrated severe ME with prominent SMD bilaterally (OU) (Figure 2(a) and (b)).

Hyperreflective deposits were also observed in the retina. Fluorescein angiography revealed a slightly delayed arterial and venous filling time, blocked fluorescence due to retinal hemorrhages, while no fluorescein leakage was observed at the macula OU (Figure 3(a) and (b)).

A clinical diagnosis of bilateral CRVO, which might have been attributed to the underlying hypertension, was initially made. However, the bilateral simultaneous onset and the reported recent onset of general weakness raised suspicion of a possible underlying pathology and, thus, patient underwent a comprehensive clinical and laboratory evaluation. Routine laboratory examination revealed anemia (hemoglobin = 9.4 g/dL), elevated globulins (6.5 g/dL; ref. range = 2.5–3.4 mg/L), and elevated erythrocyte sedimentation



**Figure 2.** Optical coherence tomography at presentation demonstrated severe macular edema in the right (a) and in left (b) eyes with prominent serous macular detachment. Fluid accumulation and large cysts with moderately hyperreflective material were observed at the outer retina and mainly at the outer nuclear layer. Furthermore, an amount of hyperreflective deposits were observed in the inner and outer retina, subretinally, adherent to the retinal surface, as well as at the level of retinal pigment epithelium. Two weeks later, after five rounds of plasmapheresis, serous macular detachment persisted while reduction in the intraretinal fluid was noted in both eyes (c, d). Two months after diagnosis, while the patient was under chemotherapy, the serous macular detachment, while decreased, persisted in both eyes (e, f), whereas the intraretinal cysts subsided significantly. The intraretinal hyperreflective deposits remained. One month after dexamethasone administration, a small serous macular detachment remained in both eyes (g, h) without any signs of intraretinal fluid, while the hyperreflective deposits remained. Nine months after dexamethasone administration, there were no signs of intraretinal or subretinal fluid in the macula of both eyes (i, j). The hyperreflective intraretinal deposits persisted, while a disruption in the ellipsoid zone was observed in OD (i).



**Figure 3.** (a, b) Fluorescein angiography revealed a slight delay in arterial and venous filling time, blocked fluorescence due to retinal hemorrhages, pinpoint areas of hyperfluorescence from microaneurysms, and vascular staining with mild leakage in the mid-periphery with areas of capillary non-perfusion nasal to the optic disk. No fluorescein leakage was observed at the macula in both eyes.

rate (145 mm/h). The serum IgA concentration as determined by serum protein electrophoresis was 5060 mg/dL (ref. range = 82–453 mg/dL) and the serum concentration of monoclonal free kappa light chains was 122 mg/L (ref. range = 3.3–19.4 mg/L). The other serum immunoglobulin fractions were normal. Urine electrophoresis revealed the presence of monoclonal kappa bands (2840 mg/L; ref. range = 0.39–15.1 mg/L). Bone marrow biopsy revealed IgA type kappa MM.

Patient was eventually diagnosed with HVS-related retinopathy and immunogammopathy maculopathy due to IgA MM. Treatment was initiated immediately with plasmapheresis and a systemic chemotherapy regimen that consisted of cyclophosphamide 300 mg/m<sup>2</sup>, bortezomib 1.3 mg/m<sup>2</sup>, and dexamethasone 40 mg orally on weekly basis. Two weeks later, after five rounds of plasmapheresis, serum IgA concentration levels fell to 647 mg/dL and BCVA improved to 20/50 OU. Dilated fundus examination revealed a relative improvement in retinopathy with reduction in dilatation and tortuosity of veins and reduction in retinal hemorrhages. Serous macular detachment (SMD) persisted (Figure 2(c) and (d)).

Two months after diagnosis, while the patient was under the same chemotherapy regimen, the levels of serum IgA dropped to 195 mg/dL and of free light kappa chains to 15.1 mg/L. The BCVA remained 20/50 OD but dropped to 20/67 OS. The retinopathy slightly improved while the ME

persisted OU (Figure 2(e) and (f)). At that point, patient received intravitreal implant of dexamethasone OU (Ozurdex; Allergan, Inc., Irvine, CA, USA). One month after dexamethasone administration, BCVA was 20/50 OU, while a significant improvement was observed in OCT (Figure 2(g) and (h)). MM was under control with normal levels of IgA during the next months. Nine months after dexamethasone treatment, BCVA further increased to 20/40 OD and 20/25 OS with a significant improvement in retinopathy OU (Figure 1(c) and (d)). Examination with OCT demonstrated no signs of intraretinal or subretinal fluid, while a disruption in the ellipsoid zone was observed in OD (Figure 2(i) and (j)).

### Discussion

The HVS is a rare but severe disorder. It occurs in 10%–30% of the patients with WM which is characterized by overproduction of monoclonal IgM, while it is rare in patients with MM with a reported incidence of 2%–6% of the cases.<sup>2</sup> Compared to other types of MM, patients with IgA MM are especially predisposed to develop HVS due to IgA's higher molecular weight and because of its tendency to form dimers resulting in high-molecular-weight complexes.<sup>5</sup>

Hemorheologic changes in the circulation and vascular disturbances during HVS trigger a distinctive, CRVO-resembling retinopathy characterized

by vascular dilatation and tortuosity, flame-shaped and dot-blot retinal hemorrhages, optic disk edema, capillary microaneurysms, and cotton-wool spots.<sup>3</sup> It is believed that the decreased velocity within the retinal vessels due to increased serum viscosity results in intraluminal pressure increase with compensatory arterial and arteriolar dilation and tortuosity. Moreover, the increased intraluminal pressure throughout the capillary network causes pathological changes in the junctional complexes between endothelial cells and disruption of the inner retinal barrier allowing vascular contents to leak into the adjacent tissues. This explains the occurrence of retinal hemorrhages. The extension of elevated pressure to the veins explains the observed venous dilation.<sup>6</sup> Hyperviscosity might also result in static hypoxia due to impaired transit of red blood cells, which explains the areas of non-perfusion observed in the cases of HVS-related retinopathy.<sup>7</sup>

Plasmapheresis is the immediate treatment of choice for HVS and HVS-related retinopathy since it can effectively reduce the levels of hypersecreted serum immunoglobulins and serum viscosity.<sup>2</sup> About 76% of IgM protein is distributed intravascularly and, consequently, a single plasmapheresis session can result in dramatic reduction in serum IgM levels. In contrast, over 60% of IgA is found extravascularly and multiple rounds of plasmapheresis are required to reduce IgA levels and serum viscosity.<sup>8</sup> Therefore, patients with WM tend to have better response to plasmapheresis. Menke and colleagues reported that a single plasmapheresis treatment in patients with WM resulted in reduction in serum IgM by 46.5% and in serum viscosity by 44.7%, while HVS-related retinopathy improved rapidly after plasmapheresis.<sup>6</sup> In our case, however, five sessions of plasmapheresis resulted in moderate reduction in IgA levels and in slight improvement in retinopathy. Even after systemic chemotherapy, HVS-related retinopathy did not completely subside despite the normal IgA serum levels.

Macular edema (ME) with SMD is an uncommon ocular manifestation of paraproteinemias and is described as immunogammopathy maculopathy.<sup>9</sup> This entity has rarely been reported in patients with IgA MM, while it is much more common in patients with WM.<sup>7</sup> The exact pathogenetic mechanism of immunogammopathy maculopathy is unknown, but it seems to be an HVS-independent entity. It is speculated that infiltration of the neurosensory retina and subretinal space by excess of immunoglobulins creates increased osmotic pressure gradient

toward the extracellular space, which may result in increased transudation of fluid subretinally and intraretinally. The transudation of fluid cannot be overcome by retinal pigment epithelium (RPE) pump and, therefore, ME with SMD occurs.<sup>7,9</sup> In support of this hypothesis, histopathologic reports from patients with WM or MM have documented immunoglobulins intraretinally, in the subretinal space and the RPE.<sup>7</sup> The hyperreflective precipitates that were observed in OCT images of our patient may comprise IgA aggregates. Characteristically, similar to our patient, no fluorescein leakage occurs in the macula during fluorescein angiography in cases of immunogammopathy maculopathy, indicating that the blood-retinal barriers at the macular area are intact or at least that the disruption of the blood-retinal barriers is not the primary mechanism for subretinal fluid accumulation.<sup>9</sup> However, the contribution of several growth factors, such as vascular endothelial growth factor (VEGF), or cytokines in the pathogenesis of immunogammopathy maculopathy could not be excluded.<sup>7</sup>

To date, there is no effective treatment for immunogammopathy maculopathy. Treatment guidelines are lacking since this entity is uncommon and treatment decisions are mainly based on reviews of case reports and clinical judgements.<sup>7</sup> Several treatment regimens that included plasmapheresis, systemic chemotherapy, or topical treatment with anti-VEGF such as bevacizumab, with triamcinolone, or rituximab have been tried with different outcomes.<sup>7</sup>

It is reasonable our treatment to direct at the underlying systemic disease. Therefore, early initiation of systemic chemotherapy remains the mainstay of therapy for immunogammopathy maculopathy, as well as for long-term treatment of HVS-related retinopathy.<sup>7,9</sup> Based on that, our patient was treated with systemic chemotherapy that resulted in normalization of IgA serum levels after 2 months, whereas SMD persisted OU with significant reduction in the intraretinal cysts. However, response of maculopathy to systemic chemotherapy may be slow and long-standing SMD could lead to permanent vision loss due to RPE and photoreceptor degeneration. Hence, in our case, topical treatment was decided to protect the retina, photoreceptors, and RPE from possible degeneration until chemotherapy was fully effective and to regulate any possible inflammatory factors that might contribute to immunogammopathy maculopathy pathogenesis. Since thrombotic complications are frequent in

patients with HVS, we did not treat our patient with an anti-VEGF agent and only intravitreal dexamethasone implants were administered.<sup>2</sup> As a result, resolution of ME and SMD occurred OU without complete restoration of visual function. We believe that our patient's visual acuity might have fared better, if he had received dexamethasone implant earlier in the course of the disease. In our case, disruption in the ellipsoid zone was noted in the OD which was the eye with the less functional restoration.

There is only one other report in the literature where dexamethasone implants were administered in a patient with WM and SMD who was already under treatment with systemic chemotherapy. In that case, however, no response to dexamethasone occurred without improvement in SMD or in BCVA.<sup>10</sup> The beneficial response to dexamethasone, in our case, could be explained by the additional treatment with plasmapheresis.

### Conclusion

To conclude, we presented a case where bilateral vision reduction with HVS-related retinopathy and immunogammopathy maculopathy was the only manifestation of an underlying systemic and potentially fatal disease. A high level of clinical suspicion and prompt systemic evaluation resulted in timely diagnosis of IgA MM and treatment of our patient. Concurrent treatment with plasmapheresis and systemic chemotherapy started early in the course of the disease. When no further visual and anatomic improvement was recorded, while patient was under systemic treatment for IgA MM, intravitreal implants of dexamethasone were administered. Finally, complete resolution of immunogammopathy maculopathy occurred while visual function was not completely restored.

### Author's Note

Angelos Angelakis is also affiliated to Department of Ophthalmology, University Hospital of Patras, Greece.

### Funding

The authors received no financial support for the research, authorship, and/or publication of this article.

### Conflict of interest statement

The authors declared no potential conflicts of interest with respect to the research, authorship, and/or publication of this article.

### ORCID iD

Olga E. Makri  <https://orcid.org/0000-0001-8136-1008>

### References

1. Ziaei M, Elgohary MA and Bremner FD. Bilateral central retinal vein occlusion in multiple myeloma. *Can J Ophthalmol* 2013; 48: e24–e15.
2. Kwaan HC. Hyperviscosity in plasma cell dyscrasias. *Clin Hemorheol Microcirc* 2013; 55: 75–83.
3. Orellana J and Friedman AH. Ocular manifestations of multiple myeloma, Waldenström's macroglobulinemia and benign monoclonal gammopathy. *Surv Ophthalmol* 1981; 26: 157–169.
4. Golesic EA and Sheidow TG. An otherwise healthy young man presents with bilateral CRVO as the first sign of hyperviscosity syndrome in the setting of new multiple myeloma. *Retin Cases Brief Rep* 2015; 9: 38–40.
5. Tuddenham EG, Whittaker JA, Bradley J, *et al.* Hyperviscosity syndrome in IgA multiple myeloma. *Br J Haematol* 1974; 27: 65–76.
6. Menke MN, Fekete GT, McMeel JW, *et al.* Effect of plasmapheresis on hyperviscosity-related retinopathy and retinal hemodynamics in patients with Waldenström's macroglobulinemia. *Invest Ophthalmol Vis Sci* 2008; 49: 1157–1160.
7. Mansour AM, Arevalo JF, Badal J, *et al.* Paraproteinemic maculopathy. *Ophthalmology* 2014; 121: 1925–1932.
8. Ferencik F. *Handbook of immunochemistry*. Berlin: Springer, 2012, p. 100.
9. Ho AC, Benson WE and Wong J. Unusual immunogammopathy maculopathy. *Ophthalmology* 2000; 107: 1099–1103.
10. Fenicia V, Balestrieri M, Perdicchi A, *et al.* Intravitreal injection of dexamethasone implant in serous macular detachment associated with Waldenström's disease. *Case Rep Ophthalmol* 2013; 4: 64–69.