



## Case report

## Jejunal lymphangioma causing intussusception in an adult: An unusual case with review of the literature

Hannah Samuelson<sup>a,\*</sup>, Dr Giovanni Giannotti<sup>b</sup>, Dr Amy Guralnick<sup>c</sup><sup>a</sup> Chicago Medical School at Rosalind Franklin University, USA<sup>b</sup> Saint Mary and Elizabeth Medical Center, USA<sup>c</sup> University of Chicago, USA

## ARTICLE INFO

## Keywords:

Lymphangioma  
Case report  
Intussusception  
Cystogenesis  
Polycystic

## ABSTRACT

**Introduction:** Adult intussusception is rare, and 90% are due to a lead point secondary to a pathologic condition. Lymphangioma is an uncommon tumor of the lymphatic system and is rarely found within the small bowel. Small bowel lymphangioma causing intussusception in an adult is a rare occurrence, with three very distinct rare pathologies occurring simultaneously

**Case description:** A 70-year-old male patient with multiple pre-existing pathologies such as advanced ADPKD, multiple persistent tubulovillous colon polyps and colon cancer in situ, was hospitalized due to rapid weight loss of 20 lbs, hematemesis, and abdominal pain. He was subsequently found to have jejunal intussusception caused by two lymphangiomas of the small bowel. The portion of intussuscepted jejunum was resected and final diagnosis on pathology was two jejunal lymphangiomas.

**Discussion:** Lymphangiomas of the small bowel are rare, but increasing in incidence due to the accessibility of endoscopic evaluations. A hypothetical connection between lymphangioma and ADPKD is unknown, but both diseases are built on a foundation of cystogenesis. There is little known about the effect ADPKD on cystogenesis and tumor formation extra-renally, and there is a possible correlation between genetic mutations in polycystin and cystic tumors such as lymphangiomas.

**Conclusion:** Lymphangioma, although rare in the small bowel, is a possible cause of intussusception and should be considered on the differential of abdominal pain in adults. The pathogenesis of polycystic kidney disease has implications that could predispose to cystic development beyond the kidney, and more research into the genetic mechanism behind the disease is necessary to support or deny this claim.

## 1. Introduction

Intussusception is a rare pathology in adults and 90% is secondary to a GI pathology. This GI pathology is typically adhesions or underlying carcinoma, which provide a lead point for the telescoping of bowel segments [1,7]. Lymphangioma is an uncommon tumor of the lymphatic system and is rarely found within the small bowel. Small bowel lymphangioma causing intussusception in an adult is a rare occurrence, with three very distinct rare pathologies occurring simultaneously

Lymphangiomas are benign tumors comprised of congenitally dilated lymphatic channels and occur most often in the axilla, head and neck [1–3]. Lymphangioma of the GI tract comprises only 1% of lymphangioma diagnoses, but with increased utilization of endoscopic procedures the incidental discovery of these tumors in GI tract is

increasing, leading us to believe they are more common than previously reported [2,4].

It is important to distinguish lymphangioma from lymphangiectasia. Lymphangiomas are congenital dilated spaces that have a covering of endothelium smooth muscle, whereas lymphangiectasia is dilation due to lymphatic obstruction of changes in flow with only a thin incomplete endothelial covering [2].

This case report is reported in line with the SCARE criteria, as outlined in the 2016 article by Agha et al.

## 2. Case presentation

70 year old male with past medical history significant for ADPKD, repeat high grade dysplasia and tubulovillous polyps of the colon, CHF post AICD placement, valvular cardiomyopathy, iron deficiency

\* Corresponding author.

E-mail address: [hannah.samuelson@my.rfums.org](mailto:hannah.samuelson@my.rfums.org) (H. Samuelson).<https://doi.org/10.1016/j.amsu.2018.08.020>

Received 7 August 2018; Received in revised form 17 August 2018; Accepted 25 August 2018

2049-0801/ © 2018 The Author(s). Published by Elsevier Ltd on behalf of IJS Publishing Group Ltd. This is an open access article under the CC BY-NC-ND license (<http://creativecommons.org/licenses/by-nc-nd/4.0/>).

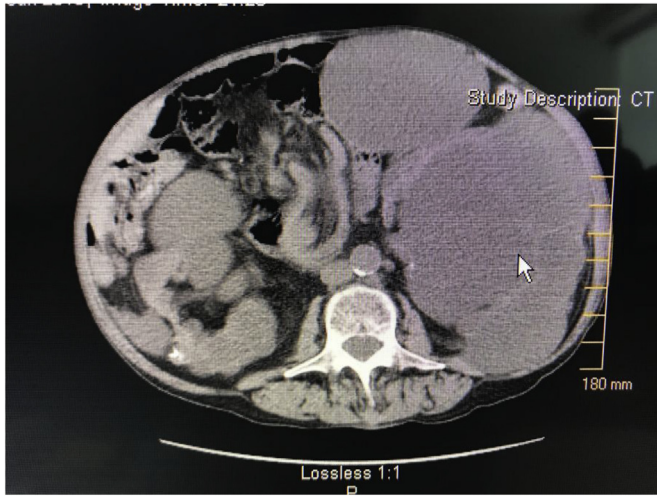


Fig. 1. Transverse visualization of the intussusception of the jejunum and the enlarged polycystic kidneys.

anemia, chronic atrial fibrillation, Gastroesophageal reflux disease (GERD), Peptic ulcer disease (PUD) and Hypertension (HTN) presented to the emergency room with several days of colicky, aching epigastric pain, nausea and cyclic vomiting with hematemesis and a 20 pound weight loss. His medications were apixaban, lanoxin, prednisone, Toprol, lisinopril, esomeprazole and atorvastatin. He had an allergy to iron. There was no family history of kidney disease, or cancers of any kind. He had a history of alcohol abuse, which ended at age 50, and a long former smoking history. The patient denied recent melena or hematochezia. The patient was distressed by his abdominal pain and inability to eat due to nausea, and emesis.

On admission he was cachectic and had tenderness to palpation without signs of acute abdomen. The Computer Tomography (CT) scan on the day of admission was significant for large polycystic kidneys and moderate ascites (Fig. 1). Esophagogastroduodenoscopy (EGD) performed next day showed stomach mucosa oozing heme, distorted, large friable rugae and congestion with ulceration across the entire stomach mucosa. Several biopsies revealed intestinal metaplasia but no evidence of malignancy. Three days later a second EGD with deeper biopsy into the muscularis revealed an infiltrating gastric adenocarcinoma. Carcinoembryonic antigen (CEA) was found to 534. Upon re-review of the CT scan, intussusception was discovered (Figs. 1–4) including a “target

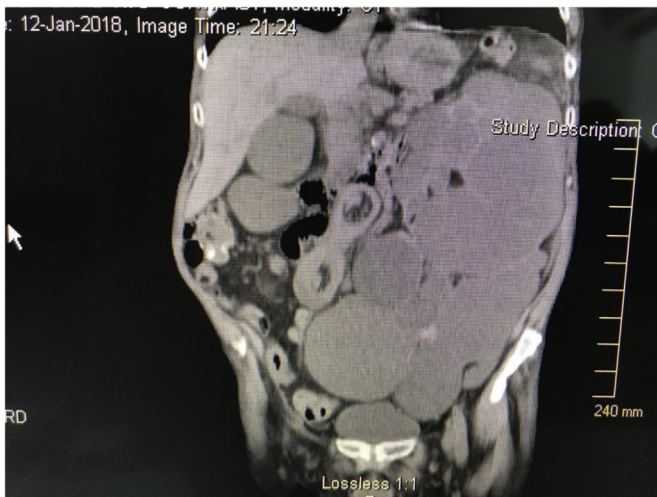


Fig. 2. Coronal visualization of the intussusception of the jejunum, with target sign, potentially the lymphangioma(s) of the small bowel and the enlarged polycystic kidney.

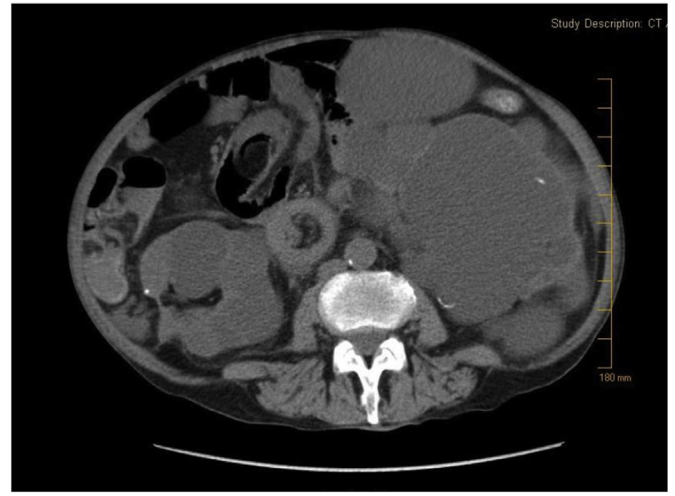


Fig. 3. Target sign demonstrating intussusception of the jejunum and potential visualization of one of the lymphangiomas.

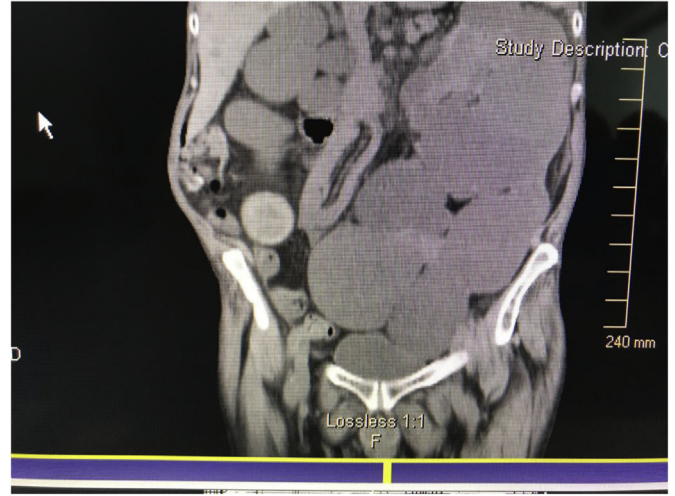


Fig. 4. Sagittal visual of the telescoping intussusception of the jejunum.

sign” (Figs. 2 and 3) proving telescoping of the jejunum with a 2.5 cm large lead point of unknown pathology was reported. The re-reviewed CT additionally showed diffuse thickening of the stomach mucosa in both curvatures and enlarged perigastric lymph nodes.

Dr. Giannotti took him to surgery and the segment of small bowel was removed and a Jejunostomy-tube was placed. Intra-operatively an erythematous and indurated portion of bowel determined to be the lead point was removed. Surgical pathology revealed a single mass comprised of two lymphangiomas. There were additional masses along the surface of the peritoneum which were sampled and determined to be metastatic peritoneal carcinomatosis showing signet rings caused by metastatic adenocarcinoma of the stomach. Sampling of the stomach tissue and perigastric lymph nodes were positive for malignancy. The patient was determined to be too high risk for extensive surgical debulking. Postoperatively he was supported via enteral feedings, and considered for chemotherapy, radiation, and possible surgery if medically stable at later visits. The patient agreed to stabilize before pursuing further treatment. A few months later the patient died of complications due to the multiple cancers and he had remained too cachectic to pursue curative intervention.

### 3. Discussion

Intussusception is classified by its location along the gastrointestinal

tract. Our report involved only the jejunum and therefore is classified as entero-enteric [5,6]. The most common cause of this entero-enteric type of intussusception is postoperative adhesions, while malignancy is more often associated with colonic intussusception [1,7]. Lymphangioma is a rare cause of intussusception, and even less common in adults.

Lymphangiomas are classified into 3 types, microcystic, macrocystic, and mixed according to the size of their cysts [7]. It is possible to hypothesize a connection between ADPKD and lymphangiomas, because they are both primarily cystic pathologies rooted in genetic and congenital processes [8]. There has been little studied about the relationship between the two, and the documentation of lymphangiomas outside of the head and neck has been uncommon until recently. The diagnosis of lymphangiomas has been increasing recently due to availability of endoscopic evaluations. Historically, lymphangiomas of the GI tract were discovered on surgical pathology, rather than imaging or procedural evaluation. The number of lymphangiomas of the gastrointestinal tract although seemingly rare, could be higher than we realize simply due to lack of complications occurring with them.

Our patient provides an example in which multiple cystic pathologies occurred together. This provides the potential for these pathologies to be considered together, and further implications for ADPKD and its impact on extra-renal cytogenesis. The simultaneous existence of all of this patient's pathologies could have clinical and medical significance for the effect of ADPKD on cyst and tumor formation. The extra-renal manifestations of ADPKD are relatively well known but its influence of the development of other solid tumors is poorly understood. Although there has been evidence that ADPKD predisposes to renal cancer, there is new evidence that it could predispose to other types of cancer, specifically along the GI tract or in the liver [9–12]. Gene mutations could predispose individuals to tumor formation, through signaling pathway disruptions, specifically suppression of the apoptotic pathway [3,11,13,14]. The signaling derangements, specifically signaling inhibitors, found in ADPKD and solid tumors are strikingly similar [15]. The dominant gene mutation in ADPKD is PKD1 which codes for polycystin-1. Zheng et al., in 2016 found an association between overexpression of polycystin-1 and potential tumor suppressor through apoptosis of cancer cells. This introduced the idea that with a mutated form of this gene, a person is may be more susceptible to tumor development. Conversely, Thivierge et al., 2006 found that either overexpression or ablation of polycystin resulted in rapid cystogenesis, showing the mutation found in ADPKD could present with either [16]. This raises the question whether polycystin and its relation with ADPKD could increase the potential for even further development of cysts and tumors outside of the renal system. If this evidence is true, our patient demonstrates a case of widespread tumor and cyst formation, such as lymphangiomas and his multiple GI cancers, which could be explained by his advanced ADPKD.

#### 4. Conclusion

This case demonstrates that although rare in adults, intussusception should be considered on the differential diagnosis for adult patients who present with colicky abdominal pain. Lymphangioma, although rare in the small bowel, can act as a possible lead point and should be considered through imaging and thorough evaluation. The pathogenesis of polycystic kidney disease has implications that could predispose to cystic and tumor development beyond the kidney, and more research into the mechanism behind the disease is necessary to support or deny this claim.

#### Ethical approval

The patient gave approval at the time of the case incidence, as a part of the operation consent form.

#### Sources of funding

None.

#### Author contribution

**Hannah Samuelson, BA, Chicago Medical School at Rosalind Franklin University class of 2019:** Author, study concept and design, data collection, data analysis and interpretations, writing the paper.

**Giovanni Giannotti M.D. Saint Mary and Elizabeth Medical Center:** Study concept and design, data collection, editing the paper.

**Amy Guralnick M.D. University of Chicago:** Data interpretations, editing the paper.

#### Conflicts of interest

None.

#### Research registration number

Case report, no human participant research.

#### Guarantor

Hannah Samuelson BA.  
Giovanni Giannotti MD.

#### Consent

Written informed consent was obtained from the patient for publication of this case report and accompanying images. A copy of the written consent is available for review by the Editor-in-Chief of this journal on request [17].

#### Provenance and peer review

Not commissioned, externally peer-reviewed.

#### Appendix A. Supplementary data

Supplementary data related to this article can be found at <https://doi.org/10.1016/j.amsu.2018.08.020>

#### References

- [1] Limaem, et al., Jejunum lymphangioma: an unusual cause of intussusception in an adult patient, *Pathologica* 107 (1) (2015 Mar) 19–21.
- [2] Suzanne Iwaz, et al., Jejunum lymphangioma and recurrent intussusception in an adult patient; a case report and review of literature, *Hum. Pathol.: Case Rep.* 12 (2018) 22–23, <https://doi.org/10.1016/j.ehpc.2017.12.003>.
- [3] Atsushi Kohga, et al., Ileo-Ileal intussusception caused by lymphangioma of the small bowel treated by single-Incision laparoscopic-Assisted ileal resection, *World J. Gastroenterol.* 23 (1) (2017) 167, <https://doi.org/10.3748/wjg.v23.i1.167>.
- [4] M.E. Lawless, et al., Lymphangiomas lesions of the gastrointestinal tract: a clinicopathologic study and comparison between adults and children, *Am. J. Clin. Pathol.* 144 (4) (2015) 563–569, <https://doi.org/10.1309/ajcp08tw6emajsrp>.
- [5] D.M. Nagorney, M.G. Sarr, D.C. McIlrath, Surgical management of intussusception in the adult, *Ann. Surg.* 193 (1981) 230–236.
- [6] J. Potts, et al., Small bowel intussusception in adults, *Ann. R. Coll. Surg. Engl.* 96 (1) (2014) 11–14, <https://doi.org/10.1308/003588414x13824511650579>.
- [7] D.L. Grasso, et al., Lymphangiomas of the head and neck in children, *Acta Otorhinolaryngol. Ital.* 28 (1) (2008) 17–20 Print.
- [8] A. Boletta, F. Qian, L.F. Onuchic, et al., The molecular basis of focal cyst formation in human autosomal dominant induces resistance to apoptosis and spontaneous tubulogenesis in MDCK cells, *Mol. Cell* 6 (2000) 1267–1273.
- [9] Anne Bretagnol, et al., Autosomal dominant polycystic kidney disease: risk factor for nonmelanoma skin cancer following kidney transplantation, *Transpl. Int.* (2010), <https://doi.org/10.1111/j.1432-2277.2010.01070.x>.
- [10] P. Harris, M. Watson, Autosomal dominant polycystic kidney disease: neoplasia in disguise? *Nephrol. Dial. Transplant.* 12 (6) (1997) 1089–1090, <https://doi.org/10.1093/ndt/12.6.1089>.
- [11] Tamina Seeger-Nukpezah, et al., The hallmarks of cancer: relevance to the

- pathogenesis of polycystic kidney disease, *Nat. Rev. Nephrol.* 11 (9) (2015) 515–534, <https://doi.org/10.1038/nrneph.2015.46>.
- [12] Tung-Min Yu, et al., Risk of cancer in patients with polycystic kidney disease: a propensity-Score matched analysis of a nationwide, population-Based cohort study, *Lancet Oncol.* 17 (10) (2016) 1419–1425, [https://doi.org/10.1016/s1470-2045\(16\)30250-9](https://doi.org/10.1016/s1470-2045(16)30250-9).
- [13] M.A. Arnaout, Molecular genetics and pathogenesis of autosomal dominant polycystic kidney disease, *Annu. Rev. Med.* 52 (2001) 93–123.
- [14] Rong Zheng, et al., Polycystin-1 induced apoptosis and cell cycle arrest in G0/G1 phase in cancer cells, *Cell Biol. Int.* 32 (4) (2008) 427–435, <https://doi.org/10.1016/j.cellbi.2007.12.014>.
- [15] R.L. Luciano, N.K. Dahl, Extra-Renal manifestations of autosomal dominant polycystic kidney disease (ADPKD): considerations for routine screening and management, *Nephrol. Dial. Transplant.* 29 (2) (Aug. 2013) 247–254, <https://doi.org/10.1093/ndt/gft437>.
- [16] C. Thivierge, A. Kurbegovic, M. Couillard, et al., Overexpression of PKD1 causes polycystic kidney disease, *Mol. Cell Biol.* 26 (2006) 1538–1548.
- [17] R.A. Agha, A.J. Fowler, A. Saetta, I. Barai, S. Rajmohan, D.P. Orgill for the SCARE Group, The SCARE Statement: consensus-based surgical case report guidelines, *Int. J. Surg.* 34 (2016) 180–186.