

CASE REPORT



Aesthetic correction of lesion by post-liposuction corticoid infiltration using subcision, PMMA filling, and CO₂ laser

Roberto Chacur, Honório Sampaio Menezes, Nívea Maria Bordin da Silva Chacur, Danuza Dias Alves, Rodrigo Cadore Mafaldo, Leandro Dias Gomes, Gina Matzenbacher and Gisele dos Santos Barreto

Leger Clinic, Rio de Janeiro, Brazil

ABSTRACT

Introduction: Post-liposuction fibrosis is a relatively common complication which can be repaired. **Case report:** We report a case of cutaneous atrophy and diffuse irregularity of the abdominal region with achromia post-liposuction. She was treated with subcision, PMMA filler and fractioned CO₂ laser. **Results:** Cutaneous colour and irregularities get improved.

ARTICLE HISTORY

Received 3 December 2018
Accepted 30 March 2019

KEYWORDS

Lipectomy; pigmentation; polymethyl methacrylate; lasers; gas; injectable corticosteroids

Introduction

The liposuction technique has evolved considerably in many countries, being one of the most popular aesthetic procedures for sculpting the human body [1–3]. It promotes the removal of subcutaneous fat, thus, correcting body lipodystrophies. For faster recovery time, shorter hospital stays, and less complicated post-operative periods, while considering smaller areas, local anaesthesia is indicated. For larger areas, the Klein's tumescent technique or epidural analgesia, with or without sedation, are suggested [4]. Some local postoperative complications may occur, such as seromas, haematomas, skin irregularities (visible and palpable), fibrosis, necrosis, and scarring. Systemic complications, such as visceral perforations, allergic reactions to intra- and postoperative medications, fever, systemic infections, fatty embolism, sepsis, and death may also occur [4].



Human skin after a tissue injury may respond with the formation of fibrosis [5], which is the main sequelae related to the scarring process in the postoperative period. Collagen is a protein found abundantly in the human body. Its development in excess or its accumulation during tissue repair generates fibrosis [5,6]. Injectable corticosteroids, which is used to inhibit the production of collagen, acts as an inhibitor of alpha-2

macroglobulin. This inhibits the action of collagenase type V, which promotes a decrease in the action of fibroblasts. Such inhibition controls the fibrotic scar process, being also used to control gynoid lipodystrophy. The use of injectable corticosteroids has been an option for the treatment of fibrosis. Nevertheless, the physician carrying out the treatment should be aware of the possible side effects related to different prescribed forms and doses [7]. Some complications are due to intralesional injection, such as the development of telangiectasias, cutaneous atrophy, and hypo- or hyperpigmentation of the skin [8].

We present a case report with corrective treatment for severe cutaneous atrophy caused by injectable triamcinolone used to improve post-liposuction fibrosis.

Case report

A 40-year-old woman, from San Paulo, presented with severe cutaneous atrophy, achromia and irregular skin texture due to the attempt to correct abdominal post-liposuction fibrosis by using corticosteroid infiltration. Two years before, the patient had undergone an abdominal liposuction procedure, followed by local application of triamcinolone, in an attempt to correct permanent fibrosis resulting from the liposuction. Injecting triamcinolone (unknown dose), aggravated

CONTACT Roberto Chacur  nucleodespesquisa@clinicaleger.com.br  Avenida das Américas, 3301 – Bloco 4 – Sala 301 – Barra da Tijuca, Leger Clinic, Rio de Janeiro, 22640102, Brazil

© 2019 The Author(s). Published by Informa UK Limited, trading as Taylor & Francis Group.

This is an Open Access article distributed under the terms of the Creative Commons Attribution License (<http://creativecommons.org/licenses/by/4.0/>), which permits unrestricted use, distribution, and reproduction in any medium, provided the original work is properly cited.

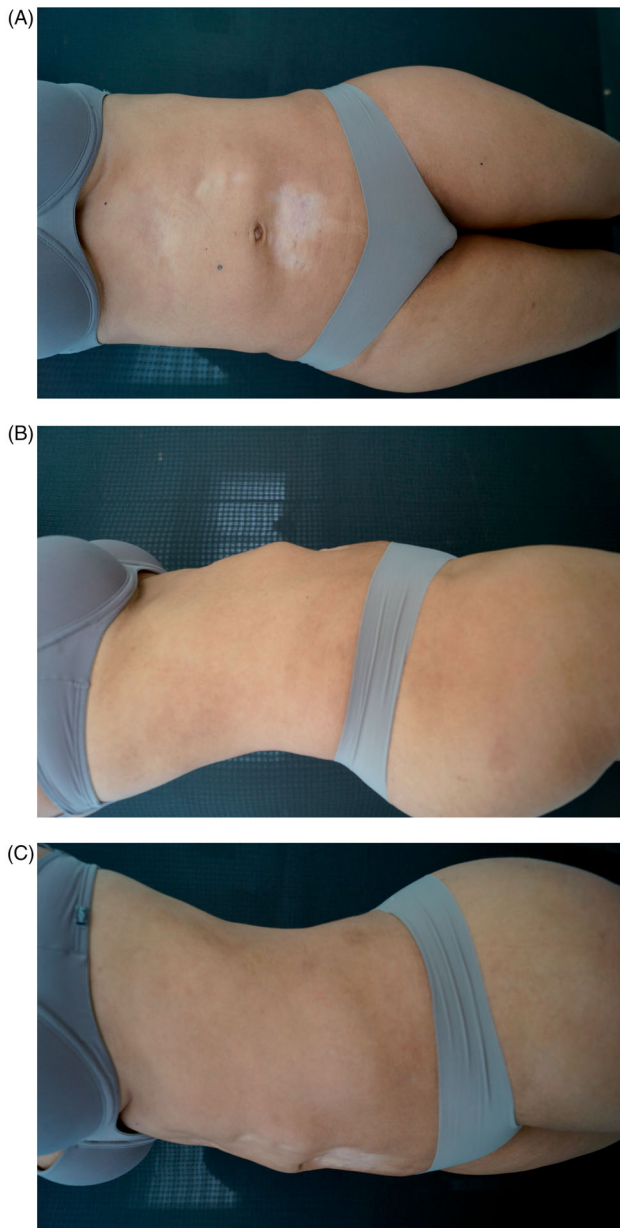


Figure 1. (A,B,C) Before treatment.

the cutaneous atrophy, abdominal irregularity, and achromia conditions (Figure 1).

This case report was approved by the Research Ethics Committee of the Universidade Veiga de Almeida (UVA/RJ) (CAAE protocol number 97197618.4.0000.5291).

There is no conflict of interest.

Subcision treatment was carried out in a single session. During this session, 26 ml of polymethyl methacrylate 10% were implanted with a micro-canula (Figure 2(A,B)). A CO₂ laser with radiofrequency coupled was applied soon after filling (Figures 3 and 4).

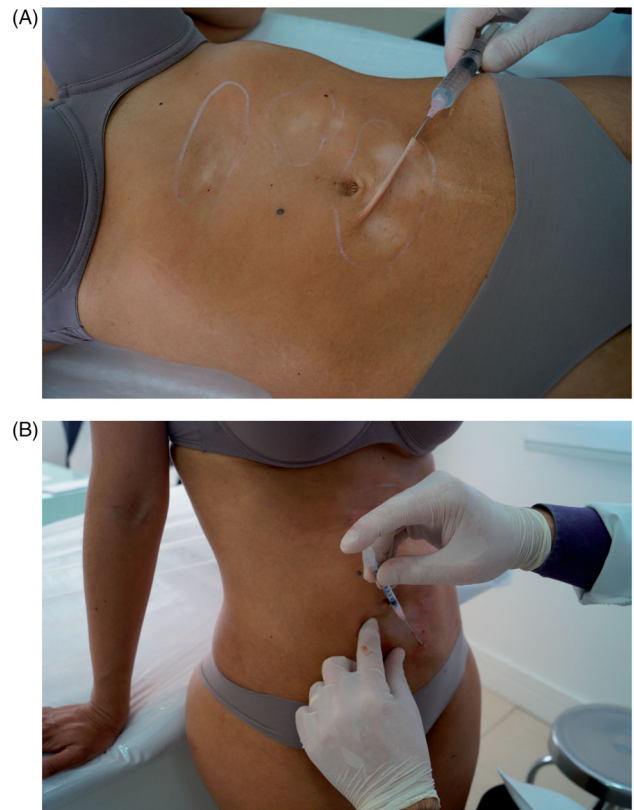


Figure 2. (A-B) Treatment fill with synthetic implant.

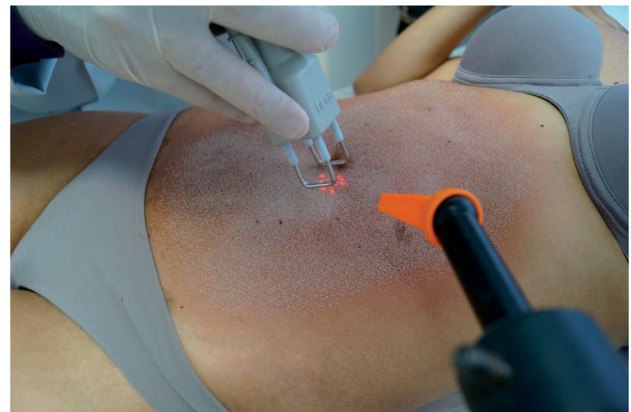

Figure 3. Treatment with fractional CO₂ laser.

Results

One month later we noted improvement of skin appearance (Figure 5). Four years follow-up demonstrated very satisfactory results (Figure 6).

Discussion

In this case, the treatment of fibrosis and its adhesions, tissue atrophy, and colour homogenisation had the objective of correcting the aesthetic damage, correction which was sought with the treatments applied

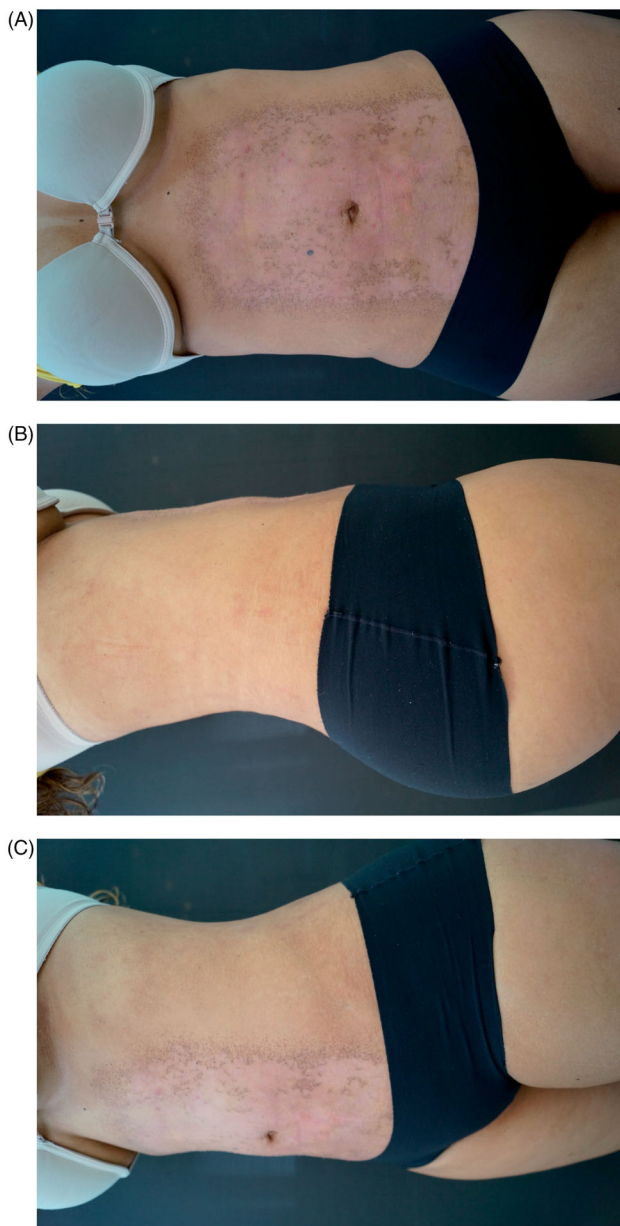


Figure 4. (A,B,C) During treatment.

to the patient. The use of injectable intralesional corticosteroids may cause some deformities in the skin [8], as presented in this case.

Injectable corticosteroid, used to inhibit the production of collagen, is known to act by inhibiting alpha-2 macroglobulin. This inhibits the action of collagenase type V, which promotes a decrease in the action of fibroblasts, thus, controlling the scar process [8].

Subcision was used to correct the skin relief by means of a Y-shaped instrument, sliding it back and forth in a fanlike movement, thus dissecting the fibrotic tissue until the skin is released [9].

Subsequently, tissues were filled with PMMA, a product which is non-absorbable by the human body.

Its microspheres are phagocytosed by macrophages, the vehicle being degraded slowly and replaced by new collagen produced from the inflammatory process, stimulating the formation of 80% of connective tissue, which will remain in place as long as the particles are present [10]. Neocollagenesis, which results from the stimulation of the fibroblast caused by the inflammatory process using PMMA (in this case beneficial), has an exact reverse action of the injectable corticosteroid. Thus, it allows the correction of the tissue atrophy in a relatively easy way, with a procedure that can be performed in the doctor's office, using local anaesthesia, and presenting permanent effect. When applied superficially these products need to be more diluted or well distributed to prevent the formation of nodules or irregularities. PMMA, when the abdomen is considered, is indicated for treatments of depressed scars, of stretch marks when there is excessive depression, and of correction and depression in the abdominal fat layer after liposuction [11].

The fat grafting procedure option was not given due the fact that should be performed in a surgical block, under anaesthesia. A lack of predictable volume retention is clearly a characteristic of autologous fat grafting which would only temporarily increase the volume, would not stimulate the production of new collagen and would not lead to the same desired result as with pmma filling [12].

Subcutaneous filling with PMMA is also widely used in patients with HIV/AIDS associated Lipodystrophy Syndrome [13,14] as well as in Romberg hemifacial atrophy, reconstructing lost angles and contours due to volume reduction by fat reabsorption (lipoatrophy). PMMA was the best choice for the case because it is a non-toxic material, which does not induce hypersensitivity or foreign body reactions, which does not degenerate over time or induce calcification, because it is chemically inert and easily implantable. In addition to the cost of the treatment being accessible to the patient.

For the correction or improvement of dermal and subdermal skin irregularities, it is possible to use radiofrequency, which was, indeed, carried out with the patient, since the CO₂ laser device had a radiofrequency head attached to it. According to Atiyeh and Dibo, improvement in the irregularities of deep dermis can be observed after the use of radiofrequency. The thermal effects of radiofrequency promote the denaturation of collagen, with immediate contraction of its fibres and subsequent activation of the fibroblasts with neocollagenesis of the collagen fibres over

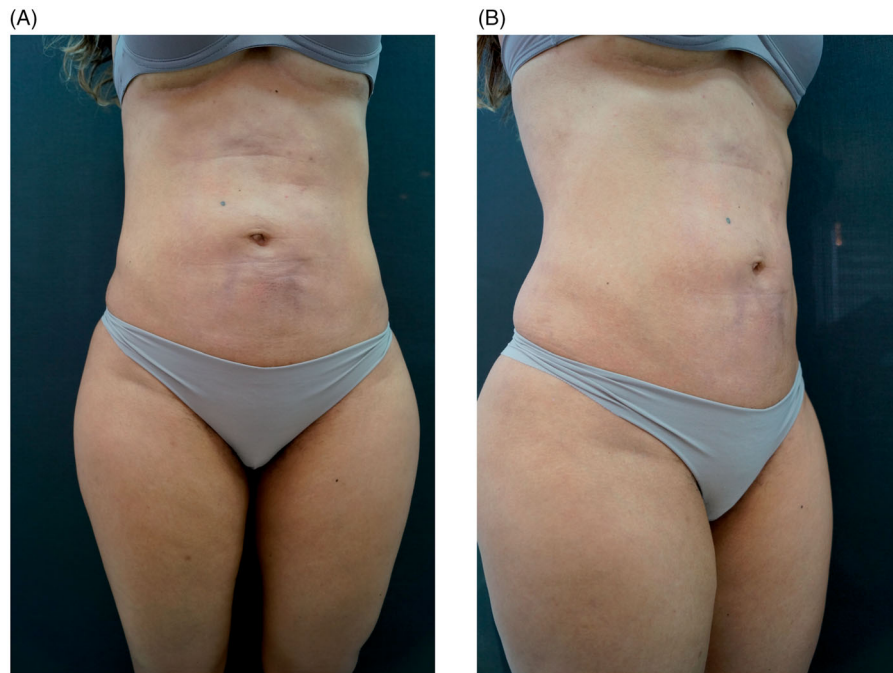


Figure 5. (A,B) One month after treatment.

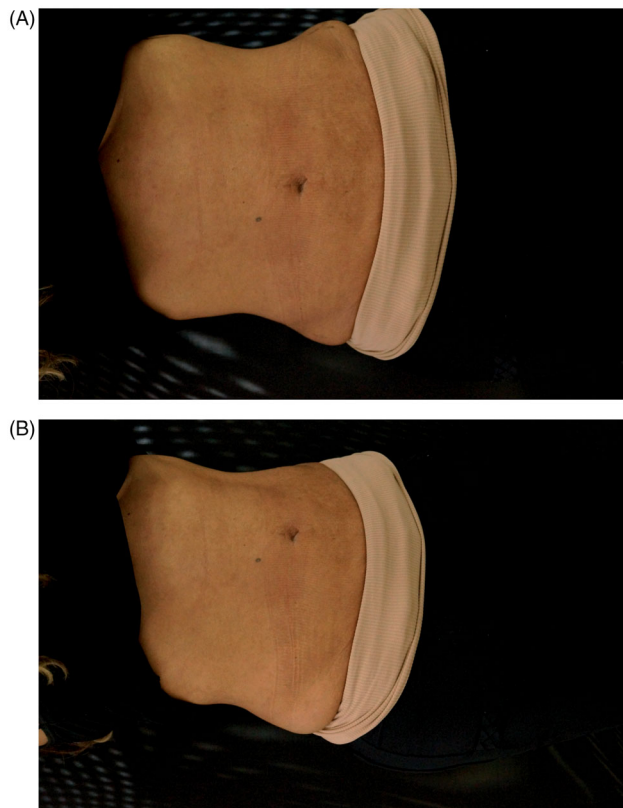


Figure 6. (A,B) 4-years follow-up treatment.

time, due to a secondary healing response and subsequent remodelling of the cutaneous tissue [15,16].

The CO₂ laser is a major advance on existing conventional methods to ablate the epidermis, thereby

inducing regrowth of a young-looking epidermis and stimulating collagenesis and remodelling in the dermis, which stimulate its healing response. Fractional lasers create microscopic heat columns causing areas of thermal damage known as microscopic thermal zones. The denaturation of the collagen takes place due to the heat emitted by the laser, causing the fibres to shrink quickly, and hardening the skin [17]. The collagenase levels rise and the healing of the lesion that degrades the collagen matrix begins [18]. Therefore, the CO₂ laser from adjacent cells reconstitutes both the dermis and the epidermis [19].

The treatment proposed in this work aimed to correct the cicatricial adhesions and to repigment the skin. A significant improvement was observed using four techniques together. The subdermal PMMA filling, which was used to stimulate the production of collagen (inhibited by the corticosteroid), to restore the volume, and to correct the irregularities of the skin, presented good results, just as the Radiofrequency correction of subdermal skin irregularities and fractionated CO₂ laser epidermic repigmentation.

Conclusion

The association of subcision, filling with polymethyl methacrylate, and CO₂ laser with radiofrequency produced satisfactory treatment of skin deformity after corticosteroid administration in abdominal liposuction surgery.

Disclosure statement

No potential conflict of interest relevant to this article was reported.

Patient consent

The patient provided written informed consent for the publication and the use of his images.

References

- [1] Pereira LH, Sterodimas A. Correction for the iatrogenic form of banana fold and sensuous triangle deformity. *Aesth Plast Surg*. 2008;32:923.
- [2] Triana L, Triana C, Barbato C, et al. Liposuction: 25 years of experience in 26,259 patients using different devices. *Aesthet Surg J*. 2009;29:509
- [3] Stephan PJ, Kenkel JM. Updates and advances in liposuction. *Aesthet Surg J*. 2010;30:83
- [4] Gomes RS. Critérios de Segurança em Lipoaspiração. *Arq Catarin Med Surg*. 2003;32:3546.
- [5] Low J, Reed A. Eletroterapia explicada: princípios e prática. São Paulo (Brazil): Manole, 2001. p.1723.
- [6] Lisboa FLF, et al. Um protocolo para avaliação fisioterapêutica dos níveis de fibrose cicatricial em pós-operatório de lipoaspiração associada ou não à abdominoplastia. *Surg*. 2003;19:1118.
- [7] Salvatore T, Sasso FC. Cushing syndrome and giant sterile abscess induced by self intramuscular injection of suprathapeutic doses of triamcinolone. *Drug Metab Lett*. 2013;7:65–67.
- [8] Saha AK, Mukhopadhyay M. A comparative clinical study on role of 5 fluorouracil versus triamcinolone in the treatment of keloids. *Indian J Surg*. 2012;74:326.
- [9] Inchingolo F, Tatullo M, Abenavoli FM, et al. Surgical treatment of depressed scar: a simple technique. *Int J Med Sci*. 2011;8:377–379.
- [10] Chacur R. *Ciência e arte do preenchimento/Roberto Chacur*. 1st ed. Porto Alegre (Brazil):AGE;2018.262 p.
- [11] Chacur R, Menezes HS, Chacur NMSB, et al. Replacement of gluteal implants by polymethyl methacrylate filler: case report. *Case Reports Plast Surg Hand Surgery*. 2019;1:1–5.
- [12] Landau MJ, Birnbaum ZE, Kurtz LG, et al. Review: proposed methods to improve the survival of adipose tissue in autologous fat grafting. *Plast Reconstr Surg Glob Open*. 2018;6:e1870.
- [13] Soares FMG, Costa I. HIV-Associated facial lipoatrophy treatment: the impact on the infection progression assessed by viral load and CD4 counting. *An Bras Dermatol*. 2013;88:570–577.
- [14] Soares FMG, Costa I. Lipoatrofia facial associada ao HIV/AIDS: do advento aos conhecimentos atuais. *An Bras Dermatol*. 2011;86:843–864.
- [15] Atiyeh BS, Dibo SA. Nonsurgical nonablative treatment of aging skin: radiofrequency technologies between aggressive marketing and evidence-based efficacy. *Aesth Plast Surg*. 2009;33:283–294.
- [16] Elsaie ML, Choudhary S, Leiva A, et al. Nonablative radiofrequency for skin rejuvenation. *Dermatol Surg*. 2010;36:577–589.
- [17] Omi T, Numano K. The role of the CO₂ laser and fractional CO₂ laser in dermatology. *Laser Ther*. 2014;23:49–60.
- [18] Helbig D, Paasch U. Molecular changes during skin aging and wound healing after fractional ablative photothermolysis. *Skin Res Technol*. 2011;17:119–128.
- [19] Hantash BM, Bedi VP, Kapadia B, et al. In vivo histological evaluation of a novel ablative fractional resurfacing device. *Lasers Surg Med*. 2007;39:96–107.