

Clinical and Radiological Outcomes of Day-care Posterior Foraminotomy and Decompression of the Cervical Spine

Abstract

Purpose: Anterior cervical procedures are associated with many intra- and post-operative complications leading to long-term patient morbidity. In this study, we have evaluated the clinical and radiological Outcome of day care posterior cervical foraminotomy in patients with single-level cervical radiculopathy with or without neurodeficit. **Materials and Methods:** Seventeen patients underwent single-level posterior cervical foraminotomy for radicular symptoms were studied between June 2011 and May 2016. Clinical outcome was studied by visual analog scale (VAS) score, neck disability index (NDI), and Odom's criteria. Adjacent segment degeneration was evaluated on lateral cervical radiograph at every follow-up by calculating the focal and global angulation of the cervical spine and disc height at the operated level and adjacent segments. Dynamic lateral cervical spine radiograph was done to evaluate segmental instability. **Results:** After a mean follow-up duration of 30.64 months, 13 patients had excellent, three patients had good, and one patient had fair outcome as per Odom's criteria. The mean VAS score for radicular pain, neck pain, and NDI was significantly reduced postoperatively ($P < 0.001$). The mean focal angulation, mean global angulation, the disc height at operated and adjacent level were not changed significantly ($P > 0.05$). There was no instability noted postoperatively on lateral dynamic cervical spine radiographs. There was no complication in our study. **Conclusion:** Posterior cervical foraminotomy is an effective surgical method for treatment of patients with single-level cervical radiculopathy and helps to achieve good clinical and radiological outcome, prevents postoperative adjacent segment degeneration and instability with minimal complications.

Keywords: *Adjacent segment degeneration, cervical radiculopathy, day care, posterior cervical foraminotomy*

Manoj Dayalal Singrakhia,
Nikhil Ramdas Malewar,
Sonal Deshmukh¹,
Shivaji Deshmukh¹

Departments of Spine Surgery and ¹Anaesthesia, Shanta Spine Institute, Nagpur, Maharashtra, India

Introduction

Cervical radiculopathy is a condition leading to radicular symptoms along the course of the involved nerve with or without neurological deficit. This is due to nerve root compression due to laterally prolapsed intervertebral disc or posterior osteophytes causing foraminal compression.^[1] Surgical treatment is required only in patients with neural compression leading to either neurological deficit or pain not responding to conservative line of management for 6–8 weeks.^[2]

The surgical treatment for patient with single-level cervical radiculopathy consists of anterior cervical discectomy, anterior cervical discectomy and fusion (ACDF), anterior cervical discectomy, fusion and plating, cervical disc arthroplasty, or posterior cervical foraminotomy.^[3] ACDF is a commonly used surgery, but it is a morbid

procedure requiring a longer recuperation period and its share of complications such as recurrent laryngeal nerve palsy, pharyngeal or esophageal laceration, respiratory distress, bone graft site pain and morbidity, dysphagia, difficulty in phonation, pseudoarthrosis, failure of implant, adjacent segment degeneration, mechanical instability, and angulation deformity.^[4,5] The complication rates in ACDF in various studies varies from 0.45% to 19.6%.^[6]

Posterior cervical foraminotomy as described by Frykholm, Scoville has the advantage of less invasive as compared to ACDF, preserves the paravertebral musculature, easy access to the laterally located disc, or osteophyte compressing the foramen and provides targeted decompression of the nerve root, preserves the disc height and motion of the operated segment, prevents adjacent segment

Address for correspondence:
Dr. Manoj Dayalal Singrakhia, Shanta Spine Institute, 1st Floor Ashirvad Complex, Ramdaspath, Nagpur - 440 010, Maharashtra, India.
E-mail: singrakhia@hotmail.com

Access this article online

Website: www.asianjns.org

DOI: 10.4103/ajns.AJNS_14_17

Quick Response Code:



How to cite this article: Singrakhia MD, Malewar NR, Deshmukh S, Deshmukh S. Clinical and radiological outcomes of day-care posterior foraminotomy and decompression of the cervical spine. *Asian J Neurosurg* 2018;13:1118-22.

This is an open access journal, and articles are distributed under the terms of the Creative Commons Attribution-NonCommercial-ShareAlike 4.0 License, which allows others to remix, tweak, and build upon the work non-commercially, as long as appropriate credit is given and the new creations are licensed under the identical terms.

For reprints contact: reprints@medknow.com

degeneration, and also avoids the complications associated with ACDF.^[7,8]

In this study, we studied the clinical and radiological effect of posterior cervical foraminotomy in patients with single-level cervical radiculopathy with or without neurological deficit.

Materials and Methods

In this retrospective study, we included 17 patients who had unrelenting cervical radiculopathy from June 2011 to May 2016. All patients were initially treated with conservative management for 6–8 weeks. The inclusion and exclusion criteria were patients with single-level cervical radiculopathy with or without neurological deficit were included in the study. Patients with multilevel radiculopathy, cervical myelopathy, cervical instability, and patients with a history of surgery in the past for cervical spine were excluded from the study. Written informed consent of all our patients was taken after explaining the pros and cons of the procedure.

Minimally invasive posterior cervical foraminotomy as a day-care surgery was performed on all the patients. Patients were followed up 1 month, 3 months, 6 months, 12 months, and then yearly after that. The clinical and radiological evaluation was done at every follow-up. The data for evaluation were selected as per the final follow-up of the particular patient.

All patients were evaluated clinically pre- and post-operatively by visual analog scale (VAS) score,^[9] neck disability index (NDI).^[10] The clinical outcome was defined as per Odom's criteria.^[11] The radiological evaluation consisted of measurement of focal angulation (Sagittal segmental alignment) at the operated level and global angulation (Sagittal cervical spine alignment) measured on the lateral cervical radiograph [Table 1].^[12]

The disc height is also measured on lateral cervical radiograph at the level of surgery and also at the adjacent level, i.e., level above and below. The changes in pre- and post-operative disc height index (DHI) at the level of surgery, above and below were calculated as the ratio of postoperative DHI and preoperative DHI multiplied by 100.^[13]

Dynamic radiograph of the cervical spine was done at each follow-up to evaluate for any instability. Radiological instability was defined as per the criteria of White and Punjabi.^[14]

Statistical analysis

The data were recorded using excel sheet in Microsoft excel. The statistical analysis was done by using "paired *t*-test" for comparing pre-and post-operative results. $P < 0.05$ was considered statistically significant.

Table 1: Odom's criteria

Outcome	Criteria
Excellent	Complete relief of symptoms, improvement of abnormal symptoms
Good	Persistence of few preoperative symptoms, no relief of abnormal symptoms
Fair	Some relief from preoperative symptoms, not complete relief, some symptoms persists
Poor	No relief of symptoms and signs, worsening of complaints

Surgical technique

Under general anesthesia, in prone position, head is stabilized in horseshoe-shaped position. Traction is applied with the help of Gardner-Wells tongs. The level of surgery is confirmed by marking it with a needle and checking on the lateral cervical radiograph. A 2 cm midline incision is taken at the level of surgery. Further dissection is done staying along the median raphe to avoid cutting of vascular musculature. By subperiosteal dissection, the muscles and ligaments are freed from the underlying bone to expose the posterior cervical skeletal elements till the lamina and medial facet complex are visualized. The dissection is carried out only on the involved side. The opposite side is not touched to minimize dissection of muscles and prevent subsequent instability.

After exposure of the bony elements, with the help of high-speed burr, the inferior edge of the lateral most part of the lamina of the superior cervical vertebrae of the involved interspace is removed. The bone removed from this part is about 3 mm to 5 mm with the help of microscope to visualize the axillary part of the nerve root. A small amount of bone is removed from the inferomedial portion of the facet. Following this, the superomedial part of the facet of the lower cervical vertebrae is removed which allows access to the proximal-most part of the nerve root. The facet is removed <50% to avoid instability and progressive kyphosis. The herniated disc fragment mostly lies caudal to the nerve root and can be visualized and removed by gentle cephalad retraction of the nerve root. The disc is removed only if soft and easily available. Caudal retraction of the nerve root is to be avoided as it can lead to traction injury to the nerve root and spinal cord. The wound is closed in layers. No drain is required. As all the patients in our study are from younger age group, all were discharged on the same day of surgery. The dressing is removed after 7 days. The patient is advised to wear soft cervical collar in flexion attitude for 1 week or more depending on the muscular spasm.

Results

In this study, 17 patients with single-level cervical radiculopathy were operated with posterior cervical foraminotomy and followed up. The average follow-up

duration was 30.64 months (range 68–14 months). All 17 patients presented with radicular pain and 12 patients also complained of neck pain. The mean preoperative VAS score for neck pain and radicular pain was 7.9 and 7.7, respectively. The mean preoperative NDI score was 30.47. At final follow-up, the mean postoperative VAS score for radicular pain and neck pain was 1.8 and 1.6, respectively. The reduction in the mean VAS score for both radicular pain and neck pain was statistically significant ($P < 0.001$). The mean post operative NDI also reduced significantly to 5.88 ($P < 0.001$) [Table 2].

Five patients presented with sensory disturbance in the involved upper limb, three patients presented with weakness of intrinsic muscle of the hand, and among these patients, one patient also had weakness of elbow flexion preoperatively. Postoperatively, all patients recovered gradually from sensory deficit and motor deficit. None of the patients had sensory and motor deficit at the final follow-up.

Four patients were operated at C4–5 level, eight patients were operated at C5–6 level, and 5 patients were operated at C6–7 level. Eight patients were operated on the right side, and nine patients were operated on the left side.

The mean preoperative focal angulation at the operated site was 2.7° (range 1.1–4.1), and global angulation of the cervical spine between C2 and C7 was 6.2° (range 3.5–9.2). Postoperatively, at the last follow-up, the focal and global angulation was 2.8 and 6.4° , respectively, indicating that there was lordosis being restored; however, the change in both the angulation was not significant statistically ($P > 0.05$, 0.240, and 0.150, respectively). The mean disc height at the operated level preoperatively was 5.92 mm, and postoperatively, it was 5.88 mm at final follow-up. The mean disc height preoperatively at the level above and below (adjacent level) was 5.98 mm and 6.02 mm, respectively, and postoperatively, at the level above and below was 5.94 mm and 5.99 mm, respectively, at final follow-up. Although there was change in the mean disc height, the change was not statistically significant ($P > 0.05$). The dynamic X-rays done on follow-up visits do not show any instability. Percentage of DHI at the level of surgery and at level above and below (adjacent segments) did not show any significant change at the final follow-up. Hence, we can say that there was no adjacent segment degeneration which is seen in 1.8%–36% cases after anterior cervical decompression and fusion or anterior cervical corpectomy [Table 3].^[6]

All patients had significant pain relief after the surgery. All patients were mobilized out of bed on the same day after surgery with the help of cervical collar. All patients were discharged on the same day of the surgery. According to Odom's criteria, at the final follow-up, 13 patients had excellent outcome, five patients had good outcome, and one patient had fair outcome. None of the patients had poor outcome as per Odom's criteria at the final follow-up. There were no complications in our study.

Table 2: Number of patients presented with radicular pain and neck pain and their respective visual analog scale score

Symptoms	Preoperative		Postoperative		P
	Number of patients	Mean VAS	Number of patients	Mean VAS	
Radiculopathy	17	7.9	8	1.8	<0.001
Neck pain	12	7.7	5	1.6	<0.001

VAS – Visual analog scale

Table 3: Pre- and post-operative radiographic evaluation for degeneration of the cervical spine

	Preoperative	Postoperative	P
NDI	30.47	5.88	<0.001
Focal angulation	2.7	2.8	0.240 (>0.05)
Global angulation	6.2	6.4	0.150 (>0.05)
Disc height at the operated segment	5.92	5.88	0.067 (>0.05)
Disc height at superior segment	5.98	5.94	0.068 (>0.05)
Disc height at inferior segment	6.02	5.99	0.289 (>0.05)

NDI – Neck disability index

Discussion

Minimally invasive microscopic technique for posterior cervical foraminotomy helps to achieve the targeted decompression of the nerve root and also prevents the injury to the anatomical structures hence preserves the mechanical stability, minimizes future cervical deformity and degenerative changes.^[7,15] Bydon *et al.* in their study on 171 patients showed that the rate for revision surgery was 9.9% at an average time of 2.4 years.^[2] Davis in his study of 170 patients, the rate for revision surgery was 6%.^[16] Wang *et al.* in their study of 178 patients, the risk for revision surgery was 5% after posterior cervical foraminotomy.^[17]

Minimally invasive endoscopic technique is also associated with complications such as inadvertent placement of k-wire or serial dilator through interlaminar space leading to spinal cord, nerve root, and vertebral artery injury, CSF leak, and seroma formation.^[18]

Posterior cervical foraminotomy can also be done without the use of endoscope with the help of microscopic loops to achieve decompression of the nerve root. This technique can be helpful in smaller centers where microscope is not available. In our study, none of the patients developed postoperative instability, adjacent segment degeneration, or kyphotic deformity. This is because we avoid extensive dissection of muscles and ligaments to preserve the stability of the cervical spine. In our technique, we use a small incision (2 cm), and the dissection is carried out only on the involved side preserving the muscular and ligament attachment with minimal removal of the lamina

and the facet joint which is compressing the nerve root. In our technique, we use simple McCullough retractor with a blade and a hook on the spinous process side and use a microscope to burr out the posterior foramen. We do not use dilators or k-wires as in microscopic technique which can lead to spinal cord or nerve root injury.^[13] The involved facet is removed <50% to avoid postoperative instability, adjacent segment degeneration, and kyphotic deformity.^[19] All patients had significant recovery from the preoperative radicular and neck pain as evident by reduction in VAS score ($P < 0.001$). The NDI score was also reduced significantly postoperatively ($P < 0.001$) indicating that patient was able to perform their daily activity without much difficulty postoperatively. All patients were discharged on the same day on which the surgery was done; hence, this procedure can be carried out as a day-care procedure for treating patients with cervical radiculopathy and avoids the short-term and long-term morbidity associated with the anterior cervical procedure. There were no complications in our study. Kwon in similar study conducted on 33 patients who underwent posterior cervical foraminotomy also showed that there were no complications after the surgery and all patients had uneventful recovery.^[13]

Posterior cervical foraminotomy can lead to instability at the operated level, adjacent segment degeneration, and kyphotic deformity of the cervical spine if there is excessive damage to the paraspinal muscle or due to excessive removal of lamina and the facet. As the cervical facet joints are placed in coronal plane, removal of more than 50% of the facet joint will lead to instability.^[19] Excessive subperiosteal dissection of the muscles (multifidus and semispinalis) and ligaments which act as dynamic stabilizers of the neck can lead to postoperative axial neck pain, excessive cervical mobility [Figure 1], and postoperative progressive kyphotic deformity due to postoperative muscle dysfunction.^[20,21] In our technique, all these complications are prevented as we avoid excessive muscle dissection, and the facet removal is done <50%.

Cho *et al.*^[3] in their study of 31 patients showed that patients who underwent posterior cervical foraminotomy had preservation of movement of the same segment and do not have degeneration of the adjacent segment while patients who underwent ACDF had lost the movement of operated segment and had degeneration of the adjacent segment. In our study also, none of the patients developed degeneration of the operated level as well as adjacent segment as the disc height was maintained postoperatively as compared to preoperatively ($P > 0.05$). Kwon *et al.*^[13] in their study of minimally invasive posterior cervical foraminotomy concluded that the VAS score improved significantly in the early postoperative period and was maintained for longer duration. They also showed that NDI also improved significantly postoperatively. The focal, global angulation, and percent DHI were maintained postoperatively in their study without significant changes. In our study, we also

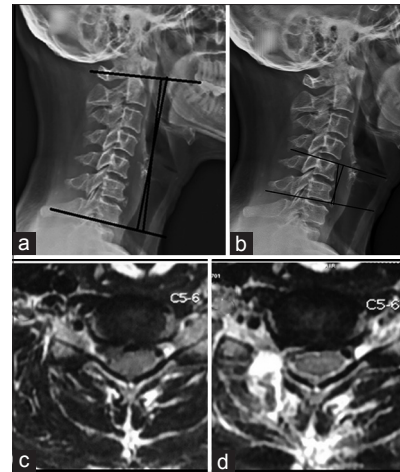


Figure 1: (a) Radiograph showing measurement of sagittal cervical spine alignment. (b) Radiograph showing measurement of segmental cervical spine alignment. (c) Preoperative axial MRI showing disc herniation on the right side at C5–C6 level. (d) Postoperative axial MRI showing posterior cervical foraminotomy on the right side at C5–C6

found that the VAS score for radicular and neck pain as well as NDI reduced significantly at final follow-up as compared to preoperative values ($P < 0.001$). Chang *et al.* in their study of 34 patients showed that posterior cervical foraminotomy with preservation of facet joint helped in significant reduction of VAS score postoperatively, and the mean focal, global angulation and the disc height were maintained postoperatively.^[22] In our study also, the focal and the global angulation was maintained as compared to preoperative values ($P > 0.05$) indicating that there was no degeneration at the operated level and no progressive deformity of the cervical spine. Terai *et al.*^[23] in their study of 35 patients who underwent keyhole posterior cervical foraminotomy showed that radicular pain was relieved in 97% of patients, and muscle power was also resolved to normal after mean follow-up duration of 6 months. In our study also, 5 patients presented with sensory deficit and 3 patients presented with motor deficit. All patients were cured from neurological deficit as assessed on final follow-up.

The limitation of our study was small number of patients were included in the study with short duration of follow-up. Another disadvantage was that it was a retrospective study, and there were no control group in the study. The advantage of this study is that it highlights that posterior cervical foraminotomy can be used for treating cervical radiculopathy with minimal cost, shorter duration of hospital stay as a day-care procedure with minimal complications.

Conclusion

This study shows that the posterior cervical foraminotomy is a good method for treatment of patients with single-level cervical radiculopathy with minimal cost, shorter hospital stay, early recovery, good functional outcome, and minimum complications.

Financial support and sponsorship

Nil.

Conflicts of interest

There are no conflicts of interest.

References

1. Tschugg A, Neururer S, Scheufler KM, Ulmer H, Thomé C, Hegewald AA. Comparison of posterior foraminotomy and anterior foraminotomy with fusion for treating spondylotic foraminal stenosis of the cervical spine: Study protocol for a randomized controlled trial (ForaC). *Trials* 2014;15:437.
2. Bydon M, Mathios D, Macki M, de la Garza-Ramos R, Sciubba DM, Witham TF, *et al.* Long-term patient outcomes after posterior cervical foraminotomy: An analysis of 151 cases. *J Neurosurg Spine* 2014;21:727-31.
3. Cho TG, Kim YB, Park SW. Long term effect on adjacent segment motion after posterior cervical foraminotomy. *Korean J Spine* 2014;11:1-6.
4. Zhu B, Xu Y, Liu X, Liu Z, Dang G. Anterior approach versus posterior approach for the treatment of multilevel cervical spondylotic myelopathy: A systemic review and meta-analysis. *Eur Spine J* 2013;22:1583-93.
5. Liu T, Xu W, Cheng T, Yang HL. Anterior versus posterior surgery for multilevel cervical myelopathy, which one is better? A systematic review. *Eur Spine J* 2011;20:224-35.
6. Fountas KN, Kapsalaki EZ, Smith BE, Nikolakakos LG, Richardson CH, Smisson HF, *et al.* Interobservational variation in determining fusion rates in anterior cervical discectomy and fusion procedures. *Eur Spine J* 2007;16:39-45.
7. Clark JG, Abdullah KG, Steinmetz MP, Benzel EC, Mroz TE. Minimally invasive versus open cervical foraminotomy: A systematic review. *Global Spine J* 2011;1:9-14.
8. Mansfield HE, Canar WJ, Gerard CS, O'Toole JE. Single-level anterior cervical discectomy and fusion versus minimally invasive posterior cervical foraminotomy for patients with cervical radiculopathy: A cost analysis. *Neurosurg Focus* 2014;37:E9.
9. Flaherty SA. Pain measurement tools for clinical practice and research. *AANA J* 1996;64:133-40.
10. Vernon H, Mior S. The neck disability index: A study of reliability and validity. *J Manipulative Physiol Ther* 1991;14:409-15.
11. Zoëga B, Kärrholm J, Lind B. Outcome scores in degenerative cervical disc surgery. *Eur Spine J* 2000;9:137-43.
12. Faldini C, Leonetti D, Nanni M, Di Martino A, Denaro L, Denaro V, *et al.* Cervical disc herniation and cervical spondylosis surgically treated by Cloward procedure: A 10-year-minimum follow-up study. *J Orthop Traumatol* 2010;11:99-103.
13. Kwon YJ. Long-term clinical and radiologic outcomes of minimally invasive posterior cervical foraminotomy. *J Korean Neurosurg Soc* 2014;56:224-9.
14. Uehara M, Takahashi J, Ogihara N, Hirabayashi H, Hashidate H, Mukaiyama K, *et al.* Cervical pedicle screw fixation combined with laminoplasty for cervical spondylotic myelopathy with instability. *Asian Spine J* 2012;6:241-8.
15. Hur JW, Kim JS, Shin MH, Ryu KS. Minimally invasive posterior cervical decompression using tubular retractor: The technical note and early clinical outcome. *Surg Neurol Int* 2014;5:34.
16. Davis RA. A long-term outcome study of 170 surgically treated patients with compressive cervical radiculopathy. *Surg Neurol* 1996;46:523-30.
17. Wang TY, Lubelski D, Abdullah KG, Steinmetz MP, Benzel EC, Mroz TE. Rates of anterior cervical discectomy and fusion after initial posterior cervical foraminotomy. *Spine J* 2015;15:971-6.
18. Branch BC, Hilton DL Jr., Watts C. Minimally invasive tubular access for posterior cervical foraminotomy. *Surg Neurol Int* 2015;6:81.
19. Barakat M, Hussein Y. Anatomical study of the cervical nerve roots for posterior foraminotomy: Cadaveric study. *Eur Spine J* 2012;21:1383-8.
20. Hilibrand AS, Carlson GD, Palumbo MA, Jones PK, Bohlman HH. Radiculopathy and myelopathy at segments adjacent to the site of a previous anterior cervical arthrodesis. *J Bone Joint Surg Am* 1999;81:519-28.
21. Kotani Y, Abumi K, Ito M, Sudo H, Takahata M, Ohshima S, *et al.* Minimum 2-year outcome of cervical laminoplasty with deep extensor muscle-preserving approach: Impact on cervical spine function and quality of life. *Eur Spine J* 2009;18:663-71.
22. Chang JC, Park HK, Choi SK. Posterior cervical inclinatory foraminotomy for spondylotic radiculopathy preliminary. *J Korean Neurosurg Soc* 2011;49:308-13.
23. Terai H, Suzuki A, Toyoda H, Yasuda H, Kaneda K, Katsutani H, *et al.* Tandem keyhole foraminotomy in the treatment of cervical radiculopathy: Retrospective review of 35 cases. *J Orthop Surg Res* 2014;9:38.