




Case Report

Kyphosis and canal compromise due to refracturing of an L1 cemented vertebra managed with posterior surgery alone

Abolfazl Rahimizadeh

Pars Advanced and Minimally Invasive Medical Manners Research Center, Pars Hospital, Iran University of Medical Sciences, Tehran, Iran.

E-mail: *Abolfazl Rahimizadeh - a_rahimizadeh@hotmail.com



***Corresponding author:**

Abolfazl Rahimizadeh,
Pars Advanced and Minimally
Invasive Medical Manners
Research Center, Num. 10,
Rastak St., Keshawarz Blvd.,
Tehran, Iran.

dr.rahimizadeh@hotmail.com

Received : 25 August 19
Accepted : 12 October 19
Published : 01 November 19

DOI
10.25259/SNI_456_2019

Quick Response Code:



ABSTRACT

Background: An already cemented vertebral body rarely refractures and its occurrence may be signaled by the reappearance of pain and/or significant vertebral collapse/kyphosis resulting in canal compromise and neurological deterioration.

Case Description: An 81-year-old male originally underwent an L1 kyphoplasty for an osteoporotic compression fracture. Nine months later, he presented with the late onset of recurrent collapse of the cemented vertebral body, leading to pain, kyphosis, and canal compromise. Surgery warranted total L1 corpectomy, reconstruction of the anterior column, and a posterior fixation through a purely posterior approach (posterior vertebral column resection [pVCR]).

Conclusion: Here, we presented the safety/efficacy of utilizing a purely posterior approach (e.g., including L1 corpectomy, reconstruction of the anterior column, and posterior fusion: pVCR) in the management of a repeated fracture of a cemented L1 vertebra resulting in kyphosis and canal compromise.

Keywords: Cemented vertebra percutaneous kyphoplasty, Percutaneous vertebroplasty, Refracture

INTRODUCTION

Percutaneous vertebroplasty (PVP) and percutaneous kyphoplasty (PKP) are increasingly used to treat osteoporotic vertebral compression fractures. However, one of the late, but rare complications, is the refracturing of the cemented vertebra.^[6,7,9,10,12,16] Here, in a patient with a recurrent/symptomatic L1 compression fracture that resulted in kyphosis and canal compromise, we utilized a purely posterior approach (e.g., posterior vertebral column resection [pVCR]) that included the performance of an anterior corpectomy, reconstruction of the anterior column, and posterior vertebral body fusion.^[4,13,14]

CASE REPORT

An 81-year-old male presented with a mild paraparesis of 2 months duration. Nine months before admission, he had undergone an L1 PKP for an osteoporotic fracture.

Radiological assessment

The anteroposterior (AP) thoracolumbar plain radiograph showed two symmetric kyphoplasty cement collections within the L1 vertebral body, while the lateral radiograph showed two

wedge-shaped lateral compartments which were attached with a narrow medial bridge. Although the height of the anterior compartment was preserved with the PKP, the wedge-shaped posterior compartment was now significantly kyphotic and had migrated dorsally into the spinal canal resulting in significant conus/cauda equina compression [Figure 1].

Surgery

The pVCR of the L1 vertebra first required pedicle screw fixation placed above and below the fractured L1 vertebral level. Next, an L1 corpectomy was performed to reset the previously cemented L1 vertebra followed by reconstruction of the anterior column utilizing a tibial shaft allograft [Figures 2-4]. Finally, posterior stabilization was completed. Postoperatively, the plain thoracolumbar X-ray demonstrated adequate alignment [Figure 5]. Within 3 weeks, the patient was using a walker, and by 6 weeks, he was ambulating

independently. Unfortunately, the patient passed away 14 months after the original surgery due to a pulmonary infection (e.g., unrelated to the spine surgery) resulting in sepsis and renal failure.

DISCUSSION

One of the late sequelae of PVP and PKP procedures is the refracturing of cemented vertebrae that can occur from 0.56% to 3.7% of PVP and from 9.7% to 12.5% of PKP cases.^[6,8,9,15,16]

Pathogenesis and rates of PVP and PKP refractures

Several studies have demonstrated that the increased “distance between polymethylmethacrylate and the endplate” increases the rate of refracture.^[1,5,7] The intervertebral cleft is another risk factor if not properly sealed during the initial procedure.^[6]

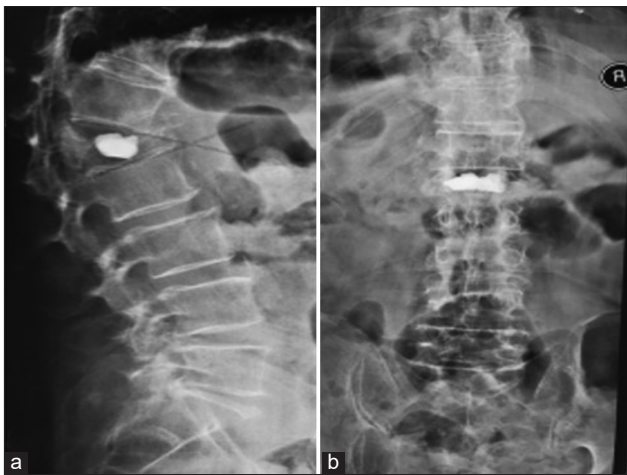


Figure 1: (a) Lateral plain radiograph shows refracture of cemented L1, note that the posterior compartment is pushed back associated with canal compromise and kyphosis, (b) anteroposterior lumbar X-ray demonstrates two cemented lumps.

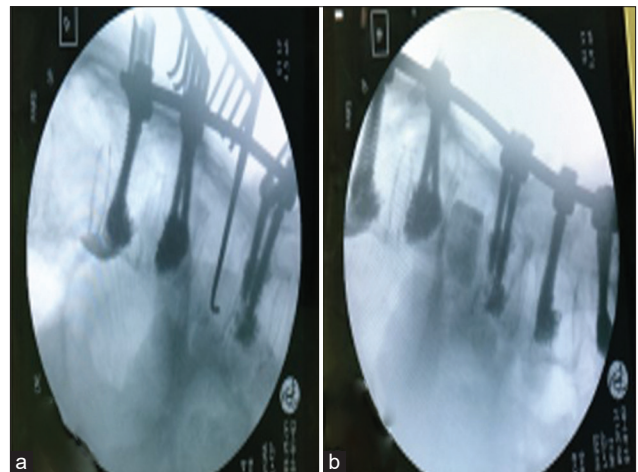


Figure 3: Intraoperative fluoroscopy (a) shows complete spondylectomy, (b) the anterior column is reconstructed with a tibial shaft allograft.

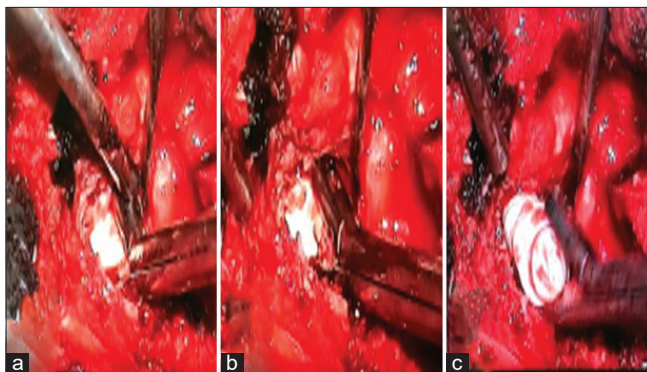


Figure 2: (a) The bone cement is demonstrated at the beginning of spondylectomy, (b) trying to remove cemented lump, (c) is almost removed.

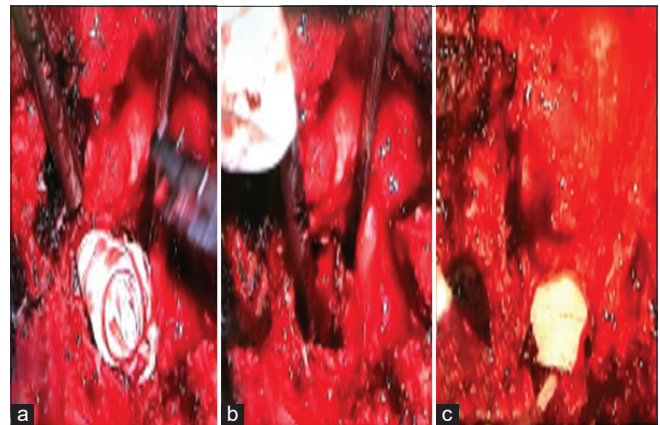


Figure 4: Intraoperative photograph, (a) the lump is removed, (b) spondylectomy done, (c) replacement of the site with allograft.

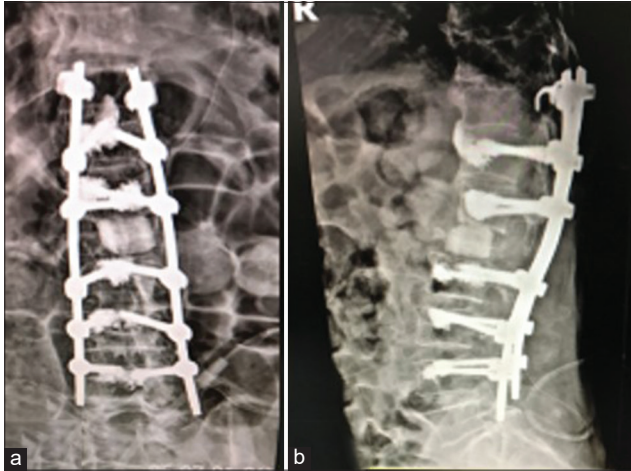


Figure 5: Postoperative lumbar X-ray, (a) anteroposterior radiograph shows proper placement of the allograft, note good coronal alignment, (b) lateral radiographs show correction of kyphosis and good sagittal alignment, note pedicle screws cement augmentation.

Distribution of cement

The distribution pattern for cement is classified into two types: (1) local solid lumps or (2) the trabecular/diffuse types.^[5,7] In the localized solid lump pattern, the cement is confined to a small area within the anterior two-thirds of the vertebral body (e.g., particularly within the middle third of the body); it results in stress shielding, thereby increasing the risk of microfracture and progressive vertebral body height loss within the noncemented areas. For the trabecular or diffuse patterns, the cement is dispersed and fills the trabecular bone of the additional posterior one-third of the vertebral body.^[5,7]

Rates of vertebral recollapse

Recollapse of a previously cemented vertebral body most often occurs within the thoracolumbar region. Infrequently, it is seen involving the low lumbar levels and only rarely within the thoracic spine itself.^[2,3,5-12] The interval between initial cement augmentation and refracture varies from 3 to 6 months for PKP and from 6 to 16 months with PVP.^[6,8,9,12,15,16] The differences in the intervals between refracturing the following initial PKP and PVP can be easily explained by the differences in the distribution patterns of the originally injected cement.

Clinical presentation of recurrent vertebral recollapse

Clinically, the refracturing of a vertebral body following initial PKP and PVP results in recurrent localized pain and/or progressive kyphosis with canal compromise and focal neurological deficits. This can be managed with repeated vertebroplasty (e.g., using a single Jamshidi needle).^[2,3,11,15]

However, for those with significant vertebral height loss, a kyphotic deformity, and canal compromise, surgical intervention may be required. Here, we describe a posterior only technique (e.g., pVCR) that offers 360° reconstruction of the vertebral column including anterior corpectomy, anterior stabilization, and posterior fusion. In the future, this pVCR technique may prove to be safe and effective for managing recurrent vertebral body fractures following PKP and PVP.

CONCLUSION

With the appearance of localized pain after prior PVP or PKP, or the onset of kyphosis with a neurological deficit, routine AP and lateral radiographs may document recurrent vertebral body fracture that may be managed with a posterior only technique (pVCR) that offers unique 360° spinal correction.

Declaration of patient consent

The authors certify that they have obtained all appropriate patient consent forms.

Financial support and sponsorship

Nil.

Conflicts of interest

There are no conflicts of interest.

REFERENCES

1. Belkoff SM, Mathis JM, Jasper LE, Deramond H. The biomechanics of vertebroplasty. The effect of cement volume on mechanical behavior. *Spine (Phila Pa 1976)* 2001;26:1537-41.
2. Chen LH, Hsieh MK, Liao JC, Lai PL, Niu CC, Fu TS, *et al.* Repeated percutaneous vertebroplasty for refracture of cemented vertebrae. *Arch Orthop Trauma Surg* 2011;131:927-33.
3. Choi SS, Hur WS, Lee JJ, Oh SK, Lee MK. Repeat vertebroplasty for the subsequent refracture of procedured vertebra. *Korean J Pain* 2013;26:94-7.
4. Fattahi A, Daneshi A. Traumatic thoracic spine spondyloptosis treated with spondylectomy and fusion. *Surg Neurol Int* 2018;9:158.
5. Feng L, Feng C, Chen J, Wu Y, Shen JM. The risk factors of vertebral refracture after kyphoplasty in patients with osteoporotic vertebral compression fractures: A study protocol for a prospective cohort study. *BMC Musculoskelet Disord* 2018;19:195.
6. Heo DH, Chin DK, Yoon YS, Kuh SU. Recollapse of previous vertebral compression fracture after percutaneous vertebroplasty. *Osteoporos Int* 2009;20:473-80.
7. Kim DJ, Kim TW, Park KH, Chi MP, Kim JO. The proper volume and distribution of cement augmentation on percutaneous vertebroplasty. *J Korean Neurosurg Soc* 2010;48:125-8.

8. Kim YY, Rhyu KW. Recompression of vertebral body after balloon kyphoplasty for osteoporotic vertebral compression fracture. *Eur Spine J* 2010;19:1907-12.
9. Lavelle WF, Cheney R. Recurrent fracture after vertebral kyphoplasty. *Spine J* 2006;6:488-93.
10. Leslie-Mazwi T, Deen HG. Repeated fracture of a vertebral body after treatment with balloon kyphoplasty: Case illustration. *J Neurosurg Spine* 2006;4:270.
11. Li X, Lou X, Lin X, Du J. Refracture of osteoporotic vertebral body concurrent with cement fragmentation at the previously treated vertebral level after balloon kyphoplasty: A case report. *Osteoporos Int* 2014;25:1647-50.
12. Li YX, Guo DQ, Zhang SC, Liang, Yuan K, Mo GY, *et al.* Risk factor analysis for re-collapse of cemented vertebrae after percutaneous vertebroplasty (PVP) or percutaneous kyphoplasty (PKP). *Int Orthop* 2018;42:2131-9.
13. Rahimizadeh A, Hassani V, Mohsenikabir N, Rahimizadeh A, Karimi M, Asgari N, *et al.* Intraoperative tension pneumothorax during posterior vertebral column resection in a child with congenital scoliosis. *Surg Neurol Int* 2019;10:155.
14. Rahimizadeh A, Rahimizadeh A. Management of traumatic double-level spondyloptosis of the thoracic spine with posterior spondylectomy: Case report. *J Neurosurg Spine* 2015;23:715-20.
15. Summa A, Crisi G, Cerasti D, Ventura E, Menozzi R, Ormitti F, *et al.* Refractures in cemented vertebrae after percutaneous vertebroplasty and pain relief after a second procedure: A retrospective analysis. *Neuroradiol J* 2009;22:239-43.
16. Yu W, Xu W, Jiang X, Liang, Jian W. Risk factors for recollapse of the augmented vertebrae after percutaneous vertebral augmentation: A systematic review and meta-analysis. *World Neurosurg* 2018;111:119-29.

How to cite this article: Rahimizadeh A. Kyphosis and canal compromise due to refracturing of an L1 cemented vertebra managed with posterior surgery alone. *Surg Neurol Int* 2019;10:212.