

Case Report

©2013 NRITLD, National Research Institute of Tuberculosis and Lung Disease, Iran

ISSN: 1735-0344 *Tanaffos* 2013; 12(4): 53-57

TANAFFOS 

Spontaneous Esophageal Perforation Presenting as a Right-Sided Pleural Effusion: A Case Report

Ebrahim Razi ¹, Abdolhossein Davoodabadi ¹, Armin Razi ²

¹ Trauma Research Center, Kashan University of Medical Sciences, Kashan, Iran

² Shahid Beheshti University of Medical Sciences, Tehran, Iran

Received: 14 March 2013

Accepted: 15 October 2013

Correspondence to: Razi E

Address: Trauma Research Center, Kashan

University of Medical Sciences, Kashan, Iran

Email address: ebrahimrazi@yahoo.com

Spontaneous esophageal perforation or Boerhaave's syndrome is an uncommon condition that may occur following forceful vomiting and lead to mediastinitis. It is associated with high mortality and morbidity in absence of therapy. We present a case of spontaneous esophageal perforation in a 63 year-old man who developed a right-sided effusion, an unusual presentation.

This case report and the relevant literature reveal that delay in prompt surgical repair is associated with a high morbidity and mortality.

Key words: Esophageal perforation, Mediastinitis, Pleural effusion

INTRODUCTION

Esophageal perforation is a rare condition that can lead to significant morbidity and mortality. Diagnosis is often delayed and usually confused with other equally serious but more prevalent pathologies such as acute myocardial infarction, perforated peptic ulcer and acute pancreatitis(1). The classic clinical presentation is a middle-aged male with episodes of repeated vomiting or retching followed by lower chest or upper abdominal pain and subcutaneous emphysema. Unfortunately, patients presenting with this syndrome comprise a heterogeneous group and often present atypically (2-4). Other frequent findings include pleural effusion, tachypnoea and abdominal rigidity. Chest radiograph is abnormal in 90% of cases and may show evidence of a pleural effusion (more frequently on the left side), pneumomediastinum, pneumothorax,

hydropneumothorax or subcutaneous emphysema. This case report describes a 63 year-old man who presented with Boerhaave's syndrome and developed a right-sided effusion.

CASE SUMMARIES

A 63 year-old man presented to the emergency department with a three hour history of dyspnea and central chest pain radiated into his back. The workup for an acute coronary syndrome was negative. On admission he had a pulse of 94 per minute, BP 135/72 mm Hg, SaO₂ 97% on air and temperature of 37°C. There was no history of alcohol ingestion, cardiovascular or abdominal diseases. There was no surgical emphysema in the supraclavicular fossae. At follow-up, three days later, physical examination revealed an acutely ill man, and the patient temperature

rose to 39 ° C. The right lower chest region was dull to percussion and had decreased breath sound.

Chest X-ray demonstrated right pleural effusion, but there was no evidence of pneumomediastinum or subcutaneous emphysema (Figure 1). A diagnostic pleural fluid aspiration confirmed exudates and the gram stain and culture were negative. Subsequent CT scan demonstrated right sided pneumothorax, extended right sided pleural effusion and a small amount of air in the mediastinum (Figure 2).

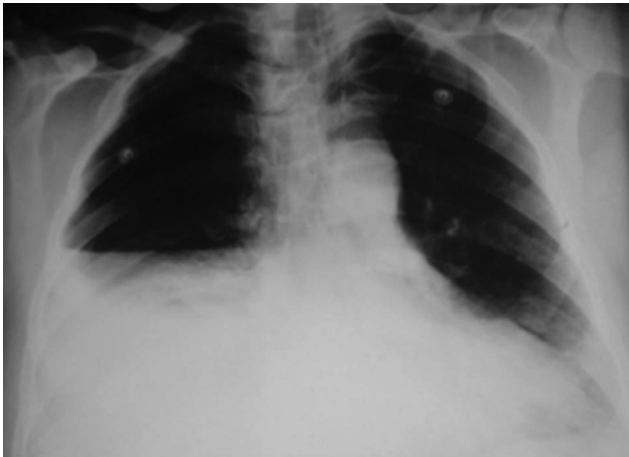


Figure 1. Chest X-ray demonstrated right hydropneumothorax in spontaneous perforation of distal esophagus (Boerhaave's syndrome).

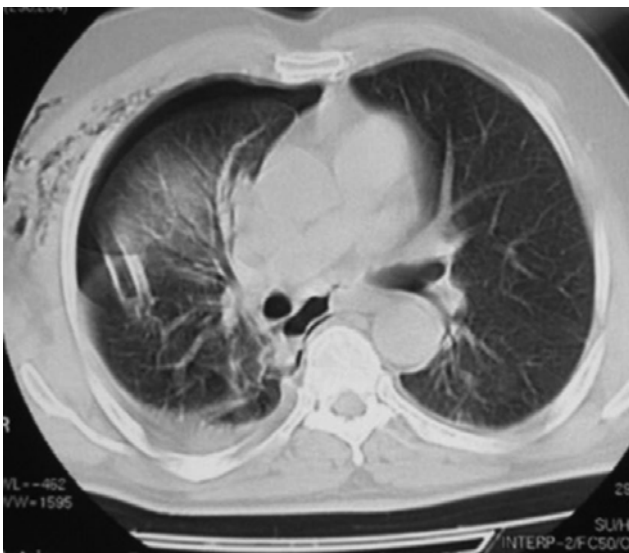


Figure 2. Chest CT scan demonstrated right sided hydropneumothorax, and a small amount of air in the mediastinum. Chest tube is located in right pleural space.

A complete blood count showed a hemoglobin concentration of 11.5 gm/dl, hematocrit of 35.4%, a white-cell count of 17500/ml with 85% neutrophils, and a platelet count of 145,000/ml. Levels of serum electrolytes were normal; the urea nitrogen level was 30 mg per deciliter, the creatinine level 2.1 mg per deciliter. Tests of liver function were normal

The patient was treated with antibiotics and a tube thoracostomy. Right closed thoracotomy was performed and water-seal drainage was established, permitting the removal of 1500 ml of fluid. The patient was initially treated with ceftriaxone (1 gm every 12 hours) and clindamycin (600 mg every eight hours). Due to the lack of response to treatment, imipenem (500 mg every six hours) plus vancomycin (1 gm every 12 hours) were added to the treatment regimen of patient. Finally, five days after admission, clinical deterioration with increased respiratory distress and discomfort, fever, delay in chest expansion and chest pain did arouse suspicion of an esophageal perforation.

The patient underwent right thoracotomy with repair of a linear longitudinal tear 3 cm in length on the posterior wall of the mid-esophagus. At the time of surgery there was marked mediastinal and pleural inflammation. An open thoracotomy, surgical repair of esophageal perforation and thoracic window were subsequently performed. Intravenous vasopressors were administered postoperatively to maintain the patient's blood pressure at satisfactory levels.

After surgery the patient's condition deteriorated, and he was transferred to the intensive care unit (ICU) and required mechanical ventilation. Despite the repair of esophageal rupture postoperative evolution was complicated by respiratory failure, acute kidney failure and pleural empyema requiring re-operation. The patient died 17 days after admission.

DISCUSSION

Spontaneous rupture of esophagus or Boerhaave's syndrome usually results from sudden rise of intraesophageal pressure (due to contraction of cricopharyngeus muscle and closing of pyloric sphincter) associated with forceful vomiting or retching. Meckler's triad of vomiting, pain and subcutaneous emphysema are characteristic features of Boerhaave's syndrome.

Boerhaave first described the spontaneous rupture of esophagus in 1724 (5).

It typically occurs after forceful emesis. Boerhaave's syndrome is a transmural perforation of the esophagus. Common causes of esophageal perforation include medical instrumentation, foreign-body ingestion, and trauma. Iatrogenic esophageal perforations have become more common due to the rapid increase and development of upper gastrointestinal tract endoscopies and now account for 63.9% of perforations. A further 16.7% can be attributed to foreign bodies, 13.9% to external trauma, and 5.5% to spontaneous rupture (Boerhaave's Syndrome)(6). Other causes of spontaneous perforation include caustic ingestion, pill esophagitis, Barrett's ulcer and infectious ulcers in patients with AIDS, and following dilation of esophageal strictures.

The incidence of esophageal perforation due to rigid esophagoscopy is 0.11% while that associated with fiberoptic examination ranges from 0.018% to 0.03% (6,7). The most common anatomical location of the tear in Boerhaave's syndrome is at the left posterolateral wall of the lower third of the esophagus, 2-3 cm proximal to the

gastroesophageal junction, along the longitudinal wall of the esophagus. The second most common site of rupture is in the subdiaphragmatic or upper thoracic area (8).

Perforation of the distal esophagus usually results in pleural effusion or hydropneumothorax on the left, while perforation of the midesophagus tends to produce pleural effusion or hydropneumothorax on the right. Spontaneous perforation (Boerhaave's syndrome) usually occurs in the

distal esophagus, with resultant hydropneumothorax on the left.

The clinical picture depends on the level of the perforation and the time interval from rupture to presentation. The mid esophagus lies next to the right pleura while the lower esophagus abuts the left pleura. Once a perforation occurs, saliva, retained gastric contents, bile and acid enter the mediastinum, resulting in mediastinitis, pneumomediastinum and pleural collections. Initially, the patient presents with pain at the site of perforation usually in the neck, chest, epigastric region, or upper abdomen (9).

The first sign may be subcutaneous emphysema (10,11). Other early symptoms include dyspnea, fever, and dysphasia. The Meckler's triad defines the classic presentation. It consists of vomiting, lower thoracic pain, and subcutaneous emphysema. In current case, at first the diagnosis of esophageal perforation was not suspected. The original diagnosis of esophageal perforation was delayed because of misinterpretation of right pleural effusion as a complication of pneumonia.

Tachycardia, diaphoresis, fever, and hypotension are common. However, these findings are nonspecific and are due to sepsis from the mediastinitis and pleural collections. In contrast to patients with Mallory-Weiss tears, hematemesis, if present, is seldom a significant feature of the presentation (3). Chest x-ray is abnormal in 90% of cases of esophageal perforation but can be normal if taken early (12). Pneumomediastinum may be seen as demonstrated above by the radiolucent streaks of free air surrounding the trachea.

The gold standard for diagnosis is to perform a contrast enhanced esophagogram, initially with water-based contrast such as gastrograffin. If this study is negative and the index of suspicion is still high, diluted barium contrast should be performed to confirm the diagnosis and localize the perforation.

Due to the nonspecific nature of its presentation, diagnosis is often delayed, since it is a rare disease and is usually confused with other equally serious but more prevalent pathologies such as acute myocardial infarction, perforated peptic ulcer and acute pancreatitis (1). The diagnosis (as in our current case) is often missed initially because this syndrome is rare and the conditions that can mimic it are more common.

Management of esophageal perforation is either surgical or medical.

Surgery has been the most common treatment. Medical management consists of the followings: intravenous fluids, broad-spectrum antibiotics, nasogastric suction, no oral intake, and adequate drainage with tube thoracostomy. Early use of nutritional supplementation is helpful. Barrett described the first successful surgical repair of the esophagus in 1947 (13). Surgical repair within 12 to 24 hours is associated with a

mortality rate of 34% while a delay of 24 hours is associated with 64% mortality (14).

Direct repair of the rupture and adequate drainage of the mediastinum and pleural cavity provide the best survival rates. Esophageal perforation is a serious condition with a high mortality rate. Successful therapy depends on the size of the rupture, the time elapsed between rupture and diagnosis, and the underlying health of the patient.

The authors described the case of a patient in whom the diagnosis was made several days following presentation by observing that a large pleural effusion had evolved rapidly on chest radiographs.

In conclusion, spontaneous rupture of the esophagus is a serious condition. Its diagnosis is usually neglected during the initial assessment. In the case presented here, vomiting, right-sided pleural effusion, thoracocentesis with aspiration of fluid with refractory improvement to tube thoracostomy making the diagnosis and recommending the surgical treatment. Postoperative evolution is almost

always complicated by organ failure and requires intensive care. High mortality and morbidity rates are expected.

REFERENCES

1. Fell SC. Esophageal perforation. In: Pearson FG, Cooper JD, Deslauries J, Ginsberg RJ, Hiebert C, Patterson GA, et al., editors. *Esophageal Surgery*. New York: Churchill Livingstone, 2002. p. 615-36.
2. Lemke T, Jagminas L. Spontaneous esophageal rupture: a frequently missed diagnosis. *Am Surg* 1999; 65 (5): 449- 52.
3. Henderson JA, Pélouquin AJ. Boerhaave revisited: spontaneous esophageal perforation as a diagnostic masquerader. *Am J Med* 1989; 86 (5): 559- 67.
4. Brauer RB, Liebermann-Meffert D, Stein HJ, Bartels H, Siewert JR. Boerhaave's syndrome: analysis of the literature and report of 18 new cases. *Dis Esophagus* 1997; 10 (1): 64- 8.
5. DERBES VJ, MITCHELL RE Jr. Hermann Boerhaave's Atrocis, nec descripti prius, morbi historia, the first translation of the classic case report of rupture of the esophagus, with annotations. *Bull Med Libr Assoc* 1955; 43 (2): 217- 40.
6. Eroglu A, Can Kürkcüoğlu I, Karaoganoğlu N, Tekinbaş C, Yılmaz O, Başoğlu M. Esophageal perforation: the importance of early diagnosis and primary repair. *Dis Esophagus* 2004; 17 (1): 91- 4.
7. Wesdorp IC, Bartelsman JF, Huijbregtse K, den Hartog Jager FC, Tytgat GN. Treatment of instrumental oesophageal perforation. *Gut* 1984; 25 (4): 398- 404.
8. Korn O, Oñate JC, López R. Anatomy of the Boerhaave syndrome. *Surgery* 2007; 141 (2): 222- 8.
9. Katsetos MC, Tagbo AC, Lindberg MP, Rosson RS. Esophageal perforation and mediastinitis from fish bone ingestion. *South Med J* 2003; 96 (5): 516- 20.
10. Eroglu A, Kürkcüoğlu C, Karaoglanoglu N, Tekinbaş C, Cesur M. Spontaneous esophageal rupture following severe vomiting in pregnancy. *Dis Esophagus* 2002; 15 (3): 242- 3.
11. Di Maggio EM, Preda L, La Fianza A, Dore R, Pallavicini D, Di Maggio G, et al. [Spontaneous rupture of the esophagus (Boerhaave syndrome): computerized tomography diagnosis

- in atypical clinical presentation]. *Radiol Med* 1997; 94 (1-2): 52-7.
12. Han SY, McElvein RB, Aldrete JS, Tishler JM. Perforation of the esophagus: correlation of site and cause with plain film findings. *AJR Am J Roentgenol* 1985; 145 (3): 537- 40.
13. Chu HN, Chang CH, Hui CK, Hui YL. Anesthetic management of Boerhaave's syndrome. *Acta Anaesthesiol Taiwan* 2004; 42 (2): 103- 6.
14. Janjua KJ. Boerhaave's syndrome. *Postgrad Med J* 1997; 73 (859): 265- 70.