

Original research

Ocular higher-order aberrations changes after implantable collamer lens implantation for high myopic astigmatism

Seyed Javad Hashemian ^{a,*}, Hosein Farrokhi ^a, Alireza Foroutan ^a, Mohammad Ebrahim Jafari ^a,
Seyed Mahyar Hashemian ^b, Sayyed Amirpooya Alemzadeh ^a, Mahsa Sadat Hashemian ^c

^a Eye Research Center, Rassoul Akram Hospital, Iran University of Medical Sciences, Tehran, Iran

^b Shahid Beheshti University of Medical Sciences, Tehran, Iran

^c International Campus, Tehran University of Medical Sciences, Tehran, Iran

Received 14 May 2017; revised 23 September 2017; accepted 18 October 2017

Available online 10 November 2017

Abstract

Purpose: To investigate the changes in higher-order aberrations (HOAs) induced by the implantation of implantable collamer lenses (ICLs) and Toric ICL (TICL) in eyes with high myopia and high myopic astigmatism.

Methods: We investigated 33 eyes of 18 consecutive patients (in a prospective, interventional case series study), with spherical equivalent errors of -6.00 to -21.09 diopters (D) and cylindrical errors of -0.5 to -4.75 D, who underwent ICL and TICL implantation. Before and after 5 days, 2 and 6 months of surgery, the uncorrected visual acuity (UCVA), best corrected visual acuity (BCVA), defocus and adverse events of the surgery were assessed. Ocular HOAs were also evaluated by Hartmann-Shack aberrometry (Technolas PV, Rochester, New York, USA) before and after 6 months of surgery.

Results: At 6.0 months after surgery, the UCVA and BCVA in 40% and 66.7% of eyes were 20/20, respectively. Mean defocus refraction and astigmatism was reduced to -0.66 and 0.65 D from -12.79 and 2.18 at baseline, respectively. For a 6 mm pupil, HOAs were not significantly changed, merely from $0.417 \pm 0.162 \mu$ before surgery to $0.393 \pm 0.119 \mu$ after surgery ($P = 0.45$). Spherical aberration (Z400) increased significantly ($P = 0.00$). Surgical induced astigmatism was lower than 0.25 D, and there were no changes in trefoils and coma aberration. No vision-threatening complications occurred during the observation period.

Conclusion: This study shows that the ICL and TICL performed well in correcting high myopic astigmatism without significant changes in HOAs during a 6-month observation period, although the spherical aberration (Z400) increased significantly.

Copyright © 2017, Iranian Society of Ophthalmology. Production and hosting by Elsevier B.V. This is an open access article under the CC BY-NC-ND license (<http://creativecommons.org/licenses/by-nc-nd/4.0/>).

Keywords: Implantable collamer lens; Higher-order aberrations; Phakic intraocular lens; Myopic astigmatism

Introduction

There are various ways to correct refractive errors. Two main surgical treatments are corneal refractive surgery and intraocular lens (IOL) implantation or phakic IOLs. Kerato-refractive surgery like laser-assisted in situ keratomileusis (LASIK) and photorefractive keratectomy (PRK) have been utilized more successfully for correcting mild and moderate than high myopia and astigmatism.^{1–4} On the other hand, limit ablation in laser refractive surgeries makes them improper for correcting high myopia owing to possible postoperative

Financial Disclosure (s): The authors have no proprietary or commercial interest in any of the materials discussed in this article.

This paper was presented at the: 1, 3rd EuCornea Congress in Milan September 2012; 2, XXX Congress of the ESCRS in Milan September 2012; 3, ASCRS, San Francisco, USA, April 21th, 2013; 4, Poster presentation at the 2012 Joint Meeting of the American Academy of Ophthalmology; 5, Asia-Pacific Academy of Ophthalmology, November 10–13, in Chicago, Illinois.

* Corresponding author. Eye Research Center, Rassoul Akram Hospital, Iran University of Medical Sciences, and Iranian Eye Clinic, No. 86, 10th Boostan Street, Pasdaran Avenue, Tehran, 1666718853, Iran.

E-mail address: sj_hashemian@yahoo.com (S.J. Hashemian).

Peer review under responsibility of the Iranian Society of Ophthalmology.

<https://doi.org/10.1016/j.joco.2017.10.002>

2452-2325/Copyright © 2017, Iranian Society of Ophthalmology. Production and hosting by Elsevier B.V. This is an open access article under the CC BY-NC-ND license (<http://creativecommons.org/licenses/by-nc-nd/4.0/>).

corneal ectasia and haziness. Another problem of this approach for high myopia is possible postoperative higher-order aberrations (HOAs) most common of which is spherical aberration.^{5,6} FDA has accepted implantable collamer lenses (ICLs) for moderate and high myopia correction. These are also employed for astigmatism and hyperopia correction.^{7–9} According to some studies, using these lenses is more appropriate than laser surgeries from safety and efficiency view point.^{10,11} Since cornea remains prolate in IOL implantation and it becomes oblate in laser surgeries (LASIK & PRK), there are more possibilities of HOAs in cornea laser surgeries as compared to IOL implantation.¹² Despite several advances in laser surgeries and wave front-guided ablation or wave front-optimized ablation for myopia correction without HOA thereafter, some factors such as preoperative HOAs or cyclotorsional misalignment can affect the laser surgery results.¹³ Phakic IOLs owing to their optic properties as well as corneal incisions made during the surgery also create HOAs.¹⁴ Thus, although studies have shown less possibility of HOAs in phakic IOL implantation as compared to laser surgeries, there are few studies on extent of HOAs which resulted merely from phakic IOLs (including ICL). Only in CariPrez Vives' study, the effects of ICL on HOA were examined, and results demonstrated negative spherical aberration. In addition, simultaneous effects of ICL and corneal incision on HOA were studied by Sun Woong Kim's study, and results indicated both changes in spherical aberration due to ICL and changes in coma caused by different corneal incision. The aim of this study is to re-examine the effects of ICL and Toric ICL (TICL) on HOA.

Methods

This study is a prospective, interventional case series. We evaluated 33 eyes of 18 patients being operated from the years 2010–2011 in Rassoul Akram Hospital, Iran University of Medical Sciences, Tehran and Iranian Eye Clinic. This study was approved by the Ethics Committee of Iran University Eye Research Center. After explaining the advantages and disadvantages of surgery, all patients agreed to be operated and filled informed consent.

The subjects include 18 (54.4%) women and 15 (45.5%) men. The average age was 24.22 ± 3.21 years ranging from 20 to 34 years old. Myopia and astigmatism among the patients ranges from -6 to -21.09 and -0.5 to -4.75 diopters (D), respectively.

All patients underwent full ophthalmic examination. This examination includes: best corrected visual acuity (BCVA) in 12 mm vertex distance, uncorrected visual acuity (UCVA), manifest and cycloplegic refraction, slit-lamp examination and funduscopy with dilated pupil, Goldmann tonometry.

Anterior chamber depth (ACD) was measured by Orbscan (Orbscan II Z: Bausch & Lomb, Rochester, New York, USA) from endothelium to anterior surface of crystalline lens. Keratometry was performed via automated keratometry by Topcon Kr 8000.

Aberrometry and pupil measurement in mesopic condition was performed for all patients using Hartmannshack method by advanced personalized technology (APT, pv. Rochester, New York, USA). Placido disc topography (Eye sys 2000 version 4.2 Irvin USA) and endothelial cell count (non-contact specular microscope: Konan Medical Inc. Nishinomiya, Japan) was conducted for all patients.

All patients were examined on the 5th day, 2nd and 6th month after operation from BCVA and UCVA, and complete ocular examination point of view. Aberrometry of all patients was performed at 6 months postoperation.

Inclusion criteria include: white-to-white >11 mm, ACD >2.8 mm, iridocorneal angle $>30^\circ$, corneal endothelial cells in 20- to 30-year-old patients was at least 2500 cells/mm² and in 30- and 40-year-old patients was at least 2000 cells/mm².

Exclusion criteria were symptoms and history of uveitis, glaucoma, ocular hypertension, maculopathy, cataract, diabetes, progressing diseases except myopia, iris pigment defect, previous experience of ocular surgery, pregnancy scotopic pupil exceeding 7.5 mm, and less than 2 months or two times postoperative examinations.

Alignment of the TICL was evaluated by slit-lamp examination at all visits postoperatively. Vector analysis of keratometric astigmatism was conducted pre-operation and 6 months postoperation.

Implantable collamer lens sizing method

ICL sizing was made based on white-to-white measurement by caliper and slit-lamp, and also confirmed by Orbscan II. Direct measurement of sulcus to sulcus was made by UBM as described below.

UBM ciliary sulcus measurement

Topical tetracaine 0.5% (Sinadarou, Tehran, Iran) was instilled to anesthetize the cornea prior to measurement. One of the 3 differently sized eyecups (18, 20, and 22 mm) was inserted depending on the ocular aperture size. An eyecup was filled with sterile normal saline, and the subject was asked to fixate on a ceiling target with the fellow eye to maintain accommodation and fixation. Diameters of the ciliary sulcus were measured via a VuMax-II UBM (Sonomed, Inc. USA) equipped with a 35-MHz transducer. Cross-sectional images were obtained on the horizontal meridians: (180°), sulcus and anterior chamber (AC) diameters were measured in captured images using the zoom function to enhance the accuracy of angle and sulcus measurements.

All measurements were carried out under usual room light condition, and after capturing a video clip of the eye, the clip was reevaluated and the best-captured image was selected.

Surgical methods

In this study, the V4 ICL design (STAAR Surgical, Nidau, Switzerland) was implanted. All patients in this study were

operated on by a single surgeon (S.J.H). Under topical anesthesia, dilating and cycloplegic agents were administered. In temporal approach, one paracentesis was created, and after viscoelastic injection, a small 3 mm clear corneal incision was made, and ICL was injected via this wound to the AC and allowed to slowly unfold.

Distal, followed by proximal footplates were tucked under the iris with a modified intraocular spatula. Irrigation and aspiration of viscoelastic material was carried out by balanced salt solution. Intraocular miotic (Acetylcholine) was used to reduce pupil size. At the end of the surgical operation, peripheral iridectomy (PI) was carried out by vitrectomy probe (Storz Protégé, USA) with a 200 mmHg vacuum and 30 cuts per minute.

For TICL implantation, at first, the surgeon marked the zero horizontal and 270° vertical axis of cornea at a slit-lamp while the patient was upright for the prevention of cyclotorsion upon lying supine. Total procedure is such as spherical ICL implantation. After injecting TICL in the AC and unfolding of ICL, with the modified ICL manipulator, the proper motion was performed for posterior pressure and slight rotation of ≤1 clock hour. This maneuver was repeated for all 4 footplates. If any adjustment of TICL was necessary, gentle movement touching of the TICL at the junction of optic and haptic was accomplished.

TICLs were made to minimize rotation and required the surgeon to rotate the ICL not more than 22.5° (three fourths of a clock hour) from horizontal meridian.^{11,15} All TICL have an implantation diagram to demonstrate the amount and direction of rotation from the horizontal axis.

All patients were examined 2 h after operation to check for intraocular pressure (IOP), ICL vault and patent of surgical PI, ACD and position of ICL.

All patients have received topical eye drop betamethasone 0.1% (Sinadarou, Tehran, Iran) every 4 h and ciprofloxacin eye drop 0.3% (Sinadarou, Tehran, Iran) every 6 h for one week. Corticosteroid was continued for one-month postoperation after tapering. This technique has been previously described in detail.¹⁶

Statistical analysis

The data were analyzed using SPSS software (version 20). Normal distribution was checked using Kolmogorov-Smirnov test. If normal distribution present we used Pair T-test and if not we used Wilcoxon test. For controlling inter-ocular symmetry, generalized estimating equations (GEE) analysis was used. After 6 months, postoperative and preoperative parameters were compared. P-values less than 0.05 ($P < 0.05$) were considered statistically significant.

Results

In this study, 33 eyes of 18 patients were included. Ten patients (55.6) were women, and 8 patients (44.4%) were men. The mean age of the patients were 24.27 ± 3.21 years ranging from 20 to 34 years old. For 7 eyes (21.2%), ICL and for 26

Table 1

Demographic characteristics of patients undergoing implantable collamer lens (ICL) implantation.

Age (years)	
Mean \pm SD	24.27 \pm 3.21
Range	20–34
Sex (n)	
Male: female	8:10
Eyes (n)	
	33
Preoperative data	
Manifest sphere (D)	−8.12 \pm 2.87
Manifest cylinder (D)	−2.65 \pm 1.44
Manifest SE (D)	−9.45 \pm 2.55
logMAR BSCVA	0.17 \pm 0.20
6-month postoperative data	
Manifest sphere (D)	−0.12 \pm 0.48
Manifest cylinder (D)	−0.67 \pm 0.50
Manifest SE (D)	−0.45 \pm 0.46
logMAR BSCVA	0.08 \pm 0.14
Safety data of BSCVA	
Unchanged (n)	15
Gained 1 line (n)	11
Gained \geq 2 line (n)	7
Safety index	1.14 \pm 0.25

SD: Standard deviation, SE: Spherical equivalent.

BSCVA: Best spectacle corrected visual acuity, D: Diopter.

eyes (78.8%), TICL were used. Table 1 presents patient demographic data.

Six months after operation, results demonstrated no changes in BCVA of 15 eyes (45.5%), 1 line gain in 11 eyes (33.3%), 2 lines gain in 5 eyes (15.2%), 3 lines gain in 1 patient (3%), and 5 lines gain in 1 another eye (3%).

Mean spherical equivalent (SE) of eyes before surgery was -9.44 ± 2.55 ranging from -15.5 to 4.75 . Mean SE of eyes in 6th month of surgery was -0.45 ± 0.46 and ranging from -2.13 to $+0.25$. ($\beta = 8.99$, $P = 0.00$, GEE analysis). Preoperative mean cylinder of eyes was -2.65 ± 1.44 D ranging from -5.0 to -0.5 . This variable in the 6th month of operation was -0.66 , ranging -2.25 to 0.0 . ($\beta = 8.00$, $P = 0.00$, GEE analysis). Mean preoperative keratometry of eyes was 43.64 ± 1.64 D, ranging from 40.75 to 46.5 D. Mean postoperative keratometry of eyes was 43.87 ± 1.61 D, ranging from 40.55 to 46.80 D ($\beta = 0.03$, $P = 0.53$, GEE analysis).

Mean preoperative pachymetry of eyes was 520.39 ± 33.8 μ ranging from 450 to 570 μ . Results showed IOP increase in 3 eyes (9.1%) and misalignment of TICL in 3 eyes (9.1%). For the latter, realignment was done. Patients with high IOP received appropriate medication, and no patient required long-term medication for glaucoma.

Results related to aberration of eyes showed that mean difference of Zernike root mean square (RMS) higher order (6 mm pupil) and Total Zernike RMS were -0.02 ± 0.15 and -11.76 ± 3.04 , respectively. Table 2 presents preoperative and postoperative HOAs of eyes while Table 3 shows the differences of HOAs after implantation of ICL and TICL.

Fig. 1 shows comparison of pre and postoperative differences of HOAs in eyes. Regarding the positive and negative sign in table and graph, it must be considered that the zywave

Table 2

Preoperative and postoperative higher-order aberrations (HOAs) in patients undergoing implantable collamer lens (ICL) insertion using generalized estimated equation (GEE) analysis.

	Pre-op	Post-op	B coefficient	P value
Zernike RMS*-High Order 6 mm	0.42 ± 0.16	0.39 ± 0.12	−0.25	0.354
Zernike RMS-HO w/o Z400 6 mm	0.37 ± 0.15	0.36 ± 0.12	−0.011	0.677
Zernike RMS-Total	13.16 ± 3.29	1.39 ± 0.84	−11.76	0.000
45 Astigmatism-Z221	0.22 ± 1.36	0.23 ± 0.64	0.011	0.953
Defocus-Z200	−12.79 ± 3.45	−0.66 ± 0.82	12.130	0.000
0 Astigmatism-Z220	2.19 ± 1.28	0.62 ± 0.70	−1.53	0.000
Vertical trefoil-Z331	0.108 ± 0.15	0.088 ± 0.16	−0.020	0.499
Vertical coma-Z311	−0.053 ± 0.24	−0.061 ± 0.16	−0.007	0.779
Horizontal coma-Z310	−0.021 ± 0.20	0.007 ± 0.13	0.028	0.124
Horizontal trefoil-Z330	−0.0104 ± 0.10	−0.031 ± 0.20	−0.021	0.362
Quadrafoil-Z441	0.004 ± 0.06	0.064 ± 0.06	0.060	0.000
2nd Astigmatism-Z421	0.018 ± 0.06	−0.006 ± 0.03	−0.025	0.004
4th order spherical aberration-Z400	−0.043 ± 0.19	0.020 ± 0.15	0.063	0.000
2nd Astigmatism-Z420	0.021 ± 0.07	0.002 ± 0.06	−0.019	0.238
Quadrifoil-Z440	0.008 ± 0.07	0.043 ± 0.07	0.035	0.006
Pentafoil-Z551	0.001 ± 0.03	−0.009 ± 0.05	−0.010	0.194
2nd Vertical trefoil-Z531	−0.004 ± 0.03	0.004 ± 0.03	0.009	0.143
2nd Vertical coma-Z511	0.004 ± 0.02	0.008 ± 0.03	0.004	0.537
2nd Horizontal coma-Z510	0.010 ± 0.03	0.012 ± 0.03	0.002	0.738
2nd Horizontal trefoil-Z530	0.007 ± 0.03	0.001 ± 0.02	−0.007	0.178
Pentafoil-Z550	0.002 ± 0.02	0.002 ± 0.03	0.000	0.974

RMS: Root-mean-square wavefront errors.

Table 3

Comparison of preoperative and postoperative higher-order aberrations (HOAs) in two groups of patients undergoing implantable collamer lens (ICL) insertion using generalized estimated equation (GEE) analysis.

	ICL		TICL		B coefficient	P value
	Pre-op	Post-op	Pre-op	Post-op		
Vertical coma-Z311	0.12 ± 0.19	0.05 ± 0.12	−0.10 ± 0.23	−0.09 ± 0.16	0.125	0.01
Horizontal coma-Z310	−0.05 ± 0.20	0.01 ± 0.14	−0.01 ± 0.21	0.005 ± 0.13	−0.014	0.74
4th order spherical aberration-Z400	−0.07 ± 0.15	0.02 ± 0.14	−0.04 ± 0.20	0.02 ± 0.16	−0.019	0.63
Vertical trefoil-Z331	0.15 ± 0.17	0.07 ± 0.22	0.09 ± 0.14	0.09 ± 0.15	0.008	0.89
Horizontal trefoil-Z330	−0.01 ± 0.10	−0.07 ± 0.24	−0.01 ± 0.11	−0.02 ± 0.19	0.024	0.28

ICL: Implantable collamer lens, TICL: Toric implantable collamer lens, Pre-op: Preoperative, Post-op: Postoperative.

sign (positive or negative) is reverse compared with other aberrometers.

Discussion

Previously, few studies had been carried out on ICL and TICL effects on HOAs, and this study is one of the few studies on the mere effect of ICL and TICL on HOAs. The efficacy and safety of these IOLs were shown in this study.

Results demonstrated that implantation of these lenses induced negative spherical aberration, and the effect of these lenses on the other HOA was negligible.

Preoperative spherical aberration in our study was 0.043 μ and with a decrease of 0.023 μ reached 0.020 μ postoperatively. The results were low as compared to the study by Salmon et al. on normal population that revealed 0.13 μ in normal population.¹⁵ The amount of spherical aberration preoperatively was exactly the same as another study by Sun Woong Kim et al.

In this study, all patients were evaluated for surgical induced corneal astigmatism. Vector analysis of corneal astigmatism was evaluated and revealed that there was no significant induction of neither corneal astigmatism nor HOAs postoperatively.

This implies that all changes of HOAs were due to the special structure of ICL and TICL.

In a study by Sun Woong Kim et al., which deals with ICL as well as corneal incision effects on HOAs results, the case of small corneal incision group demonstrated significant changes in both trefoil and spherical aberration. For the large corneal incision group, alongside the changes observed in the small corneal incision group, results demonstrated significant changes in total HOA. In that study, negative spherical aberration was created due to ICLs' special structure, and trefoil aberration was caused by large corneal incisions.¹⁷

Another study by Cari Perez Vives et al. on ICL effects on optical quality and in different pupil sizes showed that ICL increases negative spherical aberration but has no effect on

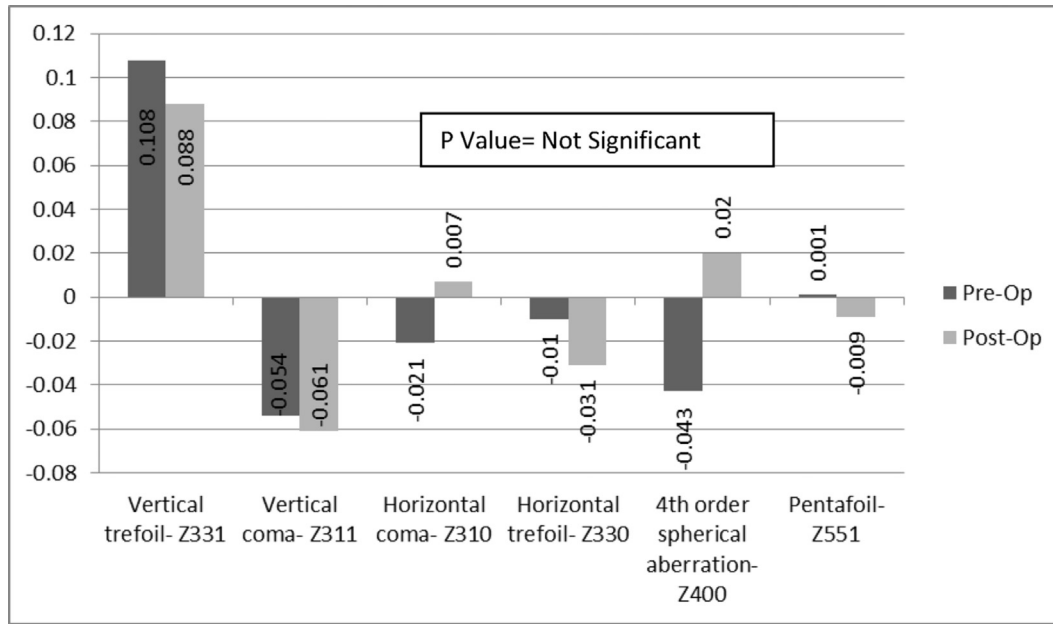


Fig. 1. Bar graphs showing the root mean square (RMS) changes in higher-order aberration (HOA) pre and postoperation.

other aberrations. The magnitude of spherical aberration was directly correlated with the amount of refractive power of ICL. According to this study, at 3-mm pupil size, no statistically significant differences were observed between ICLs for any HOAs. At 4.5-mm pupil size, spherical aberration increased significantly.¹⁸

Another study by Hidemasa Tori et al. on patients using artisan and artiflex lenses showed increase of positive spherical aberration in 6-mm pupils. It also showed more increase of positive spherical aberration in artisan group than artiflex group.¹⁹

Among other studies on other phakic IOL, the study by Antonio Toso et al. on Acrysof Cachet angle supported lenses showed that these lenses increase negative spherical aberration.²⁰

In our study, preoperative total HOA of eyes was 0.4179 μ , which without any significant change reached 0.3933 μ post-operatively (P = 0.359).

The other critical aberrations such as vertical coma (Z_3^{-1}) and horizontal coma (Z_3^1) had no significant changes. Significant postoperative astigmatism changes in three patients were for TICL misalignments. These misalignments were corrected immediately, and finally, we had no patient with astigmatism.

Since aberrations such as coma are found in patients with induced decentered laser ablation or decentered corneal graft and/or patients suffering from keratoconus,²¹ in all of which there are various kinds of asymmetry, an increase of coma cannot be expected in patients under phakic IOL operation (like ICL), who have correct lens centration. Nevertheless, spherical aberration, which results from different focusing of beam rays on peripheral and central part of an optical system

and may be a result of lens structure, can be justified in phakic IOL patients. Since the power of vertical and horizontal axis is different in TICL patients, non-spherical aberration as a result of astigmatism correcting lens structure is expected; nevertheless, in these patients, like ICL patients, only spherical aberration changes are significantly found because the summation of different rays is zero.

Although the study of Hidemasa Tori et al. demonstrated positive spherical aberration after the implantation of artisan and artiflex, most of the previous studies on either ICLs and TICLs or other phakic IOLs, like Cachet IOL, led to negative spherical aberration.

This study demonstrated significant increase in negative spherical aberration after ICLs and TICLs implantation, which was probably for these lenses' structure. As cornea and crystalline lens have typically positive and negative spherical aberration, respectively, and their total outcome is zero and implantation of ICLs and TICLs results in increase of negative spherical aberration, the style of these lenses should be aspheric. Otherwise, a preoperative aberrometry of patients can determine their individual HOA and then decide to insert the appropriate phakic IOL based on patient HOAs. That is, if the patients already have positive spherical aberration, the phakic IOL with negative spherical aberration will compensate positive spherical aberration of the patient and vice versa.

The limitation of this study may be the small sample size. Obviously, the more patients, the more accurate results.

This study shows that ICL and TICL performed well in correcting high myopic astigmatism without significant changes in HOAs during a 6.0 months observation period, although the spherical aberration (Z400) increased significantly.

Acknowledgments

Authors wish to especially acknowledge the respected staff of Eye Research Center and Iranian Eye Clinic for facilitating the evaluation of postoperative patients and the Radan Company for their English editing service.

References

- Greer D, Rosa N. Excimer laser photorefractive keratectomy (PRK) for myopia and astigmatism. *Ophthalmology*. 1999;106(2):422–437.
- Sugar A, Rapuano CJ, Culberston WW, et al. Laser in keratomileusis for myopia situ and astigmatism: safety and efficacy: a report by the American Academy of Ophthalmology. *Ophthalmology*. 2002;109(1):175–187.
- Schallhorn SC, Farjo AA, Huang D, et al. Wavefront-guided LASIK for the correction of primary myopia and astigmatism a report by the American Academy of Ophthalmology. *Ophthalmology*. 2008;115(7):1249–1261.
- Tabbara KF, Kotb AA. Risk factors for corneal ectasia after LASIK. *Ophthalmology*. 2004;113(9):1618–1622.
- Hers PS, Fry K, Blacker JW. Spherical aberration after laser in situ keratomileusis and photorefractive keratectomy. Clinical result and theoretical models of etiology. *J Cataract Refract Surg*. 2003;29(11):2096–2104.
- Yoon G, Macrac S, Williams DR, Cox IG. Cause of spherical aberration induced by laser refractive surgery. *J Cataract Refract Surg*. 2005;31(1):127–135.
- Sanders DR, Vukich JA, Doney K, Gaston M. Implantable contact lens in treatment of myopia study group. Food and Drug Administration clinical trial of the implantable contact lens for moderate to high myopia. *Ophthalmology*. 2003;110(2):255–266.
- Sanders DR, Doney K, Poco M, ICL in Treatment of Myopia Study Group. United States Food and Drug Administration clinical trial of the Implantable Collamer Lens (ICL) for moderate to high myopia three-year follow up. *Ophthalmology*. 2004;111(9):1683–1692.
- Davidof JM, Zaldivar R, Oscherow S. Posterior chamber phakic intraocular lens for hyperopia of +4 to +11 diopters. *J Refract Surg*. 1998;14(3):306–311.
- Sanders DR, Vukich JA. Comparison of implantable contact lens and laser assisted in situ keratomileusis for moderate to high myopia. *Cornea*. 2003;22(4):324–331.
- Kmiya K, Shimizu K, Igarashi A, Komatsu M. Comparison laser in situ keratomileusis for high myopic astigmatism. *J Cataract Refract Surg*. 2008;34(12):1687–1693.
- Gatinel D, Adam PA, Chaabouni S, et al. Comparison of corneal and total ocular aberration before and after myopic LASIK. *J Refract Surg*. 2010;26(5):333–340.
- Subbaram MV, MacRae SM. Customized LASIK treatment for myopia based on preoperative manifest refraction and higher order aberrometry: the Rochester nomogram. *J Refract Surg*. 2007;30(3):633–638.
- Sarver FJ, Sanders DR, Vukich JA. Image quality in myopic eyes corrected with laser in situ keratomileusis and phakic intraocular lens. *J Refract Surg*. 2003;19(4):397–404.
- Salmon TO, van de pol C. Normal-eye Zernike coefficients and root mean square wave front errors. *J Cataract Refract Surg*. 2006;32(12):2064–2074.
- Hashemian SJ, Bigzadeh F, Foroutan A, Tajoddini S, Ghaempanah MJ, Jafari ME. Outcome and complication of implantable collamer lens and Toric implantable collamer lens for the correction of high myopia with and without astigmatism (one year prospective study). *Iran J Ophthalmol*. 2013;25(1):8–18.
- Kim SW, Yang H, Yoon G, et al. Higher-order aberration changes after implantable collamer lens implantation for myopia. *Am J Ophthalmol*. 2011;151(4):653–662.
- Pérez-Vives C, Domínguez-Vicent A, Ferrer-Blasco T, Pons ÁM, Montés-Micó R. Optical quality of the visian implantable collamer lens for different refractive powers. *Graefes Arch Clin Exp Ophthalmol*. 2013;251(5):1423–1429.
- Torii H, Negishi K, Watanabe K, Saiki M, Kato N, Tsubota K. Changes in higher-order aberrations after iris-fixated phakic intraocular lens implantation. *Refract Surg*. 2013;29(10):693–700.
- Toso A, Morselli S. Visual and aberrometric outcomes in eyes with an angle supported phakic intraocular lens. *J Cataract Refract Surg*. 2012;38(9):1590–1594.
- Klyce SD, KaronSmolek MK. Advantages and disadvantages of the Zernike expansion for representing wave aberration of the normal and aberrated eye. *J Refract Surg*. 2004;20(5):S537–S541.