

Contents lists available at [ScienceDirect](http://www.sciencedirect.com)

International Journal of Surgery Case Reports

journal homepage: www.casereports.com

A case report of a groin pseudocyst following inguinal hernia repair and a review of the literature



Juan Favela, Sergio Huerta*

University of Texas Southwestern Medical Center and VA North Texas Health Care System, United States

ARTICLE INFO

Article history:

Received 18 May 2018

Accepted 11 July 2018

Available online 26 July 2018

Keywords:

Inguinal hernia

Bassini repair

Lichtenstein repair

ABSTRACT

INTRODUCTION: Groin hernias are one of the most common general surgery operations performed worldwide and in the United States. We present an exceedingly unusual complication of a patient who underwent a posterior repair of an inguinal hernia.

PRESENTATION: A 48-year-old man presented to our hospital with a chronically enlarging left groin mass for five years following a total extraperitoneal repair of a unilateral inguinal hernia. Two separate aspiration interventions led to rapid re-accumulation of the fluid. Physical exam demonstrated a large inguinoscrotal mass in the left groin. It was non-tender and there were no overlying skin changes. His testicles were palpable at the bottom of the scrotum. A computed tomography exam demonstrated evidence of a prior left inguinal hernia repair. The left groin/scrotum had a 12 cm fluid collection with incomplete peripheral calcification, consistent with previous history of seroma. An indirect hernial sac could not be excluded from the diagnosis. During groin exploration an inguinal canal pseudocyst was removed in its entirety without violating the capsule. The patient recovered well; there was no recurrence at a six month follow up. Review of the literature revealed that only two other cases had been reported, but in contrast to our case, the previous cases had an anterior repair for the index operation and the pseudocysts were open and partly resected.

CONCLUSION: Post-operative inguinal pseudocysts are exceedingly rare. Our case is the third reported in the literature. They can develop following open and laparoscopic mesh repair. Surgical intervention is required for definitive management.

Published by Elsevier Ltd on behalf of IJS Publishing Group Ltd. This is an open access article under the CC BY-NC-ND license (<http://creativecommons.org/licenses/by-nc-nd/4.0/>).

1. Introduction

Worldwide, over 20 million groin hernias are repaired every year [1]. In the United States alone, groin hernias constitute one of the most common operations undertaken by general surgeons in private practice and academic institutions, accounting for 800,000 procedures annually [2]. Up to 48 billion dollars on health care were the result of cost for caring for patients with groin hernias in 2005 [2]. Therefore, understating all aspects of this operation is important for the general surgeon and the health care provider.

Substantial complications following groin hernia repair are uncommon, but inguinaldynia, recurrence, urinary retention, hematoma and infection are important adverse effects from this intervention [3]. While the use of mesh has considerably reduced the rate of recurrence, unusual complications have emerged from this strategy. For instance, mesh migration is an unusual, but vexing clinical problem [4].

Pseudocysts are distinguished from cysts in that the former lack an epithelial lining [5]. Instead, pseudocysts are characterized by a fibrous rim of tissue that has encapsulated a chronic fluid collection and are common entities following acute pancreatitis [5]. While seromas are common complications of groin hernia repair, a groin pseudocyst is exceedingly rare. In the present report, we discuss a patient who had a pseudocyst after surgical exploration of the inguinal canal and present a review of the literature on the topic.

2. Methods

This is a case report of a patient who presented with this disease at the VA North Texas Health Care System (VANTHCS). The medical records were reviewed for this patient in the computer patient record system. Informed consent was obtained from the patient for the publication of this report. This work has been reported in line with the SCARE criteria [6].

We also undertook a review of the literature to determine if there were previous cases published. PubMed and MEDLINE were searched for relevant articles in the English literature. We also employed Ovid syntax from 1949 to January 2010, the Cochrane Library, Google and Google Scholar.

* Corresponding author at: University of Texas Southwestern, 4500 S. Lancaster Road, Dallas, TX, 75216, United States.

E-mail address: Sergio.Huerta@UTSouthwestern.edu (S. Huerta).

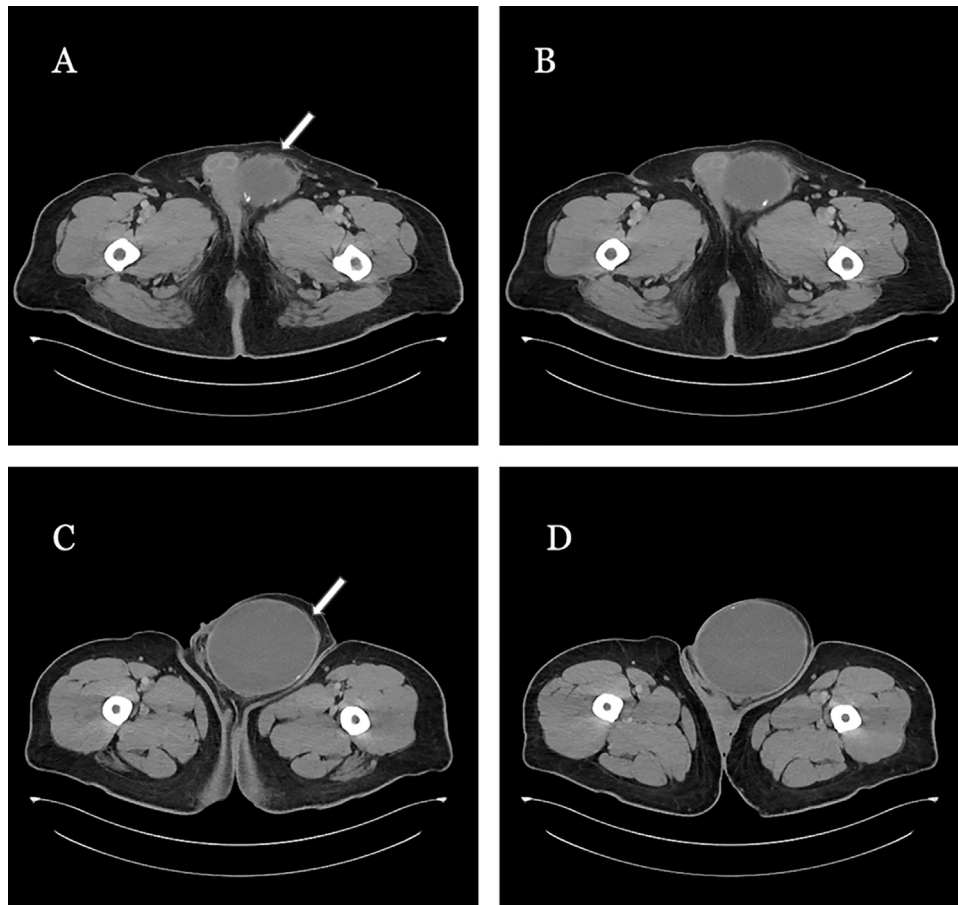


Fig. 1. Computed tomography demonstrating an inguinal canal lesion. There was evidence of a prior repair (panel A; arrow). There is a well-circumscribed 12.0 cm fluid collection. A fibrous capsule vs. hernia sac is demonstrated (panel C; arrow).

2.1. Case report

A 48-year-old man with a past medical history significant for gastroesophageal reflux disease (GERD) presented to the VANTHCS General Surgery service as a consult from the Urology service due to a large left inguinal/scrotal mass that caused him significant discomfort and pain with walking. It also limited his sexual activity. The patient had previously undergone a laparoscopic left inguinal hernia repair (total extraperitoneal approach) with mesh at an outside hospital in 2012. Soon after that surgery, the patient developed a large fluid collection which was aspirated by the general surgeon in charge of that operation on two separate occasions. Unfortunately, the seroma did not resolve. The diagnosis of recurrent left inguinal hernia vs. hydrocele was entertained.

On physical exam, the patient was in no acute distress. His vital signs demonstrated a temperature of 97.9°F (36.6°C), heart rate of 87 beats per minute, and a blood pressure of 132/74 mm/Hg. His cardiovascular and pulmonary exams were unremarkable. His abdomen was soft, non-tender, and non-distended. He had a large inguinoscrotal mass in the left groin. It was non-tender and there were no overlying skin changes. His testicles were both palpable at the bottom of the scrotum.

Laboratory data revealed a hematocrit of 35.5%, hemoglobin of 11.2 g/dL, and a white count of 10.2 K/uL. His creatinine was 0.65 mg/dL, potassium 3.8 mmol/L, and a sodium of 140 mmol/L. His liver function tests were within normal limits.

A computed tomography exam demonstrated evidence of a prior left inguinal hernia repair. The left groin/scrotum had a 12 cm fluid collection with incomplete peripheral calcification, consistent

with previous history of seroma. A small left hydrocele was also observed (Fig. 1). An indirect hernial sac could not be excluded from the diagnosis.

The patient was then taken to the operating room for a left groin exploration with the possible diagnosis of a recurrent left inguinal hernia. In the operating room, a groin exploration was performed by making an incision two thirds of the distance between anterior superior iliac spine and the pubic tubercle. The tissues were then taken down to the aponeurosis of the external oblique muscle. Sharp dissection exposed the cord structures and a Penrose was utilized to obtain circumferential access around these. A 12.0 × 9.0 × 7.0 cm cystic lesion with a well circumscribed capsule was identified and delivered into the wound. The testicles were identified, and we proceeded with exploration of the cord structures to identify the hernia sac. The cystic lesion followed the path of an indirect hernial sac located anterior and medial onto the cord structures. It was unclear if this was a fluid-filled indirect hernia sac. Careful blunt dissection was employed to remove the adhesions of the cystic lesion from the scrotum until the entirety of the cyst was delivered into the wound (Fig. 2, panel A). The cystic lesion was entirely resected from the cord structures and no intraperitoneal connection was found (Fig. 2; panel C). There was no indirect hernia sac and the floor appear to be intact, but weak. We elected to enforce the floor by bringing the conjoint tendon to the shelving edge of the inguinal ligament with 0-polydioxanone (PDS) sutures in a figure of eight fashion. The external oblique aponeurosis was closed with a 2–0 Vicryl suture, the Scarpa's fascia with 3–0 Vicryl and the skin with 4–0 Monocryl. At the end of the operation, 10 mL of 0.25% bupivacaine with epinephrine (1:200,000) was infiltrated

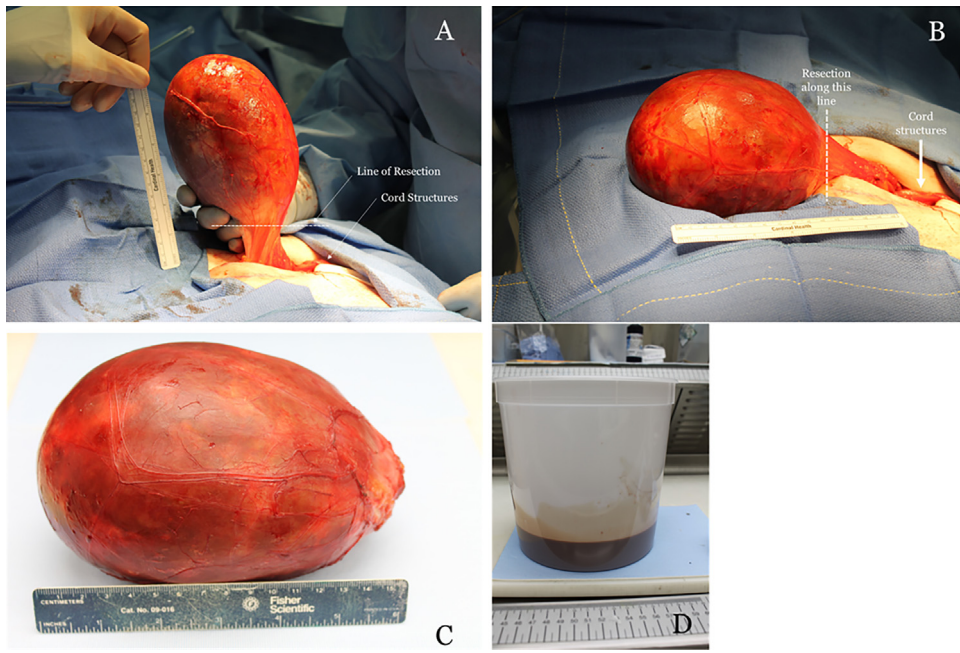


Fig. 2. Inguinal hernia pseudocyst. Approximately 750 mL of serosanguinous fluid were contained within the fibrous capsule (panel D).

Table 1 Patient characteristics of the literature review and the current case.

	Age (years-old)	Gender	Hernia Type (Index operation)	Laterality	Diameter of pseudocyst (cm)	Repair Type (Index operation)	Onset (months)	Surgical Approach to address pseudocyst	Reference
Patient 1	63	Male	Direct	Left	10	Anterior Repair (Lichtenstein)	5	Partial cystectomy	[7]
Patient 2	61	Male	Direct	Left	11	Anterior Repair (Lichtenstein)	7	Partial cystectomy	[7]
Patient 3	48	Male	Indirect	Left	12	Posterior Repair (TEP)	60	Excisional biopsy	Current

along the hernia incision. The patient was discharged home following recovery the same day after the operation. Oral opioids were prescribed (hydrocodone bitartrate and acetaminophen; NORCO) for the postoperative period. There were no intra-operative complications. The patient recovered well from the operation and was discharged home on the same day. He was doing well at a two-week postoperative visit in the surgery clinic. Pathological examination of the specimen demonstrated a pseudocyst with a thick, uniloculated fibrous capsule, filled with serofibrinous fluid containing histiocytes; clinically seroma (Fig. 2d). The specimen was negative for malignancy. Review of the electronic medical records demonstrated that he had been seen six months after the operation by his primary care physician for routine follow up. No issues related to the groin exploration or removal of the groin pseudocyst were identified.

2.2. Review of the literature

A comprehensive review of the literature revealed a previously published paper which included two similar cases [7]. The characteristics of these patients and the one of the current report are presented in Table 1.

3. Discussion

Surgical complications after inguinal hernia repair are important to recognize early such that further morbidity can be minimized. The introduction of mesh for the repair of inguinal repair has clearly minimized the rate of recurrence [8]. How-

ever, other complications have emerged from the common used of prosthetic materials utilized for the repair of inguinal hernias. In general, about 10% of patients will experience chronic post-operative pain after the repair of an inguinal hernia where mesh has been utilized [8]. Other complications of inguinal hernia repair occur commonly both in the laparoscopic and open approach and include hematomas and seromas (~8% risk), wound infection (~1% risk), and rarely testicular atrophy [8]. The use of mesh has also led to other complications that, while rare, may present a complex clinical management [4].

Fluid collections might occur after surgical intervention or inflammation. Fluid collections following an acute episode of pancreatitis are common. If they persist for several weeks a fibrous rim might develop; thereby encapsulating amylase rich fluid and leading to the formation of a pancreatic pseudocyst [5]. Fluid collections after an inguinal hernia repair are not uncommon, but rather than amylase, these fluid collections contain serosanguinous fluid and nearly always resolve without intervention [3]. In our practice of 953 inguinal hernias, four clinically significant seromas were encountered [3]. We typically do not attempt to drain these seromas as the sterile fluid collection might become infected.

Chronic fluid collections leading to an inguinal canal pseudocyst are exceedingly rare with only two previous cases reported [7]. In contrast to the previously reported case, the patient in the present report had undergone a laparoscopic inguinal hernia repair rather than a Lichtenstein approach as reported by Ielpo et al. In their experience, this Spanish group found that the pseudocyst was incorporated onto the anteriorly placed mesh. They opened the cyst intraoperatively and placed drains with a successful outcome [7].

In the present case, we found no incorporation of the mesh to the cystic lesion. We performed a complete excisional biopsy without violating the fibrous capsule. The patient did well and there has been no hernia recurrence or fluid collections almost a year from the intervention.

Post-operative inguinal hernia pseudocyst are extremely uncommon, but surgical intervention is required for their management. Aspiration is only palliative and might lead to other complications including infection, which might complicate complete excisional biopsy. Inguinal canal pseudocysts can occur following anterior and posterior hernia repair. Understanding the possibility of this complication and the management might allow a more rapid intervention to patients affected by this unusual clinical entity.

Conflicts of interest

None of the authors have any interest to disclose.

Source of funding

No funding was provided for the production of this manuscript.

Ethical approval

The VA North Texas Health Care System exempted this from Institutional Review Board Committee Review. No further approval for publication are required.

Consent

Informed consent was obtained from the patient and it is available upon request.

Author contributions

Juan Favela, BA → drafting and revising of the manuscript.

Sergio Huerta, MD → drafting, revising of the manuscript and participated in the care of the patient.

Registration of research studies

N/A.

Guarantor

Sergio Huerta, MD.

References

- [1] A. Kingsnorth, K. LeBlanc, Hernias: inguinal and incisional, *Lancet* 362 (2003) 1561–1571.
- [2] I.M. Rutkow, Epidemiologic, economic, and sociologic aspects of hernia surgery in the United States in the 1990s, *Surg. Clin. North Am.* 78 (1998) 941–951, v–vi.
- [3] S. Huerta, P.M. Patel, A.A. Mokdad, J. Chang, Predictors of inguinodynia, recurrence, and metachronous hernias after inguinal herniorrhaphy in veteran patients, *Am. J. Surg.* 212 (2016) 391–398.
- [4] H.B. Cunningham, S. Kukreja, S. Huerta, Mesh migration into an inguinal hernia sac following a laparoscopic umbilical hernia repair, *Hernia* 22 (4) (2018) 715–720.
- [5] A. Andren-Sandberg, C. Dervenis, Pancreatic pseudocysts in the 21st century. Part I: classification, pathophysiology, anatomic considerations and treatment, *JOP* 5 (2004) 8–24.
- [6] R.A. Agha, A.J. Fowler, A. Saeta, et al., The SCARE statement: consensus-based surgical case report guidelines, *Int. J. Surg.* 34 (2016) 180–186.
- [7] B. Ielpo, F. Lapuente, P. Martin, et al., First cases of giant pseudocyst complicating inguinal hernia repair, *Hernia* 16 (2012) 589–591.
- [8] R.J. Fitzgibbons Jr., R.A. Forse, Clinical practice. Groin hernias in adults, *N. Engl. J. Med.* 372 (2015) 756–763.

Open Access

This article is published Open Access at [sciencedirect.com](https://www.sciencedirect.com). It is distributed under the [IJSCR Supplemental terms and conditions](#), which permits unrestricted non commercial use, distribution, and reproduction in any medium, provided the original authors and source are credited.