

## Development of ocular hypertension secondary to tamponade with light versus heavy silicone oil: A systematic review

Vito Romano<sup>1,2</sup>, Mario Cruciani<sup>3</sup>, Francesco Semeraro<sup>4</sup>, Ciro Costagliola<sup>5</sup>, Mario R Romano<sup>6</sup>

**Aim:** The intraocular silicone oil (SO) tamponades used in the treatment of retinal detachment (RD) have been associated with a difference ocular hypertension (OH) rate. To clarify, if this complication was associated to use of standard SO (SSO) versus heavy SO (HSO), we performed a systematic review and meta-analysis of comparative study between two kind of SO (standard or light vs. heavy) for the treatment of RD and macular hole, without restriction to study design. **Materials and Methods:** The methodological quality of two randomized clinical trials (RCTs) were evaluated using the criteria given in the Cochrane Handbook for Systematic Reviews of Intervention, while three non-RCTs were assessed with the Newcastle–Ottawa Scale and Strengthening the Reporting of Observational Studies in Epidemiology checklists. We calculated Mantel–Haenszel risk ratio (RR) with 95% confidence intervals (95% CIs). The primary outcome was the rate of patients with OH treated with SSO compared to HSO. **Results:** There were a higher number of rates of OH in HSO compared to SSO. This difference was statistically significant with the fixed effect model (Mantel–Haenszel RR; 1.55; 95% CI, 1.06–2.28;  $P = 0.02$ ) while there was not significative difference with the random effect model (Mantel–Haenszel RR; 1.51; 95% CI, 0.98–2.33;  $P = 0.06$ ). **Conclusion:** We noted a trend that points out a higher OH rate in HSO group compared to SSO, but this finding, due to the small size and variable design of studies, needs to be confirmed in well-designed and large size RCTs.

**Key words:** Glaucoma, heavy silicone oil, light silicone oil, ocular hypertension, retinal detachment, standard silicone oil

The silicone oils (SOs) are intraocular tamponades diffusely used in the treatment of retinal detachment (RD) and macular hole.<sup>[1–5]</sup> The ocular hypertension (OH) has been also reported in literature after pars plana vitrectomy (PPV) and SO injection, with an incidence ranging from 3% to 40% of cases.<sup>[4,6–10]</sup> Since there is the need to support the retina in any quadrant nowadays, there are two kind of SOs available: (i) Standard SO (SSO), that has lower density than water, providing a good support for the superior retina; (ii) heavy SO (HSO), that has a heavier density than water, making it able to provide an effective postoperative tamponade of the inferior quadrants. HSO is a mixed compound obtained by adding SO to the semifluorurate (alkane or ether) in a miscible ratio. The presence of semifluorinate should make the compound more unstable and prone to induce emulsification and increase of intraocular pressure (IOP). Although using of HSO in case of inferior retinal breaks or macular hole, reduces the RD's recurrence<sup>[11]</sup> and provides to high success rate of macular hole closure,<sup>[12]</sup> several case series report a different rate of increase of postoperative IOP, with an incidence ranging from 14% to

30.7% of cases.<sup>[13–15]</sup> The OH represents an important risk factor for both SSO and HSO, which can lead to the development of secondary glaucoma.<sup>[16,17]</sup> To clarify, if this complication was associated to the type of SO, several studies have been conducted,<sup>[18–22]</sup> nevertheless they have reduced statistical power and discordant results. Therefore, a systematic review was needed to clarify this issue.

### Materials and Methods

We searched MEDLINE, EMBASE, Scopus and Google Scholar for studies that comparing the OH rate in patients treated with HSO with those treated with SSO for RD. Any study comparing HSO with SSO for RD, without restriction to study design or language, was included. The keywords used in the search were “SO”, “HSO” and “RD and SO”. We performed the final search on December 23, 2013.

Three authors (VR, FS, MRR) independently screened for potential relevance the titles and abstracts of studies to identify those that fulfilled the inclusion criteria: Patient treated with SO, vitrectomy surgery with tamponades, comparison on the complications of HSO versus SSO, and IOP.

Disagreements or doubts were resolved by discussion. We obtained in full, any study that potentially meets the inclusion criteria based on the title, abstract or both and assessed these studies against the inclusion criteria.

The following data were extracted independently by three reviewers (VR, FS, MRR): Administrative details (authors, year of publication), details of participants (number, setting, baseline characteristics by group), details of the study (study design and type), details of IOP after surgery, outcome descriptions and outcomes measures in each group with reasons.

#### Access this article online

##### Website:

www.ijo.in

##### DOI:

10.4103/0301-4738.156922

#### Quick Response Code:



<sup>1</sup>Department of Ophthalmology, Second University of Naples, Naples, Italy, <sup>2</sup>Department of Corneal and External Eye Diseases, St. Paul's Eye Unit, Royal Liverpool University Hospital, Liverpool, United Kingdom, <sup>3</sup>Center of Community Medicine and HIV Outpatient Clinic, Infectious Diseases Unit, San Bonifacio Hospital, Verona, <sup>4</sup>Department of Ophthalmology, University of Brescia, Brescia, <sup>5</sup>Department of Medicine and Health Sciences, University of Molise, Campobasso, <sup>6</sup>Department of Neuroscience, University Federico II, Naples, Italy

**Correspondence to:** Dr. Vito Romano, Via Posillipo, 390 80123, Naples, Italy. E-mail: vito.romano@gmail.com

**Manuscript received:** 07.07.14; **Revision accepted:** 18.02.15

The data abstracted for dichotomous variables are the number of eye with OH. When additional data were needed, we contacted the corresponding author of each study by E-mail in order to access further information.

Three authors (VR, FS, MRR) independently assessed studies fulfilling the review inclusion criteria for methodological quality. For randomized clinical trials (RCTs), we used the criteria given in the Cochrane Handbook for Systematic Reviews of Intervention.<sup>[23]</sup> The risk of bias was assessed in individual studies across six domains: Random sequence generation, allocation concealment, blinding of participants and personnel (performance bias), blinding of outcome assessors (detection bias), incomplete outcome data, selective outcome reporting. We categorized these judgments as “low risk”, “high risk”, or “unclear” risk of bias.

For observational studies, we used two commonly adopted checklists, the Newcastle–Ottawa Scale (NOS) and the Strengthening the Reporting of Observational Studies in Epidemiology (STROBE) checklists, from which two reading grids were adapted.<sup>[24–26]</sup> The NOS is a nine-point scale that assigns points on the basis of the process of selection of the cohorts or the cases and the controls (0–4 points), the comparability of the cohorts or the cases and the controls (0–2 points), and the identification of the exposure and the outcomes of study participants (0–3 points). The NOS was developed to assess the quality of nonrandomized studies for the purpose of incorporating quality assessments in the interpretation of meta-analytic results. This scale is recommended by the Cochrane Non-randomized Studies Methods Working Group available at the electronic address ([http://www.ohri.ca/programs/clinical\\_epidemiology/oxford.htm](http://www.ohri.ca/programs/clinical_epidemiology/oxford.htm)). STROBE is an international, collaborative initiative of epidemiologists, methodologists, statisticians, researchers and editors involved in the conduct and dissemination of observational studies. The STROBE statement consists of a checklist of 22 items, which relate to the title, abstract, introduction, methods, results and discussion sections of articles. Eighteen items are common to cohort studies, case–control studies and cross-sectional studies and four are specific to each of the three study designs. The STROBE statement provides guidance to authors about how to improve the reporting of observational studies and facilitates critical appraisal and interpretation of studies by reviewers, journal editors and readers.

We assessed statistical heterogeneity using  $\tau^2$ , Cochran’s  $Q$  and the  $I^2$  statistic. The  $I^2$  statistic describes the percentage of total variation across trials that are due to heterogeneity rather than sampling error.<sup>[27,28]</sup>

Dichotomous outcomes (e.g. rate of patients with OH) are presented as risk ratios (RRs) with 95% confidence intervals (CIs). The software used was Review Manager (RevMan, Version 5.3, The Nordic Cochrane Centre, The Cochrane Collaboration, Copenhagen, Denmark, 2014). In case of no heterogeneity ( $I^2 = 0$ ), studies were pooled using a fixed effect model. Where values of  $I^2$  were  $> 0$ , a random effects analysis was undertaken.<sup>[23,29]</sup> In addition, both the random effects and the fixed model will be used as a sensitivity analysis for evaluating the possible bias effects of smaller studies.

Where values of  $I^2 > 75\%$  indicated a very high level of heterogeneity, we refrained to pool data from different studies and we undertook a narrative overview.

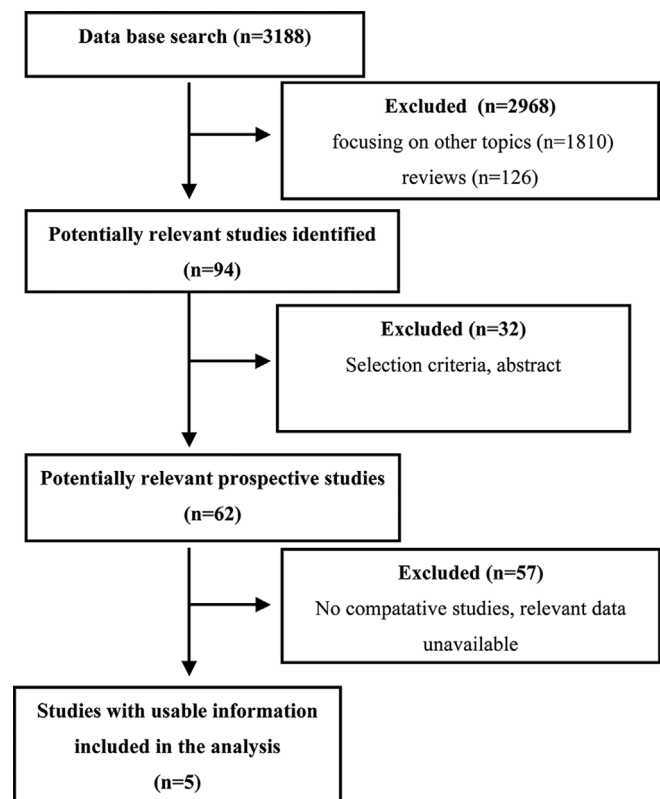
The surgical techniques were generally consistent with minor variation in different studies.

Surgery was performed with monitored anesthesia care and a retrobulbar block. In both groups, the surgical procedure included a standard 3-port PPV. During vitrectomy, the vitreous base was thoroughly removed. Epiretinal traction removal, internal limiting membrane peeling and relaxing retinotomies were performed, when necessary. The retinal periphery was inspected for retinal breaks, and any peripheral break found was treated with cryocoagulation or endolaser photocoagulation. A fluid–air exchange procedure was then performed with humidified air. At the end of the surgical procedure, SSO or HSO was injected. The iridotomies were performed when necessary and located according to the density of the oil used. At the end of surgery, the surgeons aimed to reach a complete filling and the eyes appeared clinically completely filled by the compound. Suture of the sclerotomies followed. In all cases, the surgery was not combined with scleral buckle placement.

The outcome measure was the incidence of OH at 1-month after surgery, calculated as the number of patients with IOP  $> 21$  mmHg with or without medical therapy in each study.

## Results

Three thousand one hundred eighty-eight studies were identified through a literature search. The most of these studies were excluded because no-comparative studies, unqualified intervention and unqualified outcome measure. Only five studies comparing the OH rate after PPV for RD using SSD or HSO were included [Fig. 1]. The random effects model will be used and a fixed effect model will be considered as a



**Figure 1:** The selection of publications for inclusion in this meta-analysis

sensitivity analysis for evaluating the possible bias effects of smaller studies.

### Study characteristics

A total of 441 eyes in 5 included studies were included in this meta-analysis. The 50.3% of participants were female. Sample sizes in these studies ranged from 30 to 180 eyes. Three studies were carried out in Italy, and one study was carried out in Turkey and United Kingdom each. All of the studies included OH rate after PPV for RD [Table 1].

There were 2 RCTs and 3 retrospective case-control studies. In the RCT of Kocak and Koc,<sup>[19]</sup> there was not information on random sequence generation and allocation concealment. Both studies were open label, but the outcome measure probably was not affected by blinding status. The two studies were judged as low risk of bias for the remaining items.

Methodological quality of 3 retrospective case-control studies was evaluated using NOS and STROBE. The quality of the studies, according NOS, was high: All the studies met eight of the nine study quality criteria. The only unmet item was related to comparability criteria since the studies did not report on statistical methods used to adjust for confounding. According STROBE checklist, almost all of case-control studies reported the scientific background, described the setting and locations, included a clear description of the inclusion criteria and give a clear definition of outcomes. No one provided sufficient information on how the sample size and described measures to reduce potential sources of bias; likewise, all the reports did not describe the approach to dealing with missing data or to controlling for confounding factors. All the studies described the statistical methods, but an assessment of confounding (e.g., odds ratios, RRs) was not reported. The selected studies described the characteristics of participants in detail and reported numbers of outcome events.

The pooled data are presented as Mantel-Haenszel RR and 95% CI with a fixed effect model [Fig. 2a] and random effect model [Fig. 2b] for the OH rate. The heterogeneity test shows lack of heterogeneity ( $\chi^2$ , 4.41; df 4;  $P = 0.35$ ); however, since  $I^2$  were  $>0$  ( $=9$ ). Both the random effects analysis and the fixed effect analysis are presented. Moreover, the fixed effect model is considered as a sensitivity analysis for evaluating the possible bias effects of smaller studies. There were a higher number of rates of OH in HSO compared to SSO. This difference was statistically significant with the fixed effect model (Mantel-Haenszel RR; 1.55; 95% CI, 1.06–2.28;  $P = 0.02$ , and of borderline significance with the random

effect model (Mantel-Haenszel RR; 1.51; 95% CI, 0.98–2.33;  $P = 0.06$ ).

### Discussion

The most common cause for chronic postoperative increase of IOP in patients treated with vitrectomy and SO tamponade is the blockage of trabecular meshwork in an open-angle.

The potential cause beyond the blockage of the trabecular meshwork are the emulsification of the oil with blockage of aqueous outflow by microbubbles emulsified, the intraocular inflammation induced by the surgery and the tamponade or, response to the steroid topical therapy.

Avitabile *et al.* reported OH at 1-month after the surgery in 2 eyes (13%) in SSO group and in 4 eyes (27%) of HSO group ( $P = 0.36$ ). The authors did not observe any pupil block mechanisms in these series.<sup>[18]</sup> Kocak and Koc observed OH in SSO group in 7 cases (23%) in the early postoperative period, in 1 case (3%) by the 1<sup>st</sup> month, whereas in HSO group the OH was present in 7 eyes (22%) in the early postoperative period, in 4 eyes (13%) by the 1<sup>st</sup> month.<sup>[19]</sup> Mete *et al.* reported that 2 eyes (11%), treated with SSO, developed OH that was controlled with topical beta-blocker treatment. In the group treated with HSO, 5 eyes (29%) developed OH that in one case was refractory to topical treatment and required further ciliary body cyclo-photocoagulation. No statistically significant differences were found between the two groups ( $P = 0.238$ , Fisher's exact test).<sup>[20]</sup> Romano *et al.* stated that the long-term increased IOP depends on an open-angle mechanism rather than a closed-angle mechanism, since they did not report any case of pupillary block associated with SSO or HSO.<sup>[21]</sup> They stated that the persistence of a raised pressure could be related to the presence of emulsified oil in the anterior chamber and in the trabecular meshwork, which persists after the removal of SO.<sup>[21]</sup>

Wong *et al.* showed that the IOP is higher in eyes treated with HSO at day 1 and between 7 and 14 days postoperatively ( $P = 0.05$  and  $0.01$ , respectively), whereas by the 4<sup>th</sup> week, the difference of IOP between the two groups was not significant ( $P = 0.17$ ). At 4 weeks, IOP higher than 30 mmHg was still present in 9 eyes (12.7%) in HSO group and in 1 eye (1.8%) in the SSO group. However, according to the authors, the raised IOP in HSO group was more difficult to treat.<sup>[19]</sup>

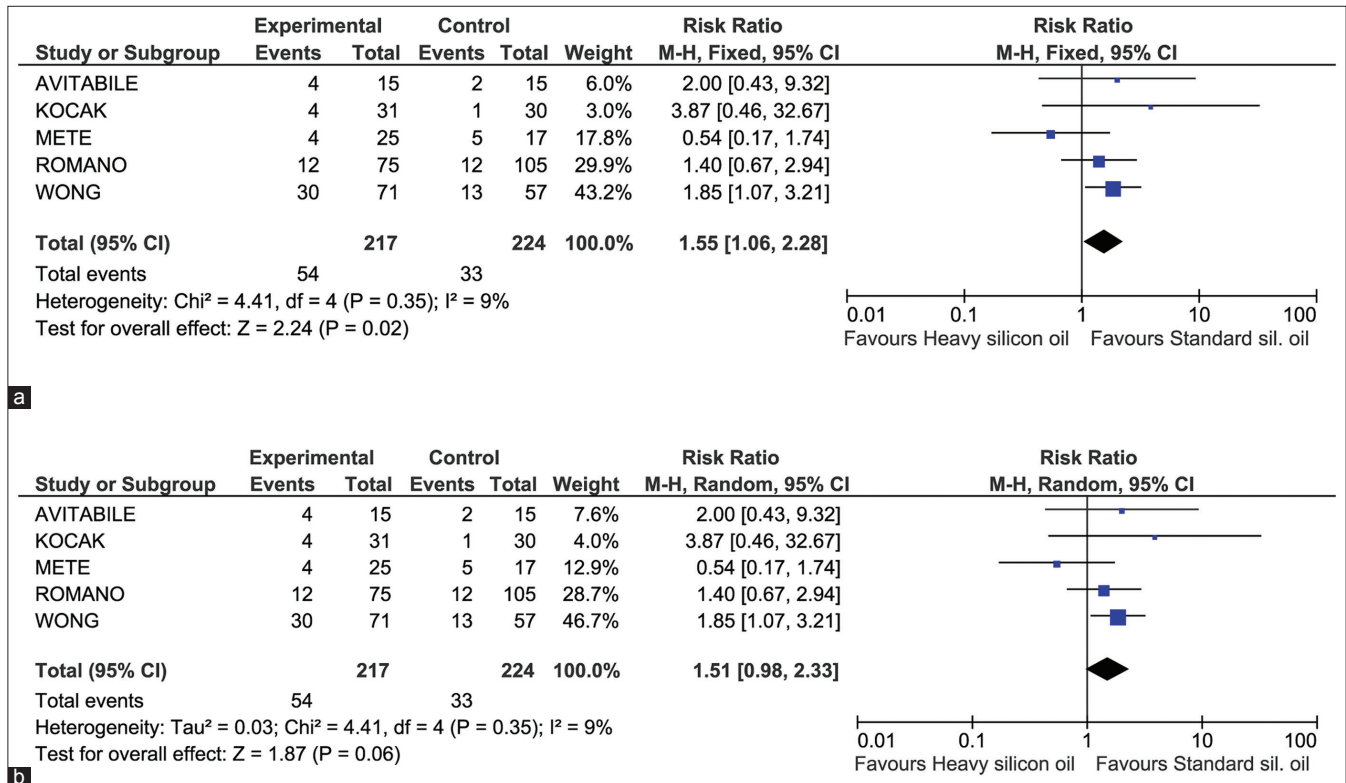
The OH due to an intraoperative overfilling is still a risk factor, but easily managed by the surgeon.<sup>[30]</sup>

Our meta-analysis considered only cases of OH in open-angle, frequent complication following PPV and SO

**Table 1: Main characteristics of selective studies**

First author, country, year publication	Study design	Patients	Number of patients enrolled in the arms (SSO/HSO)	Patient with OH (SSO vs. HSO)
Avitabile, Italy, 2011	Randomized control study	RD with macular hole and posterior staphyloma in highly myopic eyes	15/15	2/15 versus 4/15
Kocak, Turkey, 2013	Randomized control study	RD in patients with inferior breaks	30/31	1/30 versus 4/31
Mete, Italy, 2011	Retrospective case-control	RD with myopic macular hole	17/25	5/17 versus 4/25
Romano, Italy, 2010	Retrospective case-control	RD	105/75	12/105 versus 12/75
Wong, UK, 2009	Retrospective case-control	RD	57/71	13/57 versus 30/71

RD: Retinal detachment, SSO: Standard silicone oil, HSO: Heavy silicone oil, OH: Ocular hypertension



**Figure 2:** Forest plots of comparisons. The effect of heavy silicone oil versus standard silicone oil on the ocular hypertension (OH) rate is illustrated. Results are expressed as risk ratio (RR) and 95% confidence interval (CI) with a fixed effect model (a) and random-effect model (b). In the graph, squares indicate point estimates of OH rate, with the size of the squares representing the weight attribute to each study. The horizontal lines represent 95% CI for RR. The pooled estimate for OH rate is the pooled RR obtained by combining all RR of the five studies and is represented by the diamond, with the size of the diamond depicting the 95% CI

injection,<sup>[31-35]</sup> ranking second to cataract as a late complication of SO.<sup>[6,10,34,35]</sup> At least in theory, the use of HSO, mainly for the presence of semifluorinated alkanes, has been considered to be higher risk factor than SSO for postoperative OH. The semifluorinated alkanes in the beginning have been only used as intraoperative tamponades to keep the retina stable during the surgery and as silicone solvent to remove SO remnants from vitreous cavity.<sup>[36]</sup> The main problem associated with semifluorinated alkanes was the presence of emulsification, as for perfluorocarbon, liquid in up to 100% in the postoperative of all cases. The emulsification was thought to be responsible for inflammatory reaction due to foreign body response to the emulsified droplets.<sup>[37]</sup> The stability of the semifluorinated alkanes is significantly improved adding SO to the semifluorinate, and keeping at same time a density higher than water. The mixed compound generated, HSO, is currently used as postoperative intraocular tamponades,<sup>[38,39]</sup> however, the current literature still report OH in the postoperative period.<sup>[40]</sup> The results of this meta-analysis, according to the random model, lack of statistical significance. Nevertheless, it was possible to observe a trend for lower OH rate in SSO group [Fig. 2b]. This tendency is confirmed by the results of the fixed model showing a statistically significant difference in OH rate between the SSO and HSO groups.

Other risk factors associated with an increased OH rate after PPV, rather than the presence of semifluorinated alkanes in the compound, are the lens status, angle pathology, preexisting glaucoma, steroid response, axial myopia, overfilling, migration

of SO into the anterior chamber, surgical procedures commonly used in conjunction with PPV, systemic diseases.<sup>[31-35,41]</sup>

The surgeon should also consider, in the pianification of the vitreoretinal surgery, that several studies confirmed the strong relationship between high myopia and glaucoma.<sup>[42-44]</sup> In noncomparative studies a significant association of diabetes mellitus with OH after SO injection was found.<sup>[6,8]</sup> Other authors reported that OH rate was independent from systemic conditions such as diabetes mellitus.<sup>[33]</sup> In our comparative studies no one of authors found any systemic association with OH rate.

Nowadays the clinical management of eyes with OH after PPV and SO injection is medical therapy.

Jackson *et al.* observed that when SO was present in anterior chamber, high IOP usually ensued and the OH could be difficult to treat.<sup>[41]</sup>

In the comparative studies the most of patients are treated with medical therapy only 1.5% (7/441 eyes) required to glaucoma surgery. Since the trabeculectomy has a limited role and success rate,<sup>[45]</sup> besides being technically difficult, the surgical therapy with Ahmed glaucoma valve implantation with inferior placement have gained wide acceptance in recent years.<sup>[46]</sup> Previous studies have shown that Ahmed glaucoma valves have a low complication rate,<sup>[47,48]</sup> especially, if compared with other glaucoma implants.<sup>[49]</sup> Furthermore in the 1991 was proposed a new surgical technique for the pars plana insertion of a glaucoma implant, instead of anterior chamber, for the

management of neovascular glaucoma.<sup>[50]</sup> This modification can potentially cause significant anterior segment complications. Recently Maris *et al.*<sup>[51]</sup> in a retrospective study did not report differences in IOP and complication after implantation of the Ahmed glaucoma valve in posterior or in the anterior chamber. There are several important limitations to this meta-analysis, including the lack of randomized control trials, the inclusion of retrospective studies, with all the limits that they have, variety of surgeons, techniques and instruments used. In summary further well-designed and large size RCTs are necessary to confirm our results.

## References

1. Lucke KH, Foerster MH, Laqua H. Long-term results of vitrectomy and silicone oil in 500 cases of complicated retinal detachments. *Am J Ophthalmol* 1987;104:624-33.
2. Cibis PA, Becker B, Okun E, Canaan S. The use of liquid silicone in retinal detachment surgery. *Arch Ophthalmol* 1962;68:590-9.
3. Cox MS, Trese MT, Murphy PL. Silicone oil for advanced proliferative vitreoretinopathy. *Ophthalmology* 1986;93:646-50.
4. Riedel KG, Gabel VP, Neubauer L, Kampik A, Lund OE. Intravitreal silicone oil injection: Complications and treatment of 415 consecutive patients. *Graefes Arch Clin Exp Ophthalmol* 1990;228:19-23.
5. Goldbaum MH, McCuen BW, Hanneken AM, Burgess SK, Chen HH. Silicone oil tamponade to seal macular holes without position restrictions. *Ophthalmology* 1998;105:2140-7.
6. Honavar SG, Goyal M, Majji AB, Sen PK, Naduvilath T, Dandona L. Glaucoma after pars plana vitrectomy and silicone oil injection for complicated retinal detachments. *Ophthalmology* 1999;106:169-76.
7. Yamamoto S, Takeuchi S. Silicone oil and fluorosilicone. *Semin Ophthalmol* 2000;15:15-24.
8. Al-Jazzaf AM, Netland PA, Charles S. Incidence and management of elevated intraocular pressure after silicone oil injection. *J Glaucoma* 2005;14:40-6.
9. Azen SP, Scott IU, Flynn HW Jr, Lai MY, Topping TM, Benati L, *et al.* Silicone oil in the repair of complex retinal detachments. A prospective observational multicenter study. *Ophthalmology* 1998;105:1587-97.
10. Henderer JD, Budenz DL, Flynn HW Jr, Schiffman JC, Feuer WJ, Murray TG. Elevated intraocular pressure and hypotony following silicone oil retinal tamponade for complex retinal detachment: Incidence and risk factors. *Arch Ophthalmol* 1999;117:189-95.
11. Jousseaume AM, Rizzo S, Kirchhof B, Schrage N, Li X, Lente C, *et al.* Heavy silicone oil versus standard silicone oil in as vitreous tamponade in inferior PVR (HSO Study): Interim analysis. *Acta Ophthalmol* 2011;89:e483-9.
12. Lappas A, Foerster AM, Kirchhof B. Use of heavy silicone oil (Densiron-68) in the treatment of persistent macular holes. *Acta Ophthalmol* 2009;87:866-70.
13. Tognetto D, Minutola D, Sanguinetti G, Ravalico G. Anatomical and functional outcomes after heavy silicone oil tamponade in vitreoretinal surgery for complicated retinal detachment: A pilot study. *Ophthalmology* 2005;112:1574.
14. Wolf S, Schön V, Meier P, Wiedemann P. Silicone oil-RMN3 mixture ("heavy silicone oil") as internal tamponade for complicated retinal detachment. *Retina* 2003;23:335-42.
15. Wong D, Van Meurs JC, Stappler T, Groenewald C, Pearce IA, McGalliard JN, *et al.* A pilot study on the use of a perfluorohexyloctane/silicone oil solution as a heavier than water internal tamponade agent. *Br J Ophthalmol* 2005;89:662-5.
16. Weinberg RS, Peyman GA, Huamonte FU. Elevation of intraocular pressure after pars plana vitrectomy. *Albrecht Von Graefes Arch Klin Exp Ophthalmol* 1976;200:157-61.
17. Aaberg TM, Van Horn DL. Late complications of pars plana vitreous surgery. *Ophthalmology* 1978;85:126-40.
18. Avitabile T, Bonfiglio V, Buccoliero D, Castiglione F, Reibaldi M, Castaing M, *et al.* Heavy versus standard silicone oil in the management of retinal detachment with macular hole in myopic eyes. *Retina* 2011;31:540-6.
19. Kocak I, Koc H. Comparison of Densiron 68 and 1 000 cSt silicone oil in the management of rhegmatogenous retinal detachment with inferior breaks. *Int J Ophthalmol* 2013;6:81-4.
20. Mete M, Parolini B, Maggio E, Pertile G. 1000 cSt silicone oil vs heavy silicone oil as intraocular tamponade in retinal detachment associated to myopic macular hole. *Graefes Arch Clin Exp Ophthalmol* 2011;249:821-6.
21. Romano MR, Angi M, Romano V, Parmeggiani F, Campa C, Valldeperas X, *et al.* Intraocular pressure changes following the use of silicone oil or Densiron 68 as endotamponade in pars plana vitrectomy. *Clin Ophthalmol* 2010;4:1391-6.
22. Wong D, Kumar I, Quah SA, Ali H, Valldeperas X, Romano MR. Comparison of postoperative intraocular pressure in patients with Densiron-68 vs conventional silicone oil: A case-control study. *Eye (Lond)* 2009;23:190-4.
23. Higgins JPT, Green S. *Cochrane Handbook for Systematic Reviews of Interventions*, Version 5.1.0. The Cochrane Collaboration; 2011. Available from: [www.cochrane-handbook.org](http://www.cochrane-handbook.org) [Last accessed on 2011 Mar].
24. von Elm E, Altman DG, Egger M, Pocock SJ, Gøtzsche PC, Vandenbroucke JP, *et al.* The Strengthening of Reporting of Observational Studies in Epidemiology (STROBE) statement: Guidelines for reporting observational studies. *Lancet* 2007;370:1453-7.
25. Vandenbroucke JP, von Elm E, Altman DG, Gøtzsche PC, Mulrow CD, Pocock SJ, *et al.* Strengthening the Reporting of Observational Studies in Epidemiology (STROBE): Explanation and elaboration. *PLoS Med* 2007;4:E297.
26. Wells GA, Shea B, O'Connell D, Peterson J, Welch V, Losos M, *et al.* The Newcastle-Ottawa Scale (NOS) for assessing the quality of nonrandomized studies in meta-analysis. 2011. Available: [www.ohri.ca/programs/clinical\\_epidemiology/oxford.asp](http://www.ohri.ca/programs/clinical_epidemiology/oxford.asp) [Last accessed on 2010 Oct 14].
27. Higgins JP, Thompson SG, Deeks JJ, Altman DG. Measuring inconsistency in meta-analyses. *BMJ* 2003;327:557-60.
28. Cochran W. The combination of estimates from different experiments. *Biometrics* 1954;10:101-29.
29. Sterne JJ, Moher D. Investigating and dealing with bias in systematic reviews. In: 16<sup>th</sup> Cochrane Colloquium. Evidence in the Era of Globalisation. Freiburg, Germany; 2008. p. 3-7.
30. Zenoni S, Comi N, Fontana P, Romano MR. The combined use of heavy and light silicone oil in the treatment of complicated retinal detachment with 360° retinal breaks: Tamponade effect or filling effect? *Ann Acad Med Singapore* 2012;41:440-3.
31. Barr CC, Lai MY, Lean JS, Linton KL, Trese M, Abrams G, *et al.* Postoperative intraocular pressure abnormalities in the Silicone Study. Silicone Study Report 4. *Ophthalmology* 1993;100:1629-35.
32. Federman JL, Schubert HD. Complications associated with the use of silicone oil in 150 eyes after retina-vitreous surgery. *Ophthalmology* 1988;95:870-6.
33. de Corral LR, Cohen SB, Peyman GA. Effect of intravitreal silicone oil on intraocular pressure. *Ophthalmic Surg* 1987;18:446-9.
34. Grey RH, Leaver PK. Results of silicone oil injection in massive preretinal retraction. *Trans Ophthalmol Soc U K* 1977;97:238-41.

35. Leaver PK, Grey RH, Garner A. Silicone oil injection in the treatment of massive preretinal retraction. II. Late complications in 93 eyes. *Br J Ophthalmol* 1979;63:361-7.
36. Meinert H, Roy T. Semifluorinated alkanes – a new class of compounds with outstanding properties for use in ophthalmology. *Eur J Ophthalmol* 2000;10:189-97.
37. Romano MR, Baddon C, Heimann H, Wong D, Hiscott P. Histopathological findings in an epimacular membrane after intraoperative use of perfluorocarbon liquid. *Eye (Lond)* 2010;24:740-2.
38. Romano MR, Angi M, Valldeperas X, Costagliola C, Vinciguerra P. Twenty-three-gauge pars plana vitrectomy, Densiron-68, and 360° endolaser versus combined 20-gauge pars plana vitrectomy, scleral buckle, and SF6 for pseudophakic retinal detachment with inferior retinal breaks. *Retina* 2011;31:686-91.
39. Romano MR, Stappeler T, Marticorena J, Groenewald C, Pearce J, Gibran SK, *et al.* Primary vitrectomy with Densiron-68 for rhegmatogenous retinal detachment. *Graefes Arch Clin Exp Ophthalmol* 2008;246:1541-6.
40. Levasseur SD, Schendel S, Machuck RW, Dhanda D. High-density silicone oil Densiron-68 as an intraocular tamponade for primary inferior retinal detachments. *Retina* 2013;33:627-33.
41. Jackson TL, Thiagarajan M, Murthy R, Snead MP, Wong D, Williamson TH. Pupil block glaucoma in phakic and pseudophakic patients after vitrectomy with silicone oil injection. *Am J Ophthalmol* 2001;132:414-6.
42. Xu L, Wang Y, Wang S, Wang Y, Jonas JB. High myopia and glaucoma susceptibility the Beijing Eye Study. *Ophthalmology* 2007;114:216-20.
43. Mitchell P, Hourihan F, Sandbach J, Wang JJ. The relationship between glaucoma and myopia: The Blue Mountains Eye Study. *Ophthalmology* 1999;106:2010-5.
44. Leske MC, Connell AM, Wu SY, Hyman LG, Schachat AP. Risk factors for open-angle glaucoma. The Barbados Eye Study. *Arch Ophthalmol* 1995;113:918-24.
45. Nguyen QH, Lloyd MA, Heuer DK, Baerveldt G, Minckler DS, Lean JS, *et al.* Incidence and management of glaucoma after intravitreal silicone oil injection for complicated retinal detachments. *Ophthalmology* 1992;99:1520-6.
46. Assaad MH, Baerveldt G, Rockwood EJ. Glaucoma drainage devices: Pros and cons. *Curr Opin Ophthalmol* 1999;10:147-53.
47. Coleman AL, Hill R, Wilson MR, Choplin N, Kotas-Neumann R, Tam M, *et al.* Initial clinical experience with the Ahmed Glaucoma Valve implant. *Am J Ophthalmol* 1995;120:23-31.
48. Ayyala RS, Zurakowski D, Smith JA, Monshizadeh R, Netland PA, Richards DW, *et al.* A clinical study of the Ahmed glaucoma valve implant in advanced glaucoma. *Ophthalmology* 1998;105:1968-76.
49. Taglia DP, Perkins TW, Gangnon R, Heatley GA, Kaufman PL. Comparison of the Ahmed glaucoma valve, the Krupin eye valve with disk, and the double-plate Molteno implant. *J Glaucoma* 2002;11:347-53.
50. Lloyd MA, Heuer DK, Baerveldt G, Minckler DS, Martone JF, Lean JS, *et al.* Combined Molteno implantation and pars plana vitrectomy for neovascular glaucomas. *Ophthalmology* 1991;98:1401-5.
51. Maris PJ Jr, Tsai JC, Khatib N, Bansal R, Al-Aswad LA. Clinical outcomes of Ahmed Glaucoma valve in posterior segment versus anterior chamber. *J Glaucoma* 2013;22:183-9.

**Cite this article as:** Romano V, Cruciani M, Semeraro F, Costagliola C, Romano MR. Development of ocular hypertension secondary to tamponade with light versus heavy silicone oil: A systematic review. *Indian J Ophthalmol* 2015;63:227-32.

**Source of Support:** Nil. **Conflict of Interest:** None declared.