



OPEN ACCESS

Antivascular endothelial growth factor agents pretreatment before vitrectomy for complicated proliferative diabetic retinopathy: a meta-analysis of randomised controlled trials

Xin-yu Zhao, Song Xia, You-xin Chen

Department of Ophthalmology, Peking Union Medical College Hospital, Chinese Academy of Medical Sciences, Beijing, China

Correspondence to

Dr You-xin Chen, Department of Ophthalmology, Peking Union Medical College Hospital, Chinese Academy of Medical Sciences, Beijing 100730, China; 478252553@qq.com

Received 20 September 2017

Revised 2 November 2017

Accepted 21 November 2017

Published Online First

15 December 2017

ABSTRACT

Background/aims To evaluate the efficacy of antivascular endothelial growth factor (anti-VEGF) agents pretreatment before vitrectomy for patients with complicated proliferative diabetic retinopathy (PDR).

Methods The PubMed, Embase and the Cochrane Central Register of Controlled Trials were searched up to June 2017 to identify related studies. The Preferred Reporting Items for Systematic Reviews and Meta-Analysis guidelines were followed. The StataSE V.12.0 software was used to analyse the relevant data. The weighted mean difference, relative risk and their 95% CIs were used to assess the strength of the association.

Results 14 randomised controlled trials involving 613 patients were assessed, the anti-VEGF pretreatment group included 289 patients and the control group included 324 patients. Our analysis indicated that anti-VEGF pretreatment before vitrectomy for complicated PDR could facilitate much easier surgery regarding less intraoperative bleeding, less endodiathermy, shorter duration of surgery, less iatrogenic retinal breaks, less frequency of using silicone oil and relaxing retinotomy ($P<0.05$). Additionally, anti-VEGF pretreatment could also achieve better postoperative best-corrected visual acuity, less early recurrent vitreous haemorrhage (VH) and quicker absorption of recurrent VH ($P<0.05$). However, the incidence of late recurrent VH, recurrent retinal detachment or related secondary surgery could not be reduced ($P>0.05$).

Conclusion The pretreatment of anti-VEGF agents before vitrectomy for patients with complicated PDR might facilitate much easier surgery and better visual rehabilitation, reduce the rate of early recurrent VH and accelerate its absorption. Moreover, future better-designed studies with larger sample sizes are required to further evaluate the efficacy of different anti-VEGF agents and reach a firmer conclusion.

INTRODUCTION

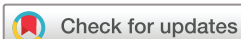Despite all the important progress in the understanding and management of diabetes over the recent years, diabetic retinopathy (DR) remains one of the leading causes of legally blind in the working-age population worldwide.¹ The prevalence of DR in diabetic patients was reported as high as 54% after 10–19 years of evolution.² Proliferative diabetic retinopathy (PDR) is the severest stage of DR, the formation of retinal neovascularisation (RNV) in the vitreous–retinal interface usually lead

to serum leakage, haemorrhage and fibrovascular proliferation. All these will further induce macular oedema, vitreous haemorrhage (VH) and even tractional retinal detachment (TRD), these complications may severely damage patient's visual function and need surgical intervention.

Pars plana vitrectomy (PPV) is widely regarded as the milestone for the management for severe complications of PDR like TRD and non-resolving VH.^{3–4} However, serious events including intraocular haemorrhage during surgery may prevent the successful conclusions of diabetic vitrectomy. Despite many manoeuvres such as elevating infusion bottle and endodiathermy are always employed, repeated bleeding from multiple retinal sites may make the operation lengthy and tedious. Additionally, excessive endodiathermy may induce necrosis and shrinkage of the retina, thus aggravating the postoperative inflammation. The oedema of corneal epithelium, which always happens after prolonged elevation of intraocular pressure, may also hamper clear surgical visualisation. If bleeding is not controlled properly, the removal of clotted blood, the delamination and segmentation of epiretinal membrane may not only extend a pre-existing retinal break but also create new iatrogenic retinal damage, which increase the risk of secondary operation for recurrent intravitreal haemorrhage and retinal detachment.⁵ Therefore, any method that can induce the regression of RNV and decrease the intraoperative bleeding may facilitate a much easier vitreoretinal surgery.

Angiogenesis is the fundamental mechanism of PDR.⁶ Studies have recently confirmed that vascular endothelial growth factor (VEGF) is the pivotal driver of the increase of vascular permeability that results in diabetic macular oedema, of the neovascularisation that can lead to VH and TRD.^{7,8} Current clinical studies suggested that the regression of RNV could be induced by the inhibition of VEGF receptors. Therefore, easier diabetic PPV and fibrovascular membrane dissection could be achieved with less risk of intraoperative bleeding. To minimise the surgical complications and maximise the surgical outcomes, intravitreal injection of anti-VEGF agents before diabetic PPV has been widely regarded as a necessary adjunctive therapy.^{9–11}

However, some controversies still exist. Some authors reported that the use of anti-VEGF agents would result in easier diabetic PPV, less



To cite: Zhao X, Xia S, Chen Y. *Br J Ophthalmol* 2018;**102**:1077–1085.

surgical complications, improved postoperative best-corrected visual acuity (BCVA), less postoperative VH and secondary surgery.^{5 11–15} While other authors insisted that anti-VEGF agents have no significant effect on facilitation of the surgery or the postoperative course.^{16–18} Besides, the sample sizes of previous studies were relatively small and may not detect the difference as statistically significant.

Several previous meta-analyses^{11–13} were performed to evaluate the intravitreal injection of anti-VEGF agents before vitrectomy and concluded that preoperative use of anti-VEGF agents in patients with complicated PDR could facilitate the surgery and minimise the iatrogenic damage. Although they were scientific and rigorous studies, some limitations still exist: (1) they only included studies before 2014, the data from recent randomised controlled trials (RCTs) were not pooled; and (2) other key indices such as postoperative BCVA, postoperative VH, the incidence of recurrent retinal detachment and secondary surgery were not considered. Hence, we performed this meta-analysis, which includes all the available data and considers all the pivotal indices to re-evaluate the efficacy of intravitreal injection of anti-VEGF agents before vitrectomy for complicated PDR in order to provide a reference for the decision-making of ophthalmologists.

METHODS

This meta-analysis was performed strictly according to the guidelines, the Preferred Reporting Items for Systematic Reviews and Meta-Analysis statement.¹⁹

Search strategy

RCTs were obtained through a literature search on PubMed, Embase and the Cochrane Central Register of Controlled Trials from their earliest entries through June 2017. The following keywords or corresponding Medical Subject Headings (Mesh) were used: ‘Diabetic Retinopathy’, ‘anti-VEGF’, ‘bevacizumab’, ‘ranibizumab’, ‘Randomized Controlled Trial’ and ‘Vitrectomy’. The detailed electronic search strategy of PubMed was ((((((‘Diabetic Retinopathy’[Mesh]) OR ((proliferative diabetic retinopathy [Title/Abstract]) OR PDR[Title/Abstract]))) AND (((((random*[Title/Abstract]) OR ‘Randomized Controlled Trial’ [Publication Type]))) AND ((‘Vitrectomy’[Mesh]) OR Vitrectomy[Title/Abstract]))) AND ((((((VEGF[Title/Abstract]) OR anti VEGF [Title/Abstract]) OR anti-VEGF [Title/Abstract]) OR lucentis[Title/Abstract]) OR bevacizumab[Title/Abstract]) OR ranibizumab [Title/Abstract]) OR aflibercept[Title/Abstract])]). The searches started at 15 May 2017 and ended at 6 June 2017. The reference lists of the relevant articles were also manually examined to further identify potentially related studies. No language restriction or time limits were imposed.

Inclusion criteria and exclusion criteria

Inclusion criteria were (1) participants: human with complicated PDR like TRD or non-resolving VH requiring surgical intervention; (2) intervention: diabetic PPV; (3) comparison: with or without intravitreal injection of anti-VEGF agents before surgery; (4) outcomes: at least one of the followings: BCVA (log MAR scale); intraoperative parameters like duration of surgery, endodiathermy application, number of iatrogenic retinal breaks, bleeding score, surgical difficulty score, relaxing retinotomy and silicone oil tamponade; postoperative parameters like postoperative VH, rate of recurrent retinal detachment and secondary surgery; levels of VEGF; and (5) methodological criterion: RCTs.

Exclusion criteria were (1) patients with other intraocular diseases that may affect the vitreoretinal surgery, such as uveitis,

proliferative vitreoretinopathy, retinal vascular disorders, congenital vitreoretinopathies and traumatic retinal detachment; (2) other differences between case group and control group beside the preoperative injection of anti-VEGF agents; (3) insufficient data to estimate a relative risk (RR) or weighted mean difference (WMD); (4) animal studies or cadaver subjects; and (5) redundant publications.

Data extraction and assessment of methodological quality

After consecutive procedures of screening titles and abstracts, obtaining the full text of each article and reviewing them, articles that met the eligibility criteria and fail the exclusion criteria were included. Two authors (X-yZ and SX) extracted and collated the following data independently using a standardised data collection protocol: first author, publication year, design, group size, patient age, gender ratio, details of anti-VEGF agent injection, details of the surgical procedure, intraoperative and postoperative evaluating parameters and follow-up periods. For updated publications with the same cohort of patients of the previous study, the data were extracted synthetically. The corresponding authors of the included articles would be contacted if the essential data were unavailable. Using 12-item scale,²⁰ the methodological quality of each included studies was assessed by two researchers independently: a trial with a score of ≥ 7 was considered high quality, >4 but no more than 7 was considered moderate quality, and no more than 4 was considered low quality. Disagreements were evaluated by kappa text, and agreement was achieved by a discussion with the corresponding author (Y-xC).

Statistical methods

Statistical analyses were performed using StataSE V.12.0 software. RR and its 95% CI were calculated for dichotomous data, WMD and its 95% CI were counted for continuous data. χ^2 test and I^2 were used to assess the statistical heterogeneity. Fixed-effect model would be used if heterogeneity was insignificant ($P > 0.1$, $I^2 < 50\%$). If heterogeneity was substantial ($P < 0.1$, $I^2 > 50\%$), both sensitivity analysis and subgroup analyses (publication year > 2010 , different anti-VEGF agent) were conducted to identify the source of the heterogeneity. If the heterogeneity could not be eliminated, a random-effect model would be used when the result of meta-analysis had clinical homogeneity, or a descriptive analysis would be used.

Begg’s funnel plot and the Egger’s linear regression test were used to evaluate the publication bias.²¹ $P < 0.05$ was considered to indicate statistical significance.

RESULTS

Study characteristics

The search yielded 145 potentially relevant articles for the meta-analysis. Among them, 100 duplicates were removed by Endnote software. On review of titles and abstracts of the 45 remaining articles, the full text of 26 articles was retrieved. Among them, another 12 studies were excluded because of unrelated data. Finally, 14 studies were selected for this meta-analysis.^{4 5 14–18 22–28} The cumulative sample size of 613 diabetic vitrectomies for complicated PDR comprised 289 with preoperative anti-VEGF agent injection and 324 without it. The demographic characteristics of the two groups were similar in each study. The main characteristics of the included studies are presented in [table 1](#), and the literature-exclusion procedures are described in [figure 1](#). The methodological quality of the included studies was assessed with the 12-item scale ([table 2](#)), the average score for the quality of included studies was 9.71,

Table 1 Main characteristics of the included studies

First author	Publication year	Design	Sample size	Group size (patient)		Details of anti-VEGF agent injection	Details of the surgical procedure	Intraoperative and postoperative evaluating parameters	Follow-up periods (weeks)
				Case/control	Average age Case/control				
Comyn <i>et al</i> ¹⁶	2017	Double-masked RCT	30	15/15	(57.1±14)/ (48.7±18)	IVR (0.5 mg) 7 days before vitrectomy	20 G PPV with fibrovascular membranes dissection. Endophotocoagulation, retinopexy and endotamponnade were used when required.	Duration of surgery; the number of back-flush cannula, endodiathermy applications, iatrogenic retinal breaks and silicone oil applications; severity of intraoperative bleeding; surgical complexity score	12
Yang <i>et al</i> ⁶	2016	Double-masked RCT	107	54/53	(48.63±8.24)/ (49.64±8.71)	IVC (0.5 mg) 3 days before vitrectomy	23 G PPV with fibrovascular membranes dissection. Endophotocoagulation, peripheral retinal cryotherapy and endotamponnade were used when required.	Postoperative BCVA, recurrent VH, complications Severity of intraoperative bleeding	12
Su <i>et al</i> ¹⁴	2016	Double-masked RCT	36	18/18	NA	IVC (0.5 mg) 7 days before vitrectomy	23 G PPV with fibrovascular membranes dissection. Endophotocoagulation and endotamponnade were used when required.	Postoperative BCVA, recurrent VH, vitreous clear-up time, complications Duration of surgery; the number of endodiathermy applications; iatrogenic retinal breaks; relaxing retinotomy and silicone oil applications; severity of intraoperative bleeding; erythrocyte count; surgical complexity score	12
Sohn <i>et al</i> ²²	2012	Double-masked RCT	19	10/9	NA	IVB (0.5 mg) 3–7 days before vitrectomy	20 G PPV with fibrovascular membranes dissection. Endophotocoagulation, endotamponnade, scleral buckling and lensectomy were used when required.	Postoperative BCVA, recurrent VH, complications BCVA, intraoperative bleeding and silicone oil applications; postoperative recurrent VH	12
Han <i>et al</i> ²³	2012	RCT	24	12/12	(50.33±7.6)/ (53.25±5.14)	IVB (1.25 mg) 6 days before vitrectomy	PPV with fibrovascular membranes dissection. The epiretinal membranes were collected	VEGF and CTGF levels in the vitreous and aqueous The levels of vascular endothelial cells, VEGF and HIF-1 α	NA
Farahvash <i>et al</i> ¹⁷	2011	Double-masked RCT	35	18/17	(58.3±24.1)/ (58.7±34.14)	IVB (1.25 mg) 7 days before vitrectomy	20 G PPV. Endophotocoagulation and endotamponnade were used when required.	The number of endodiathermy applications, iatrogenic retinal breaks and silicone oil applications; severity of intraoperative bleeding; surgical complexity score	12
Ahn <i>et al</i> ¹⁸	2011	RCT	70	36/34	(51.0±9.5)/ (55.0±11.4)	IVB (1.25 mg) 1–14 days before vitrectomy	23 G PPV with fibrovascular membranes dissection. Endodiathermy and endolaser photocoagulation were used when required.	Postoperative BCVA, recurrent VH, complications Postoperative BCVA, recurrent VH, vitreous clear-up time and complications	24

Continued

Table 1 Continued

First author	Publication year	Design	Sample size	Group size (patient)		Average age	Details of anti-VEGF agent injection	Details of the surgical procedure	Intraoperative and postoperative evaluating parameters	Follow-up periods (weeks)
				Case	control					
Hernandez-Da ¹⁵	2010	RCT	40	20/20	20/20	(55.7±9.9)/ (55.7±7.4)	IVB (1.25 mg) 2 days before vitrectomy	23 G PPV with fibrovascular membranes dissection. Endophotocoagulation and endotamponnade were used when required.	Duration of surgery; severity of intraoperative bleeding	24
di Lauro <i>et al</i> ²⁴	2010	RCT	72	24/24/24	NA	NA	IVB (1.25 mg) 7 or 20 days before vitrectomy	20 G PPV with fibrovascular membranes dissection. Endophotocoagulation and endotamponnade were used when required.	Postoperative BCVA, recurrent VH, complications Duration of surgery; the number of endodiathermy applications; iatrogenic retinal breaks; relaxing retinotomy and silicone oil applications; severity of intraoperative bleeding	24
Modarres <i>et al</i> ²⁵	2009	Surgeon-masked RCT	40	22/18	(55.8±11.3)/ (53.2±11.7)	IVB (2.5 mg) 3–5 days before vitrectomy	20 G PPV with fibrovascular membranes dissection. Endophotocoagulation, retinotomy and endotamponnade were used when required.	Duration of surgery; the number of endodiathermy applications; iatrogenic retinal breaks; relaxing retinotomy and silicone oil applications; severity of intraoperative bleeding; surgical complexity score	Postoperative BCVA, recurrent VH, complications	12
Ahmadi <i>et al</i> ²⁶	2009	Double-masked RCT	68	35/33	(53.69±11.7)/ (56.70±10.4)	IVB (1.25 mg) 7 days before vitrectomy	PPV with endophotocoagulation and endocautery when required.	The number of iatrogenic retinal breaks and intraoperative bleeding	Postoperative BCVA, recurrent VH, complications	4
Da and Lucena <i>et al</i> ²⁷	2009	Double-masked RCT	20	10/10	NA	IVB (1.5 mg) 14 days before vitrectomy	23 G PPV with fibrovascular membranes dissection. Endophotocoagulation and endotamponnade were used when required.	Erythrocyte count	Postoperative BCVA, recurrent VH, complications	–
Rizzo <i>et al</i> ²⁸	2008	RCT	22	11/11	NA	IVB (1.25 mg) 5–7 days before vitrectomy	20 G PPV with fibrovascular membranes dissection. Endophotocoagulation and endotamponnade were used when required.	Preoperative complexity score, duration of surgery; the number of too exchanges, endodiathermy applications; iatrogenic retinal breaks; severity of intraoperative bleeding	Postoperative BCVA and complications	24
El-Batarny ⁴	2008	RCT	30	15/15	(44±11)/ (46±12)	IVB (1.25 mg) 5–7 days before vitrectomy	23 G PPV with fibrovascular membranes dissection. Endophotocoagulation, peripheral retinal cryotherapy and endotamponnade were used when required.	Duration of surgery; the number of endodiathermy applications; iatrogenic retinal breaks; relaxing retinotomy and silicone oil applications; severity of intraoperative bleeding	Postoperative BCVA and complications	24

BCVA, best-corrected visual acuity; CTGF, connective tissue growth factor; HIF-1 α , hypoxia-inducible factor-1 α ; IVB, intravitreal injection of bevacizumab; IVC, intravitreal injection of conbercept; IVR, intravitreal injection of ranibizumab; NA, not available; PPV, pars plana vitrectomy; RCT, randomised controlled trials; VEGF, vascular endothelial growth factor; VH, vitreous haemorrhage.

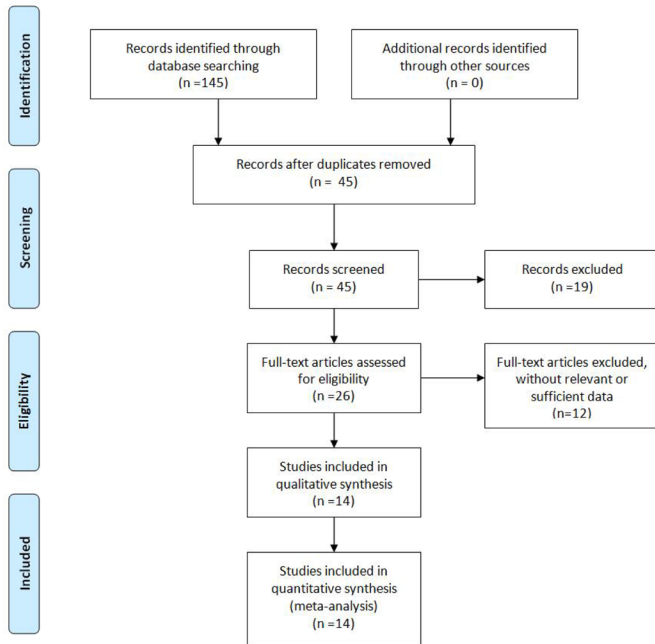


Figure 1 Flow chart depicting selection of included studies.

all of them were of high quality. Excellent inter-rater agreement was achieved between the investigators regarding eligibility ($\kappa=0.76$).

Best-corrected visual acuity

Together, nine studies^{4 14 15 17 18 24–26 28} included 223 patients in the anti-VEGF pretreatment group and 190 patients in the control group described preoperative and postoperative BCVA in the final follow-up. The pooling results by random-effect model ($P<0.1$, $I^2>50\%$) showed no statistical difference of preoperative BCVA between the two groups (WMD = -0.069 , 95% CI -0.172 to $+0.034$, $P=0.019$), while patients in the anti-VEGF group could achieve significantly better postoperative

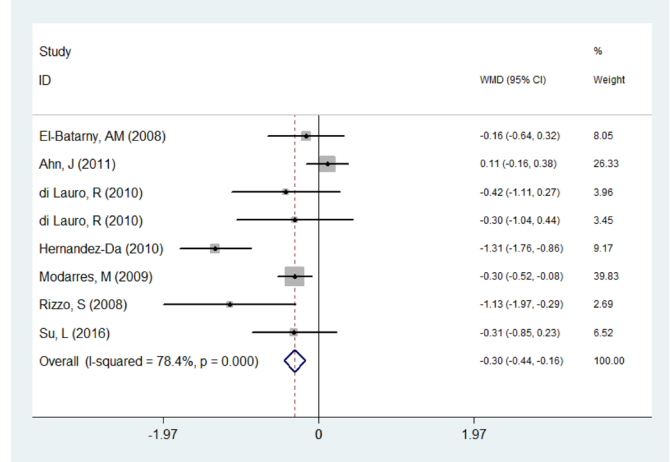


Figure 2 Comparison of the postoperative best-corrected visual acuity (logarithm of the minimum angle of resolution scale) between anti-vascular endothelial growth factor pretreatment group and control group. WMD, weighted mean difference.

BCVA than those in the control group in the final follow-up (WMD = -0.301 , 95% CI -0.438 to -0.164 , $P=0.001$, figure 2).

Intraoperative indices

The intraoperative indices are summarised in table 3. The forest plots indicated that the pretreatment of anti-VEGF agents could achieve significantly less intraoperative bleeding, less endoathermy, less frequency of using silicone oil and relaxing retinotomy ($P<0.05$).

For the incidence of intraoperative iatrogenic retinal breaks and the duration of surgery, the results of these analyses appeared heterogeneous ($P<0.1$, $I^2>50\%$). Sensitivity analysis detected that the study of Comyn *et al*¹⁶ was the source of heterogeneity. After excluding this study, we found that the heterogeneity could be significantly eliminated ($P>0.1$, $I^2<50\%$). Further

Table 2 Twelve-item scale critical appraisal scores

Author	Twelve-item scale critical appraisal score												Quality
	1	2	3	4	5	6	7	8	9	10	11	12	
Comyn <i>et al</i> ¹⁶	Y	Y	Y	Y	Y	Y	Y	Y	Y	Y	Y	Y	High
Yang <i>et al</i> ⁵	N	Y	Y	Y	Y	Y	Y	Y	Y	Y	Y	Y	High
Su <i>et al</i> ¹⁴	N	Y	Y	Y	N	Y	Y	Y	Y	Y	Y	Y	High
Sohn <i>et al</i> ²²	N	Y	Y	Y	N	Y	Y	Y	Y	Y	Y	Y	High
Han <i>et al</i> ²³	N	Y	N	N	N	Y	Y	Y	Y	Y	Y	Y	High
Farahvash <i>et al</i> ¹⁷	N	Y	Y	Y	N	Y	Y	Y	Y	Y	Y	Y	High
Ahn <i>et al</i> ¹⁸	Y	Y	N	N	N	Y	Y	Y	Y	Y	Y	Y	High
Hernandez-Da ¹⁵	N	Y	N	N	N	Y	Y	Y	Y	Y	Y	Y	High
di Lauro <i>et al</i> ²⁴	N	Y	N	N	N	Y	Y	Y	Y	Y	Y	Y	High
Modarres <i>et al</i> ²⁵	N	Y	N	Y	N	Y	Y	Y	Y	Y	Y	Y	High
Ahmadieh <i>et al</i> ²⁶	Y	Y	Y	Y	Y	Y	Y	Y	Y	Y	Y	Y	High
Da and Lucena <i>et al</i> ²⁷	Y	Y	Y	Y	N	Y	Y	Y	Y	Y	Y	Y	High
Rizzo <i>et al</i> ²⁸	Y	Y	Y	N	N	Y	Y	Y	Y	Y	Y	Y	High
El-Batarny ⁴	N	Y	N	N	N	Y	Y	Y	Y	Y	Y	Y	High

Twelve-item scale criteria: (1) method of randomisation; (2) concealed allocation; (3) patient blinding; (4) provider blinding; (5) outcome assessor blinding; (6) dropout rate; (7) patient allocated as plan; (8) free of selective outcome reporting; (9) same baseline; (10) co-interventions avoided or similar; (11) acceptable compliance; (12) same time of outcome assessment.

A trial with a score of ≥ 7 was considered high quality, >4 but no more than 7 was considered moderate quality, and no more than 4 was considered low quality. Y, yes; n, no.

Table 3 Summary of intraoperative indices

Intraoperative indices	Sample size		RR (CI)	WMD (CI)	I ² (%)	P of χ^2	Selected model	P for overall effect
	Anti-VEGF group	No anti-VEGF group						
Duration of surgery	7 (overall) 5 (bevacizumab) 1 (conbercept) 1 (ranibizumab)	107 74 18 15	NA NA NA NA	-18.277 (-29.287 to -7.267) -23.858 (-28.198 to -19.518) -10.000 (-15.916 to -4.084) 12.000 (4.038 to 19.962)	90.20 45.2 - -	0.01 >0.1 - -	Random-effect Fixed-effect Fixed-effect Fixed-effect	0.001 <0.05 <0.05 >0.05
Intraoperative bleeding	5	158	0.531 (0.440 to 0.642)	NA	92.2	0.001	Random-effect	0.001
Frequency of required endodiathermy	10	172	0.212 (0.126 to 0.362)	-1.297 (-1.590 to -1.004)	<50	>0.1	Fixed-effect	0.001
Intraoperative iatrogenic retinal breaks	6 (overall) 4 (bevacizumab) 1 (conbercept) 1 (ranibizumab)	130 97 18 15	0.422 (0.156 to 1.145) 0.351 (0.149 to 0.781) 0.143 (0.008 to 2.581) 0.806 (0.613 to 1.060)	NA NA NA NA	60.7 0 - -	0.02 0.451 - -	Random-effect Random-effect Fixed-effect Fixed-effect	0.09 <0.05 >0.05 >0.05
Frequency of required relaxing retinotomy	5	104	0.378 (0.154 to 0.929)	NA	0	0.769	Fixed-effect	0.034
Rate of endotamponade with silicone oil	7	134	0.430 (0.188 to 0.981)	NA	69.1	0.002	Random-effect	0.045

NA, not available; RR, relative risk; VEGF, vascular endothelial growth factor; WMD, weighted mean difference.

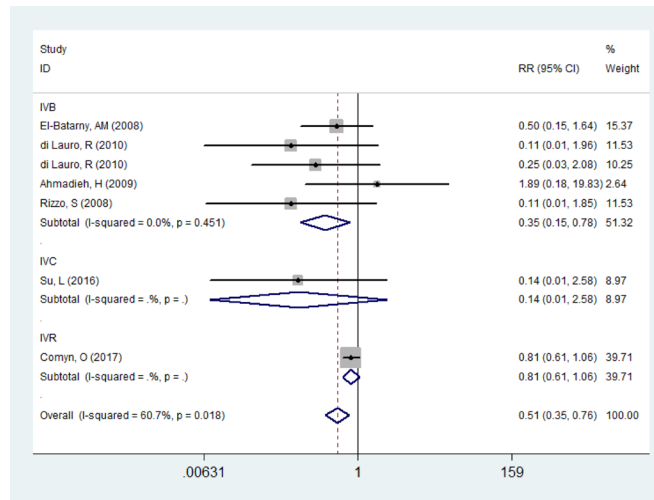


Figure 3 Comparison of the incidence of intraoperative iatrogenic retinal breaks between anti-vascular endothelial growth factor pretreatment group and control group. IVB, intravitreal injection of bevacizumab; IVC, intravitreal injection of conbercept; IVR, intravitreal injection of ranibizumab; RR, relative risk.

analysis discovered that the anti-VEGF agent in Comyn’s study was ranibizumab while others were conbercept or bevacizumab. Therefore, we made subgroup analyses by this factor and the fixed-effect model was selected. The pooling results manifested that bevacizumab pretreatment could significantly reduce the incidence of intraoperative iatrogenic retinal breaks ($P < 0.05$, figure 3), while no significant efficacy in ranibizumab or conbercept group ($P > 0.05$, figure 3). For the duration of surgery, the subgroup analyses showed that bevacizumab and conbercept pretreatment could significantly reduce the duration of surgery ($P < 0.05$), while no significant difference in the ranibizumab group ($P > 0.05$).

As the sensitivity analysis failed to support the subgroup factors like publication year and the heterogeneity of relative subgroup analyses were significantly high, these subgroup analyses were regarded as ineffective.

Postoperative indices

The postoperative indices are summed up in table 4. The results of meta-analysis manifested that the anti-VEGF pretreatment could significantly decrease the rate of recurrent RD, the rate of required secondary surgery for recurrent RD and the vitreous clear-up time of recurrent VH ($P < 0.05$).

For the incidence of recurrent VH, the pooling result by fixed-effect model ($P = 0.274$, $I^2 = 19.7\%$) manifested that the general incidence of postoperative VH in the case group was significantly lower than the control group ($RR = 0.389$, 95% CI 0.255 to 0.594, $P = 0.001$). When dividing the postoperative VH to early recurrent VH and late recurrent VH (4 weeks as cutting point), the results of meta-analysis by fixed-effect model ($P > 0.1$, $I^2 < 50\%$) indicated that preoperative application of anti-VEGF agents could significantly decrease the incidence of early recurrent VH ($RR = 0.421$, 95% CI 0.262 to 0.678, $P = 0.001$, figure 4), while there was no significant difference between case group and control group for late recurrent VH ($RR = 0.657$, 95% CI 0.315 to 1.372, $P = 0.264$).

Publication bias

Using Begg’s test ($P = 0.89$, continuity corrected) and Egger’s test ($P = 0.345$), publication bias was not found to be significant.

Table 4 Summary of postoperative indices

Intraoperative indices	Studies (n)	Sample size		RR (CI)	WMD (CI)	I ² (%)	P of χ^2	Selected model	P for overall effect
		Anti-VEGF group	No anti-VEGF group						
General incidence of recurrent VH	7	134	128	0.389 (0.255 to 0.594)	NA	19.70	0.274	Fixed-effect	0.001
Incidence of early recurrent VH (<4 weeks)	4	120	117	0.421 (0.262 to 0.678)	NA	5.7	0.365	Fixed-effect	0.001
Incidence of early recurrent VH (>4 weeks)	4	120	117	0.657 (0.315 to 1.372)	NA	0	0.697	Fixed-effect	0.264
Vitreous clear-up time of recurrent	2	90	87	NA	-5.829 (-7.079 to -4.579)	0	0.400	Fixed-effect	0.001
The rate of recurrent RD	8	145	139	0.502 (0.200 to 1.260)	NA	0	0.873	Fixed-effect	0.142
Required secondary surgery for recurrent RD	5	126	120	0.598 (0.245 to 1.495)	NA	0	0.978	Fixed-effect	0.259

NA, not available; RD, retinal detachment; RR, relative risk; VEGF, vascular endothelial growth factor; VH, vitreous haemorrhage; WMD, weighted mean difference.

DISCUSSION

Our study found that the pretreatment of anti-VEGF agents before vitrectomy for complicated PDR might facilitate much easier surgery regarding less intraoperative bleeding, less endodiathermy, shorter duration of surgery, less iatrogenic retinal breaks, lower frequency of using silicone oil and relaxing retinotomy. Additionally, anti-VEGF pretreatment could achieve better postoperative BCVA, less early recurrent VH and quicker absorption of recurrent VH. However, the incidence of late recurrent VH, recurrent RD or related secondary surgery could not be reduced.

Preoperatively, some authors expressed their concerns about the formation or aggravation of TRD associated with progressive fibrosis of fibrovascular membrane following the pretreatment of anti-VEGF agents.^{17 28–30} The interval between injection and diabetic vitrectomy of the included studies in our meta-analysis varied from 1 to 20 days, only one participant in each group developed new TRD following injection. Besides, Comyn *et al*¹⁶ used ultrasonography to investigate the impact of anti-VEGF drugs on the extent of TRD prior to surgery, and they found no difference in the progression of TRD between case group and control group. Therefore, based on the current evidence, we suggest that anti-VEGF pretreatment before vitrectomy for complicated PDR is relatively safe and may not induce development or progression of TRD.

Intraoperatively, routine diabetic vitrectomy for complicated PDR has several drawbacks.¹⁵ Many previous studies had investigated the efficacy of anti-VEGF pretreatment on diabetic vitrectomy; however, many intraoperative evaluating indices still had controversies.^{5 16 18}

The forest plots of intraoperative bleeding, frequency of required relaxing retinotomy and endodiathermy in our meta-analysis indicated that the anti-VEGF pretreatment could significantly benefit the diabetic vitrectomy. Some meta-analyses of these indices appeared heterogeneous, and sensitivity analysis and subgroup analyses failed to eliminate the heterogeneity. However, regardless of the exclusion or inclusion of every study, the results were all the same and had clinical agreement, so we conducted these analyses by random-effect model for the reason that all studies were of high quality.

For the incidence of intraoperative iatrogenic retinal breaks and the duration of surgery, Comyn's study¹⁶ was the source of heterogeneity and the anti-VEGF agent in this study was ranibizumab, while others were conbercept or bevacizumab. Although Comyn's study did not influence the final results of other indices in our meta-analysis, we found that it was always the source of heterogeneity. Until now, only this RCT investigated the ranibizumab pretreatment before vitrectomy for complicated PDR. Therefore, we suggest more RCTs are required to further investigate the efficacy of ranibizumab pretreatment.

Silicone endotamponade is always used in the cases of intraoperative complications like severe bleeding, iatrogenic retina breaks or retinotomy. It supports the retina after reattachment, decreases the chance of postoperative VH, provides the longest term tamponade and has additional benefit of non-critical posturing.^{4 17} However, several disadvantages exist, including the certainty of cataract formation and eventual oil removal for visual rehabilitation. The pooling results in our meta-analysis indicated that anti-VEGF pretreatment could significantly reduce the frequency of silicone oil application during vitrectomy for complicated PDR, which partly implied anti-VEGF pretreatment might facilitate easier diabetic vitrectomy and less intraoperative complications.

Postoperatively, recurrent VH after PPV for PDR, which is a major concern for both patients and surgeons, is one of the most common adverse events, with a reported incidence up to 75%.³¹ For patient's side, expectations regarding visual improvement are not achieved, and this is vital for monocular patients; for surgeon's side, recurrent VH prevents clear fundus examination, detection of iatrogenic retinal breaks and further laser therapy.

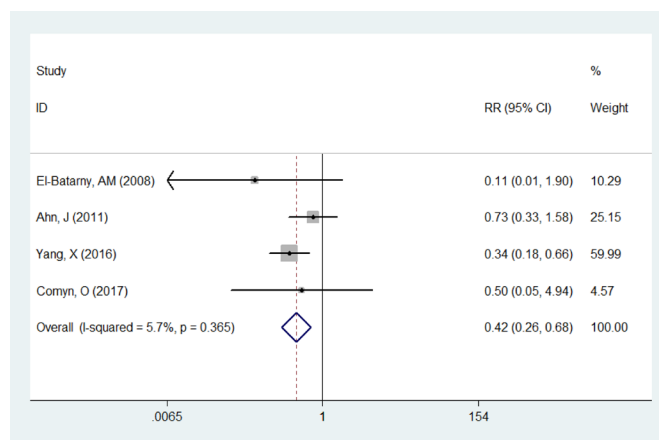


Figure 4 Comparison of the incidence of early recurrent vitreous haemorrhage between anti-vascular endothelial growth factor pretreatment group and control group. RR, relative risk.

To reduce the incidence of recurrent VH, various medications and surgical techniques have been used, but none of them has been shown to be effective.^{32–35} The source of early and late postoperative recurrent VH was reported to be different, and early recurrent VH was associated with dissection of fibrovascular membranes, recurrent bleeding from initial bleeding site, surgically injured retinal tissue and increased vascular permeability; while recurrent neovascularisation was believed to be the crucial cause in late recurrent VH and postoperative recurrent RD.^{5 18 36 37} Our study indicated that anti-VEGF pretreatment might reduce the incidence of early recurrent VH and achieve shorter absorption of recurrent VH, while it has no significant effect on late recurrent VH, recurrent RD or related secondary surgery. These results suggested that anti-VEGF pretreatment could induce the regression of neovascularisation, cessation of haemorrhage from all potential bleeding sources and reintegration of retinal vascular tissue. However, as anti-VEGF agents could only provide complete VEGF blockade for about 4 weeks and almost all the amount of anti-VEGF agents injected preoperatively would be removed during vitrectomy,^{4 38} panretinal photocoagulation should be done adequately during and post surgery to prevent recurrent neovascularisation and reduce the incidence of late recurrent VH and postoperative recurrent RD.

Postoperative BCVA is determined by many factors such as preoperative VA, intraoperative side injury and postoperative complications. Our meta-analysis detected significant better postoperative BCVA in the anti-VEGF pretreatment group, while no statistical difference existed in preoperative BCVA, which also suggests that anti-VEGF pretreatment might reduce the intraoperative side injury and postoperative complications.

To our knowledge, this is the first meta-analysis which includes all the available data of high quality and considers all the pivotal indices to re-evaluate the efficacy of intravitreal injection of anti-VEGF agents before vitrectomy for complicated PDR in order to provide a reference for the decision-making of ophthalmologists. However, it has the following limitations: (1) the inconsistent interval between injection and diabetic vitrectomy, which varies from 1 day to 20 days, might potentially influence the results of our study; (2) although we had pooled the data of all the available studies to get the results through the most reliable way, the final sample size was still relatively small, which means more high-quality research should be carried out; and (3) there were insufficient data to compare the efficacy of different anti-VEGF agents.

CONCLUSIONS

Based on the available evidence, pretreatment of anti-VEGF agents before vitrectomy for complicated PDR could facilitate much easier surgery and achieve better postoperative BCVA, less early recurrent VH and quicker absorption of recurrent VH. However, the incidence of late recurrent VH, recurrent RD or related secondary surgery could not be reduced.

Moreover, better-designed studies with larger sample sizes are required to further evaluate the efficacy of different anti-VEGF agents and reach a firmer conclusion.

Acknowledgements The authors thank Sheng-zhi Liu for the assistance of language.

Contributors XYZ carried out the entire procedure including the literature search, data extraction, performed the statistical analysis, drafted the manuscript and revised submitted the manuscript. YXC conceived of the study, coordinated and participated in the entire process of drafting and revised the manuscript. SX contributed to statistical analysis and revision the manuscript. All authors read and approved the final manuscript.

Competing interests None declared.

Provenance and peer review Not commissioned; externally peer reviewed.

Open access This is an open access article distributed in accordance with the Creative Commons Attribution Non Commercial (CC BY-NC 4.0) license, which permits others to distribute, remix, adapt, build upon this work non-commercially, and license their derivative works on different terms, provided the original work is properly cited and the use is non-commercial. See: <http://creativecommons.org/licenses/by-nc/4.0/>

© Article author(s) (or their employer(s) unless otherwise stated in the text of the article) 2018. All rights reserved. No commercial use is permitted unless otherwise expressly granted.

REFERENCES

- Klein BE. Overview of epidemiologic studies of diabetic retinopathy. *Ophthalmic Epidemiol* 2007;14:179–83.
- Xie XW, Xu L, Jonas JB, et al. Prevalence of diabetic retinopathy among subjects with known diabetes in China: the Beijing eye study. *Eur J Ophthalmol* 2009;19:91–9.
- Blankenship GW, Machefer R. Long-term diabetic vitrectomy results. Report of 10 year follow-up. *Ophthalmology* 1985;92:503–6.
- El-Batarny AM. Intravitreal bevacizumab as an adjunctive therapy before diabetic vitrectomy. *Clin Ophthalmol* 2008;2:709–16.
- Yang X, Xu J, Wang R, et al. A randomized controlled trial of conbercept pretreatment before vitrectomy in proliferative diabetic retinopathy. *J Ophthalmol* 2016;2016:1–8.
- Shi L, Huang YF. Postvitrectomy diabetic vitreous hemorrhage in proliferative diabetic retinopathy. *J Res Med Sci* 2012;17:865–71.
- Wisniewska-Kruk J, Klaassen I, Vogels IM, et al. Molecular analysis of blood-retinal barrier loss in the Akimba mouse, a model of advanced diabetic retinopathy. *Exp Eye Res* 2014;122:123–31.
- Moreira Y, González R, Lamdan H, et al. Vaccination with a mutated variant of human Vascular Endothelial Growth Factor (VEGF) blocks VEGF-induced retinal neovascularization in a rabbit experimental model. *Exp Eye Res* 2014;122:102–9.
- Smith JM, Steel DH. Anti-vascular endothelial growth factor for prevention of postoperative vitreous cavity haemorrhage after vitrectomy for proliferative diabetic retinopathy. *Cochrane Database Syst Rev* 2015:CD008214.
- Pakzad-Vaezi K, Albani DA, Kirker AW, et al. A randomized study comparing the efficacy of bevacizumab and ranibizumab as pre-treatment for pars plana vitrectomy in proliferative diabetic retinopathy. *Ophthalmic Surg Lasers Imaging Retina* 2014;45:521–4.
- Simunovic MP, Maberley DA. Anti-vascular endothelial growth factor therapy for proliferative diabetic retinopathy: a systematic review and meta-analysis. *Retina* 2015;35:1931–42.
- Zhang ZH, Liu HY, Hernandez-Da Mota SE, et al. Vitrectomy with or without preoperative intravitreal bevacizumab for proliferative diabetic retinopathy: a meta-analysis of randomized controlled trials. *Am J Ophthalmol* 2013;156:106–15.
- Zhao LQ, Zhu H, Zhao PQ, et al. A systematic review and meta-analysis of clinical outcomes of vitrectomy with or without intravitreal bevacizumab pretreatment for severe diabetic retinopathy. *Br J Ophthalmol* 2011;95:1216–22.
- Su L, Ren X, Wei H, et al. Intravitreal conbercept (kh902) for surgical treatment of severe proliferative diabetic retinopathy. *Retina* 2016;36:938–43.
- Hernández-Da Mota SE, Nuñez-Solorio SM. Experience with intravitreal bevacizumab as a preoperative adjunct in 23-G vitrectomy for advanced proliferative diabetic retinopathy. *Eur J Ophthalmol* 2010;20:1047–52.
- Comyn O, Wickham L, Charteris DG, et al. Ranibizumab pretreatment in diabetic vitrectomy: a pilot randomised controlled trial (the RaDiVit study). *Eye* 2017;31:1253–8.
- Farahvash MS, Majidi AR, Roohipoor R, et al. Preoperative injection of intravitreal bevacizumab in dense diabetic vitreous hemorrhage. *Retina* 2011;31:1254–60.
- Ahn J, Woo SJ, Chung H, et al. The effect of adjunctive intravitreal bevacizumab for preventing postvitrectomy hemorrhage in proliferative diabetic retinopathy. *Ophthalmology* 2011;118:2218–26.
- Moher D, Liberati A, Tetzlaff J, et al. Preferred reporting items for systematic reviews and meta-analyses: the PRISMA statement. *J Clin Epidemiol* 2009;62:1006–12.
- Furlan AD, Pennick V, Bombardier C, et al. 2009 updated method guidelines for systematic reviews in the Cochrane Back Review Group. *Spin* 2009;34:1929–41.
- Egger M, Davey Smith G, Schneider M, et al. Bias in meta-analysis detected by a simple, graphical test. *BMJ* 1997;315:629–34.
- Sohn EH, He S, Kim LA, et al. Angiofibrotic response to vascular endothelial growth factor inhibition in diabetic retinal detachment: report no. 1. *Arch Ophthalmol* 2012;130:1127–34.
- Han XX, Guo CM, Li Y, et al. Effects of bevacizumab on the neovascular membrane of proliferative diabetic retinopathy: reduction of endothelial cells and expressions of VEGF and HIF-1 α . *Mol Vis* 2012;18:1–9.
- di Lauro R, De Ruggiero P, di Lauro R, et al. Intravitreal bevacizumab for surgical treatment of severe proliferative diabetic retinopathy. *Graefes Arch Clin Exp Ophthalmol* 2010;248:785–91.

- 25 Modarres M, Nazari H, Falavarjani KG, *et al.* Intravitreal injection of bevacizumab before vitrectomy for proliferative diabetic retinopathy. *Eur J Ophthalmol* 2009;19:848–52.
- 26 Ahmadi H, Shoeibi N, Entezari M, *et al.* Intravitreal bevacizumab for prevention of early postvitrectomy hemorrhage in diabetic patients: a randomized clinical trial. *Ophthalmology* 2009;116:1943–8.
- 27 da R Lucena D, Ribeiro JA, Costa RA, *et al.* Intraoperative bleeding during vitrectomy for diabetic tractional retinal detachment with versus without preoperative intravitreal bevacizumab (IBeTra study). *Br J Ophthalmol* 2009;93:688–91.
- 28 Rizzo S, Genovesi-Ebert F, Di Bartolo E, *et al.* Injection of intravitreal bevacizumab (Avastin) as a preoperative adjunct before vitrectomy surgery in the treatment of severe proliferative diabetic retinopathy (PDR). *Graefes Arch Clin Exp Ophthalmol* 2008;246:837–42.
- 29 Van Geest RJ, Lesnik-Oberstein SY, Tan HS, *et al.* A shift in the balance of vascular endothelial growth factor and connective tissue growth factor by bevacizumab causes the angiofibrotic switch in proliferative diabetic retinopathy. *Br J Ophthalmol* 2012;96:587–90.
- 30 Arevalo JF, Maia M, Flynn HW, *et al.* Tractional retinal detachment following intravitreal bevacizumab (Avastin) in patients with severe proliferative diabetic retinopathy. *Br J Ophthalmol* 2008;92:213–6.
- 31 Schachat AP, Oyakawa RT, Michels RG, *et al.* Complications of vitreous surgery for diabetic retinopathy. II. Postoperative complications. *Ophthalmology* 1983;90:522–30.
- 32 Yang CM, Yeh PT, Yang CH. Intravitreal long-acting gas in the prevention of early postoperative vitreous hemorrhage in diabetic vitrectomy. *Ophthalmology* 2007;114:710–5.
- 33 Ramezani AR, Ahmadi H, Ghaseminejad AK, *et al.* Effect of tranexamic acid on early postvitrectomy diabetic haemorrhage; a randomised clinical trial. *Br J Ophthalmol* 2005;89:1041–4.
- 34 Packer AJ, McCuen BW, Hutton WL, *et al.* Procoagulant effects of intraocular sodium hyaluronate (Healon) after phakic diabetic vitrectomy. A prospective, randomized study. *Ophthalmology* 1989;96:1491–4.
- 35 Joondeph BC, Blankenship GW. Hemostatic effects of air versus fluid in diabetic vitrectomy. *Ophthalmology* 1989;96:1701–6.
- 36 Williams DF, Burke JM, Williams GA. Clearance of experimental vitreous hemorrhage after panretinal cryotherapy is related to macrophage influx. *Arch Ophthalmol* 1990;108:595–7.
- 37 Li T, Hu J, Du S, *et al.* ERK1/2/COX-2/PGE2 signaling pathway mediates GPR91-dependent VEGF release in streptozotocin-induced diabetes. *Mol Vis* 2014;20:1109–21.
- 38 Beer PM, Wong SJ, Hammad AM, *et al.* Vitreous levels of unbound bevacizumab and unbound vascular endothelial growth factor in two patients. *Retina* 2006;26:871–6.