

Hepatic encephalopathy coexists with acquired chronic hepatocerebral degeneration

Feng-Zhen Huang, MSc, Xuan Hou, MSc, Tie-Qiao Zhou, BSc, Si Chen, MD.

ABSTRACT

تعد متلازمة فرط الحركة خارج الهرمية السمة النموذجية المكتسبة لانحطاط الكبد الدماغى (AHD) والتي لا تلاحظ مع الاعتلال الدماغى الكبدى (HE). نستعرض هنا حالة AHD ظهرت مع HE. كلا الحالتين كانت ثانوية لتليف الكبد وعدوى فيروس التهاب الكبد C. اظهر التصوير بالرنين المغناطيسى الدماغى إشارة عالية الكثافة ثنائية ومتماثلة في شاحبة غلوبوس، وانتشار عالي الكثافة للمادة البيضاء في نصف الكرة الأرضية على ميل الصورة T2. وعادة يبقى وجود AHD ويتم تجاهل التشخيص وخاصة عندما يظهر مع HE، تسلط هذه الحالة الضوء على ضرورة تمييز AHD لا تغيير فيه.

Hyperkinetic extrapyramidal syndrome is the typical clinical characteristic of acquired hepatocerebral degeneration (AHD), but is usually not observed with hepatic encephalopathy (HE). We present a case of AHD coexisting with HE. Both conditions were secondary to liver cirrhosis and hepatitis C virus infection. The brain MRI showed bilateral and symmetric high T1 signal-intensity in the globus pallidus, and diffuse high signal-intensity of the hemispheric white matter on T2-FLAIR images. As we usually neglect the existence of AHD, the diagnosis is often ignored, especially when it coexists with HE. This case highlights the need to distinguish irreversible AHD from HE.

Neurosciences 2015; Vol. 20 (3): 277-279
doi: 10.17712/nsj.2015.3.20140759

From Department of Neurology (Hou, Chen), Xiangya Hospital, Central South University, Changsha, the Department of Neurology & Institute of Translational Medicine at University of South China (Huang), and the Department of Laboratory Medicine & Institute of Translational Medicine at University of South China (Zhou), the First People's Hospital of Chenzhou, Chenzhou, Hunan, P. R. China.

Reserved 9th December 2014. Accepted 27th April 2015.

Address correspondence and reprint request to: Dr. Si Chen, Department of Neurology, Xiangya Hospital, Central South University, Changsha, Hunan 410008, China. E-mail: sichenhfz114@126.com

Progressive chronic liver disease often causes neurological manifestation, including hepatic encephalopathy (HE), acquired hepatocerebral degeneration (AHD), and hepatic myelopathy (HM). Among these dysfunctions, HE is the most common and reversible disorder, while AHD is a rare and irreversible syndrome. Hepatic encephalopathy is a serious complication of liver disease and is characterized by neuropsychiatric symptoms, which range from subtle neurocognitive alterations to severe life-threatening neurological impairment.^{1,2} Hepatic encephalopathy presents in as many as 28% of patients with liver cirrhosis, and can be alleviated by lowering the blood ammonia levels.^{1,2} However, AHD is rare and the best result among the possible treatments is orthotopic liver transplantation.³ The prevalence of this disease is between 0.8-2% of cirrhotic patients. Of note, the more relevant risk factors are the presence of portosystemic shunts and the multiple bouts of hepatic coma seen in some patients with HE.^{4,5} Acquired hepatocerebral degeneration is a progressive, irreversible neurological syndrome caused by persistent and decompensated liver disease, and characterized by abnormal movements, dysarthria, rigidity, intention tremor, ataxia, and impairment of intellectual functions.⁶ In AHD physiopathology, manganese accumulation in the basal nuclei appears to be a key factor. This metal concentration is responsible for the MRI T1 hyperintensity mainly involving the basal ganglia, which can be considered a biomarker of manganese overload.^{3,6} Hepatic encephalopathy and AHD are 2 different CNS disorders secondary to hepatic dysfunction. Hyperkinetic extrapyramidal syndrome is the typical clinical characteristic of AHD, but usually not observed in HE. Here, we describe a case coexisting with HE and AHD in the presence of symmetrical basal ganglia high signal intensity on T1-weighted images and widespread T2 high signal intensity of the hemispheric white matter. Our objective in presenting this particular case is to highlight the presence of AHD that is considered rare as the diagnosis tends to be ignored.

Case Report. A 65-year-old woman with cirrhosis due to hepatitis C infection was submitted for a splenectomy in 2011 in order to control an upper gastrointestinal bleed. Since 2012, she had at least 3 episodes of mental and behavioral disorders, which were alleviated by lowering the blood ammonia. She had progressive bradykinesia and dysarthria, which could not be mitigated by common therapy. Before her first visit to our hospital, the extrapyramidal symptoms worsened. In April, 2013, she fell into a coma after a high protein diet, and was admitted to our hospital for further treatment. In the emergency room, serum electrolytes, serum glucose, and the renal function tests were normal, while the hepatic tests were as follows: aspartate aminotransferase (AST) 29.6 IU/L (0 to 40 IU/L as normal), alanine transaminase (ALT) 62.5 IU/L (0 to 40 IU/L as normal), total bilirubin 15.5 μ mol/L (0 to 17.1 IU/L as normal). The initial blood ammonia was elevated to 158.5 mmol/L (0 to 47 mmol/L as normal). Hepatitis B virus antibodies were negative. A diffuse theta slow wave pattern was seen on EEG. The brain MRI 3.0 T scan revealed bilateral

and symmetrical T1 high-intensity of the basal ganglia (Figure 1A) associated with widespread high-signal intensity of the brain hemispheric white matter on fast T2 and T2-FLAIR sequences (Figures 1B & 1C) without diffusivity restriction (high signal intensity on the apparent diffusion coefficient [ADC] map) indicating that the signal abnormality corresponded to interstitial edema (Figures 1D & 1E). From these clinical and laboratory findings, the diagnosis could be limited to liver cirrhosis, hepatitis C, and HE. After conventional HE treatment, her level of consciousness recovered on the fourth day. However, as she already had signs of AHD according to the MRI exams, the diagnosis of AHD was also considered, and she maintained the extrapyramidal symptoms. Accordingly, as in this patient HE coexisted with AHD, these findings remind us that these 2 conditions can be found in the same patient, and the diagnosis of AHD must be made as soon as possible due to the severity of the disease.

Discussion. The classical pathogenesis of HE is the ammonia accumulation in the blood, thus

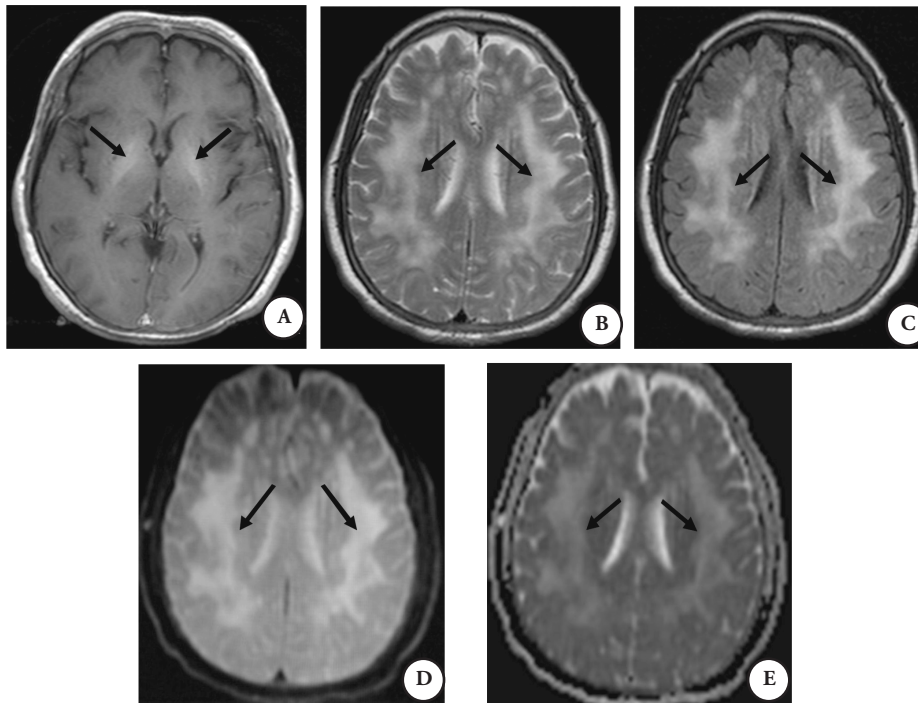


Figure 1 - Brain MRI acquired at 3.0T. A) T1-weighted images show bilateral and symmetric high-intensity of the globus pallidus, which reflects abnormal manganese deposition related to acquired hepatocerebral degeneration. B & C) Diffuse high-intensity in subcortical hemispheric white matter was observed on T2-weighted images. (D & E) The lesions were mildly hyperintense on DWI and unequivocally hyperintense on the ADC map likely reflecting interstitial edema secondary to hyperammonemia.

reaching the CNS.¹ The T2 hyperintensity seen on T2-weighted images is a common finding in patients with HE. The lesions can be observed on the cortex or in a diffuse pattern on the white matter, and may be related to the focal injuries caused by increased ammonia concentration.⁷ On the other hand, the AHD pathogenesis still has some unknown components. The high-intensity pattern on the basal ganglia seen on T1-weighted sequences at MRI suggests the diagnosis of AHD.⁸ Liver failure seems to be directly responsible for the manganese accumulation, which may contribute to the extrapyramidal symptoms.⁶ The bilateral and symmetric T1 high-intensity alterations involving the globus pallidus are often observed in AHD because of the manganese deposition.⁶

In this case, the patient had hepatitis C infection and liver cirrhosis, and the consciousness impairment was caused by HE. Thus, it was alleviated after lowering the serum ammonia levels. The widespread white matter signal abnormalities likely reflecting interstitial edema (Figures 1B-1E) was considered as a result of the toxic involvement related to the liver disease, and ammonia is probably implicated in its development.⁹ Thus, the progressive development of extrapyramidal symptoms was a characteristic feature of AHD. Moreover, the bilateral globus pallidus hyperintensity on T1-weighted images was also a typical AHD finding, leading to the diagnosis of AHD associated to HE.

To date there is no consensus on whether repeated HE episodes constitute a key factor in AHD development.¹⁰ Thus, it is still a challenge to distinguish AHD from HE, especially when these 2 disorders coexist. We should learn more to guide early intervention and treatment, especially from the noninvasive and objective MRI findings. Although the pathogenesis of AHD remains partially unknown and shares some aspects with HE, it is important to realize that AHD is a more severe disease. Therefore, more attention should be focused on preventing such diseases, and physicians must be aware that the lack of response after HE treatment can be a clue for AHD. For patients who could not be submitted to

orthotopic liver transplantation, the flow interruption in portosystemic shunts should be considered to avoid the development of neurological sequelae.

Acknowledgments. *The figures in the text were reviewed by the radiologists Xiaosu Yang (MD) and Wenbin Zhou (MD).*

References

1. Sturgeon JP, Shawcross DL. Recent insights into the pathogenesis of hepatic encephalopathy and treatments. *Expert Rev Gastroenterol Hepatol* 2014; 8: 83-100.
2. Dhiman RK, Kurmi R, Thumburu KK, Venkataramarao SH, Agarwal R, Duseja A, et al. Diagnosis and prognostic significance of minimal hepatic encephalopathy in patients with cirrhosis of liver. *Dig Dis Sci* 2010; 55: 2381-2390.
3. Maffeo E, Montuschi A, Stura G, Giordana MT. Chronic acquired hepatocerebral degeneration, pallidal T1 MRI hyperintensity and manganese in a series of cirrhotic patients. *Neurol Sci* 2014; 35: 523-530.
4. Stracciari A, Baldin E, Cretella L, Delaj L, D'Alessandro R, Guarino M. Chronic acquired hepatocerebral degeneration: effects of liver transplantation on neurological manifestations. *Neurol Sci* 2011; 32: 411-415.
5. Ishihara T, Ito M, Watanabe H, Ishigami M, Kiuchi T, Sobue G. [Case of acquired hepatocerebral degeneration with prominent improvement of parkinsonism and cognitive deficits after living-donor liver transplantation]. *Rinsho Shinkeigaku* 2012; 52: 581-584. Japanese
6. Fernández-Rodríguez R, Contreras A, De Villoria JG, Grandas F. Acquired hepatocerebral degeneration: clinical characteristics and MRI findings. *Eur J Neurol* 2010; 17: 1463-1470.
7. Alonso J, Córdoba J, Rovira A. Brain magnetic resonance in hepatic encephalopathy. *Semin Ultrasound CT MR* 2014; 35: 136-152.
8. Erro R, Vitale C, Picillo M, Barone P, Pellecchia MT. Early MRI findings in acquired hepatocerebral degeneration. *Neurol Sci* 2013; 34: 589-591.
9. Chavarria L, Alonso J, García-Martínez R, Simón-Talero M, Ventura-Cots M, Ramírez C, et al. Brain magnetic resonance spectroscopy in episodic hepatic encephalopathy. *J Cereb Blood Flow Metab* 2013; 33: 272-277.
10. Romeiro FG, Américo MF, Yamashiro FS, Caramori CA, Schelp AO, Santos AC, et al. Acquired hepatocerebral degeneration and hepatic encephalopathy: correlations and variety of clinical presentations in overt and subclinical liver disease. *Arg Neuropsiquiatr* 2011; 69: 496-501.