




Contents lists available at ScienceDirect

# Journal of Clinical Tuberculosis and Other Mycobacterial Diseases

journal homepage: [www.elsevier.com/locate/jctube](http://www.elsevier.com/locate/jctube)

## Fifteen-year clinical experience with *Mycobacterium haemophilum* at the Mayo Clinic: A case series

Harmony L. Tyner<sup>a,\*</sup>, John W. Wilson<sup>b</sup><sup>a</sup> St. Luke's Infectious Disease Associates, 920 First St., Duluth, MN 55805, United States<sup>b</sup> Division of Infectious Diseases, Mayo Clinic, 200 First St., Rochester, MN 55905, United States

### ARTICLE INFO

#### Article history:

Received 20 December 2016

Revised 12 June 2017

Accepted 17 June 2017

#### Keywords:

*Mycobacterium haemophilum*

Acid fast bacilli

Case series

### ABSTRACT

*Mycobacterium haemophilum* is an uncommonly encountered acid-fast staining bacillus (AFB) that can cause a broad range of infections. We describe a tertiary care center's experience with *M. haemophilum* infections identified from 2000 to 2015. Ten adult patients were identified with *M. haemophilum* infections, and most had immunocompromising conditions. *M. haemophilum* presented in one of two syndromes: a peripheral cutaneous infection presenting with skin nodularity and local invasion, and a cervicofacial infection involving regional lymph nodes. Duration of therapy was variable (0–18 months) and was dependent on the underlying syndrome and immunological status of the patient. Treatment responses were favorable in all patients. During therapy, three patients developed culture-negative aseptic cutaneous lesions, consistent with immunologic reconstitution inflammatory syndrome (IRIS); we postulate that such reactions may not be uncommon with select *M. haemophilum* infections.

© 2017 The Authors. Published by Elsevier Ltd.

This is an open access article under the CC BY-NC-ND license.

<http://creativecommons.org/licenses/by-nc-nd/4.0/>

### 1. Introduction

*M. haemophilum* is an acid-fast bacillus that has a wide geographic distribution, having been described in many parts of the world including France, the United Kingdom, Israel, parts of Africa, Australia, Canada, the US, and Brazil. Similar to *M. ulcerans*, *M. haemophilum* has been isolated from the environment but also has been found in several species of animals as well as causing human infection.

Distinct from most other non-TB mycobacteria (NTM), *M. haemophilum* in vitro growth requires a lower incubation temperature and hemin or iron supplementation. *M. haemophilum* is unable to synthesize iron-binding siderophores, therefore it requires iron supplementation to grow in culture [1–6]. Its preference for lower temperatures, similar to that of *M. leprae* and *M. marinum*, has been associated with a predilection for clinical infections to be located over the extremities.

With its fastidious growth requirements, *M. haemophilum* may be underdiagnosed and more prevalent than previously reported. It can cause localized or disseminated infection usually in patients with an underlying immunomodulatory condition such as

HIV/AIDS, organ transplant, and autoimmune disorders on immune modulation [7–9]. The source of *M. haemophilum* often is from environmental habitats, specifically water reservoirs [1,10–13]. While most reported cases do not have a clearly identified source, infection in adults has been associated with tattoo parlors, acupuncture needles, and select therapeutic or diagnostic interventions [6,13–16].

### 2. Methods

We conducted a retrospective case review with Institutional Review Board approval, of all patents seen at Mayo Clinic in Rochester, MN from 2000 to 2015 from whom *M. haemophilum* was isolated in culture by our clinical mycobacterial laboratory. The patients' medical records including clinical assessments, surgical and pathology reports, laboratory and microbiology data, imaging studies, and medications were reviewed. Ten adult patients (no pediatric cases) were identified with *M. haemophilum* infection.

### 3. Results

#### 3.1. Patient cases

**Case 1** is a 63 year old man with a history of polyarteritis nodosa who treated with Cytoxan for 6 months, followed by a

\* Corresponding author.

E-mail address: [harmony.tyner@slhduluth.com](mailto:harmony.tyner@slhduluth.com) (H.L. Tyner).

transition to Azathioprine and 10 mg prednisone. Six months after transitioning to Azathioprine and prednisone, he developed a nodule on his arm with erythema extending to the left hand. An MRI demonstrated moderate tenosynovitis of the flexor and extensor tendons of the left hand extending into the distal forearm. Intra-operatively, areas of necrotic subcutaneous tissue which were overlying small reticular cysts were encountered and surgically resected (Fig. 1a). Tissue pathology showed necrotizing granulomas with acid fast staining bacilli (AFB) present. Multiple intra-operative cultures grew *M. haemophilum* after 33 days. Antimicrobial drug susceptibility testing (DST) is listed in Table 2. The patient was treated with oral clarithromycin and Moxifloxacin for 4 months with complete disease resolution.

**Case 2** is 82 year old man with a history of B-cell Chronic Lymphocytic Leukemia and hypogammaglobulinemia who was previously treated with fludarabine followed by rituximab, cyclophosphamide, doxorubicin, vincristine and prednisone (R-CHOP). After restarting treatment with rituximab, he developed acute swelling at the tip of his right finger with significant erythema. The patient had surgical exploration of the finger identifying necrotic tissue extending to the bone and subsequent amputation through the distal interphalangeal joint. Acid fast staining was not done on the resected tissue; however, tissue cultures grew *M. haemophilum* and *Pseudomonas aeruginosa*. Antimicrobial DST was not performed, and the patient fully recovered post-operatively and with 2 weeks of ciprofloxacin and doxycycline.

**Case 3** is a 53 year old man with a history of Chronic Lymphocytic Leukemia treated with pentostatin, alemtuzumab, and rituximab. He developed shingles over his upper right arm and left chest along with palpable nodular areas of induration at both sites with intermittent drainage (Fig. 1b). The area was biopsied and showed necrotizing granulomatous inflammation and deep dermal granulomatous inflammation with necrosis, with acid-fast positive organisms. One of four cultures was positive for *M. haemophilum* growth after 33 days. Antimicrobial DST is listed in Table 2. He was treated with daily Clarithromycin Moxifloxacin and Doxycycline for a total of 4 months and with complete recovery.

**Case 4** is an 84 year old woman with a history of polymyalgia rheumatica and a seronegative inflammatory arthritis managed with daily prednisone and mycophenolate mofetil. She developed non-tender, weeping, non-pruritic nodules on both legs (Fig. 1c) that were subsequently biopsied. Tissue pathology showed palisading dermal granulomatous inflammation with subtle features of necrobiosis, features consistent with granuloma annulare. AFB stains were negative but one of two tissue biopsies grew *M. haemophilum* after 35 days. Antimicrobial DST is listed in Table 2. She was treated initially with Clarithromycin, rifabutin, and ciprofloxacin, and subsequently had a changed to Azithromycin, Moxifloxacin and rifampin because of suspected drug intolerance. After 4 months of therapy, some nodules improved while others worsened and a few new skin nodules developed as well. Repeated tissue biopsies showed positive stains for AFB; however, all mycobacterial cultures remained uniformly negative. The patient passed away from unrelated causes after 9 months of therapy.

**Case 5** is a 74 year old woman receiving methotrexate and etanercept for rheumatoid arthritis and with a history of recurrent carcinoma of the tongue, treated with resection and radiation. She developed a rash on her cheek with small, inflamed pustular lesions which later became ulcerative (Fig. 1d). Tissue biopsies showed ruptured folliculitis with mixed dermal and granulomatous inflammation. Two

of three biopsies stained positive for AFB, and one of two cultures grew *M. haemophilum* after 30 days. Antimicrobial DST is listed in Table 2. She was treated successfully with 9 months of Clarithromycin.

**Case 6** is a 72 year old man with a history of seronegative rheumatoid arthritis managed with infliximab, methotrexate, prednisone, and abatacept. He developed painful red nodules and plaques on both upper and lower extremities (Fig. 1e). Tissue biopsies showed patchy dermal and subcutaneous granulomatous inflammation and all tissue specimens stained positive for AFB. Two tissue cultures grew *M. haemophilum* after 23 days, and *M. haemophilum* eventually grew from a blood culture as well. Antimicrobial DST is listed in Table 2. He was treated initially with Azithromycin, Rifampin, and amikacin for 3 months with near-resolution of symptoms and was then transitioned to Azithromycin plus rifampin to complete 12 months of therapy. At the end of 12 months of therapy, he was maintained on azithromycin and doxycycline chronic suppression.

**Case 7** is a 63 year old immunocompetent woman who spontaneously developed a large, tender left cervical lymph node over the course of 2 months. This was surgically excised with pathology showing necrotizing granulomatous inflammation. Tissue staining for AFB was negative; however, one of two tissue cultures grew *M. haemophilum* after 33 days. The isolate was not sent for DST, and she was not treated with any antimicrobials (treated with excision alone). After surgical lymph node resection the patient was symptom free and without disease recurrence.

**Case 8** is a 52 year old woman with a history of systemic lupus erythematosus, treated with cyclophosphamide, azathioprine, and corticosteroids developed proximal interphalangeal joint edema along with skin nodules over the right hand, arm and leg (Fig. 1f). Multiple tissue biopsies of the nodules were done and stained positive for AFB. Five of 13 cultures grew *M. haemophilum* after 60 days (leg cutaneous biopsy), 76 days (synovium), and 80 days (arm cutaneous biopsy). Antimicrobial DST is listed in Table 2. She was treated with azithromycin, rifabutin, and amikacin, with subsequent discontinuation of amikacin secondary to ototoxicity. While on therapy, most of her cutaneous findings improved, although a few new skin nodules emerged after therapy was initiated. Additional tissue biopsies of the new nodules were performed; AFB staining was negative and mycobacterial, fungal and bacterial cultures remained uniformly culture negative. The patient completed 18 months of combination antimicrobial therapy with eventual resolution of all skin lesions.

**Case 9** is a 65 year old woman with a history of seronegative rheumatoid arthritis controlled with methotrexate and who developed an almond-sized tender mass on her left neck. The mass was partially resected, as it encased the internal carotid artery. Tissue pathology showed necrotizing granulomatous inflammation that stained AFB positive. Tissue cultures grew *M. haemophilum* after 34 days. Antimicrobial DST is listed in Table 2. She was treated with azithromycin, moxifloxacin, and Rifampin, for 1 year. Several months after starting combination antimicrobial therapy, a neck MRI showed an increasing size of the mass. Further surgical resection of the mass was performed and tissue histology again showed necrotizing granulomatous inflammation with rare AFB present. Mycobacterial cultures, however, remained negative. The patient completed a 1 year combination antimicrobial therapy without disease recurrence.

**Case 10** is a 43 year old male recipient of a living related donor kidney transplant (for focal segmental glomerulosclerosis)

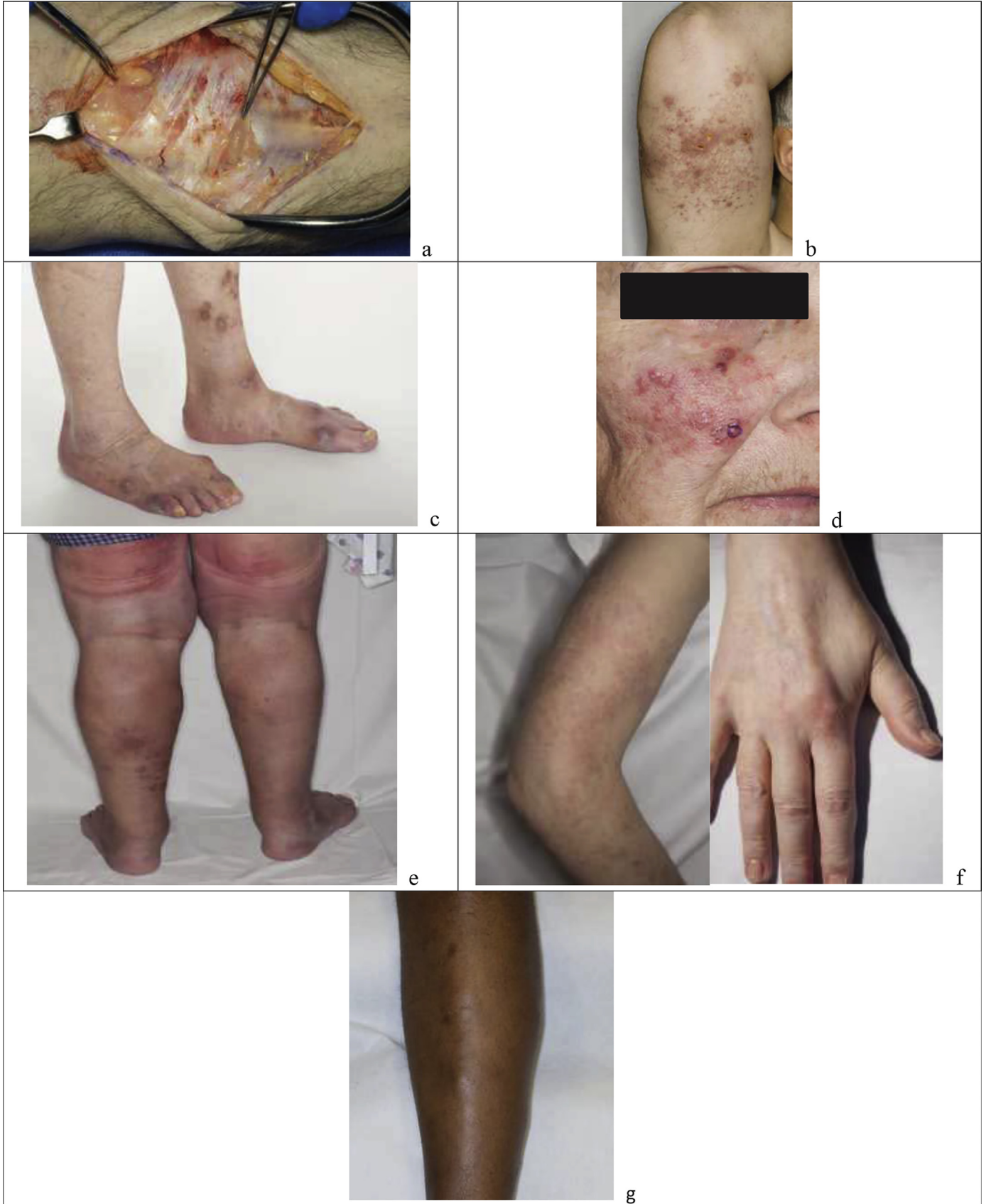

Fig. 1. *M. haemophilum* clinical presentations.

**Table 1**  
Patient characteristics, disease types and therapies.

Case	Gender	Age	Comorbidities	Immunosuppression	Disease site	Treatment	Response
1	M	63	PAN	Cytoxan, Azathioprine/Prednisone	Forearm/wrist	4 months: Rifampin, Clarithromycin, Moxifloxacin	Complete resolution
2	M	82	CLL, Hypogammaglobulinemia	Rituxan	Finger tip	2 weeks: Ciprofloxacin, Doxycycline	Complete resolution
3	M	53	CLL	Pentostatin/alemtuzumab, rituximab	Right upper arm and left chest skin lesions	4 months: Clarithromycin, Moxifloxacin, Doxycycline	Complete resolution
4	F	84	Seronegative arthritis, PMR	Prednisone 10 mg/CellCept	Bilateral legs	Azithromycin Moxifloxacin Rifampin	Patient responded to therapy but developed suspected IRIS; deceased secondary to unrelated causes
5	F	74	RA, Recurrent carcinoma of the tongue, radiation	Methotrexate, etanercept	Cheek	Clarithromycin for 9 months, and Minocycline for 4 months	Complete resolution
6	M	72	Seronegative RA	Remicade, methotrexate, prednisone 10 mg, abatacept	Leg, arm, cheek, blood.	12 months: Azithromycin, Rifampin Doxycycline chronic suppression with Azithromycin and Doxycycline	Resolution of symptoms. Chronic suppression.
7	F	63	None	None	Cervical lymph node	No antimicrobial therapy; surgical excision alone	Complete resolution
8	F	52	SLE	Cytoxan, Imuran, Methylprednisolone 12 mg	Joint swelling with nodules on the extremities	18 months: Azithromycin Rifabutin Doxycycline	Patient responded to therapy but developed suspected IRIS
9	F	65	Seronegative RA	Methotrexate	Neck	12 months: Azithromycin Moxifloxacin Rifampin	Patient responded to therapy but developed suspected IRIS
10	M	42	Kidney Transplant	Prograf, CellCept, Tacrolimus	Bilateral legs	12 months: Azithromycin Ciprofloxacin Rifabutin	Patient responded to therapy; completed therapy elsewhere

PAN = polyarteritis nodosum.  
 CLL = chronic lymphocytic leukemia.  
 RA = rheumatoid arthritis.  
 SLE = systemic lupus erythematosus.

managed with tacrolimus and mycophenolate mofetil. One year after his renal transplant, he developed skin nodules on his lower legs (Fig. 1g). Skin punch biopsies were performed and showed subcutaneous palisaded and interstitial granulomatous inflammation with collagen necrobiosis, fibrosis, and associated lymphocytic inflammation. AFB staining of the tissue was negative; however, tissue culture grew *M. haemophilum* after 29 days. Antimicrobial DST is listed in Table 2. He was treated with azithromycin, ciprofloxacin, and rifabutin with an anticipated duration of 12 months. After 2 months' therapy, the skin lesions were notably improved and care was transferred to a provider closer to home.

## 4. Findings

### 4.1. Patient features

There was an even distribution of men (5) to women (5) (Table 1). The age range was 42–84 years, with an average age of 65 years. All patients except one had immunosuppressive conditions. Only one patient had documented fever. Seven of 10 patients with *M. haemophilum* infection presented with skin lesions on the extremities including the joints. Three patients had head/neck soft tissue infections, including facial lesions or lymphadenopathy of

the neck. One patient had disseminated *M. haemophilum* infection with cutaneous and soft tissue lesions over the face and both upper and lower extremities, along with growth of *M. haemophilum* from the blood.

### 4.2. Surgical, laboratory, and pathology findings

All but one specimen was noted to have granulomatous inflammation, and four of the 9 specimens with granulomatous inflammation were identified as having necrotizing granulomatous inflammation (Table 1). In the four patients requiring surgical intervention, all had local inflammation with invasion into local structures. The average estimated sedimentation rate (ESR) was 31 (seven patients had ESR performed), and the average C-reactive protein was 10.5 (six patients had a CRP performed) (Table 2). Eight of the 10 patients had a serum QuantiFERON-TB assay checked for *M. tuberculosis* infection and none were positive. Tuberculin skin testing (TST) was not performed on any patient; however, reactive TSTs can develop in patients with *M. haemophilum* infection (as with some other NTMs) in patients without evidence of *M. tuberculosis* infection [17].

All ten patients with *M. haemophilum* infection were HIV seronegative. The average peripheral blood WBC was  $7.39 \times 10^9/L$ ,



**Table 2**  
Patient laboratory studies.

Case	ESR	CRP	WBC	Neutrophils ( $\times 10^9$ cells/L)	Lymphocytes ( $\times 10^9$ cells/L)
1	2.0	3	9.9	9.09	0.31
2	NA	NA	18.4	3.00	6.85
3	NA	NA	2.8	1.95	0.32
4	82	13.8	9.1	8.37	0.32
5	16	5.4	3.6	1.70	1.31
6	3	6	8.6	7.26	0.77
7	19	27.1	7.8	5.46	1.83
8	50	ND	2.4	1.71	0.43
9	46	7.9	9.6	4.75	2.51
10	NA	NA	2.6	1.66	0.84

ESR = estimated sedimentation rate.

CRP = C-reactive protein.

NA = not available or not performed.

for which there was not a pattern of subclass predominance of neutrophils or lymphocytes.

#### 4.3. In vitro antimicrobial drug susceptibility testing (DST)

*M. haemophilum* isolates from eight patients were available for DST. The minimum inhibitory concentration (MIC) breakpoints for *M. haemophilum* for select antimicrobials as outlined by the Clinical Laboratory Standards Institute (CLSI) changed over the study period; therefore, interpreting in vitro values of 'susceptible' vs. 'resistant' drugs depends upon when the isolated was tested. Of the ten *M. haemophilum* isolates, 8 had antimicrobial DST performed (Table 3). There was noted variability to the ciprofloxacin susceptibility. Five isolates had a ciprofloxacin MIC of  $<2$ , and were identified as susceptible. Three other isolates had a ciprofloxacin MIC of 2 and, depending upon the year it was processed, was identified as 'susceptible' (case #6), 'resistant' (case #5) and 'intermediate' (case #4).

Eight *M. haemophilum* isolates were tested against clarithromycin, and all were susceptible. Five of 8 isolates tested against linezolid had an MIC  $<6$  (interpreted as 'susceptible'). Among the other three isolates, 2 had MIC values of 6 with different CLSI established breakpoints.

Four of 8 *M. haemophilum* isolates tested against rifampin had MICs  $<1$  (interpreted as 'susceptible'). With MIC values  $>1.0$ , the CLSI clinical breakpoint data again changed over time. Six of the 8 isolates were susceptible to trimethoprim/sulfamethoxazole. Isolates tested against minocycline, doxycycline and amikacin appeared to have mixed results with variable clinical interpretations.

All ten patients improved with treatment—medical and/or surgical. Among the nine patients who received antimicrobial therapy for *M. haemophilum* infection, 7 received a newer macrolide, 6 received a rifamycin, 4 received moxifloxacin, 4 received doxycycline, and 1 received minocycline. Antimicrobial treatment duration varied widely from 2 weeks of therapy (Case #2 with surgical resection) to 18 months (Case #8 with disseminated disease). The combination of a newer macrolide, rifamycin and fluoroquinolone was the most common combination regimen used.

Seven patients who received antimicrobial therapy completed therapy with documented complete resolution of infection. One patient demonstrated clinical improvement after 2 months' treatment and completed his care elsewhere (could not assess end of treatment result). One patient had shown clinical improvement after 9 months' of therapy but died of unrelated causes before treatment was completed. One patient did not receive antimicrobial therapy and was cured with surgical lymph node resection. As most infections in our patients occurred among those with immunosuppressive conditions, the reduction of immunosuppressant therapies may be helpful when feasible [1–3]. This, however, was

not always possible in our cases, and dependent upon the stability of the patients' underlying comorbidities.

While receiving antimicrobial therapy, three patients experienced initial worsening or recurring skin and soft tissue inflammatory lesions. With repeated tissue biopsies, mycobacterial cultures were negative in all cases, and the lesions eventually resolved or notably improved with completion of therapy.

## 5. Discussion

Patients identified with *M. haemophilum* infection predominantly had immunosuppressive conditions. Cutaneous disease, predominantly multifocal, was the most common form of *M. haemophilum* infection. Nodular lesions involving the peripheral extremities were among the most common presentation. A pattern of disease progression was identified: nodular cutaneous lesions that become accompanied by a cellulitis-appearing configuration and eventually progress into painful, deep tissue lesions. Lymphatic, bone and joint and disseminated disease were occasionally encountered and most likely reflects the immunologic conditions of affected patients. Some of the patients evaluated had cutaneous disease with contiguous involvement of adjacent tissues including bone, joint or adjacent lymph nodes.

When surgery was performed, purulence or tissue necrosis was most commonly encountered along with extensive inflammation. Non-necrotizing and necrotizing granulomatous inflammation was identified within the tissue histology in about half of the cases.

*M. haemophilum* associated cervicofacial infection has been previously described [1,3,4,10,18,19] and was encountered in two patients (Cases #7 and 9). Case #7 was a healthy immunocompetent patient with cervical lymphatic infection that was cured with surgical excision alone—a treatment that has been successful for immunocompetent pediatric patients [1,4,18]. The other case only had partial surgical resection of lymphatic disease and therefore necessitated a prolonged course of antimicrobials. Both of these patients responded well. *M. haemophilum* cervicofacial infection is seen more commonly in the pediatric population [1,3,18]; however, we did not identify any pediatric patients with *M. haemophilum* at our center during this time period. While *M. haemophilum* cutaneous disease may be more commonly encountered in adult patients and cervicofacial adenitis may be more typical in children [18], we observed both forms of disease in our adult patients, a finding that may reflect the individual's immunologic status.

Of note, we did have one patient with rheumatoid arthritis with significant immunosuppression who developed *M. haemophilum* blood stream infection. While not a common occurrence, *M. haemophilum* blood stream infections have been described in with immunologically advanced HIV infected patients and also in those with significant non-HIV immunosuppressive conditions [20–21].

*M. haemophilum* is a slow growing NTM, and the time required for detectable growth in culture ranged from 23 to over 80 days, with most isolates requiring over 30 days incubation. In vitro *M. haemophilum* DST results needs to be interpreted with caution in setting of changing methodologies and difficulties correlating in vitro MIC values with clinical responses [20]. The *M. haemophilum* isolates tested at our center were found uniformly susceptible to clarithromycin and most isolates susceptible to ciprofloxacin, linezolid and trimethoprim/sulfamethoxazole. Higher rates of drug resistance were encountered with amikacin, rifampin, doxycycline and minocycline.

No standard guidelines are available for the treatment of *M. haemophilum* infection [19]; however, combination antimicrobial therapy is recommended. Clarithromycin, ciprofloxacin and a ri-

**Table 3**

Organism culture characteristics, MIC breakpoints and corresponding antimicrobial drug susceptibilities.

Case	AFB tissue stain positive	Time to culture positivity (days)	Ciprofloxacin	Clarithromycin	Linezolid	Amikacin	Rifampin	Sulfamethoxazole	Moxifloxacin	Doxycycline	Minocycline
1	Yes	33	S < 2	S < 15	S < 6	R > 6	R > 1	R > 0.5/9.5	NA	NA	NA
2	Yes	58	NA	NA	NA	NA	NA	NA	NA	NA	NA
3	Yes	33	S < 1	S < 3	S < 8	R > 6	S < 1	S < 0.25/4.75	S < 1	NA	NA
4	No	35	I (2)	S < 4	S < 4	R > 8	I 2.0	R > 8.0	NA	R 16	S < 4
5	Yes	30	R (2)	S 15	R 6	R 12	R 1	S 0.5/9.5	NA	R 6	R 6
6	Yes	23	S (2)	S 15	S 6	R 12	R 1	S 0.5/9.5	NA	S 6	R 6
7	No	33	NA	NA	NA	NA	NA	NA	NA	NA	NA
8	Yes	60	S < 2	S < 15	S < 6	S < 12	S < 1	S < 0.5/9.5	NA	NA	S < 6
9	Yes	34	S < 2	S < 15	S < 6	S < 12	S < 1	S < 0.9/9.5	NA	S < 6	S < 6
10	No	29	S < 2	S < 15	S < 6	S < 12	S < 1	S < 0.5	NA	S < 6	S < 6

S = susceptible.

R = resistant.

NA = not available or not performed.

famycin have been successfully used and a prolonged duration may be needed for more severe and disseminated forms of disease [1–3,20–21]. Among the patients treated at Mayo Clinic, Rochester, the duration of therapy was variable, ranging from 2 weeks to 18 months depending upon the infection syndrome and underlying host immunology, with 12 months of therapy the most common duration. One patient has been treated with chronic suppressive antimicrobials, and one patient was treated with excision alone. Based on these observations, and often in the setting of immunomodulatory patient co-morbidities, prolonged durations of therapy have been commonly used for disease resolution. The specific duration of antimicrobial therapy for *M. haemophilum* infection, however, can be quite variable and typically dependent upon numerous factors including the severity of disease, anatomic location and immunologic status of the host. Our case series included one immunocompromised patient with a rare, life-threatening disseminated infection for whom chronic, suppressive therapy was chosen. Disease remission has been maintained in this individual with a suppressive regimen of doxycycline and azithromycin. Shorter courses of treatment may be appropriate for select immunocompetent patients with localized soft tissue disease, especially if surgically resection is feasible. Our observations would further suggest that *M. haemophilum* infections isolated to one or few localized lymph nodes, and without involvement of adjacent soft tissues, may be successfully treated with surgical excision alone.

Although the response to therapy was favorable for all patients, three patients had findings of initial worsening of lesions or emergence of new sterile lesions while receiving therapy. Tissue cultures of biopsied lesions were negative and there was eventual clinical improvement. Immunologic reconstitution inflammatory syndrome (IRIS) was considered a strong possibility in such cases. In addition to our case series, a number of *M. haemophilum* case reports have implicated possible IRIS [3,11] A few of our cases had mild degrees of ongoing inflammation present even after the conclusion of antimicrobial therapy. In some cases, immunosuppressive drug reduction may contribute toward initial or recurrent inflammatory lesions, but not all cases in our series had such clear immunosuppressive drug dosing correlation.

Questions have been raised whether *M. haemophilum* may pose a higher risk of post-treatment reactions, or IRIS reactions, compared to other NTM species. [11]. Whether post-treatment reactions or IRIS reactions are more common in *M. haemophilum* infections compared to other NTM is not clear, and corresponding changes in immunosuppressive therapies must be taken into consideration. We found the onset of IRIS during *H. haemophilum* therapy not uncommon. More study regarding the comparative frequency of IRIS with *M. haemophilum* to that of other NTMs is warranted.

## 6. Conclusion

Our institutional case series of *M. haemophilum* infections supports previous observations that *M. haemophilum* disease is predominantly found in immunosuppressed patients, and occasionally in immunocompetent patients. Given the fastidious growth requirements, extended incubation may be required for organism isolation in culture. Patients responded well to antimicrobial therapy, and the most commonly used 2–3 drug program included a newer macrolide, a rifamycin, a fluoroquinolone, and/or doxycycline. Although formal guidelines for the treatment of infection are insufficient as comparative treatment trials for *M. haemophilum* are lacking, our experience suggests that the combination of a newer macrolide, rifamycin and a fluoroquinolone is effective. Localized adenitis in an immunocompetent patient may be treated with surgery alone if excision is complete.

A novel observation made in our case series is the presence of possible IRIS-like reactions while on effective therapy with both cutaneous and cervicofacial forms of *M. haemophilum* disease. The nature of these post-treatment inflammatory reactions is poorly understood. Further study is warranted.

## Funding

This research did not receive any specific grant from funding agencies in the public, commercial or not-for-profit sectors.

## Conflict of interest

All authors, no conflicts.

## References

- [1] Lindeboom JA, Bruijnesteijn van Coppenraet LE, van Soolingen D, Prins JM, Kuijper EJ. Clinical manifestations, diagnosis, and treatment of *Mycobacterium haemophilum* infections. *Clin Microbiol Rev* 2011;24(4):701–17.
- [2] Lott JP, Werth VP, Kovarik CL. Cutaneous *Mycobacterium haemophilum* infection in iatrogenically immunocompromised patients without transplantation. *J Am Acad Dermatol* 2008;59(1):139–42.
- [3] Shah MK, Sebti A, Kiehn TE, Massarella SA, Sepkowitz KA. *Mycobacterium haemophilum* in immunocompromised patients. *Clin Infect Dis* 2001;33(3):330–7.
- [4] Saubolle MA, Kiehn TE, White MH, Rudinsky MF, Armstrong D. *Mycobacterium haemophilum*: microbiology and expanding clinical and geographic spectra of disease in humans. *Clin Microbiol Rev* 1996;9(4):435–47.
- [5] Tufariello JM, Kerantzas CA, Vilch ze C, Calder RB, Nordberg EK, Fischer JA, et al. The complete genome sequence of the emerging pathogen *Mycobacterium haemophilum* explains its unique culture requirements. *MBio* 2015;6(6):e01313–15.
- [6] Castro-Silva AN, Freire AO, Grinbaum RS, Elmor de Ara jo MR, Abensur H, Ara jo MR, et al. Cutaneous *Mycobacterium haemophilum* infection in a kidney transplant recipient after acupuncture treatment. *Transpl Infect Dis* 2011;13(1):33–7.

- [7] Cross GB, Le Q, Webb B, Jenkin GA, Korman TM, Francis M, et al. *Mycobacterium haemophilum* bone and joint infection in HIV/AIDS: case report and literature review. *Int J STD AIDS* 2015.
- [8] Ducharlet K, Murphy C, Tan SJ, Dwyer KM, Goodman D, Aboltins C, et al. Recurrent *Mycobacterium haemophilum* in a renal transplant recipient. *Nephrology (Carlton)* 2014;19 Suppl 1:14–17.
- [9] Touma Z, Haddad A, Gladman DD, Uleryk EM, Urowitz MB. Skin nontuberculous mycobacterial infection in systemic lupus erythematosus: an unusual skin infection mimicking lupus vasculitis. *Semin Arthritis Rheum* 2013;42(5):498–506.
- [10] Lindeboom JA, Prins JM, Bruijnesteijn van Coppenraet ES, Lindeboom R, Kuijper EJ. Cervicofacial lymphadenitis in children caused by *Mycobacterium haemophilum*. *Clin Infect Dis* 2005;41(11):1569–75.
- [11] Geisler WM, Harrington RD, Wallis CK, Harnisch JP, Liles WC. Broad spectrum of dermatologic manifestations caused by *Mycobacterium haemophilum* infection. *Arch Dermatol* 2002;138(2):229–30.
- [12] Smith S, Taylor GD, Fanning EA. Chronic cutaneous *Mycobacterium haemophilum* infection acquired from coral injury. *Clin Infect Dis* 2003;37(7):e100–1.
- [13] Dobos KM, Quinn FD, Ashford DA, Horsburgh CR, King CH. Emergence of a unique group of necrotizing mycobacterial diseases. *Emerg Infect Dis* 1999;5(3):367–78.
- [14] Giulieri S, Morisod B, Edney T, Odman M, Genné D, Malinverni R, et al. Outbreak of *Mycobacterium haemophilum* infections after permanent makeup of the eyebrows. *Clin Infect Dis* 2011;52(4):488–91.
- [15] Hamsch C, Hartschuh W, Enk A, Flux K. A Chinese tattoo paint as a vector of atypical mycobacteria-outbreak in 7 patients in Germany. *Acta Derm Venereol* 2011;91(1):63–4.
- [16] Kay MK, Perti TR, Duchin JS. Tattoo-associated *Mycobacterium haemophilum* skin infection in immunocompetent adult, 2009. *Emerg Infect Dis* 2011;17(9):1734–6.
- [17] Haimi-Cohen Y, Zeharia A, Mimouni M, Soukhman M, Amir J. Skin induration in response to tuberculin testing in patients with nontuberculous mycobacterial lymphadenitis. *Clin Infect Dis* 2001;33(10):1786–8.
- [18] Lindeboom JA. Surgical treatment for nontuberculous mycobacterial (NTM) cervicofacial lymphadenitis in children. *J Oral Maxillofac Surg* 2012;70(2):345–8.
- [19] Cohen YH, Amir J, Ashkenazi S, Eidlitz-Markus T, Samra Z, Kaufmann L, et al. *Mycobacterium haemophilum* and lymphadenitis in immunocompetent children, Israel. *Emerg Infect Dis* 2008;14(9):1437–9.
- [20] Kelley CF, Armstrong WS, Eaton ME. Disseminated *Mycobacterium haemophilum* infection. *Lancet Infect Dis* 2011;11(7):571–8.
- [21] Stürenburg E, Horstkotte MA, Aberle J, Meyer K, Richter E, Laufs R, et al. Disseminated *Mycobacterium haemophilum* infection as initial manifestation of AIDS. *Tuberculosis (Edinb)* 2004;84(6):341–5.