

Review Article

Periodontal Regeneration with Enamel Matrix Derivative in the Management of Generalized Aggressive Periodontitis: A Case Report with 11-Year Follow-up and Literature Review

Dimitra Trikka, Spyridon Vassilopoulos

Department of
Periodontology, School
of Dentistry, National and
Kapodistrian University of
Athens, Greece

ABSTRACT

Objectives: Aggressive periodontitis (AgP) represents an uncommon but rapidly advanced inflammatory process, which involves the destruction of periodontal tissues. This study aimed to report a case of generalized AgP (GAgP), where the treatment approach consists of the utilization of the full-mouth disinfection protocol (FMDP) in conjunction with flap curettage and regenerative appliance of enamel matrix derivatives (EMDs). The associated literature was also reviewed.

Materials and Methods: A 19-year-old female patient was diagnosed with GAgP. The treatment was initiated with FMDP and administration of antibiotics. Afterward, open flap debridement was performed, and EMD was selected as the regenerative material for the reconstruction of the periodontal defects. Over an 11-year period and during all the phases of the treatment, the outcomes were regularly evaluated with clinical measurements and radiographic controls.

Results: The 11-year results demonstrated no recurrence of disease, and the patient's periodontal health exhibited evident improvement. Overall, the pocket depths presented satisfactory reduction while the clinical attachment loss (CAL) was improved. Both our limited experience and available literature data revealed that the use of EMD in AgP treatment contributes to bone fill of the intrabony defects as well as regeneration of the destructed periodontal apparatus.

Conclusions: Although the outcomes of this treatment approach have not been widely evaluated, it seems that the use of EMD may be an effective means of periodontal regeneration in patients with GAgP. Additional prospective studies with adequate number of GAgP patients are essential to thoroughly assess the effectiveness of this approach.

KEYWORDS: Aggressive periodontitis, enamel matrix derivative, periodontal regeneration, treatment of periodontitis

Received : 18-03-18.

Accepted : 20-11-18.

Published : 14-02-19.

INTRODUCTION

Aggressive periodontitis (AgP) is a quite rare but severe inflammatory process which involves the destruction of periodontal tissues with rapid fashion; it is also characterized by early-onset and familial aggregation.^[1] From a historical aspect, this specific type of periodontal disease is known since 1923 when Gottlieb described it as “diffuse atrophy of the alveolar bone.”^[2] The term “AgP” replaced the already used one of “early-onset periodontitis”^[3] in the

last Classification Workshop of the American Academy of Periodontology (1999).^[4]

There are specific clinical and laboratory features which discriminate AgP into localized and generalized form. Generalized AgP (GAgP) commonly appears under

Address for correspondence: Dr. Dimitra Trikka,
6 Str Kapodistriou, Argos, Argolida, 21200, Greece.
E-mail: mirka.trikka@gmail.com

This is an open access journal, and articles are distributed under the terms of the Creative Commons Attribution-NonCommercial-ShareAlike 4.0 License, which allows others to remix, tweak, and build upon the work non-commercially, as long as appropriate credit is given and the new creations are licensed under the identical terms.

For reprints contact: reprints@medknow.com

How to cite this article: Trikka D, Vassilopoulos S. Periodontal regeneration with enamel matrix derivative in the management of generalized aggressive periodontitis: A case report with 11-year follow-up and literature review. J Int Soc Prevent Communit Dent 2019;9:13-20.

Access this article online	
Quick Response Code: 	Website: www.jispcd.org
	DOI: 10.4103/jispcd.JISPCD_119_18

the age of 30 years; however, older patients may also be affected. Patients with GAgP present at least three permanent teeth (other than first molars and incisors) with generalized interproximal attachment loss. The whole inflammatory process is distinguished by exacerbation episodes interrupted by quiescence periods lasting for variable length of time (weeks to months or years). Moreover, the immunologic response to the infecting agents, in terms of antibody production, is weak.^[4-6] However, in 2018, the AAP and the European Federation of Periodontology established a new classification for periodontal disease according to the current knowledge of pathophysiology. Thus, three forms of periodontitis can be identified: necrotizing periodontitis, periodontitis as a manifestation of systemic disease, and periodontitis. The last one type contains the previously known disease as chronic or AgP, which now grouped under the single category of periodontitis. In this article, the previous classification method of American Academy of Periodontology (1999) was used for comprehension reasons.^[7,8]

The treatment of the AgP, which is a mainstream use of full-mouth disinfection protocol (FMDP) combined with systematic antibiotic administration, although has led to improved clinical outcomes, should not be limited to the arrest of the disease progression, but also to include the regeneration of the destructed periodontal tissues.^[9,10] The application of enamel matrix derivatives (EMDs) has been proved effective in enhancement of osteoblast and periodontal ligament cell proliferation as well as in acceleration of new bone formation.^[11-13] Kaner *et al.*^[14] reported satisfactory clinical radiographic and microbiologic outcomes when minimally invasive access flaps were combined with the use of EMD in a case of localized AgP.

This article aimed to report a case of GAgP where the treatment plan included the utilization of the FMDP followed by open flap surgery in combination with EMD application. Furthermore, the English literature in PubMed was searched and reviewed regarding periodontal regeneration with EMD only for the patients diagnosed with AgP.

MATERIALS AND METHODS

In 1999, a 19-year-old female patient who presented in a private dental practice complained about the increased mobility of her teeth during the past months together with the progressive widening of interdental diastema in both upper and lower front teeth [Figure 1a-e]. She was systematic disease-free, and her medical history did not include medications, allergies, and alcohol or cigarette use. The patient stated that she received

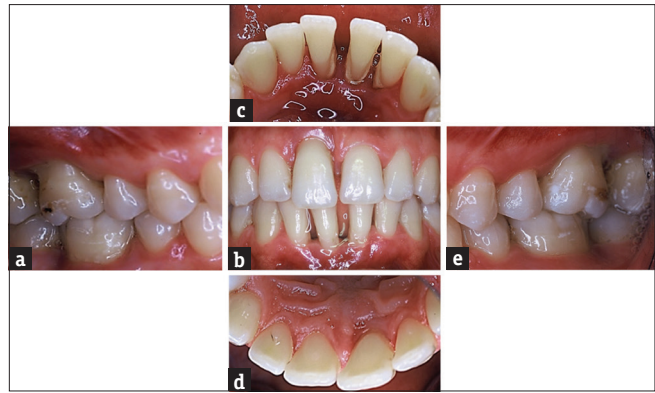

Figure 1: (a-e) Initial intraoral views

supragingival scaling every 6 months from her general dentist. Furthermore, the patient cited that her father had suffered from multiple teeth losses and severe periodontal problems despite his age (51 years old). Patient consent was obtained for the publication.

The initial periodontal examination demonstrated bleeding on probing (BOP) >50%, plaque index 30%, and periodontal attachment loss (PAL) and pocket depth (PD) exceeding 6 mm in more than three teeth other from central incisors and first molars. The initial clinical measurements are presented in Table 1. They were carried out by the same clinician at six sites per tooth (mesiofacial, facial, distofacial, mesiolingual, lingual, and distolingual). The long-cone paralleling technique was used for the periapical radiographic examination, while a panoramic radiograph was also screened. The collected data support the diagnosis of GAgP.

Immobilization of all maxillary and mandibular teeth was utilized to improve patient comfort and function before the initiation of periodontal treatment. The conservative treatment was performed according to the FMDP proposed by Quirynen *et al.*^[15] All teeth were subjected to scaling and root planing both with manual instruments (Gracey curettes, Hu-Friedy®, Chicago, EUA) and piezomagnetic ultrasonic scaler within 48 h under local anesthesia. Amoxicillin (500 mg/qid) in combination with metronidazole (500 mg/tid) was prescribed per os for 7 days. The patient was instructed for proper oral hygiene by brushing her teeth according to the modified Bass technique and rinsing a chlorhexidine solution (0.12% twice a day for 2 weeks).

The first reevaluation was carried out 8 weeks later. Despite the improvement of some clinical indexes, the periodontal examination also revealed residual intrabony defects deeper than 6 mm localized in the following teeth: 11, 15–16, 25–26, 35–36, 31–42, and 45–46, which implied surgical access leading to six surgical interventions as well as periodontal regeneration

Table 1: Initial periodontal chart

	18	17	16	15	14	13	12	11	21	22	23	24	25	26	27	28	
Mobility	0	0	1	0	0	0	0	2	0	0	0	0	0	1	0	0	
Implant																	
Furcation		●	●											●			
Bleeding on Probing	+	+	+	+	+	+	+	+	+	+	+	+	+	+	+	+	
Plaque	+	+	+	+	+	+	+	+	+	+	+	+	+	+	+	+	
Gingival Margin	-1	0	-1	-2	-3	-4	-1	-1	0	0	0	0	0	0	-1	-1	
Probing Depth	5	5	7	7	8	7	6	9	5	7	5	7	6	4	5	3	3
Mean Probing Depth = 5.7 mm Mean Attachment Level = -6.6 mm 30% Plaque 52% Bleeding on Probing																	
Note																	
Furcation																	
Bleeding on Probing	+	+	+	+	+	+	+	+	+	+	+	+	+	+	+	+	
Plaque	+	+	+	+	+	+	+	+	+	+	+	+	+	+	+	+	
Gingival Margin	-1	-1	-1	-1	-1	-1	-1	-1	0	0	0	0	0	0	-1	-1	
Probing Depth	4	4	7	8	8	6	9	5	7	5	7	6	4	5	3	3	
Mean Probing Depth = 5.7 mm Mean Attachment Level = -6.6 mm 30% Plaque 52% Bleeding on Probing																	
Mobility	0	0	1	0	0	0	0	2	2	1	0	0	0	1	0	0	
Implant																	
Furcation																	
Bleeding on Probing	+	+	+	+	+	+	+	+	+	+	+	+	+	+	+	+	
Plaque	+	+	+	+	+	+	+	+	+	+	+	+	+	+	+	+	
Gingival Margin	-1	-1	-1	-1	-1	-1	-1	-1	0	0	0	0	0	0	-1	-1	
Probing Depth	4	4	7	8	8	6	9	5	7	5	7	6	4	5	3	3	

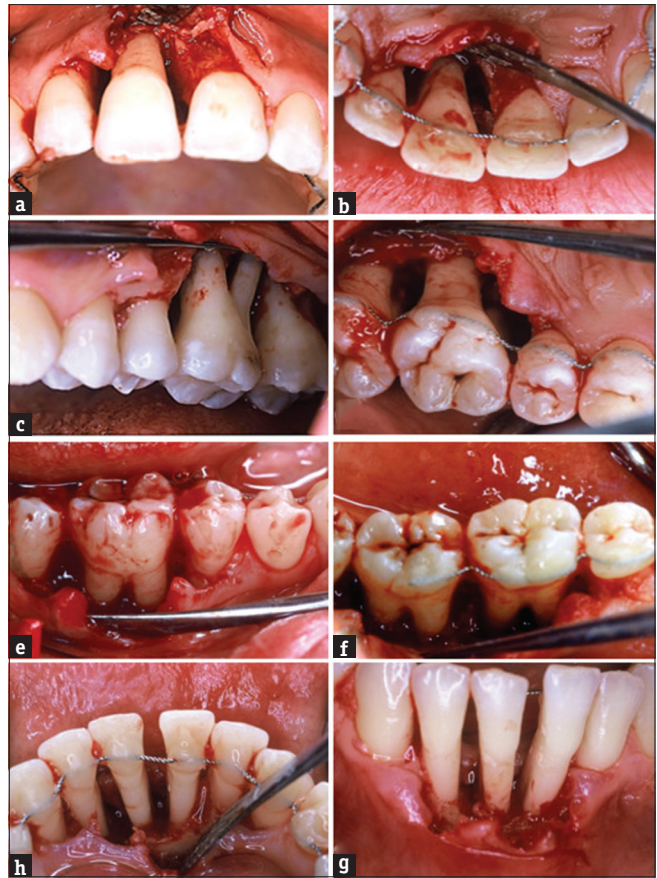


Figure 2: (a-g) Open flap surgery with the application of enamel matrix derivatives

DISCUSSION

Eleven years later, no recurrence of periodontal diseases was noted [Figure 3a-c]. The improvement of periodontal health was indicated by a reduction of PD and gain of clinical attachment loss (CAL) [Table 2] when compared to the baseline measurements [Table 1]. Particularly, the mean PD was 5.62 ± 2.91 mm at the baseline, whereas the mean PD 11 years later was 3.57 ± 0.95 mm. Similarly, the mean CAL was estimated to be 6.63 ± 4.01 mm at the baseline, but after 11 years, it was reduced to 5.53 ± 3.03 mm. The periapical radiographic examination exhibited stability and possible regeneration of the affected intrabony defects on single and multirooted teeth [Figure 4a-l].

In general, the pattern and the aims of AgP treatment are not considerably different from those of chronic periodontitis. However, both the severity and the rapid process of bone loss affecting the young patients with AgP commonly require conformity with a more aggressive treatment approach.^[4]

The current data have drawn up the conclusion that there is no superior benefit of FMDP over the conventional scaling and root planing in the treatment

procedures with the use of EMD (Emdogain®, Biora AB, Malmo, Sweden) [Figure 2a-i]. Specifically, the sulcular incisions by 15c scalpel and fine elevator were utilized to raise mucoperiosteal flaps in various sites. Then, meticulous degranulation of intrabony defects and scaling of the root surfaces were applied. The surgical field was rinsed with saline, and afterward, the exposed roots were carefully dried with cotton swabs to secure the application of 24% ethylenediaminetetraacetic acid (PrefGel®, Institut Straumann) for 2 min. The root surfaces were rinsed again with saline allowing EMD placement. The flap was tightly closed with Laurell–Gottlow suturing technique (5.0 silk). The sutures were removed 10 days postoperatively.

Oral hygiene measures were restricted to local rinses with chlorhexidine 0.2% twice a day for 6 weeks. After suture removal, tooth brushing was implemented using a soft brush, and the 3rd postoperative week, interdental cleaning was recommended. The first postoperative evaluation underwent at 6 months, which was followed by a strict maintenance protocol.

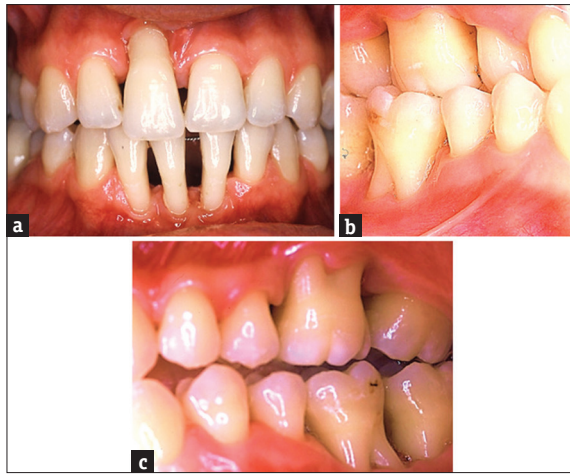

Figure 3: (a-c) Eleven-year follow-up: Absence of periodontal inflammation, minor plaque deposes, and pronounce recession

of chronic periodontitis.^[16] Yet, FMDP has been incorporated that in the treatment of AgP is an effective approach. In fact, several authors documented clinical improvement in PD, PAL, and BOP.^[17,18] Mongardini *et al.* compared the effectiveness between FMDP and conventional treatment in 16 patients with AgP (referred as early-onset periodontitis) and ascertained small but significant differences in periodontal indexes over an 8-month period.^[19] Furthermore, Quirynen *et al.* provided additional evidence which indicated a significantly greater reduction of spirochetes and motile organisms *Porphyromonas gingivalis* after FMDP in comparison to conventional approaches.^[20] Furthermore, randomized placebo-controlled studies reported that the clinical benefits of FMDP in the context of AgP treatment may be significantly reinforced by the adjunctive use of systemic antibiotic regimen containing amoxicillin and metronidazole.^[21] The meta-analysis of Keestra *et al.* also provided extra evidence about the advantageous role of systematic administration of amoxicillin and metronidazole in nonsurgical treatment of AgP.^[22] Several studies evaluated the clinical effect of different antibiotic protocols.^[23,24] One-year randomized trial on a patient with generalized CP demonstrated that the use of 400 or 250 mg metronidazole in conjunction with 500 mg amoxicillin (tid) for 14 days has statistically significant superior clinical outcomes compared to no antibiotic utilization. Furthermore, it is mentioned that the use of those antibiotic for 7 days has no added benefits.^[25] However, the current systematic review and meta-analysis reveals that there are no clinical benefits between different doses or duration of amoxicillin plus metronidazole at 3 months posttreatment, and it is concluded that 500 mg amoxicillin plus 500 or 400 mg metronidazole for 7 days would be appropriate.^[26]

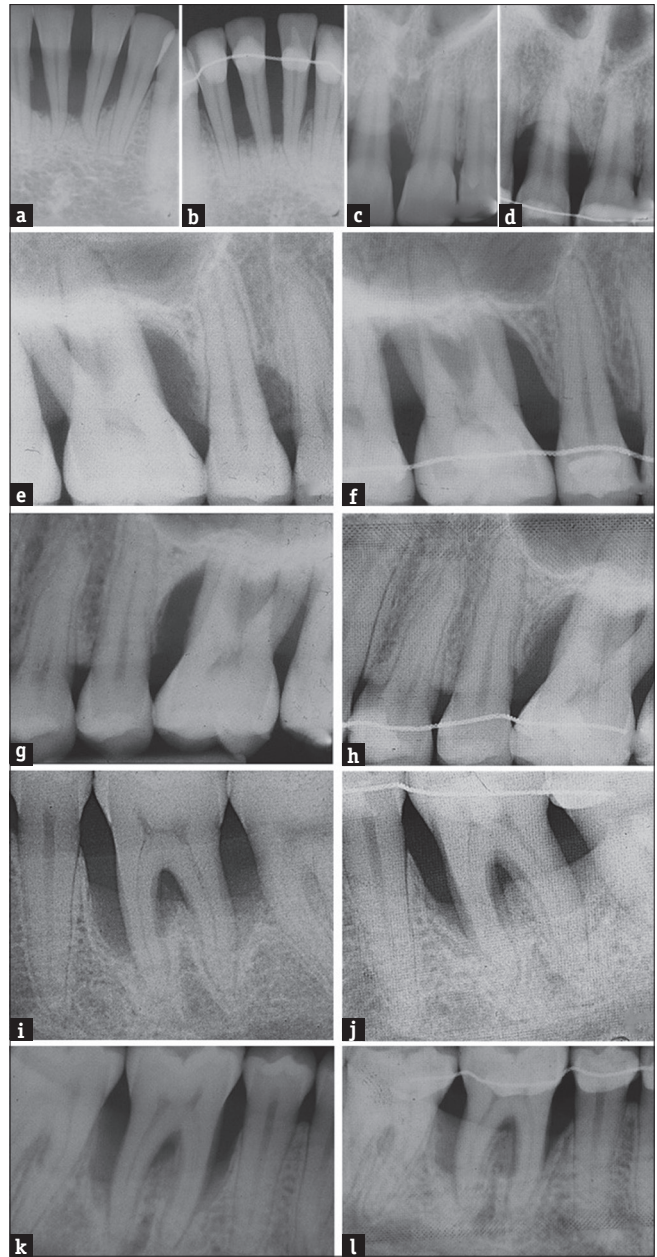
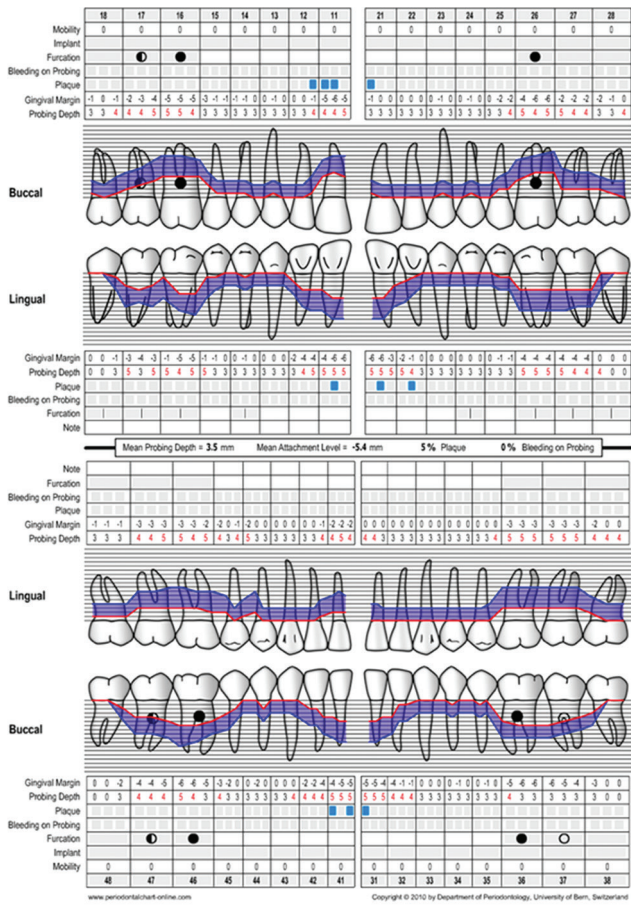


Figure 4: (a-l) Periapical radiographies at the baseline (a, c, e, g, i, and k) and after 11 years. (b, d, f, h, j and l) Evidenced a significant bony fill following the treatment

Although the nonsurgical treatment may be proved adequate for the management and control of AgP, the tenacious existence of pathologic periodontal pockets (>6 mm) leads to the necessity of surgical approaches.^[27] Hence, surgical therapy has shown favorable clinical outcomes in studies containing patients with AgP with advanced residual pockets.^[28] Likewise, the conservative periodontal treatment in our patient failed to reduce optimally the PD in all of the affected teeth, and therefore, access flap surgery was required. Jiao *et al.* performed nonsurgical therapy in 1004 patients with GAgP, with 6-week (203 patients),

Table 2: Final periodontal chart (11-year follow-up)



3-month (310 patients), 6-month (193 patients), 1-year (205 patients), 3-year (70 patients), and >5-year (23 patients) follow-up period. The authors demonstrated the limitation of nonsurgical treatment on teeth with advanced periodontal destruction, especially for molars with furcation involvement and/or angular bone defect.^[29] The surgical procedures involved not only the removal of granulation tissue but also periodontal regeneration with the use of EMD.

The EMD is both well-established and documented methods to promote regeneration of cementum, periodontal ligament, and alveolar bone. The main point of its use entails the creation of a regenerative environment that reproduces the biological conditions occurring in the embryonic development of the periodontal tissues. One significant feature of EMD is the prevention of epithelial downgrowth along the root surface after the surgical procedure. This can be achieved by the formation of a mechanical obstacle such as that of barrier membranes in guided tissue regeneration (GTR) procedures. EMD fosters the proliferation of PDL cells, cementoblasts, and osteoblasts by allowing the reestablishment of normal periodontal architecture.^[11,12,30]

The ease of its use in clinical practice relies on its possible application in multiple contiguous defects, in one operation and within short interventional time.^[31]

Armitage *et al.* advocated that chronic periodontitis and AgP should share the same treatment goals, regardless of their differences in etiologic/contributing factor and aggressiveness.^[4] A systematic review focused on the evaluation of various regenerative techniques which had been used in patients with AgP. This review inducted that the application of EMD in those patients offered comparable clinical improvements in comparison to the use of EMD in patients with chronic periodontitis.^[24]

The meta-analysis of Esposito *et al.* isolated for analysis nine studies which evaluated the comparison outcomes between EMD and control or placebo groups at 1 year postoperatively.^[32] Various clinical parameters were examined such as tooth loss, PAL, esthetics, complications, PAL gain <2 mm, PD, gingival recessions (REC), and radiographic bone level. Statistically significant superiority for EMD versus control/placebo groups was found, regarding PAL (mean difference of 1.08 mm, 95% confidence interval [CI]: 0.61–1.55) and PD (mean difference of 0.88 mm, 95% CI: 0.44–1.31). By contrast, there was no significant difference between the compared groups in the assessment of REC and radiographic bone level. Another meta-analysis by Matarasso *et al.*^[33] concluded that the combination of EMD and bone grafting materials has greater clinical profits concerning CAL gain and PD decrease, compared to the isolated use of EMD. In addition, when EMD was applied alone as a regenerative technique, the increase of REC was higher than the one combined with bone substitutes. However, the authors did not provide information of the comparative assessment of the radiographic bone level despite the approach.

A major number of studies have evaluated the regenerative therapy of intrabony defects with EMD in patients with chronic periodontitis. A prospective case series study assesses the long-term stability after surgical treatment of intrabony defect with either EMD or barrier membrane (plus or without filler). Specifically, 35 intrabony defects were treated with EMD, 3 defects with EMD with combination of fillers, 1 patient was treated with bioabsorbable L-lactic-D-lactic-glycolic acid-trimethylene carbonate membrane, and 1 other with titanium-reinforced expanded polytetrafluorethylene membrane. The mean observation period lasted 63.8 months. The authors revealed that 41% of the infrabony defects gained ≥4 mm vertical CAL, while 24% gained <2 mm in 5-year follow-up. They concluded that the vertical CAL of the infrabony defects may had

not been changed, and it was correlated with the number of supportive therapy visits as well.^[13]

Another prospective 2-year study assesses the use of EMD in 42 intrabony defects. The mean value of bone loss at the baseline was 47.5% ± 13.3%, and at the 1st year postoperative, the bone fill was 25.6% ± 12.9%, and at the 2nd year postoperative, it was 36.2 ± 14.6%. Apart from that, the authors yielded that there were statistically significant gains in CAL and reductions in PD during the observation period. This study revealed that there was no significant association between the type of intrabony defects and the gain of CAL, but they attribute that to the small sample size.^[34]

Losada *et al.* conducted a 12-month randomized controlled clinical trial on 42 patients with uncontained infrabony defects, which were treated with the combination of EMD and biphasic calcium phosphate or EMD alone, and the authors demonstrated that there is no significant different on bone fill, CAL, and decrease of PD. A correlation between the angle, the number of the residual bony walls, and the gain of CAL was

revealed. Particularly, they illustrated a probability of 2.57 times higher CAL gain ≥3 mm in intrabony defect with angulation <24.75° than in wider angles and of 0.55 times reduction of CAL gain ≥3 mm in 2-wall defects compared with 1 wall.^[35]

There are limited studies which investigate the effect of EMD on the subgingival microbiome. The current study analyzes the changes in periodontal microbiome in class II buccal furcation defects after treatment with beta-tricalcium-phosphate/hydroxyapatite graft (βTCP/HA), EMD + βTCP/HA, or EMD alone. Thirty-nine lesions were examined and 422 species were revealed, with an average of 119 ± 35 species-level operational taxonomic units. All three groups achieved changing the subgingival microbiome, with reductions of the red-complex species and increases in health compatible species.. However, the EMD groups came out with more long-term reductions in higher number of species, that is, the βTCP/HA group. Specifically, Filifactor alocis was reduced for a short time, but after 6 months, it was increased again in βTCP/HA group. Furthermore, in EMD groups, *Selenomonas* spp., which

Table 3: Review of studies containing AgP patients treated with enamel matrix derivatives

Authors/ year	Type of study	No of patients with AgP	Type of AgP (L or G)	Regenerative technique	Follow-up period (months)	Outcomes of study
Bonta <i>et al.</i> 2003.	Case report	1	L	EMD	6	Mean PD reduction=4.5 mm Mean CAL gain=4.5 mm
Vandana <i>et al.</i> 2004	Controlled Split-mouth clinical trial (surgical debridement alone vs. surgical debridement and EMD)	4	Not defined	EMD	9	AgP group: Mean PD reduction=2.5 mm; Mean CAL gain=5.25 mm Significant difference within group between baseline and 9 months No significant differences between control and test groups
Miliauskaite <i>et al.</i> 2007	Case report	1	L	EMD; EMD + BG	36	EMD: Mean PD from 7.6±2.0 to 2.6±1.5 (P<0.038); mean CAL from 8.3±3.2 to 4.0±3.6 (P<0.39) EMD + BG: Mean PD from 8.1±1.7 to 3.0±0.6 (P<0.001); mean CAL: from 8.6±2.4 to 3.7±0.8 (P<0.001)
Kaner <i>et al.</i> 2009	Case report	1	L	EMD	18	Mean PD reduction=7.25 mm Mean CAL gain=6.25 mm Significant differences
Siqueira Jr <i>et al.</i> 2016	Case report	1	L	EMD	120	Treated sites with PD ≥5mm: mean PD reduction=4.57±1.26 mm; mean CAL gain=2.43±1.87 mm. All sites: mean PD reduction=3.15±1.54 mm; mean CAL gain=1.54±1.85
Artzi <i>et al.</i> 2015	Retrospective study	32	L and G; Numbers not defined	Group 1 (n=16, sites=67): GTR (DBX + CM); Group 2 (n=16, sites=73): EMD	12	Group 1: PD reduction=5.35±1.10 mm; CAL gain=4.87±0.91mm; Group 2: PD reduction=5.15±1.28 mm; CAL gain=5.02±1.2 mm

L=Localized, G=Generalized, CM=Collagen membrane

have been associated with periodontal disease, especially AgP and sites with progressing attachment loss, were greater reduced compared with the β TCP/HA group.^[36]

In case of AgP treatment, EMD may be used in conjunction with deproteinized bone xenograft (DBX) alternatively to GTR. In fact, Artzi *et al.*^[37] did not report significant differences between the combination of EMD and DBX and GTR technique containing DBX with a resorbable membrane over a 1-year period. Both techniques resulted in similar PD reduction (GTR-treated sites 61.1% vs. EMD-treated sites 61.6%) and CAL gain (GTR-treated sites 54.5% vs. EMD-treated sites 59.3%). However, the authors did not mention the analysis of data related to radiographic documentation of hard-tissue regeneration/reestablishment of periodontal ligament.^[37] The regenerative application of EMD may be successfully combined with bioactive glass,^[38] even though the short- and long-term results were proved beneficial secondary to the isolated use of EMD, as in our case report.^[39,40] All the isolated data from the available studies, which involved EMD application in the management of AgP, are summarized in Table 3.

For the AgP patients who receive the appropriate periodontal treatment and follow a strict maintenance protocol reduce their possibility of tooth loss. This finding (mean tooth loss per patient for periodontal disease 0.9 ± 2.0) derived from the retrospective study of Diaz-Faes *et al.* which contained 656 teeth and 3168 clinical sites with mean follow-up of 10.9 ± 2 years.^[41] Over this long-term period, the mean reduction of PD was 1 ± 0.8 mm as well as CAL exhibited the mean increase of 0.6 ± 0.9 mm. Those results are in an agreement with those of another study, which is concluded that the progression of AgP is correlated with the supportive therapy protocol. The researchers examined 2379 teeth and 7.7% of those had been lost before reexamination, which had revealed the annual tooth loss rate of 0.14 teeth/patient/year. Nevertheless, 42.7% of patients had no further tooth loss.^[42] In contrast, other authors did not confirm the aforementioned findings and evidenced that annual tooth loss rates are higher despite the patients' compliance with the supportive periodontal treatment.^[43]

CONCLUSIONS

The long-term results of this case report of GAgP support the effectiveness of FMDP followed by EMD use as a regenerative adjunct. The clinical and radiographic measurements demonstrated improvement over an 11-year period. Since there are a few publications reporting this certain approach in patients with GAgP, randomized control studies are required to adequately

document its possible benefits in comparison to other treatments.

FINANCIAL SUPPORT AND SPONSORSHIP

Nil.

CONFLICTS OF INTEREST

There are no conflicts of interest.

REFERENCES

1. Baer PN. The case for periodontosis as a clinical entity. *J Periodontol* 1971;42:516-20.
2. Gootlie B. Diffuse atrophy of the alveolar bone. Further contributions in knowledge about reduction of alveolar bone and its repair with growth cement. *Z Stomatol* 1923;21:195-262.
3. Lang N, Bartold PM, Cullinan M, Jeffcoat M, Mombelli A, Murakami S, *et al.* Consensus report – Aggressive periodontitis. *Ann Periodontol* 1999;4:53.
4. Armitage GC. Development of a classification system for periodontal diseases and conditions. *Ann Periodontol* 1999;4:1-6.
5. Masumoto R, Kitagaki J, Fujihara C, Matsumoto M, Miyauchi S, Asano Y, *et al.* Identification of genetic risk factors of aggressive periodontitis using genomewide association studies in association with those of chronic periodontitis. *J Periodontol Res* 2018. doi: 10.1111/jre.12620. [Epub ahead of print].
6. Chen HW, Zhou W, Liao Y, Hu SC, Chen TL, Song ZC. Analysis of metabolic profiles of generalized aggressive periodontitis. *J Periodontol Res* 2018;53:894-901.
7. Caton JG, Armitage G, Berglundh T, Chapple ILC, Jepsen S, Kornman KS, *et al.* A new classification scheme for periodontal and peri-implant diseases and conditions – Introduction and key changes from the 1999 classification. *J Periodontol* 2018;89 Suppl 1:S1-S8.
8. Fine DH, Patil AG, Loos BG. Classification and diagnosis of aggressive periodontitis. *J Periodontol* 2018;89 Suppl 1:S103-19.
9. Aimetti M, Romano F, Guzzi N, Carnevale G. Full-mouth disinfection and systemic antimicrobial therapy in generalized aggressive periodontitis: A randomized, placebo-controlled trial. *J Clin Periodontol* 2012;39:284-94.
10. Garcia Canas P, Khouly I, Sanz J, Loomer PM. Effectiveness of systemic antimicrobial therapy in combination with scaling and root planing in the treatment of periodontitis: A systematic review. *J Am Dent Assoc* 2015;146:150-63.
11. Zou R, Wan W, Li J, Du C, Wang Y, Qian T, *et al.* Combining enamel matrix proteins with mechanical stimuli potentiates human periodontal ligament fibroblasts proliferation and periodontium remodeling. *Histol Histopathol* 2018;33:825-33.
12. Wyganowska-Swiatkowska M, Urbaniak P, Lipinski D, Szalata M, Borysiak K, Jakun J, *et al.* Effects of enamel matrix proteins on adherence, proliferation and migration of epithelial cells: A real-time *in vitro* study. *Exp Ther Med* 2017;13:160-8.
13. Nickles K, Dannewitz B, Gallenbach K, Ramich T, Scharf S, Röllke L, *et al.* Long-term stability after regenerative treatment of infrabony defects: A retrospective case series. *J Periodontol* 2017;88:536-42.
14. Kaner D, Bernimoulin JP, Kleber BM, Friedmann A. Minimally invasive flapsurgery and enamel matrix derivative in the treatment of localized aggressiveperiodontitis: Case report. *Int J Periodontics Restorative Dent* 2009;29:89-97.
15. Quirynen M, Mongardini C, de Soete M, Pauwels M, Coucke W, van Eldere J, *et al.* The rôle of chlorhexidine in the one-stage full-mouth disinfectiontreatment of patients with advanced adult periodontitis. Long-term clinical andmicrobiological observations. *J Clin Periodontol* 2000;27:578-89.
16. Santuchi CC, Cortelli JR, Cortelli SC, Cota LO, Fonseca DC, Alencar CO, *et al.* Scaling and root planing per quadrant versus one-stage full-mouth disinfection: Assessment of the impact of

- chronic periodontitis treatment on quality of life – A clinical randomized, controlled trial. *J Periodontol* 2016;87:114-23.
17. Aimetti M, Romano F, Guzzi N, Carnevale G. One-stage full-mouth disinfection as a therapeutic approach for generalized aggressive periodontitis. *J Periodontol* 2011;82:845-53.
 18. Miller KA, Branco-de-Almeida LS, Wolf S, Hovencamp N, Treloar T, Harrison P, *et al.* Long-term clinical response to treatment and maintenance of localized aggressive periodontitis: A cohort study. *J Clin Periodontol* 2017;44:158-68.
 19. Mongardini C, van Steenberghe D, Dekeyser C, Quirynen M. One stage full-versus partial-mouth disinfection in the treatment of chronic adult or generalized early-onset periodontitis. I. Long-term clinical observations. *J Periodontol* 1999;70:632-45.
 20. Quirynen M, Mongardini C, Pauwels M, Bollen CM, Van Eldere J, van Steenberghe D, *et al.* One stage full- versus partial-mouth disinfection in the treatment of chronic adult or generalized early-onset periodontitis. II. Long-term impact on microbial load. *J Periodontol* 1999;70:646-56.
 21. Guerrero A, Griffiths GS, Nibali L, Suvan J, Moles DR, Laurell L, *et al.* Adjunctive benefits of systemic amoxicillin and metronidazole in non-surgical treatment of generalized aggressive periodontitis: A randomized placebo-controlled clinical trial. *J Clin Periodontol* 2005;32:1096-107.
 22. Keestra JA, Grosjean I, Coucke W, Quirynen M, Teughels W. Non-surgical periodontal therapy with systemic antibiotics in patients with untreated aggressive periodontitis: A systematic review and meta-analysis. *J Periodontol Res* 2015;50:689-706.
 23. Feres M, Retamal-Valdes B, Mestnik MJ, de Figueiredo LC, Faveri M, Duarte PM, *et al.* The ideal time of systemic metronidazole and amoxicillin administration in the treatment of severe periodontitis: Study protocol for a randomized controlled trial. *Trials* 2018;19:201.
 24. Eick S, Nydegger J, Bürgin W, Salvi GE, Sculean A, Ramseier C, *et al.* Microbiological analysis and the outcomes of periodontal treatment with or without adjunctive systemic antibiotics – A retrospective study. *Clin Oral Investig* 2018;22:3031-41.
 25. Borges I, Faveri M, Figueiredo LC, Duarte PM, Retamal-Valdes B, Montenegro SC, *et al.* Different antibiotic protocols in the treatment of severe chronic periodontitis: A 1-year randomized trial. *J Clin Periodontol* 2017;44:822-32.
 26. McGowan K, McGowan T, Ivanovski S. Optimal dose and duration of amoxicillin-plus-metronidazole as an adjunct to non-surgical periodontal therapy: A systematic review and meta-analysis of randomized, placebo-controlled trials. *J Clin Periodontol* 2018;45:56-67.
 27. Matuliene G, Pjetursson BE, Salvi GE, Schmidlin K, Brägger U, Zwahlen M, *et al.* Influence of residual pockets on progression of periodontitis and tooth loss: Results after 11 years of maintenance. *J Clin Periodontol* 2008;35:685-95.
 28. Corbella S, Weinstein R, Francetti L, Taschieri S, Del Fabbro M. Periodontal regeneration in aggressive periodontitis patients: A systematic review of the literature. *J Invest Clin Dent.* 2017;8:4.
 29. Jiao J, Zhang L, Meng HX, Shi D, Lu RF, Xu L, *et al.* Clinical performance of non-surgical periodontal therapy in a large Chinese population with generalized aggressive periodontitis. *J Clin Periodontol* 2018;45:1184-97.
 30. Venezia E, Goldstein M, Boyan BD, Schwartz Z. The use of enamel matrix derivative in the treatment of periodontal defects: A literature review and meta-analysis. *Crit Rev Oral Biol Med* 2004;15:382-402.
 31. Vandana KL, Shah K, Prakash S. Clinical and radiographic evaluation of emdogain as a regenerative material in the treatment of interproximal vertical defects in chronic and aggressive periodontitis patients. *Int J Periodontics Restorative Dent* 2004;24:185-91.
 32. Esposito M, Grusovin MG, Papanikolaou N, Coulthard P, Worthington HV. Enamel matrix derivative (Emdogain(R)) for periodontal tissue regeneration in intrabony defects. *Cochrane Database Syst Rev* 2009;7:4.
 33. Matarasso M, Iorio-Siciliano V, Blasi A, Ramaglia L, Salvi GE, Sculean A. Enamel matrix derivative and bone grafts for periodontal regeneration of intrabony defects. A systematic review and meta-analysis. *Clin Oral Investig* 2015;19:1581-93.
 34. Seshima F, Aoki H, Takeuchi T, Suzuki E, Irokawa D, Makino-Oi A, *et al.* Periodontal regenerative therapy with enamel matrix derivative in the treatment of intrabony defects: A prospective 2-year study. *BMC Res Notes* 2017;10:256.
 35. Losada M, González R, Garcia ÀP, Santos A, Nart J. Treatment of non-contained intrabony defects with enamel matrix derivative alone or in combination with biphasic calcium phosphate bone graft: A 12-month randomized controlled clinical trial. *J Periodontol* 2017;88:426-35.
 36. Queiroz LA, Casarin RC, Dabdoub SM, Tatakis DN, Sallum EA, Kumar PS, *et al.* Furcation therapy with enamel matrix derivative: Effects on the subgingival microbiome. *J Periodontol* 2017;88:617-25.
 37. Artzi Z, Tal H, Platner O, Wassersprung N, Weinberg E, Slutzkey S, *et al.* Deproteinized bovine bone in association with guided tissue regeneration or enamel matrix derivatives procedures in aggressive periodontitis patients: A 1-year retrospective study. *J Clin Periodontol* 2015;42:547-56.
 38. Miliuskaite A, Selimovic D, Hannig M. Successful management of aggressive periodontitis by regenerative therapy: A 3-year follow-up case report. *J Periodontol* 2007;78:2043-50.
 39. Siqueira SJ, Ribeiro FV, Villalpando KT, Cirano FR, Pimentel SP. Maintenance periodontal therapy after systemic antibiotic and regenerative therapy of generalized aggressive periodontitis. A case report with 10-year follow-up. *Dent Update* 2015;42:385-6, 389-90, 392-3.
 40. Bonta H, Llambes F, Moretti AJ, Mathur H, Bouwsma OJ. The use of enamel matrix protein in the treatment of localized aggressive periodontitis: A case report. *Quintessence Int* 2003;34:247-52.
 41. Díaz-Faes L, Guerrero A, Magán-Fernández A, Bravo M, Mesa F. Tooth loss and alveolar bone crest loss during supportive periodontal therapy in patients with generalized aggressive periodontitis: Retrospective study with follow-up of 8 to 15 years. *J Clin Periodontol* 2016;43:1109-15.
 42. Goh V, Nihalani D, Yeung KW, Corbet EF, Leung WK. Moderate- to long-term therapeutic outcomes of treated aggressive periodontitis patients without regular supportive care. *J Periodontol Res* 2018;53:324-33.
 43. Dopico J, Nibali L, Donos N. Disease progression in aggressive periodontitis patients. A retrospective study. *J Clin Periodontol* 2016;43:531-7.