



King Saud University
Saudi Dental Journal

www.ksu.edu.sa
www.sciencedirect.com



ORIGINAL ARTICLE

Implications of impacted mandibular cuspids on mental foramen position



A.K. Nagarajappa^a, M.K. Alam^{b,*}, A.A. Alanazi^a, V. Bandela^c, S. Faruqi^c

^a Oral Radiology Division, Department of Oral and Maxillofacial Surgery and Diagnostic Sciences, College of Dentistry, Jouf University. 72721 Sakaka, Saudi arabia

^b Orthodontic Division, Department of Preventive Dentistry, College of Dentistry, Jouf University. 72721 Sakaka, Saudi arabia

^c Department of Prosthetic Dental Sciences, College of Dentistry, Jouf University. 72721 Sakaka, Saudi arabia

Received 5 February 2020; revised 1 April 2020; accepted 5 April 2020

Available online 10 April 2020

KEYWORDS

Mental foramen;
Mental nerve;
Panoramic Radiograph;
Impacted Mandibular
Cuspid

Abstract *Objective:* To determine the horizontal and vertical locations and dimensions of the mental foramen (MF) in digital panoramic images (DPI), and to evaluate the effect of impacted mandibular cuspids (IMC) on the position of the MF.

Materials and Methods: 715 Digital panoramic images were obtained from the archives of oral radiology clinics of the College of Dentistry, Jouf University. Altogether 236 DPI that met inclusion and exclusion criteria were investigated. One specialist principal investigator examined and analyzed the DPI on a computer screen for horizontal location, average position, and vertical location of the MF.

Results: The most common horizontal location of MF with the apices of the teeth in the non-impacted group (NIG) was found to be c = 64.70%, and in the impacted group (IG) d = 47.10%. The average magnitude of MF relative to the apex of second bicuspid in the NIG was found to be 47.10% on the mesial side, and in IG 44.10% on the distal side. The average vertical distance of MF from the lower border of the mandible to the lower border of MF (DLM) in NIG was 14.13 mm (SD ± 1.75 mm), and in IG was 16.85 mm (SD ± 3.06 mm). The average vertical distance of MF from the alveolar crest to the superior border of MF (DAC) in NIG was 6.56 mm (SD ± 2.02 mm), and in IG was 6.67 mm (SD ± 2.28 mm).

Conclusion: The impacted mandibular cuspid has a definite influence on the location and position of the MF.

© 2020 The Authors. Production and hosting by Elsevier B.V. on behalf of King Saud University. This is an open access article under the CC BY-NC-ND license (<http://creativecommons.org/licenses/by-nc-nd/4.0/>).

* Corresponding author at: Orthodontic Division, Department of Preventive Dentistry, College of Dentistry, Jouf University. 72721 Sakaka, Saudi arabia

E-mail addresses: dralam@gmail.com, mkalam@ju.edu.sa (M.K. Alam).

Peer review under responsibility of King Saud University.



Production and hosting by Elsevier

1. Introduction

Mental foramen (MF) can be defined as “a funnel like opening on the lateral surface of the mandible at the terminus of the mandibular canal” (Gada and Nagda, 2014). MF transmits bundle of mental nerves and blood vessels, providing sensory innervations and nutrition supply to the skin and mucosa of the lower lip, cheeks, and chin on both sides of the mandible (Gada and Nagda, 2014; Kqiku et al., 2013; Gupta et al., 2015). It is a strategically located eminent landmark at the apical premolar region, which shares its significance in various disciplines of dentistry (Gada and Nagda, 2014; Kqiku et al., 2013; Gupta et al., 2015). Identification of the location of MF is of utmost importance before placement of implants, or any surgical procedure near its vicinity (Gupta et al., 2015; Chkoura and El Wady, 2013; Zaman et al., 2016). Failure to identify the MF results in traumatization of nerves and vessels passing through it, leading to partial or total loss of sensory perception of the supplied area (Kqiku et al., 2013; Chkoura and El Wady, 2013). Therefore, it is of utmost importance for the clinician to identify the location of MF during treatment planning, so that damage to its neurovascular bundle can be prevented (Gada and Nagda, 2014; Kqiku et al., 2013; Gupta et al., 2015; Chkoura and El Wady, 2013; Zaman et al., 2016). Clinical identification and palpation of the MF is very difficult and there is no anatomical landmark available as reference for locating its exact location (Zaman et al., 2016). Frequent repeated failures witnessed during mental nerve blocks indicate variability of the MF location in a given population (Gada and Nagda, 2014; Chkoura and El Wady, 2013; Alma et al., 2015). Moreover, the position of the mental foramen can change with age (Zaman et al., 2016; Al Jasser and Nwoku, 1998). MF appears radiolucent at the apex of the premolar teeth (Gada and Nagda, 2014; Kqiku et al., 2013; Gupta et al., 2015; Chkoura and El Wady, 2013; Zaman et al., 2016). DPI allows broad coverage of the oral structures with bilateral visualization of MF (Gada and Nagda, 2014; Zaman et al., 2016). Several studies have reported on the location, position and size of the MF in DPI in different populations, and found that the location of the MF varied in different race, gender, and ethnic origin (Gada and Nagda, 2014; Kqiku et al., 2013; Gupta et al., 2015; Chkoura and El Wady, 2013; Zaman et al., 2016; Alma et al., 2015). Incidence of impacted mandibular cuspids (IMC) ranges between 0.92% and 5.1%. The exact etiology remains unclear; odontomes, cysts, and lateral incisors' anomalies could be probable causes (Dalessandri et al., 2017). It is observed on the DPI that IMC may also influence the location of the MF. However, no studies were found in the literature to confirm this particular observation. Therefore, this study was designed to study the effect of IMC on the location of the MF. Considering these factors, the study was designed to determine the morphological position of the MF and the effect of IMC on MF location in DPI, in the Saudi population of the Aljof region.

2. Material and Methods

2.1. Study setting

Altogether 715 DPI were examined from the archives of the College of Dentistry, Jof University. Ethical clearance was

obtained from the Local Committee for Bioethics (LCBE no: 9-16-8/39). DPI in the local Saudi population were obtained in the oral clinical radiology section of the College of Dentistry, Jof University, for various dental treatment. All DPI acquired between January 2018 and December 2019, were retrieved, and examined retrospectively. Altogether 236 DPI were selected based on the set inclusion criteria.

2.2. Inclusion and exclusion criteria

The ages of the subjects ranged from 19 to 45 years. Subjects selected for the study had their full complement of mandibular permanent teeth between the right and left mandibular first molars. Mandibular bicuspid were present in the normal position and alignment. Images with good resolution and clear anatomic visibility of MF with at least one IMC tooth were selected for the study. DPI showing severe crowding and spacing in the lower arch, supra erupted lower premolars, weak periodontal status, undergoing orthodontic treatment, presence of radiolucent lesions, or fracture of the parasymphysial region, were excluded from the study.

2.3. Selection of images

Out of 236 DPI, 130 were from male and 106 were from female subjects. DPI were divided into two groups: the impacted group (IG, 118 DPI) and the non-impacted group (NIG, 118 DPI) to determine the effect of IMC on MF location. All DPI were captured by a single experienced radiographer using one digital radiographic machine (Soredex-Cranex-D, Finland) to ensure consistency.

2.4. Radiographic evaluation

Each DPI was examined on a computer screen by the principle investigator, and the horizontal location (Gada and Nagda, 2014; Gupta et al., 2015; Ngeow and Yuzawati, 2003; Al Jasser and Nwoku, 1998), average position (Gupta et al., 2015), and vertical location (Gupta et al., 2015; Afkhami et al., 2013; Phillips et al., 1992) of the MF were recorded. All the aforementioned parameters, along with the effect of IMC on MF, were determined on the DPI using Digora 2.8 software (Finland) tools present in the system, for both groups (NIG and IG).

2.5. Statistical analysis

The collected data were entered in master charts for analyses. Descriptive statistics were calculated using SPSS v.20.5 Chicago, Illinois, USA. The independent *t*-test was used to check for statistical significance among the groups.

3. Results

The most common horizontal location of MF in relation to the apices of the teeth in the NIG was found to be location c, which accounted for 64.70%; followed by d = 26.50%; a, e, f = 2.90%; and b = 0%. The most common horizontal location of MF in relation to the apices of the teeth in the IG was found to be location d, which accounted for 47.10%; followed by c = 38.20%; e = 5.90%; and a, b, f = 2.90% (Fig. 1).

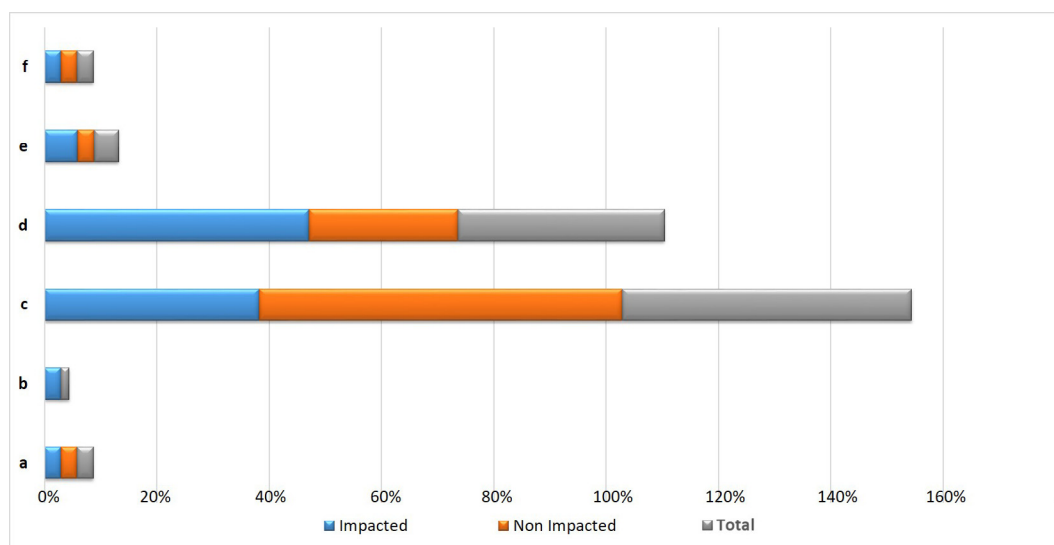


Fig. 1 Horizontal location of MF in IG and NIG. a: Anterior to the first bicuspid b: In line with the first bicuspid c: Between the first and second bicuspids d: In line with the second bicuspid e: Between the second bicuspid and the first molar f: In line with the first molar.

The average proportion of MF relative to the apex of the second bicuspid in NIG was found to be 47.10% on the mesial side, 26.50% was on both distal side and intersecting with the apex. The average proportion of MF relative to the apex of the second bicuspid in the IG was found to be 44.10% on the distal side, 32.40% on the mesial side, and 23.50% intersected with the apex (Fig. 2).

The average length of MF in the NIG was 3.64 mm ($SD \pm 1.17$ mm), and in IG was 3.56 mm ($SD \pm 1.22$ mm). The average breadth of MF in the NIG was 3.55 mm ($SD \pm 0.79$), and in IG 3.53 mm ($SD \pm 1.19$ mm). The average vertical distance of MF from the lower border of the mandible to the lower border of the MF (DLM) in the NIG was 14.13 mm ($SD \pm 1.75$), and in the IG 16.85 mm ($SD \pm 3.06$ mm), and the disparities were statistically signifi-

cant ($p < 0.05$). The average vertical distance of MF from the DAC in the NIG was 6.56 ($SD \pm 2.02$ mm), and in IG, 6.67 mm ($SD \pm 2.28$ mm) (Table 1).

4. Discussion

Recording the position of the MF allows for accurate delivery of local anesthesia for dental procedures and the prevention of damage to the mental nerve during implant and other surgical procedures (Neo, 1989). DPI was used in this study because MF was seen more regularly on the wide field of view in DPI of the mandible than on intraoral periapical images (Haghanifar and Rokouei, 2009). In this DPI study, the most common horizontal location of MF in relation to the apices of

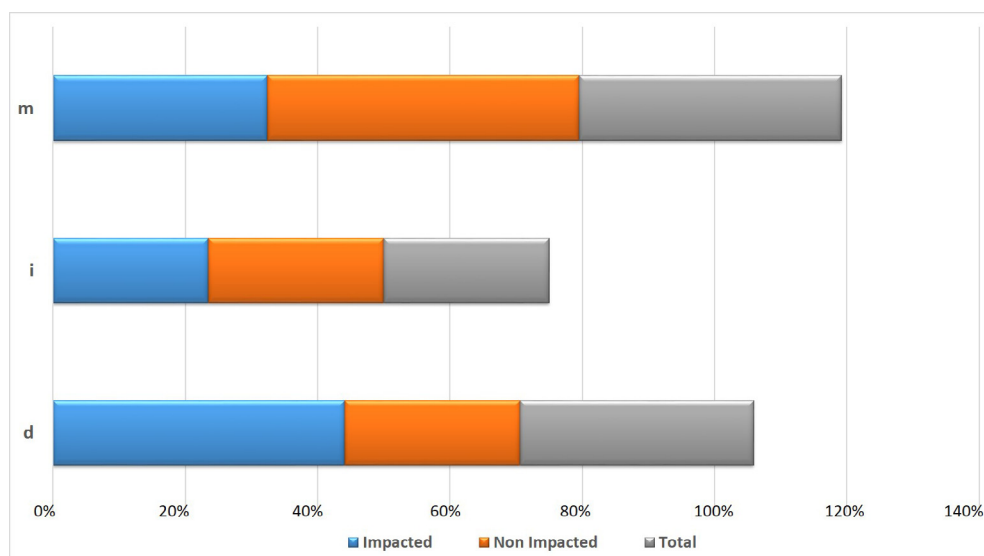


Fig. 2 Average position of MF in IG and NIG. m: mesial, i: intersecting, d: distal.

Table 1 Length, Breadth and vertical location of the MF in IG and NIG.

	Groups	Mean	SD	95% CI		p value
				Lower	Upper	
Length MF	IG	3.562	1.229	-0.661	0.502	0.786
	NIG	3.641	1.170			
Breadth MF	IG	3.538	1.195	-0.504	0.480	0.962
	NIG	3.550	0.799			
DLM	IG	16.850	3.065	1.511	3.929	> 0.001
	NIG	14.132	1.754			
DAC	IG	6.677	2.284	-0.932	1.156	0.831
	NIG	6.565	2.020			

DLM: Distance from lower border of mandible to the lower border of MF; DAC: Distance from alveolar crest to the superior border of MF; SD: Standard deviation; CI: Confidence Interval.

teeth in NIG was found to be 'location c' (between the apices of the first and second bicuspid), which accounted for 64.70%. Results from this study concurred with those of some previous studies on different populations (Gada and Nagda, 2014; Gupta et al., 2015; Haghanifar and Rokouei, 2009; Moiseiwitsch, 1998), but disagreed with few others (Ngeow and Yuzawati, 2003; Al Jasser and Nwoku, 1998; Afkhami et al., 2013; Alam et al., 2018). Velasco-Torres *et al.*, analyzed 348 cone beam computed tomography (CBCT) images for the trajectory of the inferior alveolar nerve, MF location, and incidence of mental nerve anterior loop, and found that the most common horizontal location of MF was between the apices of the first and second bicuspid (98%) (Velasco-Torres et al., 2017). The most common horizontal location of MF in relation to the apices of the teeth in the IG was found to be 'location d' (in line with the second bicuspid), which accounted for 47.10%. This finding suggests that IMC may be responsible for the slight horizontal shift in the location of the MF in the IG.

In this investigation, the average function of MF relative to the apex of the second bicuspid in NIG was found to be 47.10% on the mesial side, which was analogous to the outcomes reported by Gupta et al. (2015), Phillips et al. (1992). However, Moiseiwitsch (1998) reported that 90% of the mental foramen was detected immediately distal to the second bicuspid. The average proportion of MF in relation to the apex of the second bicuspid in the IG was found to be 44.10% on the distal side. Similar to the horizontal shift of MF, IMC may play a role in the distal shift of the MF position.

This study revealed that the average length of MF in the NIG was 3.64 mm (SD \pm 1.17 mm), and an IG of 3.56 mm (SD \pm 1.22 mm). These findings were not in agreement with that of Gupta et al. (2015) and Alma et al., (2015). The average breadth of MF in NIG was 3.55 mm (SD \pm 0.79 mm), and in IG 3.53 mm (SD \pm 1.19 mm). Møystad et al. studied the MF size in postoperative neurosensory dysfunction subjects using ultrasonography and found significantly smaller MF on the injured side 2.5 (SD \pm 8 mm). The result was not in agreement with our study (Møystad et al., 2015). The average vertical distance of MF from DLM in NIG was 14.13 mm (SD \pm 1.75 mm), and in IG, 16.85 mm (SD \pm 3.06 mm). The average vertical distance of MF from DAC in the NIG is 6.56 mm (SD \pm 2.02 mm), and in IG, 6.67 mm (SD \pm 2.28 mm). However, the calculated p value did not show any statistical significance between the above-mentioned parameters except for the

vertical distance of MF from DLM. The results obtained from our study were similar to those obtained by Phillips et al. (1992) but not in accordance with the study done by Gupta et al., (2015). In this study, the effect of IMC on MF position in the Saudi Arabian population was investigated. After an exhaustive literature search, it was found that this kind of study has not been conducted so far in any Saudi population, and that this is the first study of its type. In this study, it was observed that MF location shifted distally secondary to IMC in IG. It was also revealed that the average position of the MF in relation to the apex of the mandibular bicuspid lied more on distal side in IG; however, no major statistical significance was observed between NIG and IG. Therefore, based on the above two facts it can be inferred that the IMC may influence the location and position of the MF. However, from our study it appears that IMC did not have any influence on the size and vertical location of the MF. The key limitation of our study is that two-dimensional DPI was used. In future studies, more advanced three-dimensional cone beam imaging should be employed to examine a wide range of samples for more accurate results (Ulu et al., 2016).

5. Conclusions

This study demonstrated that the most common horizontal location of MF was found between the apices of the first and second bicuspid in NIG, and it was in line with the second bicuspid in the IG. This study depicts the most frequent manifestation of MF in relation to the apex of the second bicuspid was positioned more mesially in NIG but more distally in the IG. As far as the effect of IMC on MF was concerned, findings from this present study suggest that IMC has a definite influence on the location and position of the MF. Therefore, the influence of IMC along with the correct radiographic identification of MF becomes important and must be considered before any invasive and noninvasive procedures in the mandible near MF.

Declaration of Competing Interest

The authors declare that they have no known competing financial interests or personal relationships that could have appeared to influence the work reported in this paper.

References

- Afkhami, F. et al, 2013. Radiographic localization of the mental foramen and mandibular canal. *J. Dent. (Tehran)*. 10, 436–442.
- Al Jasser, N.M., Nwoku, A.L., 1998. Radiographic study of mental foramen in a selected Saudi population. *Dento. Maxillafac. Radiol.* 27, 341–343.
- Alam, M.K. et al, 2018. 3D CBCT morphometric assessment of mental foramen in Arabic population and global comparison: imperative for invasive and non-invasive procedures in mandible. *Acta Odontol. Scand.* 76 (2), 98–104.
- Alma, V. et al, 2015. Morphological and morphometric analysis of the shape, position, number and size of mental foramen on human mandibles. *Actamedica* 44 (1), 31–38.
- Chkoura, A., El Wady, W., 2013. Position of the mental foramen in a Moroccan population: a radiographic study. *Imaging. Sci. Dent.* 43 (2), 71–75.
- Dalessandri, D. et al, 2017. Impacted and transmigrant mandibular canines incidence, aetiology, and treatment: a systematic review. *Eur. J. Orthod.* 39 (2), 161–169.
- Gada, S.K., Nagda, S.J., 2014. Assessment of position and bilateral symmetry of occurrence of mental foramen in dentate Asian population. *J. Clin. Diagn. Res.* 8, 203–205.
- Gupta, V. et al, 2015. Panoramic radiographic study of mental foramen in selected Dravidians of south Indian population: a hospital based study. *J. Clin. Exp Dent.* 7 (4), 451–456.
- Haghanifar, S., Rokouei, M., 2009. Radiographic evaluation of the mental foramen in a selected Iranian population. *Indian J. Dent. Res.* 20, 150–152.
- Kqiku, L. et al, 2013. Position of the mental foramen in Kosovarian population. *CollAntropol.* 37 (2), 545–549.
- Moiseiwitsch, J.R., 1998. Position of mental foramen in a North American, White population. *Oral Surg. Oral Med. Oral Pathol. Oral Radiol. Endod.* 85, 457–460.
- Møystad, A. et al, 2015. Ultrasonographic pilot study of mental foramen size, with and without postoperative neurosensory dysfunction. *Oral Surg. Oral Med. Oral Pathol. Oral Radiol.* 120 (2), 275–280.
- Neo, J., 1989. Position of the mental foramen in Singaporean Malays and Indians. *AnesthProg.* 36, 276–278.
- Ngeow, W.C., Yuzawati, Y., 2003. The location of the mental foramen in a selected Malay population. *J. Oral Sci.* 45 (3), 171–175.
- Phillips, J.L. et al, 1992. The mental foramen: 3. size and position on panoramic radiograph. *J Endod.* 18, 383–386.
- Ulu M. et al, 2016. Unilateral Absence of Mental Foramen with Surgical Exploration in a Living Human Subject. *Case Rep Dent.* Volume 2016, Article ID 1971925, 4 pages.
- Velasco-Torres, M. et al, 2017. Inferior alveolar nerve trajectory, mental foramen location and incidence of mental nerve anterior loop. *Med. Oral Patol. Oral Cir. Bucal.* 22 (5), 630–635.
- Zaman, S. et al, 2016. Mental foramen position using modified assessment system: an imperative landmark for implant and orthognathic surgery. *J. Hard Tissue Biol.* 25 (4), 365–370.