

Rationale and study design for one-stop assessment of renal artery stenosis and renal microvascular perfusion with contrast-enhanced ultrasound for patients with suspected renovascular hypertension

Jun-Hong Ren¹, Na Ma¹, Si-Yu Wang¹, You-Jing Sun¹, Yue-Wei Zhang¹, Fa-Jin Guo¹, Yong-Jun Li², Tian-Hui Li³, Hu Ai⁴, Wen-Duo Zhang⁴, Peng Li⁵, Wei-Hua Ma¹

¹Department of Sonography, Beijing Hospital, National Center of Gerontology, Beijing 100730, China;

²Vascular Department, Beijing Hospital, National Center of Gerontology, Beijing 100730, China;

³Nephrology Department, Beijing Hospital, National Center of Gerontology, Beijing 100730, China;

⁴Department of Cardiology, Beijing Hospital, National Center of Gerontology, Beijing 100730, China;

⁵Beijing Hospital, National Center of Gerontology, Beijing 100730, China.

Abstract

Background: Renal artery stenosis (RAS) is always associated with abnormalities in renal microvascular perfusion (RMP). However, few imaging methods can simultaneously evaluate the degree of luminal stenosis and RMP. Thus, this study will aim to evaluate the feasibility of using contrast-enhanced ultrasound (CEUS) for assessing both RAS and RMP to achieve a one-stop assessment of patients with suspected renovascular hypertension.

Methods: This will be a single-center diagnostic study with a sample size of 440. Patients with chronic kidney disease (CKD) and suspected of having resistant hypertension will be eligible. Patients with Stages 1–3 CKD will undergo CEUS and computed tomography (CT) angiography (CTA). Values obtained by CEUS and CTA for diagnosing low-grade (lumen reduced by <60%) and high-grade (lumen reduced by ≥60%) RAS will be compared. Moreover, all patients will also undergo radionuclide imaging. The diagnostic value for RAS will be assessed by the receiver operating characteristic curve, including the accuracy, sensitivity, specificity, positive predictive values, negative predictive values, and area under the ROC. Pearson correlation analysis will be performed to assess the association between CEUS findings for RMP and glomerular filtration rate measured by a radionuclide imaging method.

Conclusion: The data gathered from this study will be used to evaluate the feasibility of expanding clinical applications of CEUS for evaluation of patients with suspected renovascular hypertension.

Trial Registration: Chinese Clinical Trial Registry, ChiCTR1800016252; <https://www.chictr.org.cn>.

Keywords: Renovascular hypertension; contrast-enhanced ultrasound; renal artery stenosis; renal microvascular perfusion

Introduction

Renal artery stenosis (RAS) is a common condition with a poor prognosis. Atherosclerosis accounts for nearly 90% of RAS in older persons and it usually involves the ostium and proximal third of the main renal artery and the perirenal aorta.^[1] RAS is associated with increased risk of renal microvascular perfusion (RMP) abnormalities. Renal cortical perfusion dysfunction becomes significant even at a RAS around 30%.^[2,3] Moreover, compared with patients with hypertension and patent renal arteries, those with hypertension and low-grade stenosis have been shown to have markedly faster decline in renal function

and to be at higher risk of cardiovascular complications.^[4] Kalra *et al*^[5] have shown that, compared with the general population, incident RAS that has developed in individuals without renovascular disease is associated with a markedly increased risk of cardiovascular complications and mortality. Therefore, one-stop evaluation of RAS and RMP in patients with suspected renovascular hypertension is warranted.

Conventional imaging techniques are suboptimal for 1-stop assessment for RAS and RMP. Contrast-enhanced computed tomography (CT) renal angiography (CTA) and CT perfusion imaging is commonly used to evaluate RAS

Access this article online

Quick Response Code:



Website:
www.cmj.org

DOI:
10.1097/CM9.000000000000002

Correspondence to: Dr. Jun-Hong Ren, Department of Sonography, Beijing Hospital, National Center of Gerontology, No. 1, Dahua Road, Dongcheng District, Beijing 100730, China
E-Mail: renjunhong2002@hotmail.com

Copyright © 2018 The Chinese Medical Association, produced by Wolters Kluwer, Inc. under the CC-BY-NC-ND license. This is an open access article distributed under the terms of the Creative Commons Attribution-Non Commercial-No Derivatives License 4.0 (CCBY-NC-ND), where it is permissible to download and share the work provided it is properly cited. The work cannot be changed in any way or used commercially without permission from the journal.

Chinese Medical Journal 2019;132(1)

Received: 29-10-2018 Edited by: Ning-Ning Wang

and RMP simultaneously.^[6] Additionally, with technological advances, MR angiography and dynamic MR techniques for measuring renal perfusion are also being used to assess RAS and RMP.^[7] However, these methods often require intravenous injection of contrast agents, which are hazardous in patients with renal insufficiency,^[8] rendering them dangerous in patients with Stages 4 and 5 chronic kidney disease (CKD). Furthermore, radionuclide methods involve exposure to radioactivity.^[9] Therefore, a safe and effective 1-stop method for evaluating RAS and RMP is needed.

Contrast-enhanced ultrasound (CEUS) is a reliable and non-invasive imaging method for assessing RAS and RMP. Many studies have confirmed that CEUS is a safe and accurate means for evaluating the degree of stenosis and RMP.^[10,11] However, there are few prior studies on investigating the feasibility of CEUS in patients with renovascular hypertension. Hence, we plan to perform this study to evaluate the safety and feasibility of CEUS for evaluating RAS and RMP.

Methods

Ethical approval

The present study will be conducted in Beijing in China, and be in accordance with the guiding principles for human experimentation summarized in the latest version of the *Declaration of Helsinki*. The study protocol has been approved by the Institutional Review Board (IRB) of Beijing Hospital (No. 2018BJYYEC-043-02), and will meet regularly and monitor the progress of this study. Informed consent will be obtained from all participants.

Study design

This will be a single-center diagnostic study. First, all patients with suspected resistant hypertension will undergo CEUS and CTA. Based on the stenotic degree of luminal diameter, RAS is divided into low-grade (lumen reduced by <60%) and high-grade (lumen reduced by ≥60%) stenosis.^[12] Thus, the diagnostic value of CEUS for low and high-grade RAS will be compared with CTA. Second, all patients will undergo CEUS and radionuclide imaging, and associations between RMP variables evaluated by CEUS and glomerular filtration rate (GFR) measured by radionuclide methods will be analyzed to find the optimal RMP variable associated with GFR. Therefore, CEUS with 1-stop strategy will constitute assessment of RAS and RMP simultaneously.

Study organization

This study has been designed by a team of researchers from an external institution, National Center of Gerontology, Beijing Hospital. It will be conducted in 3 Departments, those of Cardiology, Nephrology, and Vascular Disease, in the authors' institution. The Executive Committee includes a project manager, research physicians/investigators, and research coordinators. The project manager will review all case report forms to ensure that enrolment criteria have

been met, the protocol has been correctly implemented, and reports are accurate each week after enrolment. All investigators and study staff are required to attend a site training to explain the protocol before the study is initiated.

Participants

Adult patients (age ≥18 years old) of both sexes with suspected renovascular hypertension will be assessed for eligibility according to the following inclusion and exclusion criteria.

Inclusion criteria

Patients suspected of resistant hypertension will be included in this study.^[13,14] Eligibility requires meeting of one of the following criteria: (1) onset of hypertension before the age of 30 years or severe hypertension and age >55 years; (2) resistant, malignant, or accelerated hypertension; (3) development of new azotemia or worsening renal function after administration of an angiotensin converting enzyme inhibitor or angiotensin receptor blocker; (4) unexplained atrophic kidney or size discrepancy between kidneys of >1.5 cm; (5) unexplained renal dysfunction; (6) sudden, unexplained pulmonary edema; (7) abdominal vascular bruits; (8) hypokalemia; or (9) other vascular diseases such as peripheral arterial disease.

Exclusion criteria

Individuals who met any of the following exclusion criteria will be excluded from this study: (1) severe heart and/or pulmonary dysfunction; (2) sensitive to sulfur hexafluoride and/or iodinated contrast agent; (3) pregnancy; (4) co-existing cancer; or (5) poor images.

Study procedures

All participants will be identified by inpatient services of the 3 participating wards. A research physician will confirm the diagnosis of RAS by CTA and the GFR by a radionuclide imaging method. The one-stop strategy will constitute assessment of RAS followed by evaluation of RCP with CEUS.

The CEUS will be performed with the patient in a supine and/or left or right lateral position, depending on which artery is being assessed. All assessments will be performed by 3 operators (Ren JH, Ma N and Wang SY), using a high-resolution ultrasonograph (GE LOGIQ E8 with a 3.5–5 MHz electronic probe) and an intravenous contrast galactose microparticle suspension containing microbubbles (SF6; Sono Vue, Bracco, Milan, Italy). An injectable preparation of 5 mL of a suspension of Sono Vue will be administered by bolus injection (1.25 mL for each kidney). The Sono Vue will provide amplification of the Doppler signal for 5 min from starting the bolus. RAS will be diagnosed in accordance with the indirect or direct criteria [Table 1]. RMP variables will be analyzed using specialized computer software Sonoliver[®] (TomTec Imaging Systems, Germany) that generates time-dependent intensity curves on selected regions of interest in the renal cortex. Peak

Table 1: Contrast-enhanced ultrasound criteria for the evaluation of renal artery stenosis

Stenosis degree	Indirect criteria			Direct criteria		
	PSV-P (cm/s)	PSV-A (cm/s)	RAR	D-SRS	D-MRA	D-SRS/D-MAR
Low grade	150–180	NA	≥2.0	NA	NA	<0.6
High grade	>180	NA	≥3.5	NA	NA	≥0.6
Obstruction	0	NA	NA	0	NA	0

D-MRA: diameter at the main renal artery; D-SRS: diameter at the stenotic renal artery; PSV-A: peak systolic velocity of the abdominal aorta; PSV-P: peak systolic velocity at the proximal main renal artery; RAR: renal aortic ratio PSV-P/PSV-A: lesion divided by the diameter at the normal renal artery; NA: not available.

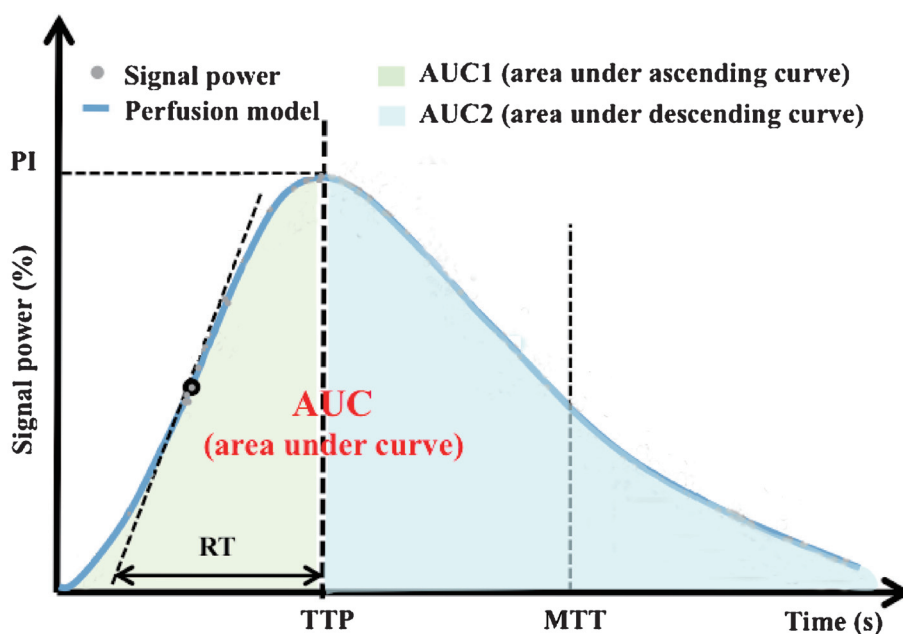


Figure 1: Time-dependent intensity curves (TIC) based on selected regions of interest. AUC: area under the curve; MTT: mean transit time; PI: peak intensity; TTP: time to peak intensity; RT: rise time.

intensity (PI), time-to-peak intensity (TTP), mean transit time (MTT), and area under the curve (AUC) will be the key observational variables for renal RMP [Figure 1]. CEUS images will be independently reviewed by 2 radiologists who will be blinding to the study.

Data collection

Data will be collected via abstraction from central medical charts, physical examinations, and laboratory tests. Standardized instruments will be used. All data will be treated as protected health information and securely stored in a password-protected database.

Study outcomes

The primary outcome is the diagnostic value of CEUS compared with CTA for low-grade (lumen reduced by <60%) and high-grade (lumen reduced by ≥60%) RAS,^[12] including (1) positive predictive value (PPV); (2) negative predictive value (NPV); (3) sensitivity; (4)

specificity; (5) accuracy; and (6) area under the receiver operating characteristic curve.

The secondary outcome is the association between CEUS findings for RMP and GFR measured by a radionuclide imaging method. These variables will include PI, rise time (RT), TTP, MTT, AUC.

Safety end points are the risks of local or systemic adverse events associated with planned imaging methods, including the number (percentage) of patients having allergic reactions, palpitation, dizziness, and contrast-induced nephropathy (CIN).^[15] CIN will be diagnosed if all 4 of the following criteria are met: (1) exposure to contrast agent; (2) increase in serum creatinine concentration of 0.5 mg/dL or 25% greater than baseline; (3) increase in serum creatinine concentration occurring 48–72 h after administration of contrast agent and persisting for 2–5 d; and (4) exclusion of alternative major responsible factors. Any new condition (symptom, injury, or significant abnormal laboratory value) that is not present at the beginning of the study will be documented as an unexpected adverse event. Serious adverse events, including

death, life-threatening events, hospitalization or prolongation of hospitalization, requirement of medical/surgical intervention, and CIN, will be reported to the Institutional Review Board (IRB) within 24h.

Statistical analysis

In this diagnostic study, categorical variables will be compared. In accordance with the previous studies,^[16,17] the hypothetical sensitivity is 0.85 and specificity is 0.9, and acceptable variations in sensitivity and specificity both is 0.05. With α as 0.05, 2-tailed test, and accuracy as 0.5, the minimal required sample size is 400. If the attrition rate can be kept at 1 higher than 0.1, a sample size of 440 should be adequate.

Results will be analyzed quantitatively with STATA 14.0 software (Stata, CA). Continuous variables will be expressed as mean \pm standard deviation (SD), and categorical variables expressed as frequencies or percentages. Categorical variables will be compared using the χ^2 or Fisher's exact test and quantitative variables using the paired samples *t*-test. The diagnostic value for RAS will be assessed by the receiver operating characteristic curve, including the accuracy, sensitivity, specificity, PPVs, NPVs, and AUC. Pearson correlation analysis will be performed to assess the association between CEUS findings for RMP and GFR measured by a radionuclide imaging method. Statistical significance will be set at 0.05.

Discussion

This will be a single-center diagnostic study aimed at investigating the feasibility, safety, and accuracy of CEUS for 1-stop assessment of RAS and RMP in patients with suspected renovascular hypertension. The study will provide evidence as to whether CEUS can safely and reliably provide clinical benefits with respect to simultaneous evaluation of RAS and RMP, especially in patients with renal insufficiency.

The CEUS is a reliable imaging method to assess the functional significance of RAS. What extent a kidney is influenced depends on not only the degree of the stenosis, but also how acutely this happens, and the autoregulatory potential of the kidney. Real-time CEUS using microbubble-based contrast agents, which are well regarded for the renal safety, high tolerance, and lack of radiation, can visualize the perfused microvascular bed. Kogan *et al*^[18] found that CEUS-derived parameters, such as PI, TTP, MTT, and area under the time-dependent intensity curve, were comparable to absolute measurements of blood flow in rat kidney. In humans, CEUS has already been used to the study of various kidney diseases, including acute kidney injury,^[19] CKD,^[20] and kidney transplantation.^[21] By assessing RMP, CEUS could not only evaluate renal dysfunction, but also predict early kidney injury.^[22] Furthermore, several clinical studies have showed that angioplasty with or without stenting could not decrease the level of systolic blood pressure, the rate of renal events and cardiovascular complications in patients with high-grade stenosis.^[23–25] However, the included patients were with high-grade stenosis, had little viable kidney tissue left, and

their chances to improve after revascularization were poor.^[26] Therefore, CEUS may be useful to guide the patient selection and efficacy evaluation in angioplasty procedure. Collectively, CEUS can provide real-time, non-invasive, and relative quantitative estimate of RMP and offers great potential in monitoring and predicting renal injury in acute and chronic renal disease. However, there is no international standard for assessing RMP. Hence, well-powered clinical studies are needed to establish the parameters that are optimal for clinical evaluation and the normal range in different patient groups.

This study could make several important contributions to expanding clinical applications of CEUS in patients with suspected renovascular hypertension. First, this study will provide preliminary evidence of the accuracy of CEUS for RAS in real-world practice, especially in patients with low-grade stenosis. Second, this study will provide evidence concerning the safety of CEUS, especially in patients with Stages 4 and 5 CKD. Third, this study will promote the clinical application of CEUS for assessment of renal RMP. Real-time CEUS using microbubble-based contrast agents, which are well regarded for their renal safety, high tolerance, and lack of radiation, enable visualization of the perfused microvascular bed.^[27] Thus, CEUS can provide real-time, non-invasive,^[28] and relative quantitative estimate of renal RMP and offers great potential for monitoring and prediction of renal injury in acute and chronic renal disease.^[29]

Study limitations

The present study has a few limitations. First, this study was a single-center design, therefore, it cannot represent the actual situation of the whole RAS population owing to geographical and regional differences. Second, there are inherent limitations to use an observational method owing to these unmeasured or undefined confounding factors. Third, there is no international standard for assessing RMP, and the normal range in different patient groups is also lacking. Fourth, CEUS is operator dependent. Previous study showed that imaging quality was correlated with the radiologist's experience, and it was markedly higher for radiologists who had performed more than 60 CEUS examination.^[30] Fifth, CEUS has an inherent relatively high variability, related to several factors, including the patient, contrast agent used, and machine settings. Stock *et al*^[31] found that time-related parameters for the renal cortex showed a reasonable repeatability, whereas poor repeatability is present for intensity-related parameters and those related to inflow and outflow of contrast agent. Furthermore, Lassau *et al*^[32] showed that AUC and area under the washout are the 2 most reproducible CEUS parameters. Therefore, future studies will require larger numbers of patients, careful matching of key clinical and technical variables to definitively quantify the potential clinical value of one-stop evaluation of RAS and RMP by CEUS for patients with suspected RAS.

In summary, we have designed this study to evaluate the feasibility, safety, and accuracy of CEUS for 1-stop assessment of RAS and RMP in patients with resistant hypertension.

Acknowledgements

The authors acknowledge Dr. Yang Wang from National Center for Cardiovascular Diseases, Fuwai Hospital, Chinese Academy of Medical Sciences, for study design and sample size calculation. Meanwhile, they also thank Dr. Trish Reynolds, MBBS, FRACP, from Liwen Bianji, Edanz Group China (www.liwenbianji.cn/ac), for editing the English text of a draft of this manuscript.

Funding

This study was supported by grants from the Beijing Hospital Clinical Research 121 Project (No. BJ-2018-198) and the Scientific Research Project of Beijing Hospital (No. 2018-001).

Conflicts of interest

There are no conflicts of interest.

References

- Soliman KM, Abdul Salim S, Fülöp T. Renal artery stenosis in China: the state of changes. *J Clin Hypertens (Greenwich)* 2018;2:1310–1312. doi: 10.1111/jch.13359.
- Gross CM, Kramer J, Weingartner O, Uhlich F, Luft FC, Waigand J, et al. Determination of renal arterial stenosis severity: comparison of pressure gradient and vessel diameter. *Radiology* 2001;220:751–756. doi: 10.1148/radiol.2203001444.
- Schreij G, Ritsema GH, Vreugdenhil G, de Leeuw PW. Stenosis and renographic characteristics in renovascular disease. *J Nucl Med* 1996;37:594–597.
- Mers DI, Poole LJ, Imam K, Scheel PJ, Eustace JA. Renal artery stenosis by three-dimensional magnetic resonance angiography in type 2 diabetics with uncontrolled hypertension and chronic renal insufficiency: prevalence and effect on renal function. *Am J Kidney Dis* 2003;41:351–359. doi: 10.1053/ajdk.2003.50043.
- Kalra PA, Guo H, Kausz AT, Gilbertson DT, Liu J, Chen SC, et al. Atherosclerotic renovascular disease in United States patients aged 67 years or older: risk factors, revascularization, and prognosis. *Kidney Int* 2005;68:293–301. doi: 10.1111/j.1523-1755.2005.00406.x.
- Rountas C, Vlychou M, Vassiou K, Liakopoulos V, Kapsalaki E, Koukoulis G. Imaging modalities for renal artery stenosis in suspected renovascular hypertension: prospective intraindividual comparison of color Doppler US, CT angiography, GD-enhanced MR angiography and digital subtraction angiography. *Ren Fail* 2007;29:295–302. doi: 10.1080/08860220601166305.
- Slanina M, Zizka J, Klzo L, Lojik M. Contrast-enhanced MR angiography utilizing parallel acquisition techniques in renal artery stenosis detection. *Eur J Radiol* 2010;75:e46–e50. doi: 10.1016/j.ejrad.2009.07.010.
- Michaely HJ, Kramer H, Oesingmann N, Lodemann KP, Reiser MF, Schoenberg SO. Semiquantitative assessment for first-pass renal perfusion at 1.5 T: comparison of 2D saturation recovery sequences with and without parallel imaging. *AJR Am J Roentgenol* 2007;188:919–926. doi: 10.2214/AJR.06.0567.
- Taylor AT. Radionuclides in nephrourology. Part 2: pitfalls and diagnostic applications. *J Nucl Med* 2014;55:786–798. doi: 10.2967/jnumed.113.133454.
- Schäberle W, Leyerer L, Schierling W, Pfister K. Ultrasound diagnostics of renal artery stenosis: stenosis criteria, CEUS and recurrent in-stent stenosis. *Gefasschirurgie* 2016;21:4–13. doi: 10.1007/s00772-015-0060-3.
- Schneider A, Johnson L, Goodwin M, Schelleman A, Bellomo R. Bench-to-bedside review: contrast enhanced ultrasonography—a promising technique to assess renal perfusion in the ICU. *Crit Care* 2011;15:157. doi: 10.1186/cc10058.
- Cooper CJ, Murphy TP, Cutlip DE, Jamerson K, Henrich W, Reid DM, et al. Stenting and medical therapy for atherosclerotic renal-artery stenosis. *N Engl J Med* 2014;370:13–22. doi: 10.1056/NEJMoa1310753.
- Calhoun DA, Jones D, Textor S, Goff DC, Murphy TP, Toto RD, et al. Resistant hypertension: diagnosis, evaluation, and treatment. A scientific statement from the American Heart Association Professional Education Committee of the Council for High Blood Pressure Research. *Hypertension* 2008;51:1403–1419. doi: 10.1161/HYPERTENSIONAHA.108.189141.
- Liu LS. Writing Group of 2010 Chinese Guidelines for the Management of Hypertension. 2010 Chinese guidelines for the management of hypertension (In Chinese). *Chin J Cardiol* 2011;39:579–615.
- Solomon R. Contrast media: are there differences in nephrotoxicity among contrast media? *Biomed Res Int* 2014;2014:934947. doi: 10.1155/2014/934947.
- Argalia G, Cacciamani L, Fazi R, Salera D, Giuseppetti GM. Contrast-enhanced sonography in the diagnosis of renal artery stenosis: comparison with MR-angiography. *Radiol Med* 2004;107:208–217.
- Xu JL, Shi DP, Li YL, Zhang JL, Zhu SC, Shen H. Non-enhanced MR angiography of renal artery using inflow-sensitive inversion recovery pulse sequence: a prospective comparison with enhanced CT angiography. *Eur J Radiol* 2011;80:e57–e63. doi: 10.1016/j.ejrad.2010.08.004.
- Kogan P, Johnson KA, Feingold S, Garrett N, Guracar I, Arendshorst WJ, et al. Validation of dynamic contrast-enhanced ultrasound in rodent kidneys as an absolute quantitative method for measuring blood perfusion. *Ultrasound Med Biol* 2011;37:900–908. doi: 10.1016/j.ultrasmedbio.2011.03.011.
- Cao W, Cui S, Yang L, Wu C, Liu J, Yang F, et al. Contrast-enhanced ultrasound for assessing renal perfusion impairment and predicting acute kidney injury to chronic kidney disease progression. *Antioxid Redox Signal* 2017;27:1397–1411. doi: 10.1089/ars.2017.7006.
- Dong Y, Wang WP, Cao J, Fan P, Lin X. Early assessment of chronic kidney dysfunction using contrast-enhanced ultrasound: a pilot study. *Br J Radiol* 2014;87:20140350. doi: 10.1259/bjr.20140350.
- Wang X, Yu Z, Guo R, Yin H, Hu X. Assessment of postoperative perfusion with contrast-enhanced ultrasonography in kidney transplantation. *Int J Clin Exp Med* 2015;8:18399–18405.
- Wang L, Mohan C. Contrast-enhanced ultrasound: a promising method for renal microvascular perfusion evaluation. *J Transl Int Med* 2016;4:104–108. doi: 10.1515/jtim-2016-0033.
- Tuttle KR, Dworkin LD, Henrich W, Greco BA, Steffes M, Tobe S, et al. Effects of stenting for atherosclerotic renal artery stenosis on eGFR and predictors of clinical events in the CORAL trial. *Clin J Am Soc Nephrol* 2016;11:1180–1188. doi: 10.2215/CJN.10491015.
- Zeller T, Krankenberg H, Erglis A, Blessing E, Fuss T, Scheiner D, et al. A randomized, multi-center, prospective study comparing best medical treatment versus best medical treatment plus renal artery stenting in patients with hemodynamically relevant atherosclerotic renal artery stenosis (RADAR) - one-year results of a pre-maturely terminated study. *Trials* 2017;18:380. doi: 10.1186/s13063-017-2126-x.
- Riaz IB, Husnain M, Riaz H, Asawaer M, Bilal J, Pandit A, et al. Meta-analysis of revascularization versus medical therapy for atherosclerotic renal artery stenosis. *Am J Cardiol* 2014;114:1116–1123.
- Koivuviita N, Liukko K, Kudomi N, Oikonen V, Tertti R, Manner I, et al. The effect of revascularization of renal artery stenosis on renal perfusion in patients with atherosclerotic renovascular disease. *Nephrol Dial Transplant* 2012;27:3843–3848. doi: 10.1093/ndt/gfs301.
- García Roch C, Muñoz Cepeda MÁ, García García F, Ciampi Dopazo JJ, Pinto Varela JM, Díaz Crespo FJ. Contrast enhanced ultrasound (CEUS) efficiency in renal graft complications evaluation. *Nefrologia* 2018;38:444–446. doi: 10.1016/j.nefro.2017.09.005.
- Al-Hamad S, Hackam DJ, Goldstein SD, Huisman TAGM, Darge K, Hwang M. Contrast-enhanced ultrasound and near-infrared spectroscopy of the neonatal bowel: novel, bedside, noninvasive, and radiation-free imaging for early detection of necrotizing enterocolitis. *Am J Perinatol* 2018;35:1358–1365. [Epub ahead of print]. doi: 10.1055/s-0038-1655768.
- Jennings CG, Houston JG, Severn A, Bell S, Mackenzie IS, Macdonald TM. Renal artery stenosis—when to screen, what to stent? *Curr Atheroscler Rep* 2014;16:416. doi: 10.1007/s11883-014-0416-2.

30. Lassau N, Chapotot L, Benatsou B, Vilgrain V, Kind M, Lacroix J, et al. Standardization of dynamic contrast-enhanced ultrasound for the evaluation of antiangiogenic therapies: the French multicenter Support for Innovative and Expensive Techniques Study. *Invest Radiol* 2012;47:711–716. doi: 10.1097/RLI.0b013e31826dc255.
31. Stock E, Duchateau L, Saunders JH, Volckaert V, Polis I, Vanderperren K. Repeatability of contrast-enhanced ultrasonography of the kidneys in healthy cats. *Ultrasound Med Biol* 2018;44:426–433. doi: 10.1016/j.ultrasmedbio.2017.09.019.
32. Lassau N, Coiffier B, Faivre L, Benatsou B, Bidault S, Girard E, et al. Study of inpatient variability and reproducibility of quantitative

tumor perfusion parameters evaluated with dynamic contrast-enhanced ultrasonography. *Invest Radiol* 2017;52:148–154. doi: 10.1097/RLI.0000000000000324.

How to cite this article: Ren JH, Ma N, Wang SY, Sun YJ, Zhang YW, Guo FJ, Li YJ, Li TH, Ai H, Zhang WD, Li P, Ma WH. Rationale and study design for one-stop assessment of renal artery stenosis and renal microvascular perfusion with contrast-enhanced ultrasound for patients with suspected renovascular hypertension. *Chin Med J* 2019;132:63–68. doi: 10.1097/CM9.0000000000000002.