




CASE REPORT

 OPEN ACCESS  Check for updates

A rare case of necrotizing fasciitis of the leg in an intravenous drug user caused by *Prevotella denticola*

Andrea Bedini ^a, Filippo Medioli^a, Altea Gallerani^a, Irene Venturelli^b, Giacomo Franceschi^a, Marianna Meschiari^a, Erica Franceschini^a, Giacomo Maria Lima^c, Mario Sarti^b and Cristina Mussini^a

^aInfectious Diseases Unit, Azienda Ospedaliero-Universitaria Policlinico di Modena, Modena, Italy; ^bClinical Microbiology Unit, Azienda Ospedaliero-Universitaria Policlinico di Modena, Modena, Italy; ^cNuclear Medicine Unit, Azienda Ospedaliero-Universitaria Policlinico di Modena, Modena, Italy

ABSTRACT

Background: Intravenous drug users (IDUs) have a high risk of developing skin and soft tissue infections such as erysipelas, abscesses, and less frequently necrotizing fasciitis (NF) or gas gangrene. Rarely, the cause of the infection is microorganisms residing in the oral cavity and can lead to life-threatening infections.

Methods: We describe the case of a 43-year-old man intravenous drug user (IDU) who was admitted for intense leg pain following an injection of cocaine at that site.

Results: A clinical and radiological diagnosis of NF was made, so the patient was started on empirical antibiotic therapy and underwent surgical fasciotomy (after 8 hours from admission). *Prevotella denticola* was isolated from multiple intraoperative specimens and was resistant to initial antimicrobial therapy. The man, suffering from periodontal disease, reported sucking the syringe several times to unblock it. Both fasciotomy surgery and adjustment of antimicrobial therapy enabled therapeutic success.

Conclusions: In IDUs the risk of deep skin and soft tissue infections is high and may be aggravated by contamination with oral microorganisms. The choice of empirical antibiotic treatment should include agents active against oral cavity anaerobes, such as *P. denticola*.

ARTICLE HISTORY

Received 27 November 2023

Revised 7 January 2024

Accepted 19 March 2024

KEYWORDS

ABSSSIs; anaerobes; LRINEC Score; intravenous drug user; skin infections; abscesses



Background

Necrotizing fasciitis (NF) is a life-threatening infection characterized by necrosis of muscle fascia and subcutaneous tissues, rapidly spreading to perifascial planes, skin, soft tissues, and muscles [1,2]. This type of infection is usually polymicrobial, caused by Gram-positive, Gram-negative aerobic and anaerobic bacteria. More rarely it is caused by a single microorganism: in these cases, it is often a Gram-positive microorganism such as *Staphylococcus aureus* or *Streptococcus* species. Intravenous drug users (IDUs) represent a population group at high risk of developing serious skin and soft tissue infections, such as NF [3]: favourable factors include direct injection into skin or muscle when veins are no longer accessible ('skin popping'), use of dirty needles, and injection of a mixture of heroin and cocaine [3,4]. We provide a descriptive analysis of a case of NF in a male IDU caused by *Prevotella denticola*, following injection of cocaine into the calf. This is a rare case of NF with monomicrobial aetiology, where the source of infection was identified in the patient's oral cavity.

Case history

The patient described in this article was informed of the publication and he signed the consent form. The Ethics Committee charter of our hospital does not require approval for the publication of case reports.

A 43-year-old male intravenous drug user (IDU) presented to the emergency department with fever, intense pain in his left calf, and localized swelling for 48 hours. The patient reported that he had injected cocaine into his leg 3 days earlier and had difficulties to do it: more than once he had to unblock the syringe by sucking the needle. The general practitioner prescribed Ceftriaxone 2 g/day and gentamicin 160 mg/day for 2 days, but the hyperpyrexia, the leg pain and localized swelling worsened. The patient was admitted to the emergency department, with modified vital signs; blood pressure was 130/70 mm Hg, heart rate 120 bpm, body temperature 38.7°C and normal blood oxygen saturation (98%). No comorbidities were identified, including viral hepatitis B, C, and human immunodeficiency virus. The left calf clinically appeared with moderate erythema, localized swelling (from the proximal 1/3 to the distal 1/3 of the calf) and hard (positive 'wooden hard feel' sign)

CONTACT Andrea Bedini  andreabedini@yahoo.com  Infectious Diseases Unit, Azienda Ospedaliero-Universitaria Policlinico di Modena, Via del Pozzo 71, Modena 41124, Italy

© 2024 The Author(s). Published by Informa UK Limited, trading as Taylor & Francis Group.

This is an Open Access article distributed under the terms of the Creative Commons Attribution-NonCommercial License (<http://creativecommons.org/licenses/by-nc/4.0/>), which permits unrestricted non-commercial use, distribution, and reproduction in any medium, provided the original work is properly cited. The terms on which this article has been published allow the posting of the Accepted Manuscript in a repository by the author(s) or with their consent.

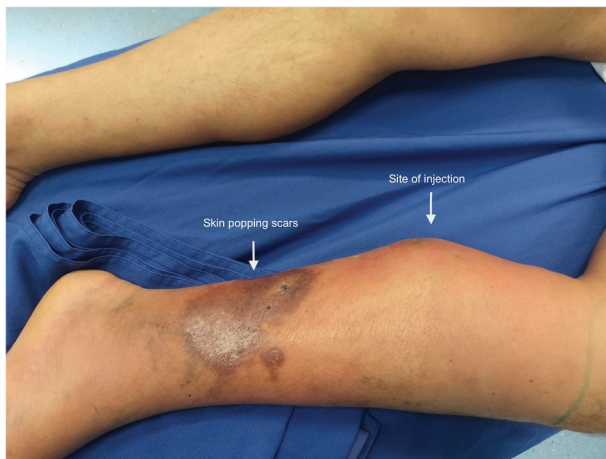

Figure 1. Left calf of a IDU patient: evidence of swelling and ecchymosis in the site of cocaine injection; hyperpigmentation and chronic scarring (skin popping scars) in the distal leg area.

Table 1. The laboratory risk indicator for necrotizing fasciitis score (based on [5]).

| Variable | Value | Score |
|---|---------|-------|
| C-Reactive protein (mg/L) | ≤150 | 0 |
| | >150 | 4 |
| Total white blood cell count (10 ³ cells/μL) | <15 | 0 |
| | 15–25 | 1 |
| | >25 | 2 |
| Hemoglobin (g/dL) | >13.5 | 0 |
| | 11–13.5 | 1 |
| | <11 | 2 |
| Sodium (mmol/L) | ≥135 | 0 |
| | <135 | 2 |
| Creatinine (mg/dL) | ≤1.6 | 0 |
| | >1.6 | 2 |
| Glucose (mg/dL) | ≤180 | 0 |
| | >180 | 1 |

Table 2. LRINEC risk assessment (based on [5]).

| Risk Category | LRINEC Points | Probability for Presence of NF |
|---------------|---------------|--------------------------------|
| Low | ≤5 | <50% |
| Medium | 6–7 | 50–75% |
| High | ≥8 | >75% |

with a small ecchymosis area (Figure 1) in the site of injection. No subcutaneous crepitus was evident. At homolateral distal extremity, there was evidence of drug induced scarring (skin popping; Figure 1). In the suspicion of NF, the Laboratory Risk Indicator for NF (LRINEC) score was calculated. This score is based on six laboratory tests (Table 1) and stratifies patients into low, medium, or high risk of NF (Table 2) [5]. On the admission, the patient had high C-reactive protein (19.8 mg/dl; range: <0.5 mg/dl), white blood cells (19.29×10³/μL; range: 4.0–10.9×10³/μL), low hemoglobin count (11.8 g/dl; range: 13.5–17.5 g/dl), normal sodium (140 mEq/L; range: 136–146 mEq/L), creatinine (0.97 mg/dl; range 0.5–1.4 mg/dl), and glucose count (108 mg/dl; range 70–110 mg/dl). The LRINEC score resulted 6 (intermediate risk of NF). Computed tomography (CT)

scan showed a large subfascial abscess in the posterior region of the leg (axial diameter of 3.5 cm x 7.2 cm and longitudinal extension of 10.4 cm), associated with multiple air bubbles in the adjacent supra-fascial soft tissues down to the skin plane (Figure 2 (a,b)). Pre-operative blood cultures for aerobes and anaerobes were collected, and combination antibiotic treatment was started with piperacillin-tazobactam 4.5 g every 6 hours, daptomycin 600 mg every 24 hours and clindamycin 900 mg every 8 hours (NF therapy protocol of our hospital). After 8 hours from admission, surgical fasciotomy was performed. At the surgical incision of the posterior region of the left calf, from the proximal 1/3 to the distal 1/3, air leaked and a large blood-purulent abscess in the subcutaneous tissue was found. The subcutaneous tissue appeared hard and granular, adhering to the muscle fascia. The tissue was removed, and fasciotomy was performed: in the subfascial area, the superficial portion of the belly of the medial muscle gastrocnemius was found with necrosis and diffuse blood-purulent material. Drainage of necrotic and purulent material (approximately 250 cc) and removal of multiple areas of sub-fascial necrosis was performed. Direct Gram staining of the intraoperative purulent exudate showed no microorganisms. Culture for aerobic organisms was negative (the culture was plated on Columbia agar plus 5% sheep blood incubated in a CO₂-enriched atmosphere, and on MacConkey agar). However, culture for anaerobic microorganisms (Schadler agar; Figure 3) resulted positive after 5 days of incubation in an oxygen-free environment at 35°C, with growth of Gram-negative bacilli (Figure 4). No samples were sent for histopathological examination. Blood cultures for aerobic and anaerobic organisms were negative.

The identification of the anaerobic microorganism was performed using the Vitek Mass Spectrometry (MS): *Prevotella denticola* was identified. No pigmentation was evident. Antimicrobial susceptibility testing, performed via E-test and considering the EUCAST breakpoints, showed resistance to penicillin (MIC >32 μ/dl), to clindamycin (MIC >256 μ/dl), and susceptibility to meropenem (MIC 0.064 μ/dl) and metronidazole (MIC 0.25 μ/dl). Considering that E-test is not validated for piperacillin/tazobactam, Kirby-Bauer test was performed for this agent which showed efficacy against *P. denticola* (MIC not available). We de-escalated the therapy discontinuing daptomycin and clindamycin: the choice to continue piperacillin/tazobactam without adding metronidazole was guided by the excellent clinical response. No plastic surgery procedures were performed for the skin lesions caused by the recent cocaine injection, nor for the previous injections (skin popping scars).

As *P. denticola* is a commensal of the oral cavity, an orthopantomography was performed and it showed

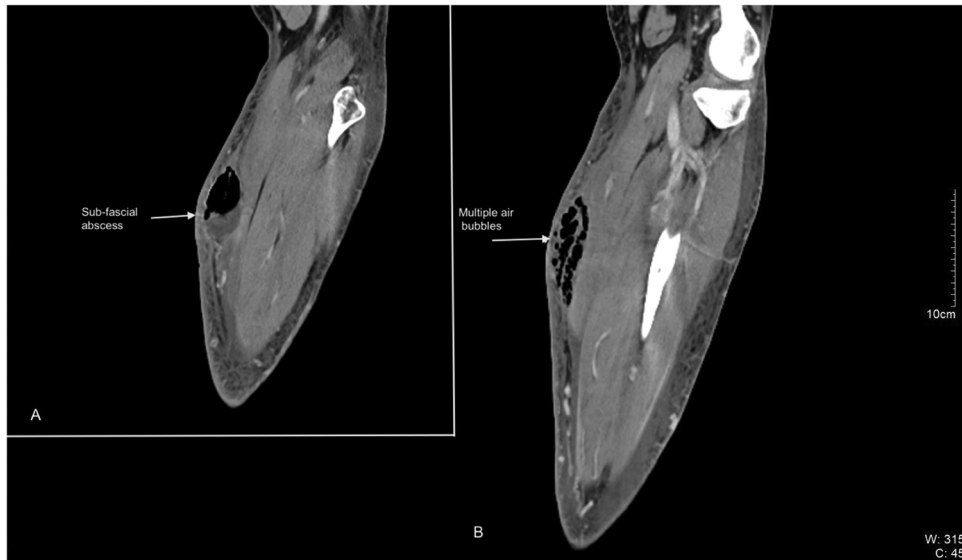


Figure 2.CT scan of the left leg (sagittal scans): evidence of large subfascial abscess (a) and multiple air bubbles in the sub- and supra-fascial soft tissues (b).

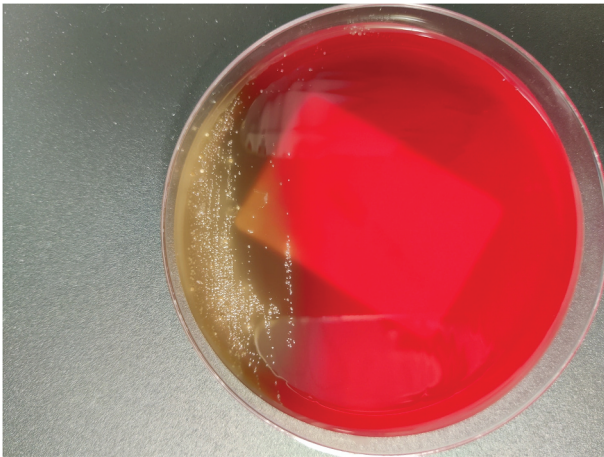


Figure 3.Culture on anaerobic medium (schaedler agar) from intraoperative specimens collected during fasciotomy of the leg.

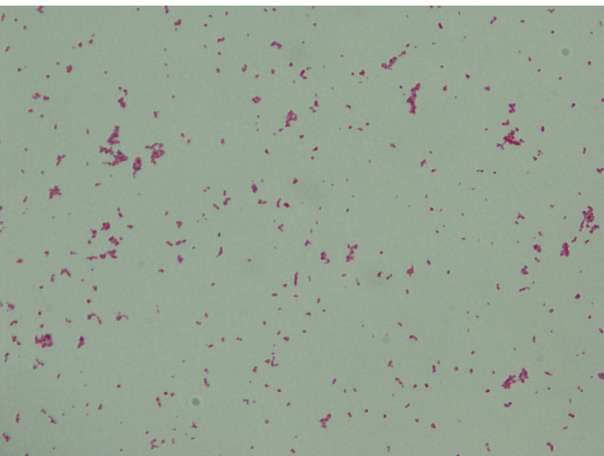


Figure 4.Growth of Gram-negative bacilli on anaerobic medium from intraoperative specimens collected during fasciotomy of the leg.

signs of periodontal disease, with a thin periodontal pocket at the implantation of a tooth element (Figure 5). A trans-thoracic echocardiography was performed which resulted negative for endocarditic vegetations. The clinical course was regular, and on post-operative day 21, therapy has been discontinued and the patient was discharged. At the 6-week follow-up visit, excellent healing of the surgical wound.

Discussion

Prevotella species are anaerobic commensals of the mouth and could contribute to oral inflammatory processes [4]. Rarely, they can cause cervicofacial infections [6,7], peritoneal and pelvic cavity infections (*P. bivia* and *P. disiens*) [8], surgical or human bite wound infections [9], and hepatosplenic abscesses [10]. Cases of NF caused by *Prevotella* spp. mainly affect the head and neck, but the cases of infection due to *P. denticola* are rare: the literature describes 1 case of NF of the leg in an IDU [11], and 1 case of tricuspid endocarditis [12], also in an IDU. In the first case the infection was polymicrobial, in the second monomicrobial. In both cases, it was not reported whether the patient had contaminated the needle with saliva and whether he had periodontal disease, as in our case, or not. In another study that compared the bacteriology of cutaneous and subcutaneous abscesses among IDUs and non-IDUs, *Prevotella* species resulted responsible for 35/86 (40.7%) cases of abscesses in IDUs, and for 14/74 (18.9%) in non-IDUs [13]. The only 3 cases of abscess due to *P. denticola* were observed in the group of IDUs. In the same study, the 67% of the isolates from IDUs group were of oral origin, compared with only the 25% from non-IDUs group.

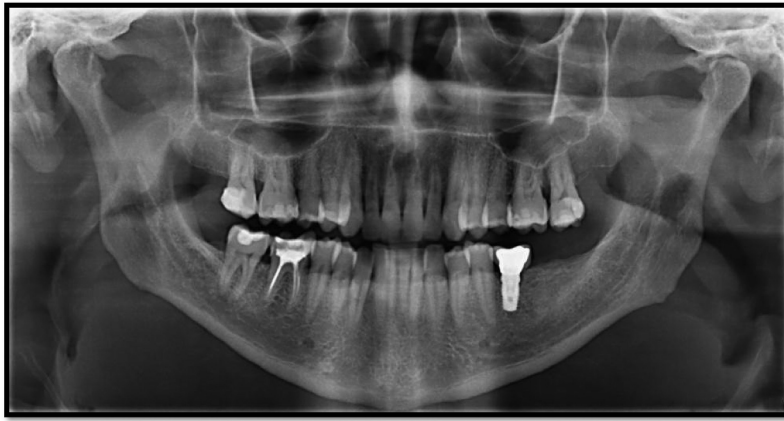

Figure 5. Orthopantomography of the IDU patient: signs of periodontal disease, with a thin periodontal pocket at the implantation of a tooth element.

In our case, the only isolate obtained from culture examination of intra-operative samples was *P. denticola*. Often, more than one microorganism is responsible for NF, especially if the source is assumed to be the microbial flora of the oral cavity. Direct Gram staining of the intra-operative sample was not conclusive, showing no microorganism. This finding may have been influenced, at least in part, by the administration of ceftriaxone and gentamicin prior to admission which may have inhibited the growth of pathogens such as alpha-hemolytic streptococci, methicillin-susceptible staphylococci or Gram-negative bacilli. The culture examination of intra-operative samples may also have been influenced by the antibiotic therapy prior to admission, or by the antibiotic administered during the first 8 hours prior to fasciotomy (piperacillin-tazobactam, daptomycin and clindamycin). Although we know that the clinical course of NF is characterized by a very rapid evolution, we believe that this case has the characteristics of NF, especially because of the macroscopic appearance revealed in the operating room (areas of sub-fascial necrosis), the presence of air bubbles in the supra- and subfascial regions and a LRINEC score of 6 [5]. Unfortunately, no intra-operative material was sent for histopathological analysis that could have confirmed tissue necrosis. Considering that the blood cultures yielded no growth, and that the transthoracic echocardiography revealed no endocarditic vegetations on the valves, we assume it highly probable that the origin of the infection was direct contamination of the needle with the patient's saliva during the tentative to unblock the syringe. The finding of a picture of periodontal disease on the orthopantomography reinforces this belief. It is very likely that the patient had colonization by *P. denticola* and that it was responsible for the periodontal disease.

An interesting finding was the resistance of *P. denticola* to clindamycin and penicillin. While resistance to penicillin is common (up to 40%), resistance

to clindamycin is less frequent: literature data indicate that resistance of *Prevotella* species to clindamycin is < 10% for pigment-producing forms, but higher (12–15%) in non-pigment-producing species [14], as in our case. This is very important to consider: indeed, in many clinical centers, clindamycin is one of the antibiotics used in the empirical therapeutic combination scheme for skin and soft tissue infections (such as abscesses or NF). Fortunately, many international guidelines recommend the combination of higher-spectrum drugs such as piperacillin-tazobactam or a carbapenem, rather than a third-generation cephalosporin which may be less effective [15]. World Society of Emergency Surgery (WSES) and the Surgical Infection Society Europe (SIS-E) recommend combination antibiotic therapy with early surgical debridement (as early as possible) in cases of NF [15]. In our hospital, the empirical antibiotic therapy regimen consists of piperacillin-tazobactam, daptomycin and clindamycin. The same scheme is recommended by the WSES and SIS-E guidelines.

A crucial point in the management of the patient with NF is the timing of surgical source control. Early surgical debridement with complete removal of necrotic tissue is essential to decrease mortality and other complications: probably, it is the most important determinant of outcome in necrotizing infections. WSES and SIS-E recommend providing surgical source control as early as possible, but at least within the first 12 h after admission. In the study of Bilton *et al.*, patients with NF who had adequate surgical debridement (early and complete), were compared to those with either delayed or incomplete debridement [16]. The mortality in the latter group was 38% compared to 4.2% in the group receiving early adequate surgical treatment. Delay in source control has been repeatedly associated with a higher mortality.

In 2020, Nawijn *et al.* published a meta-analysis that aimed to review the literature concerning the timing of surgery in relation to mortality and amputation in

patients with NF [17]. A total of 33 studies, with combined 2123 NF patients, were included for quantitative analysis. Mortality was significantly lower for patients with surgery within 6 h after presentation compared to when treatment was delayed more than 6 h (OR 0.43; 95% CI 0.26–0.70; 10 studies included). We believe that, in our case, the favorable evolution was determined by the combination antibiotic therapy started after hospitalization and by the early surgical intervention, performed after 8 hours from admission.

Conclusions

In conclusion, *P. denticola* is a rare cause of NF, in most cases involving the head and the neck. However, when we consider the group of IDUs, *P. denticola* should be considered as a possible cause of NF at any sites, especially if the patient has periodontal disease. This data is important, because an empirical antibiotic therapy such as ceftriaxone and clindamycin may not be effective, as emerged from the susceptibility test of our case.

Disclosure statement

No potential conflict of interest was reported by the author(s).

Funding

No funds received

Data availability statement

The data supporting this paper are not openly available due to reasons of sensitivity and are available from the corresponding author upon reasonable request. Data are in controlled access data storage at AOU 'Policlinico di Modena'.

Ethical approval

Not applicable (our Institution's ethics committee does not provide approval for case reports)

ORCID

Andrea Bedini  <http://orcid.org/0000-0002-4041-1459>

References

- [1] Wallace HA, Perera TB Necrotizing Fasciitis. In: StatPearls [Internet]. Treasure Island (FL): StatPearls Publishing; 2023 Jan. [cited 2023 Feb 21]. Available from: <https://www.ncbi.nlm.nih.gov/books/NBK430756/>
- [2] Salati SA. Necrotizing fasciitis a review. Pol Przegl Chir. 2022 Feb 23;95(2):1–8. doi: 10.5604/01.3001.0015.7676 PMID: 36805313.
- [3] Ebricht JR, Pieper B. Skin and soft tissue infections in injection drug users. Infect Dis Clin North Am. 2002 Sep;16(3):697–712. doi: 10.1016/s0891-5520(02)00017-x PMID: 12371123.
- [4] Könönen E, Fteita D, Gursoy UK, et al. *Prevotella* species as oral residents and infectious agents with potential impact on systemic conditions. 2022. J Oral Microbiol. 2022;14(1):1–24. doi: 10.1080/20002297.2022.2079814 fasc. 1eCollection 2022.
- [5] Wong CH, Khin LW, Heng KS, et al. The LRINEC (laboratory risk indicator for necrotizing fasciitis) score: a tool for distinguishing necrotizing fasciitis from other soft tissue infections. Crit Care Med. 2004;32(7):1535–1541. doi: 10.1097/01.ccm.0000129486.35458.7d
- [6] Gunaratne DA, Tseros EA, Hasan Z, et al. Cervical necrotizing fasciitis: systematic review and analysis of 1235 reported cases from the literature. Head & Neck. 2018;2094–2102. doi: 10.1002/hed.25184 40 9
- [7] Fihman V, Raskine L, Petitpas F, et al. Cervical necrotizing fasciitis: 8-years' experience of microbiology. 2008;27(8):691–695. doi: 10.1007/s10096-008-0491-9
- [8] Kuzaka B, et al. Fournier's gangrene: clinical presentation of 13 cases. Med Sci Monit. 2018;24:548–555. doi: 10.12659/MSM.905836
- [9] Sagristà M, Martín-Ezquerria G, Gallardo F, et al. Inguinal syndrome secondary to *Prevotella bivia* after accidental bite in orogenital sex. Sex Transm Infect. 2012 Jun;88(4):250–251. doi: 10.1136/sextrans-2011-050348
- [10] Brook I, Frazier EH. Microbiology of liver and spleen abscesses. J Med Microbiol. 1998;47(12):1.075–.1.080. doi: 10.1099/00222615-47-12-1075
- [11] Ling J, Hirase T. Necrotizing Fasciitis Due to *Prevotella denticola* Infection in an Intravenous Drug User. Cureus. 2022;14(1):e20901. doi: 10.7759/cureus.20901
- [12] Dominguez-Castellano A, Ángel Muniain M, José Ríos-Villegas M, et al. Endocarditis tricuspidé por *Prevotella denticola* en un consumidor de drogas por vía parenteral. Enferm Infec Microbiol Clin. 2001;19(6):280–281. doi: 10.1016/s0213-005x(01)72639-0
- [13] Summanen PH, Talan DA, Strong C, et al. Bacteriology of skin and soft-tissue infections: comparison of infections in intravenous drug users and individuals with no history of intravenous drug use. Clin Infect Dis. 1995;20(Supplement_2):S279–282. doi: 10.1093/clinids/20.supplement_2.s279
- [14] Shilnikova II, Dmitrieva NV. Evaluation of antibiotic susceptibility of bacteroides, *Prevotella* and fusobacterium species isolated from patients of the N. N. Blokhin cancer research center, Moscow, Russia. Anaerobe. 2015;31:15–18. doi: 10.1016/j.anaerobe.2014.08.003
- [15] Sartelli M, Guirao X, Hardcastle TC, et al. WSES/SIS-E consensus conference: recommendations for the management of skin and soft-tissue infections. World J Emerg Surg. 2018;13(1):58. doi: 10.1186/s13017-018-0219-9
- [16] Bilton BD, Zibari GB, McMillan RW, et al. Aggressive surgical management of necrotizing fasciitis serves to decrease mortality: a retrospective study. Am Surg. 1998;64(5): 397–400.
- [17] Nawijn F, Smeeing DPJ, Houwert RM, et al. Time is of the essence when treating necrotizing soft tissue infections: a systematic review and meta-analysis. World J Emerg Surg. 2020;15(4):1–11. doi: 10.1186/s13017-019-0286-6 eCollection 2020.