

Severe Hypophosphatemia-Induced Acute Toxic-Metabolic Encephalopathy in Continuous Renal Replacement Therapy

Sun Ae Han, Ha Yeol Park, Hyun Woo Kim, Jong In Choi, Da Yeong Kang, Hyun Lee Kim, Jong Hoon Chung, Byung Chul Shin

Department of Internal Medicine, Chosun University Medical School, Gwangju, Korea

Received: November 21, 2019

Revised: December 2, 2019

Accepted: December 9, 2019

Corresponding Author: Byung Chul Shin, MD, PhD
Department of Internal Medicine, Chosun University Hospital, Chosun University Medical School, 365 Pilmun-daero Dong-gu, Gwangju 61453, Korea
Tel: +82-62-220-3967
Fax: +82-62-234-9653
E-mail: bcshin@chosun.ac.kr

Acute toxic-metabolic encephalopathy (TME) is an acute condition of global cerebral dysfunction in the absence of primary structural brain disease. Severe hypophosphatemia leads to muscle weakness and involves the diaphragm but hypophosphatemia-induced TME is very rare. Herein, we report the case of a 43-year-old woman with encephalopathy with severe hypophosphatemia during continuous renal replacement therapy. She presented with features of oliguric acute kidney injury on diabetic kidney disease due to volume depletion. At admission, her mental status was alert but gradually changed to stupor mentation during continuous renal replacement therapy. Her phosphate level was less than 0.41 mEq/L and Glasgow coma scale decreased from 15 to 5. After phosphate intravenous replacement and administration of phosphate-containing replacement solution, the phosphate level increased to 2.97 mEq/L and mental state returned to alert state. This case demonstrates that the level of phosphorus should be observed during continuous renal replacement therapy.

Key Words: Hypophosphatemia, Encephalopathy, Continuous renal replacement therapy

This is an Open Access article distributed under the terms of the Creative Commons Attribution Non-Commercial License (<https://creativecommons.org/licenses/by-nc/4.0/>) which permits unrestricted non-commercial use, distribution, and reproduction in any medium, provided the original work is properly cited.

Introduction

Acute toxic-encephalopathy (TME), which includes delirium and confusion, is an acute condition of global cerebral dysfunction in the absence of primary structural brain disease¹. TME is common among critically ill patients and usually a consequence of systemic illness². The electrolyte abnormalities that lead to encephalopathy include hypocalcemia or hypercalcemia, hypomagnesemia, and hypophosphatemia^{3,4}. Possibly, hypophosphatemia occurs in 10-60% of patients receiving acute renal replacement therapy (RRT), especially continuous or prolonged therapy^{5,6}. Moderate or severe hypophosphate-

mia has been recognized as a cause of respiratory muscle weakness⁷. Herein, we report the case of a 43-year-old woman who developed severe hypophosphatemia-induced acute TME during continuous RRT.

Case Report

A 43-year-old woman visited the emergency room for oliguria. She was followed up in the hospital for type I diabetes mellitus, chronic kidney disease due to diabetic nephropathy, hypertension and heart failure with dilated cardiomyopathy. She had a history of volume depletion due to diarrhea and a decrease in urine volume. At the time of arrival, level of consciousness was drowsy and the

Glasgow coma scale was 14. Physical examination revealed dehydration, including decrease in skin turgor, and tongue dehydration. The vital signs were blood pressure 110/60 mmHg, pulse rate 104 beats/min, respiratory rate 20 breaths/min, and body temperature 36.2°C. In the chest auscultation the cardiac sound was normal without murmur and the breath sound was normal. Abdominal examination revealed no specific findings such as tenderness, and no pitting edema was observed in the lower extremities. Complete blood cell count examination revealed hemoglobin 8.3 g/dL; hematocrit 27.7%; WBC 12,070/mm³; and platelet count 195,000/mm³. The initial laboratory values were: serum sodium 134 mEq/L; potassium 4.2 mEq/L; calcium 8.71 mg/dL; phosphorus 4.28 mg/dL; magnesium 1.89 mg/dL; serum urea nitrogen 46.7 mg/dL; creatinine 6.86 mg/dL; albumin 2.49 g/dL; total bilirubin 0.12 mg/dL; AST/ALT 6.7/3.8 IU/L; glucose 235 mg/dL; lactic acid 8.21 mg/dL; alkaline phosphatase 68 IU/L; NGAL 739 ng/mL; ammonia 77 ug/dL; Pro-BNP >35,000 pg/mL; and CRP 3.95 mg/dL. Arterial blood gas analysis revealed pH 7.14; pCO₂ 24 mmHg; pO₂ 121 mmHg, and tCO₂ 8.3 mL/dL. The serum IgA was 109 mg/dL; ASO 32 U; C3 92 mg/dL; C4 35 mg/dL; FANA negative; and ANCA negative. In the urine analysis, the specific gravity of urine was 1.007; pH 5.0; urine protein 2+; blood 3+; RBC 1-4/HPF; and WBC 5-9/HPF. Urine creatinine level was 14.9 mg/dL, and urine protein was 6.78 mg/dL. In the immune serum test, the HBs Ag/Ab, Anti-HCV Ab, Anti-HIV Ab, and VDRL results were all negative. Due to persistence of oliguria, continuous RRT was started. On the ninth hospital day, her mentation changed from alert to stupor mentation. The Glasgow coma scale (GCS) changed from 15 to 5. Brain images showed normal findings (Fig. 1). The following laboratory values were obtained: serum sodium 138 mEq/L; potassium 4.5 mEq/L; calcium 8.26 mg/dL; phosphorus <0.41 mg/dL; magnesium 1.96 mg/dL; serum urea nitrogen 21.4 mg/dL; creatinine 1.45 mg/dL; albumin 2.32 g/dL; glucose 209 mg/dL; and CRP 2.75 mg/dL. After phosphate intravenous replacement, 0.25-0.5 mmol/kg monobasic potassium phosphate (Phosten, JW, Korea) for 6 days, and administration of phosphate-containing replacement solution Phoxilium (containing phosphate at 1.2 mmol/L; Baxter Gambro, Deerfield, IL, USA) use, the pho-

sphate level increased to 2.97 mEq/L and mental state returned to alert (Fig. 2). On the 29th day of continuous RRT, normal urine volume was recovered with decrease in serum creatinine level. On the 33rd day, serum creatinine level decreased to 2.08 mg/dL, subsequently RRT was stopped. At the time of discharge, serum creatinine and phosphorus level were 1.82 mg/dL and 2.75 mg/dL, respectively with alert mentation. The patient is still on outpatient follow-up.

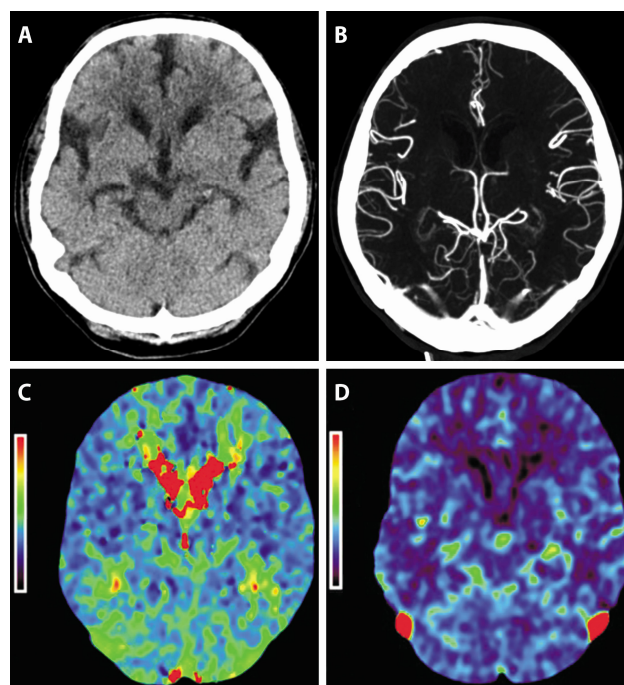


Fig. 1. Brain and neck perfusion CT scan. There were no significant abnormal findings including recent infarction or intracranial hemorrhage, or steno-occlusive lesion (A: non-enhanced CT, B: CT angiography, C, D: perfusion CT angiography).

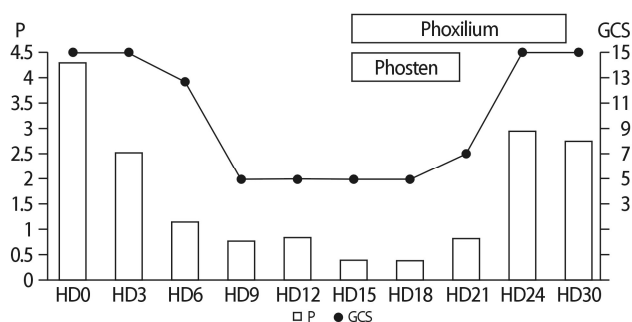


Fig. 2. Serum phosphorus level and Glasgow coma scale follow up. GCS, Glasgow coma scale; P, serum phosphorus level (mEq/L); HD, hospital day.

Discussion

In the present case, severe hypophosphatemia-induced acute TME with oliguric acute kidney injury developed in a patient during continuous RRT. On the day of her hospital arrival, her mental status was alert with normal serum phosphate levels. On the ninth hospital day, her mentation changed from alert to stupor mentation with decrease in serum phosphate level during continuous CRRT. After phosphate intravenous replacement and administration of phosphate-containing replacement solution, her mental state returned to alert with normal serum phosphate level. Brain images and other studies showed normal findings. Based on these findings, severe hypophosphatemia-induced acute TME was diagnosed.

Continuous renal replacement therapy (CRRT) plays a crucial role in critically ill patients with acute kidney injury, particularly those with hemodynamic instability⁸⁾. However, CRRT is associated with a risk of electrolyte imbalances, including hypophosphatemia, acid-base imbalances, hypotension, infection, bleeding and hypothermia^{9,10)}. The incidence of CRRT-related hypophosphatemia widely ranges from 27% to 78%^{5,6,11)}. The CRRT-related hypophosphatemia can cause respiratory muscle failure, prolonged mechanical ventilation requirements, longer hospital length of stay, and mortality^{6,11,12)}. It has been reported that mild hypophosphatemia is associated with poor outcome¹³⁾. Lim et al., reported that the risk of prolonged mechanical ventilation increased even in patients with serum phosphorus <2.9 mg/dL during CRRT¹²⁾. In the present case, hypophosphatemia occurred 6 days after CRRT was initiated and her mentation was changed from alert to stupor on 9th day (Fig. 2).

There are several studies on phosphate supplementation for the prevention of hypophosphatemia during CRRT treatment. Troyanov et al. found that addition of 1.2 mmol/L of phosphate to the dialysis fluid in adult CRRT patients¹⁴⁾. Song et al. reported a dose of 2 mmol/L of phosphate as appropriate for patients with CRRT-induced hypophosphatemia¹³⁾. Recently, commercialized phosphate-containing dialysis solutions (e.g., Phoxilium) are used for CRRT patients¹⁵⁾. In the present patient, af-

ter phosphate intravenous replacement and administration of phosphate-containing replacement solution, the phosphate level increased to 2.97 mEq/L and mental state returned to alert (Fig. 2).

In the present case, severe hypophosphatemia-induced acute TME with oliguric acute kidney injury developed during continuous RRT. Consequently, a careful workup for hypophosphatemia and appropriate phosphate supplementation should be considered in addition to renal care in continuous RRT patient.

Conflict of interest

None of the authors has conflicts of interest concerning commercial or financial involvements. None of the authors affiliated with an organization whose financial interests may be affected by material in the manuscript.

References

1. Chen R, Young GB: Metabolic Encephalopathies. In: Baillere's Clinical Neurology, Bolton CF, Young GB (Eds), Balliere Tindall, London p.577-598
2. Ely EW, Stephens RK, Jackson JC, et al.: Current opinions regarding the importance, diagnosis, and management of delirium in the intensive care unit: a survey of 912 healthcare professionals. *Crit Care Med* 32:106-112, 2004
3. Young GB, DeRubeis DA: Metabolic encephalopathies. In: Coma and Impaired Consciousness, Young GB, Ropper AH, Bolton CF (Eds), McGraw-Hill, 1998. p.307
4. Wijdicks E: Neurologic manifestations of acid base derangements, electrolyte disorders, and endocrine crises. In: Neurology of Critical Illness, Wijdicks E (Ed), FA Davis Company, Philadelphia 1995. p.104
5. Bellomo R, Cass A, Cole L, et al.: The relationship between hypophosphataemia and outcomes during low-intensity and high-intensity continuous renal replacement therapy. *Crit Care Resusc* 16:34-41, 2014
6. Yang Y, Zhang P, Cui Y, et al.: Hypophosphatemia during continuous veno-venous hemofiltration is associated with mortality in critically ill patients with acute kidney injury. *Crit Care* 17:R205, 2013
7. Gravelyn TR, Brophy N, Siegert C, et al.: Hypophosphatemia-associated respiratory muscle weakness in a general

- inpatient population. *Am J Med* 84:870-876, 1998
8. Kellum JA, Lameire N, Aspelin P, et al.: KDIGO clinical practice guideline for acute kidney injury. *Kidney Int* 2: 1-138, 2012
 9. Finkel KW, Podoll AS: Complications of continuous renal replacement therapy. *Semin Dial* 22:155-159, 2009
 10. Akhoundi A, Singh B, Vela M, et al.: Incidence of adverse events during continuous renal replacement therapy. *Blood Purif* 39:333-339, 2015
 11. Demirjian S, Teo BW, Guzman JA, et al.: Hypophosphatemia during continuous hemodialysis is associated with prolonged respiratory failure in patients with acute kidney injury. *Nephrol Dial Transplant* 26:3508-3514, 2011
 12. Lim C, Tan HK, Kaushik M: Hypophosphatemia in critically ill patients with acute kidney injury treated with hemodialysis is associated with adverse events. *Clin Kidney J* 10:341-347, 2017
 13. Song YH, Seo EH, Yoo YS, Jo YI: Phosphate supplementation for hypophosphatemia during continuous renal replacement therapy in adults. *Ren Fail* 41:72-79, 2019
 14. Troyanov S, Geadah D, Ghannoum M, et al.: Phosphate addition to hemodiafiltration solutions during continuous renal replacement therapy. *Intensive Care Med* 30:1662-1665, 2004
 15. Godaly G, Carlsson O, Broman M: Phoxilium(R) reduces hypophosphataemia and magnesium supplementation during continuous renal replacement therapy. *Clin Kidney J* 9:205-210, 2016