



Published in final edited form as:

J Clin Exp Ophthalmol. 2018 ; 9(4): . doi:10.4172/2155-9570.1000740.

Prevalence of Hepatocyte Growth Factor and Autoantibodies to α -HGF as a New Etiology for Bilateral Diffuse Uveal Melanocytic Proliferation Masquerading as Neovascular Age-Related Macular Degeneration

John H Niffenegger¹, Arysol Soltero¹, James S Niffenegger², Sufang Yang³, and Grazyna Adamus^{3,*}

¹Retina Associates of Sarasota, Sarasota, Florida, USA

²Harvard College, Cambridge, Massachusetts, USA

³Casey Eye Institute, School of Medicine, Oregon Health and Science University, Portland, Oregon, USA

Abstract

Objective: The goal was to test the hypothesis that high serum hepatocyte growth factor (HGF) and retinal autoantibodies against α -HGF contribute to the pathology of bilateral diffuse melanocytic proliferation (BDUMP).

Methods: Case report of an elderly diagnosed with neovascular age-related macular degeneration (n-AMD) treated with bilateral Bevacizumab injections. Examination included comprehensive ophthalmic examination and images obtained by fundus photography, fundus autofluorescence, fluorescein angiography, spectral-domain optical coherence tomography (OCT), and B-scan ultrasonography. The levels of HGF and circulating HGF receptor (c-MET) were measured in the serum by ELISA and anti-retinal autoantibodies by western blotting.

Results: Patient received Bevacizumab injections for presumed n-AMD and had a history of papillary renal cell carcinoma stage 4 with a tumor containing gene mutation Y1230C in the mesenchymal-epithelial transition factor (MET). Visual acuity was 20/200 OD and CF OS. Multimodal imaging was consistent with BDUMP. Plasma exchange therapy was recommended but could not be started until 10 months later due to deterioration in his medical condition. Pre- and post-plasma exchange sera demonstrated anti-retinal autoantibodies against 69-kDa protein of the same molecular weight as the α -HGF. Serum autoantibodies reacted with purified recombinant α -HGF on the blot.

Conclusions: BDUMP can mimic n-AMD, which can delay treatment. Plasma exchange resulted in resolved inflammation, resolution of exudative detachments and improved vision after

This is an open-access article distributed under the terms of the Creative Commons Attribution License, which permits unrestricted use, distribution, and reproduction in any medium, provided the original author and source are credited.

*Corresponding author: Dr. Grazyna Adamus, Casey Eye Institute, School of Medicine, Oregon Health and Science University, Portland, Oregon, USA, Tel: +1 503-418-2540; adamusg@ohsu.edu.

Conflicts of Interest

The authors have no financial or conflicts of interest to disclose.

cataract surgery. Consideration of the tumor genetics led to the recognition of elevated HGF levels and autoantibodies to α -HGF (anti-69-kDa), which suggested a new pathogenic mechanism of BDUMP. We believe that therapy with tyrosine kinase inhibitors and a checkpoint inhibitor may contribute to the high HGF levels and subsequent immune response.

Keywords

BDUMP; HGF; Autoimmunity; Cancer; Tyrosine kinase inhibitors; HGF receptor (c-MET)

Introduction

BDUMP is a rare paraneoplastic condition [1] with increasing incidence that may masquerade as n-AMD, resulting in delayed diagnosis and treatment. Autoimmune response is highly likely and a serum factor in BDUMP patients has been shown to induce cultured melanocyte elongation and proliferation [2,3]. Multimodal imaging facilitated the diagnosis. In our study, consideration of tumor genetics led us to evaluate serum retinal autoantibodies and levels of HGF and c-MET before and after treatment with plasma exchange.

Report of a Case

A 74-year-old elderly white man complaining of blindness, photophobia and scotomas presented to Retina Associates of Sarasota one month after bevacizumab injection in each eye. Twenty-six months earlier a robotic right partial nephrectomy was performed. Ten months after procedure, CT scanning and biopsy demonstrated Stage 4 papillary renal carcinoma with a MET gene mutation Y1230C. Initially, the patient was treated with tyrosine kinase inhibitors (Pazopanib and later Sorafenib), and then due to side effects, he was switched to an anti-PD-1 antibody check point inhibitor (Nivolumab). Two months later, he was diagnosed with n-AMD and given a Bevacizumab injection in each eye. Nivolumab was discontinued after four months due to side effects and Axitinib (a tyrosine kinase inhibitor) was initiated, and the patient has continued on this medication.

At presentation, vision was 20/200 OD and CF OS. Intraocular pressure was low (8 mmHg OD and 6 mmHg OS). The anterior segment had dilated episcleral vessels but no abnormal pigmentation in either eye. The corneas were clear and the anterior chambers were deep and quiet. The irises were normal and there were no nevi or masses. The lenses had moderate nuclear sclerosis. Both eyes had a posterior vitreous detachment but no vitreous cells. The fundus examination in each eye demonstrated multiple nevi and many round reddish patches with sub-retinal fluid in the macula and shifting exudative retinal detachments in the inferior periphery OU. Color fundus photography revealed multiple pigmented nevi OU and round reddish islands of retinal pigment epithelium (RPE) separated by a pattern of polygonal orange pigmentation (Figures 1A and 1B). Fundus autofluorescence (30° Heidelberg Retinal Angiograph; Heidelberg Engineering) demonstrated increased levels of autofluorescence corresponding to the orange polygonal lesions and decreased levels of expected RPE autofluorescence, corresponding to the round areas of presumed RPE atrophy (Figures 1C and 1D). These round lesions appeared dark on the near infrared images (Figures 1E and 1F). Spectral domain optical coherence tomography (OCT) demonstrated macular neurosensory

detachment with focal areas of RPE atrophy and hypertrophy OU (Figures 1G and 1H). In addition to the highly reflective choroidal nevi, thickened choroid OU was noted on the enhanced depth imaging OCT (EDI-OCT) (Figures 1G and 1H). Fluorescein angiography demonstrated transmission defects corresponding to areas of RPE atrophy, blocking corresponding to orange polygonal areas and nevi, and scattered speckled and peripapillary punctate areas of hyperfluorescence. B-scan ultrasonography confirmed the presence of thickened choroid and exudative retinal detachments OU.

BDUMP was diagnosed based on the history, ophthalmic examination and multimodal imaging. Plasma exchange was recommended but could not be started until ten months later due to deterioration in his medical condition. The highest HGF levels were present in pre-plasma exchange at 1990 pg/ml and then lowered after plasma exchange (681 pg/ml), and in final post-plasma exchange dropped to 452 pg/ml. No circulating HGF receptor (c-MET) was detected. Pre- and post-plasma exchange fluid demonstrated anti-retinal autoantibodies against 69-kDa protein of the same molecular weight as α -HGF. Serum autoantibodies were found to react with a purified recombinant α -HGF on the blot. Plasma exchange resulted in reduced inflammation, resolution of exudative detachments and improvement in vision after cataract surgery. Multimodal imaging demonstrated the progression of RPE atrophy (Figures 2A and 2B), nevi growth (Figures 2C and 2D), resolution of neurosensory detachments (Figures 2E and 2F) and stable choroidal thickening on EDI-OCT (Figures 2G and 2H). Nineteen months after presentation (5 months after finishing plasma exchange), visual acuity was 20/40+2 OD and 20/50+2 OS.

Discussion

BDUMP is a rare ocular paraneoplastic syndrome that may masquerade as n-AMD, resulting in delayed diagnosis and treatment [4]. The observation that approximately 40% of BDUMP cases occur prior to the diagnosis of the primary cancer and that BDUMP patients often present with advanced cancer suggests the potential for autoimmunity to contribute both to the survival and to the paraneoplastic process [4]. The etiology of the syndrome is not understood. Plasma exchange improves the signs and symptoms of BDUMP [5]. Recent studies showed that the plasma IgG fraction caused melanocyte elongation and migration [2]. However, a specific factor that could contribute to pathology of the syndrome has not been identified [3]. We believe that our study further elucidates a possible mechanism of BDUMP, by showing high levels of α -HGF combined with likely autoantibody response to the α -HGF (69-kDa).

An array of seemingly unrelated tumors can rarely be associated with BDMUP, including ovarian, lung, gallbladder, cervical, uterine, kidney, pancreatic, breast, esophageal/gastric and colorectal cancer [6]. All of these tumors have been found to have concomitant elevation of serum HGF in some patients and HGF can be delivered from remote tissues through the circulation [7]. Excepting pancreatic, these cancers have been known to rarely have MET gene mutations. Although pancreatic cancer remains the exception, MET gene dysregulation and elevated HGF levels have been found to lead to poor prognosis in pancreatic cancer [8]. Non-small cell lung cancer has been known to have the Y1230C mutation at a very low frequency (mutant allele frequency=0.3%).

Consideration of our patient's papillary renal-cell carcinoma tumor activating missense mutation (Y1230C) in the tyrosine kinase domain of the MET gene [9] led to the hypothesis that BDUMP is caused by retinal autoantibodies to α -HGF. The MET gene encodes the receptor for HGF (c-MET). HGF is made of a 69-kDa α -chain and a 34-kDa β -chain. Previous 2 reports of circulating anti-retinal autoantibodies in BDUMP patients were positive for recoverin (23-kDa) and a 70-kDa protein thought to be Heat Shock Protein (HSP70) in one case, and 33-kDa and 34-kDa in the second case [5,10]. We found elevated level of α -HGF in our patient and identified α -HGF as the retinal protein reacting with the anti-69-kDa retinal autoantibodies present in the serum.

It is possible that chronic high levels of HGF in combination with retinal autoantibodies may drive the choroidal nevi growth and RPE damage seen in BDUMP. In donor eyes, the RPE layer is the most positive site for c-MET (HGF receptor) expression [11] HGF stimulation of melanocytes up-regulates c-MET expression [12], promotes melanocyte proliferation and motility [13], stimulates RPE proliferation and migration during wound healing [14] and, in proliferative vitreoretinopathy models, induces RPE separation and dedifferentiation [15]. High serum levels of HGF have been associated with metastasis and reduced survival in cancer patients [8].

The reason for the doubling in incidence of BDUMP over the past decade is unclear. In addition to increased awareness, an improved identification with multimodal imaging, longer patient survival, and new therapies may contribute to increase incidence. Tyrosine kinase inhibitors can increase HGF levels [16]. Checkpoint inhibitors, such as Nivolumab, have been associated with ocular immune dysfunction manifesting as Vogt-Koyanagi-Harada-like choroidal thickening, choroidal effusions and keratitis [17–19]. In conclusion, our study show for the first time that BDUMP was associated with high levels of HGF as well as anti-retinal autoantibodies against α -HGF (69-kDa). Therapy with a tyrosine kinase inhibitor (Pazopanib, Sorafenib, Axitinib) and a checkpoint inhibitor (Nivolumab) may contribute to the high HGF levels and the immune response. These results suggest a new etiology related to high levels of HGF combined with an autoimmune response to the α -HGF (69-kDa) in the pathogenesis of BDUMP.

Acknowledgements

This work was supported by grant P30 EY010572 from the National Institutes of Health (Bethesda, MD) and by unrestricted departmental funding to CEI from Research to Prevent Blindness (New York, NY).

References

1. Gass JD, Gieser RG, Wilkinson CP, Beahm DE, Pautler SE (1990) Bilateral diffuse uveal melanocytic proliferation in patients with occult carcinoma. *Arch Ophthalmol* 108: 527–533. [PubMed: 2322154]
2. Miles SL, Niles RM, Pittock S, Vile R, Davies J, et al. (2012) A factor found in the IgG fraction of serum of patients with paraneoplastic bilateral diffuse uveal melanocytic proliferation causes proliferation of cultured human melanocytes. *Retina* 32: 1959–1966. [PubMed: 22791177]
3. Jansen JC, Van Calster J, Pulido JS, Miles SL, Vile RG, et al. (2015) Early diagnosis and successful treatment of paraneoplastic melanocytic proliferation. *Br J Ophthalmol* 99: 943–948. [PubMed: 25908835]

4. Klemp K, Kiilgaard JF, Heegaard S, Norgaard T, Andersen MK, et al. (2017) Bilateral diffuse uveal melanocytic proliferation: Case report and literature review. *Acta Ophthalmol* 95: 439–445. [PubMed: 28636126]
5. Mets RB, Golchet P, Adamus G, Anitori R, Wilson D, et al. (2011) Bilateral Diffuse Uveal Melanocytic Proliferation With a Positive Ophthalmoscopic and Visual Response to Plasmapheresis. *Arch Ophthalmol* 129: 1235–1238. [PubMed: 21911680]
6. O’Neal KD, Butnor KJ, Perkinson KR, Proia AD (2003) Bilateral diffuse uveal melanocytic proliferation associated with pancreatic carcinoma: a case report and literature review of this paraneoplastic syndrome. *Sur Ophthalmol* 48: 613–625.
7. Kwon Y, Smith BD, Zhou Y, Kaufman MD, Godwin AK (2015) Effective Inhibition of c-MET-mediated Signaling, Growth, and Migration of Ovarian Cancer Cells is Influenced by the Ovarian Tissue Microenvironment. *Oncogene* 34: 144–153. [PubMed: 24362531]
8. Matsumoto K, Umitsu M, De Silva DM, Roy A, Bottaro DP (2017) Hepatocyte growth factor/MET in cancer progression and biomarker discovery. *Cancer Sci* 108: 296–307. [PubMed: 28064454]
9. Linehan WM, Spellman PT, Ricketts CJ, Creighton CJ, Fei SS, et al. (2016) Comprehensive Molecular Characterization of Papillary Renal Cell Carcinoma. *N Eng J Med* 374: 135–145.
10. Saito W, Kase S, Yoshida K, Ohguro H, Yokoi M, et al. (2005) Bilateral Diffuse Uveal Melanocytic Proliferation in a Patient With Cancer-Associated Retinopathy. *Am J Ophthalmol* 140: 942–945. [PubMed: 16310487]
11. Lashkari K, Hirose T, Yazdany J, McMeel JW, Kazlauskas A, et al. (2000) Vascular endothelial growth factor and hepatocyte growth factor levels are differentially elevated in patients with advanced retinopathy of prematurity. *Am J Pathol* 156: 1337–1344. [PubMed: 10751359]
12. McGill GG, Haq R, Nishimura EK, Fisher DE (2006) c-Met Expression Is Regulated by Mitf in the Melanocyte Lineage. *J Biol Chem* 281: 10365–10373. [PubMed: 16455654]
13. Kos L, Aronzon A, Takayama H, Maina F, Ponzetto C, et al. (1999) Hepatocyte Growth Factor/Scatter Factor-MET Signaling in Neural Crest-Derived Melanocyte Development. *Pigment Cell Res* 12: 13–21. [PubMed: 10193678]
14. Miura Y, Yanagihara N, Imamura H, Kaida M, Moriwaki M, et al. (2003) Hepatocyte growth factor stimulates proliferation and migration during wound healing of retinal pigment epithelial cells in vitro. *Jpn J Ophthalmol* 47: 268–275. [PubMed: 12782163]
15. Hinton DR, He S, Jin ML, Barron E, Ryan SJ (2002) Novel growth factors involved in the pathogenesis of proliferative vitreoretinopathy. *Eye* 16: 422. [PubMed: 12101449]
16. Organ SL, Tsao MS (2011) An overview of the c-MET signaling pathway. *Ther Adv Med Oncol* 3: S7–S19. [PubMed: 22128289]
17. Matsuo T, Yamasaki O (2017) Vogt-Koyanagi-Harada disease-like posterior uveitis in the course of nivolumab (anti-PD-1 antibody), interposed by vemurafenib (BRAF inhibitor), for metastatic cutaneous malignant melanoma. *Clin Case Rep* 5: 694–700. [PubMed: 28469878]
18. Thomas M, Armenti ST, Ayres M, Demirci H (2018) Uveal effusion after immune checkpoint inhibitor therapy. *JAMA Ophthalmol* 136: 553–556. [PubMed: 29677240]
19. Baughman DM, Lee CS, Snysman BE, Jung HC (2017) Bilateral Uveitis and Keratitis Following Nivolumab Treatment for Metastatic Melanoma. *Med case rep* 3: 8.

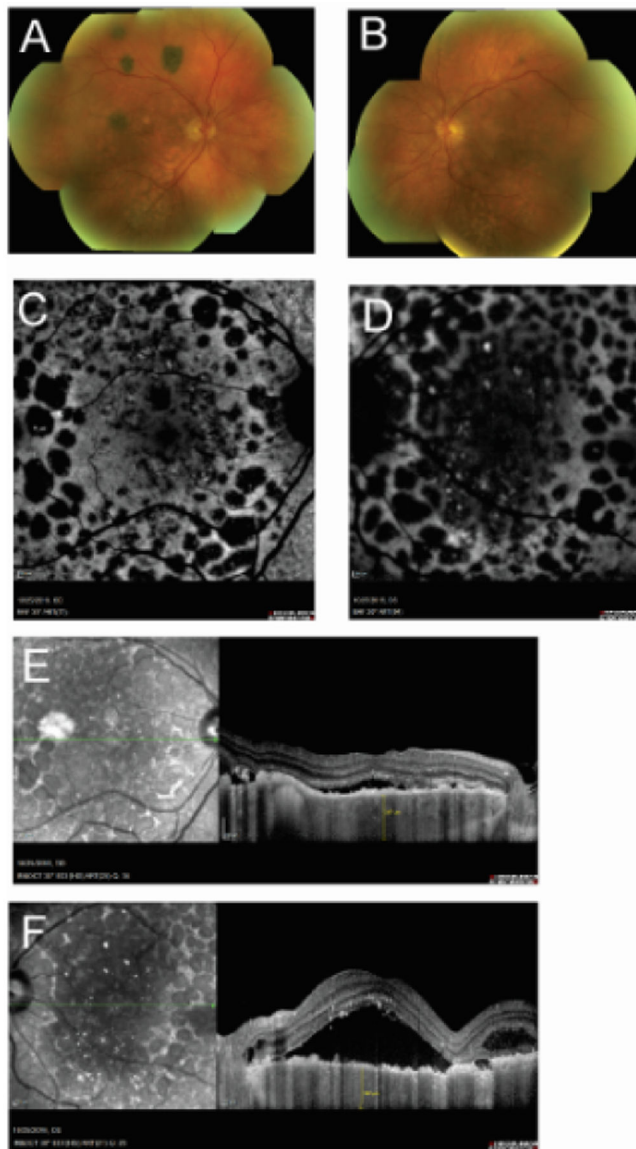


Figure 1:

Multimodal Imaging of the Retina Prior to Plasma Exchange A and B, Color fundus montage of the right (A) and left (B) eye showing showing multiple nevi, orange polygonal pigment and round reddish lesions. C and D: fundus autofluorescence (30° Heidelberg Retinal Angiograph; Heidelberg Engineering) demonstrating increased autofluorescence corresponding to the polygonal pigment and absence of autofluorescence corresponding to the round areas of presumed RPE atrophy. E and F: near infrared images showing the dark round lesions corresponding to presumed RPE atrophy and a bright lesion in the right eye corresponding to a choroidal nevus. G and H: spectral domain (OCT) demonstrated macular neurosensory detachment with focal areas of RPE atrophy and hypertrophy, and a highly reflective choroidal nevus in the right eye; enhanced depth imaging optical coherence tomography (EDI-OCT) demonstrated thickened choroid in both eyes.

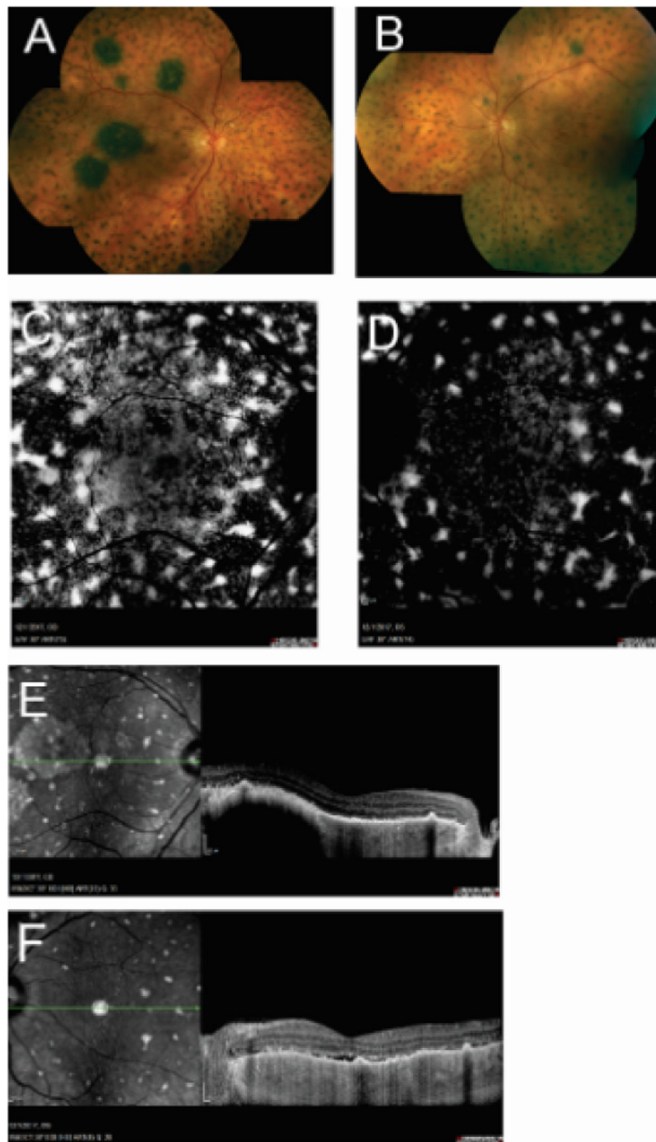


Figure 2: Multimodal imaging of the retina after plasma exchange A and B, Color fundus of the right (A) and left (B) eye showing showing enlarged multiple nevi, contracted orange polygonal pigment and increased pigment clumping. C and D: fundus autofluorescence (30° Heidelberg Retinal Angiograph; Heidelberg Engineering) demonstrating increased autofluorescence corresponding to the polygonal pigment and increased absence of autofluorescence corresponding to presumed RPE atrophy. E and F: near infrared images showing loss of the dark round lesions and enlarged bright lesion in the right eye corresponding to a choroidal nevus. G and H: spectral domain (OCT) demonstrated resolved macular neurosensory detachment with focal areas of RPE atrophy and hypertrophy, and an enlarged choroidal nevus in the right eye; enhanced depth imaging optical coherence tomography (EDI-OCT) demonstrated stable thickened choroid in both eyes.