




Editorial

Hemophagocytic Lymphohistiocytosis (HLH): A Rare Cause of Primary Engraftment Failure Post Autologous Stem Cell Transplant

Pallavi Mehta¹ Aakanksha Singh¹ Rohan Halder¹ Ankit Jain¹ Narendra Agrawal¹ Rayaz Ahmed¹
Dinesh Bhurani¹¹ Department of Hemato-Oncology and Bone Marrow Transplant Unit, Rajiv Gandhi Cancer Institute & Research Centre, Delhi, India

South Asian J Cancer 2023;12(3):229–232.

Introduction

Hemophagocytic lymphohistiocytosis (HLH) is a devastating disorder of uncontrolled immune activation characterized by clinical and laboratory evidence of extreme inflammation, occurring either as a familial or a secondary HLH, which is acquired in association with a variety of pathological states.¹ In recent years, HLH has attracted growing attention due to an inexplicable rise in the interest of physicians in recognizing and reporting the disorder. Clinical features may vary from a typical presentation with fever, cytopenia, hepatosplenomegaly to atypical complications such as rash, hepatitis or acute liver failure, coagulopathy, and central nervous system (CNS) involvement, which manifest as an altered mental status, seizures, and focal deficits.² Unfortunately, the diagnosis of HLH is often delayed due to the intricacies of the established diagnostic criteria¹ of this deadly disease, which leads to irony as HLH needs a very fast and accurate diagnosis to prevent mortality. It is also worthy to be aware of the fact that diagnosis of HLH does not fundamentally depend upon morphological findings of hemophagocytosis as it can be absent in the early stages of the disease. Hence, it would be wise to perform serial bone marrow aspirations later in the course of the disease if the clinical suspicion is very high.³

HLH post stem cell transplant, either autologous or allogeneic, is a very rare complication, which involves the complexities of the diagnosis due to various confounding factors commonly encountered in the peri-transplant period. In addition to that, it is a known fact that it is associated with high mortality.⁴ A separate set of criteria for HLH after SCT has been proposed requires two major criteria, or one major and all four minor criteria. The major criteria are¹ engraftment failure, delayed engraftment or secondary

engraftment failure after SCT, and² histopathological evidence of hemophagocytosis. The four minor criteria are high-grade fever, hepatosplenomegaly, elevated ferritin, and elevated serum LDH.⁵ A prospective observational study on 171 post stem cell transplantation (68 allogeneic and 103 autologous) showed 6 cases of secondary HLH in allogeneic transplants, whereas only 1 case was reported in autologous transplant cases which clearly highlights the rarity of this complication.⁶ We hereby present the case of a young male recipient of an autologous stem cell transplant for his primary disease of diffuse large B cell lymphoma, leading to primary graft failure secondary to HLH.

Case Presentation

We describe the case of a 50-year-old male patient, who was diagnosed with diffuse large B cell lymphoma (DLBCL)-non-germinal center type Stage IV in April 2019, received 6 cycles of RCHOP that showed good response to treatment on PET scan at the end of the therapy. The patient presented again in February 2021 with progressively enlarging cervical lymph nodes. PET CT confirmed the progression of the disease. Bone marrow was not involved. At relapse, the disease was in stage IV as supradiaphragmatic and infra diaphragmatic nodes were involved along with the liver. He was salvaged with 4 cycles of RDHAP with which he could achieve a partial response. The patient was taken for an autologous transplant for further disease control. He received BEAM conditioning regimen at the doses: carmustine @ 300 mg/sqm on day-6, cytarabine @200 mg/sqm on day-5 to -2, etoposide @ 200 mg/sqm on day-5 to -2, melphalan @ 120 mg/sqm on day-1 followed by infusion of autologous stem cells (G-CSF and

Address for correspondence

Pallavi Mehta, MD, DM (Clinical Hematology), Hematology and Bone Marrow Transplant Unit, Rajiv Gandhi Cancer Institute and Research Centre, Sector 5, Rohini, New Delhi 110085, India (e-mail: dr_pallavimehta@yahoo.co.in).

DOI <https://doi.org/>

10.1055/s-0042-1748183.

ISSN 2278-330X.

© 2023. MedIntel Services Pvt Ltd. All rights reserved.

This is an open access article published by Thieme under the terms of the Creative Commons Attribution-NonDerivative-NonCommercial-License, permitting copying and reproduction so long as the original work is given appropriate credit. Contents may not be used for commercial purposes, or adapted, remixed, transformed or built upon. (<https://creativecommons.org/licenses/by-nc-nd/4.0/>)

Thieme Medical and Scientific Publishers Pvt. Ltd., A-12, 2nd Floor, Sector 2, Noida-201301 UP, India

plerixafor mobilized) at dose of $5.1 \times 10^6/\text{kg}$ on day 0. On day +4, the patient developed oral and abdominal mucositis grade III. Subsequently, on day +6, he also had a septicemic shock and required antibiotics along with inotropic support. Growth factor support was continued since day +1. In view of the deterioration in his clinical condition, granulocyte infusions were also given. Initially around day +16, the patient had a favorable evolution of the white blood cell count reaching $200/\text{mm}^3$ on day +18 only to start falling off again on day +21 (to $90/\text{mm}^3$). He remained to be febrile throughout the course and hence workup for secondary HLH was initiated. Although the bone marrow was hypocellular with <5% cellularity with occasional hemophagocytosis (–Fig. 1), other parameters such as engraftment failure, high-grade fever, elevated ferritin (3,660 ng/mL) were fulfilling the criteria of post-transplant secondary HLH as defined by Takagi et al in post-HSCT setting, which requires either both major criteria (first major criterion comprises engraftment failure, delayed engraftment, or secondary engraftment failure after HSCT and the second is histopathological evidence of hemophagocytosis), or one major and all four minor criteria (high-grade fever, hepatosplenomegaly, elevated ferritin, and elevated serum lactate dehydrogenase).⁵ With triglyceride levels of 362 mg/dL, fibrinogen 565 mg/dL, and procalcitonin 1.0 ng/mL, his H score was 253. Elevated

serum IL2R levels (26,638 pg/mL, normal range: 1,555–10,800 pg/mL) consolidated our diagnosis of HLH, before starting steroids. Viral PCRs for CMV, EBV, and respiratory viruses were done to rule out infections related to HLH; however, all were negative. He was initiated on dexamethasone on day +24 along with IvIg (immunoglobulin) @ 1 mg/kg/day for 2 days. Later on, cyclosporine was also added on day +25. On day +27, an increasing trend in WBC was observed. On day +29, neutrophil engraftment was achieved ($\text{ANC} > 500/\text{mm}^3$). The steroid was started to be tapered off thereafter and was stopped as the patient developed *Pseudomonas* bacteremia. The patient could not tolerate cyclosporine due to raised creatinine and hyperkalemia, and hence it was stopped on day +40. His platelet count continued to be low and required repeated transfusions. Bone marrow aspiration and biopsy were repeated on day +41, which revealed occasional histiocytosis although the cellularity was still low (<5% cellularity) (–Fig. 2). In view of persistent severe thrombocytopenia, immunoglobulin (Ig) administration was repeated every 3 weeks. However, IgG levels were not checked before every dose of Ig administration. At the time of writing this report, the patient continued to have a low-grade fever with no localizing focus for infection. He has been continued on eltrombopag (thrombopoietin receptor agonist) since day

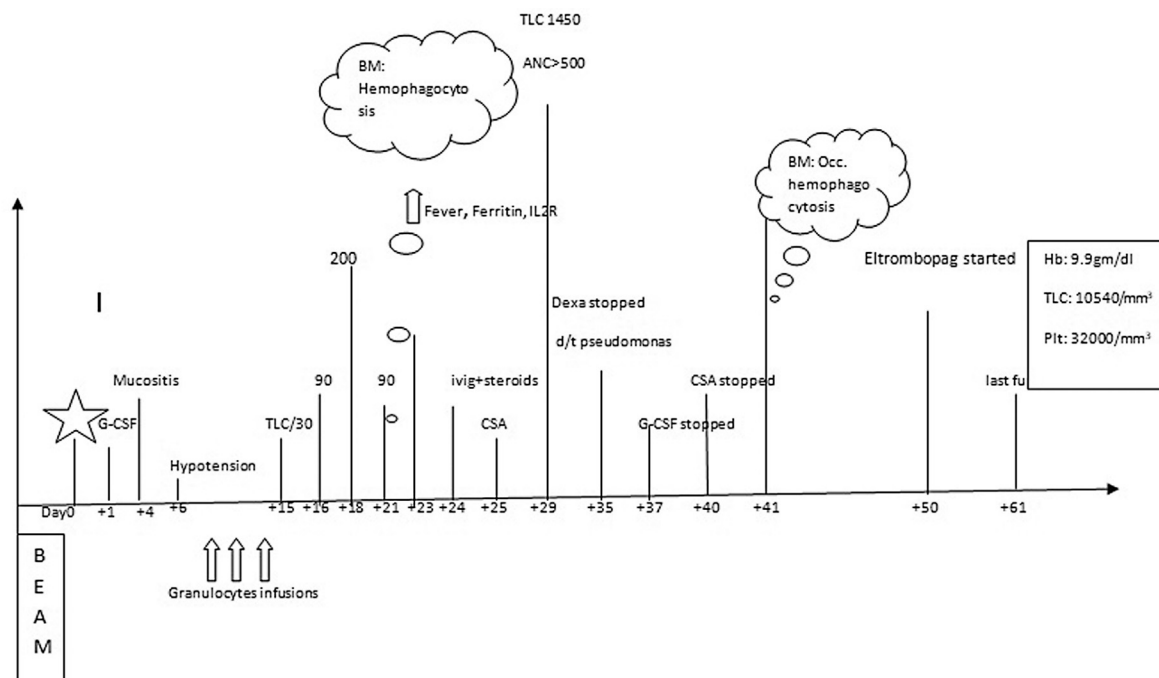


Fig. 1 This figure depicts the clinical course of the patient post autologous until the last follow-up (duration between the days is not according to the scale). The patient received BEAM (carmustine/etoposide/cytarabine/melphalan) conditioning regimen. Day 0 represents the days of autologous transplant (CD34 dose was $5.1 \times 10^6/\text{kg}$). From day +1, G-CSF was started as a part of the protocol. On day +4, mucositis started followed by hypotension on day +6. He was managed with antibiotic support along with granulocyte infusions. TLC started rising gradually until day +18 only to have a failing trend again by day +21. On day +23, bone marrow examination showed hemophagocytosis. The patient received IvIg (immunoglobulin) and steroid from day +24. Cyclosporine was added on day +25. TLC started rising by day +29 ($\text{ANC} > 500/\text{mm}^3$). On day +35, the steroid was stopped due to *Pseudomonas* bacteremia. By day +37, G-CSF was also stopped on day +41 due to a rise in creatinine and persistent hyperkalemia. Repeat bone marrow examination on day +41 showed occasional hemophagocytic cells. In view of persistent thrombocytopenia, eltrombopag was added on day +50. On the last follow-up (day +61), the patient had TLC $10,540/\text{mm}^3$ and platelets $32,000/\text{mm}^3$ without transfusion support.

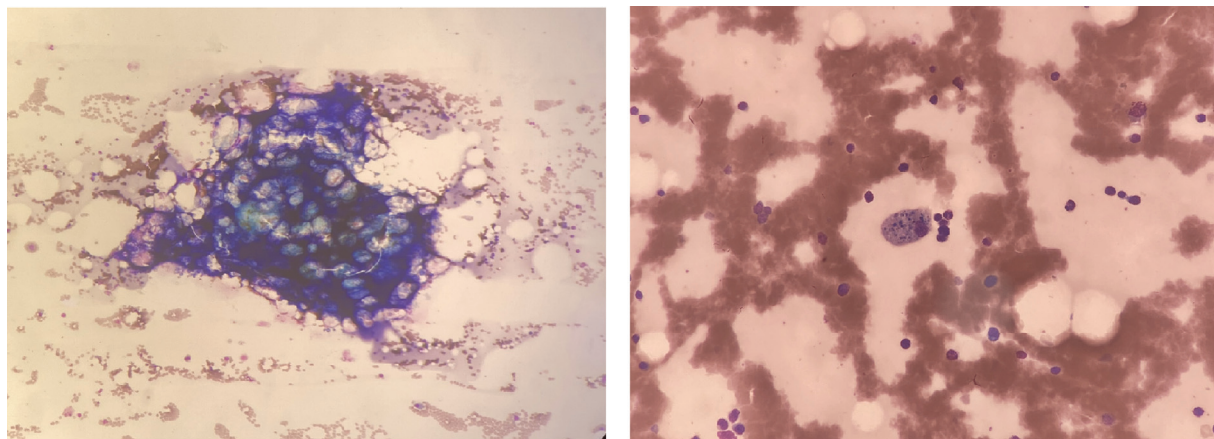


Fig. 2 Progressive improvement in cellularity, with few histiocytes showing iron pigment deposition in the cytoplasm.

+50 for the platelet engraftment until his last follow-up day (day +61) (→ Fig. 1).

Discussion

The occurrence of the HLH phenomenon post-transplant, although rare, is a well-known entity. It can complicate both allogeneic and autologous transplants leading to high mortality.^{4,5} It could be related to infections, mainly viral, or could be independent of any reason.⁷ One of the challenging tasks for a clinician is to differentiate HLH from other variety of systemic inflammatory syndromes, including disseminated intravascular coagulation, capillary leak syndrome, engraftment syndrome, and infection-associated macrophage activation syndrome.⁸ Also, ferritin is a ubiquitously expressed protein, and the specificity of ferritin for HLH is questionable, particularly in transplant settings.

However, primary engraftment failure is a rare complication post autologous transplant; a few case reports support this evidently. Fukuno et al reported a case of B-NHL with graft failure post auto SCT.⁹ Although the patient received high-dose methylprednisolone, the patient succumbed to multiorgan failure. Similarly, HLH post autologous for multiple myeloma has also been reported.¹⁰ In contrast, reporting of secondary HLH in allogeneic transplants is relatively common in the literature. Abe et al have shared their experience of two cases of secondary HLH post allogeneic transplant for lymphoma.¹¹ An interesting prospective observational study by Abdelkefi et al reported the incidence of HLH after SCT in a single institution over 18 months. They found 8.8% incidence in alloSCT vs. 0.9% in auto SCT. In spite of aggressive treatment, half of the patients with HLH died in their study, which emphasizes the dreadfulness of this rare complication.⁶

Recently, EBMT has reported an estimated rate following allogeneic HSCT of 1.09% and much lower estimate of 0.15% following autologous HSCT. In their report, the median cut-off value of ferritin deemed significant was 3,000 µg/L (1,000–10,000 µg/L). However, EBMT commented that what constitutes significant hyperferritinemia in the post-HSCT setting is still undefined and further study is needed to

define appropriate cut-off ranges to inform novel screening and diagnostic criteria.¹² In the experience of Colita et al, there was only 1 case of HLH out of the 22 patients receiving auto-SCT in 18 months (incidence: 4.5%).³ It was also emphasized that the conditioning regimens such as BEAM that contain etoposide have no protective effect against HLH.

As shown in various studies and case reports, HLH has a poor outcome despite aggressive therapy. Albeit, there is no specific recommendation for posttransplant HLH, therapy ranges from corticosteroids, cyclosporine A, low-dose etoposide, intravenous immunoglobulins to the second transplant in case of refractory cases.^{3,10}

In this present report, our patient faced primary graft failure secondary to HLH post autologous transplant. This patient had no clinical features of engraftment syndrome as there were no rashes and weight gain. Also, we ruled out sepsis with low procalcitonin and repeated negative blood cultures. He attained neutrophil engraftment post steroids and cyclosporine. Nonetheless, platelet engraftment could not be achieved which prompted us to start a thrombopoietin receptor agonist (eltrombopag). We also encountered renal toxicity due to cyclosporine and hence it could not be continued for a longer duration.

Conclusion

Posttransplant HLH is a rare but possible cause of primary graft failure in autologous stem cell transplants. Whenever sustained fever with cytopenia and hyperferritinemia is observed, a differential diagnosis of secondary HLH should be acknowledged. The most important aspect is prompt recognition and initiation of the treatment, which could be lifesaving. Our patient was mobilized with a G-CSF alone peripheral blood graft. It would be intriguing to explore whether immune-mediated complications differ between a chemo-mobilized graft versus G-CSF alone graft.

Patient Consent

Signed patient permission to publish the case report has been taken from the patient.

Ethical Approval

The study was approved by the Institutional Review Board of our Center.

Conflict of Interest

None declared.

References

- 1 Schram AM, Berliner N. How I treat hemophagocytic lymphohistiocytosis in the adult patient. *Blood* 2015;125(19):2908–2914
- 2 Marsh RA, Haddad E. How i treat primary haemophagocytic lymphohistiocytosis. *Br J Haematol* 2018;182(02):185–199
- 3 ColiȚă A, ColiȚă A, Dobrea CM, et al. Hemophagocytic lymphohistiocytosis: a rare complication of autologous stem cell transplantation. *Rom J Morphol Embryol* 2016;57(02):551–557
- 4 Ishii E, Ohga S, Imashuku S, et al. Nationwide survey of hemophagocytic lymphohistiocytosis in Japan. *Int J Hematol* 2007;86(01):58–65
- 5 Takagi S, Masuoka K, Uchida N, et al. High incidence of haemophagocytic syndrome following umbilical cord blood transplantation for adults. *Br J Haematol* 2009;147(04):543–553
- 6 Abdelkefi A, Jamil WB, Torjman L, et al. Hemophagocytic syndrome after hematopoietic stem cell transplantation: a prospective observational study. *Int J Hematol* 2009;89(03):368–373
- 7 Nagafuji K, Eto T, Hayashi S, Tokunaga Y, Gondo H, Niho YFukuoka Bone Marrow Transplantation Group. Fatal cytomegalovirus interstitial pneumonia following autologous peripheral blood stem cell transplantation. *Bone Marrow Transplant* 1998;21(03):301–303
- 8 Sreedharan A, Bowyer S, Wallace CA, et al. Macrophage activation syndrome and other systemic inflammatory conditions after BMT. *Bone Marrow Transplant* 2006;37(07):629–634
- 9 Fukuno K, Tsurumi H, Yamada T, Oyama M, Moriwaki H. Graft failure due to hemophagocytic syndrome after autologous peripheral blood stem cell transplantation. *Int J Hematol* 2001;73(02):262–265
- 10 Ostronoff M, Ostronoff F, Coutinho M, et al. Hemophagocytic syndrome after autologous peripheral blood stem cell transplantation for multiple myeloma; successful treatment with high-dose intravenous immunoglobulin. *Bone Marrow Transplant* 2006;37(08):797–798
- 11 Abe Y, Choi I, Hara K, et al. Hemophagocytic syndrome: a rare complication of allogeneic nonmyeloablative hematopoietic stem cell transplantation. *Bone Marrow Transplant* 2002;29(09):799–801
- 12 Sandler RD, Tattersall RS, Schoemans H, et al. Diagnosis and management of secondary HLH/MAS following HSCT and CAR-T cell therapy in adults; a review of the literature and a survey of practice within EBMT centres on behalf of the Autoimmune Diseases Working Party (ADWP) and Transplant Complications Working Party (TCWP). *Front Immunol* 2020;11:524