

Perioperative anesthetic concerns in postcovid mucormycosis patients posted for surgical intervention: An observational Study

ABSTRACT

Background: COVID 19 pandemic caused by severe acute respiratory syndrome coronavirus -2 has proven to be the deadliest pandemic till date. Multiple covid waves have hit people hard on each part of the continent throughout the world. The second wave in India turned out to be highly infectious and virulent. Sudden surge in cases of mucormycosis after recovery of COVID surprised many clinician. Mucormycosis being a rapidly progressive and fulminant fungal infection required surgical debridement of necrotic tissue on emergency basis. The fatal combination of immunocompromised status, multisystemic involvement, and difficult airway in these patients pose numerous new challenges regarding anesthetic management. The present study was conducted to outline major concerns and the anesthetic management of patients undergoing surgical resection for rhinoorbital mucormycosis (ROM).

Materials and Methods: A retrospective observational study was conducted in our institute for a duration of 2 months (June and July 2021). The data of all the cases posted for ROM was collected from the ENT and Anesthesia record register. Total 70 patients presented with mucormycosis, for surgical debridement out of which 25 patients were posted for surgery under general anesthesia or monitored anesthesia care (MAC). Demographic characteristics, comorbidities, duration of COVID illness, treatment taken during COVID (oxygen therapy/steroid intake), hemodynamic parameters, monitoring methods, and surgical procedures were recorded for each patient.


Statistical Evaluation: SPSS version 21.0 was used for data analysis. Mean and SD were used to analyze the difference in mean values, and independent Student's *t*-test were utilized to compare the quantitative variables. Frequency distribution and percentage were used for qualitative parameters. Significant difference was accepted at $P \leq 0.05$ with 95% CI (confidence interval) in the study.

Results: Demographic data were comparable with respect to age, gender distribution, and ASA status. Mean duration of Covid illness was (12.18 ± 3.68) days. The mean HbA1C measured was (10.8 ± 1.42) . Strong correlation was found between steroid intake and raised HbA1c in all patients ($r = 0.77$). Regarding the comorbidities, 24 (96%) patients had associated type 2 diabetes mellitus, 16 patients (64%) had pneumonitis, and 1 patient had pulmonary TB and hepatitis.

Conclusion: Considering the perioperative risk associated with high HbA1C and pneumonitis, MAC was preferred in majority of cases. Strict hemodynamic monitoring, perioperative glucose control, difficult airway cart, metabolic and electrolyte balance and vigilant peri-operative monitoring are cornerstone for better outcome and short length of hospital stay.

Key words: Anesthetic concerns, postcovid, rhinoorbital mucormycosis

Access this article online

Website: www.saudija.org	Quick Response Code 
DOI: 10.4103/sja.sja_783_21	

This is an open access journal, and articles are distributed under the terms of the Creative Commons Attribution-NonCommercial-ShareAlike 4.0 License, which allows others to remix, tweak, and build upon the work non-commercially, as long as appropriate credit is given and the new creations are licensed under the identical terms.

For reprints contact: WKHLRPMedknow_reprints@wolterskluwer.com

How to cite this article: Misra S, Rastogi S, Malviya D, Gupta R, Yadav SK, Alam S. Perioperative anesthetic concerns in postcovid mucormycosis patients posted for surgical intervention: An observational study. Saudi J Anaesth 2022;16:176-81.

SHILPI MISRA, SHIVANI RASTOGI, DEEPAK MALVIYA, RACHANA GUPTA, SANDEEP K. YADAV, SHARIF ALAM

Department of Anesthesiology and Critical Care, Dr. Ram Manohar Lohia Institute of Medical Sciences, Lucknow, Uttar Pradesh, India

Address for correspondence: Dr. Shivani Rastogi, Department of Anesthesiology and Critical Care, Dr. Ram Manohar Lohia Institute of Medical Sciences, Lucknow - 226 010, Uttar Pradesh, India.
E mail: neuromanu@yahoo.com

Submitted: 03-Nov-2021, **Accepted:** 29-Nov-2021, **Published:** 17-Mar-2022

Introduction

Mucormycosis, known to be a rare, fulminant, rapidly progressive, and opportunistic fungal infection, is most commonly seen in immunocompromised patients.^[1,2] The sudden surge in mucormycosis cases in *long Covid* patients in India during the second wave surprised many clinicians. The causative factors were supposed to be steroid use and immunocompromised state in Covid pneumonia. The treatment guidelines and reduction in morbidity and mortality for mucormycosis lies in early diagnosis, treatment of predisposing factors, surgical debridement of necrotic tissue, and administration of antifungal therapy.^[3] The anesthetic concerns for patients scheduled for surgical debridement in ROM include multisystemic involvement, residual respiratory compromise, immunocompromised status, adrenal suppression, difficult airway, and the drug interaction with amphotericin B. These patients have higher chances of cerebral extension if surgery is delayed; thus, emergency debridement is necessary.

The previous studies done on ROM with immunocompromised status did not take in account the associated risk complications with COVID. Majority of our patients were having rhinomaxillary-orbital mucormycosis (ROM) with recent onset diabetes and were treated with systemic amphotericin B, antiinflammatory drugs, and regular insulin.

After analyzing the data and the patient outcome in these patients, the present study outlines the anesthetic concerns and management of postcovid patients posted for surgical debridement and orbital exenteration for Rhino orbital mucormycosis (ROM).

Material and Methods

Patient population

After approval from institutional ethical committee (IEC 67/21), this retrospective observational study was carried out in a tertiary government institute in the department of anesthesiology on patients presented with ROM. A total of 70 patients presented with mucormycosis during the period of June 2021–July 2021, out of which 25 patients were posted for surgical resection under general anesthesia or monitored anesthesia care (MAC) [Figure 1]. The data was collected from the ENT operation theatre record register.

Demographic parameters including age, sex, duration of covid illness, treatment received, comorbidities, extension of mucormycosis, and surgical debridement required were recorded.

Keeping the concerns in mind, the patients were investigated for baseline parameters. Complete blood count, liver and kidney function tests, coagulation profiles, fasting/postprandial blood sugar, HbA1C, serum electrolytes, ECG, pulmonary function test (PFT), and if required echocardiography was done. Histopathological examination of biopsy specimen and imaging (CT/MRI) confirmed the diagnosis and extension of mucormycosis.

Anesthetic management

The anesthetic technique either GA/MAC was decided after due discussion with the operating surgeon keeping in mind the extension of mucor and feasibility of the surgery with utmost safety.

Patients were asked to nil per oral for solid food 6 h and clear liquid 2 h before surgery. Patients were premedicated with tablet alprazolam 0.5 mg and tablet ranitidine 150 mg in the night before surgery.

After obtaining verbal and written consent, the patients were wheeled into operation theater, intravenous access (18 G) were secured, and baseline multipara monitors were attached which included ECG, pulse oximeter, NIBP, end tidal CO₂, temperature. A difficult intubation cart was kept ready in view of anticipated difficult airway. Patients posted under GA technique were premedicated with inj glycopyrrolate 0.2 mg, inj midazolam 1.5 mg, and inj fentanyl 2 mcg/kg. After preoxygenation with 100% oxygen, induction done with inj propofol 2 mg/kg and intubated with cuffed reinforced endotracheal tube after relaxation with inj vecuronium 0.8 mg/kg. Intraoperative vitals, temperature, urine output, blood sugar, arterial blood gas monitoring was done. Further maintenance dose of relaxant was given with proper neuromuscular monitoring. The patient was maintained with oxygen and air (40:60) and isoflurane MAC 1% with controlled mechanical ventilation.

Patients under MAC were given the drugs for anxiolysis and sedation, inj glycopyrrolate 0.2 mg, inj midazolam 1.5 mg, and inj fentanyl 1–2 mcg/kg with maintenance of spontaneous ventilation.

Invasive arterial line was inserted postintubation for strict hemodynamic monitoring. Isotonic iv fluid (crystalloids and kablyte) were preferred during perioperative maintenance, but colloid and vasopressors were kept ready in view of hypotension unresponsive to crystalloid. The hemodynamic measurements were done at baseline, after intubation, 30 min, 1 h, and after extubation.

The BS monitoring was done every hourly and target of blood sugar level kept between 110 and 180 mg/dL.

ABG was performed preoperatively to assess the ventilatory, electrolyte, and metabolic parameters and repeated before extubation trial.

On completion of surgery, residual muscle paralysis was reversed with inj glycopyrrolate and inj neostigmine. After complete reversal, patients were shifted to postoperative room with and patients maintaining SpO₂ <92% were kept on O₂ by face mask/nasal prong and shifted to ICU for further observation.

Statistical evaluation

SPSS version 21.0 was used for data analysis. Mean, SD, and interquartile range were used to analyze the difference in mean values, and independent Student's *t*-test Kruskal–Wallis test were utilized to compare the quantitative variables. Frequency distribution and percentage were used for qualitative parameters. Significant difference was accepted at $P \leq 0.05$ with 95% CI (confidence interval) in the study.

Results

Demographic data were comparable with respect to age, gender distribution, and ASA status [Tables 1 and 2]. Age of the patients ranged between 32 and 75 years, mean age being (51.64 ± 9.6) year. Fourteen patients were male (56%) and 11 were female (44%). Ten patients were ASA II, while 15 patients were ASA III grading. Mean duration of Covid illness was (12.18 ± 3.68) days. The mean HbA1C measured was 10.8 ± 1.42.

There was a strong correlation found between steroid intake and raised HbA1c in all patients ($r = 0.77$) [Table 3, Figure 2].

The pathologies ranged from sino nasal, sino orbital, to sino naso orbital mucormycosis [Figure 3].

Surgeries performed were B/L endoscopic debridement in 10 patients (40%), diagnostic nasal endoscopy and debridement on 5 patients, endoscopic sinus surgery + orbital exenteration on 4 patients, and medial maxillectomies on 6 patients.

Regarding the comorbidities associated, 24 patients had associated type 2 diabetes mellitus, 16 patients (64%) had pneumonitis, and 1 patient had pulmonary TB and hepatitis.

Twenty-four patients had mild to moderate anemia but despite that, iron supplementation was not given due to

Table 1: Demographic details in the study (independent Student's *t*-test)

Demographic details	<i>n</i>	mean ± SD	<i>P</i>
Age	25	51.64 ± 9.6	0.053 (NS)
Hb		9.79 ± 0.92	0.044 (S)
HbA1c		10.8 ± 1.42	0.022 (S)
Duration of illness		12.18 ± 3.68	0.052 (NS)

NS: statistically nonsignificant, S: statistically significant

Table 2: Frequency distribution table

Variables	<i>n</i>	%
Sex		
Male	14	56
Female	11	44
Diagnosis		
Sino orbital mucor	3	12
Sino nasal mucor	6	24
Right sino nasal	6	24
Left sino nasal	5	20
Sino nasal orbital	5	20
Surgery		
B/L endoscopic debridement	10	40
DNE and debridement	3	12
ESS + orbital exenteration	4	16
Left nasal cavity debridement	1	4
Right nasal cavity debridement	1	4
Right medial maxillectomy	3	12
Left medial maxillectomy	3	12
Comorbidity		
Pneumonitis + T2DM + O ₂	12	48
Pneumonitis + T2DM + RA	2	8
T2DM	5	20
Bilateral pneumonitis + T2DM	1	4
T2DM/HT	3	12
Pulmonary TB + ATT-induced hepatitis	1	4
Steroid		
Dexa 8 mg BD	7	28
Dexa 4 mg BD	1	4
Medrol 4 mg BD	2	8
Medrol 16 mg OD	2	8
Investigations		
Anemia + Hypokalemia	8	32
Anemia + Hypoalbuminemia	3	12
Anemia	13	52
Hypoalbuminemia	1	4
Postoperative		
O ₂ inhalation	14	56
Room air	11	44
Anesthesia		
GA	6	24
MAC	19	76
ASA		
II	10	40
III	15	60

T2DM: Type 2 diabetes Mellitus, HT: hypertension, RA: Rheumatoid arthritis, O₂: on oxygen inhalation by face mask/nasal prong

probability of exacerbation of mucor mycosis growth in an iron- rich and acidotic environment. Four patients had hypoalbuminemia. Hypokalaemia was the commonest electrolyte imbalance found in eight patients.

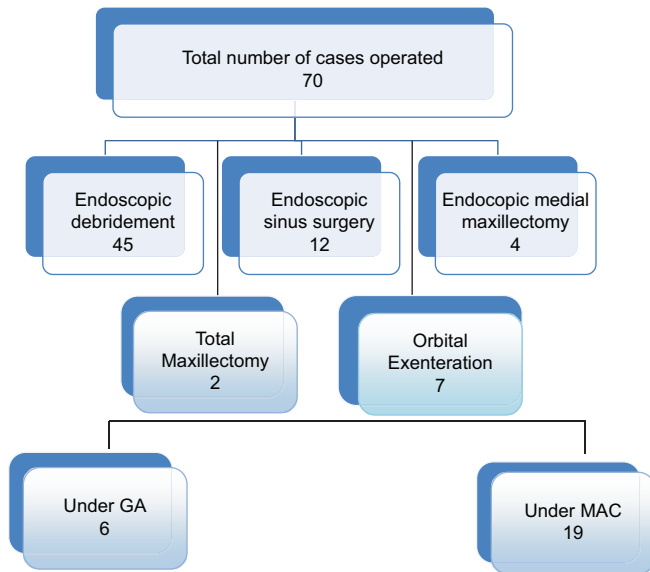


Figure 1: Flow chart depicting distribution of cases

The hemodynamic measurements done perioperatively did not show any instability [Table 4].

Fourteen patients required oxygen inhalation postoperatively, while 11 maintained spO₂ >94% at room air. None of the patient required vasopressor perioperatively.

Discussion

Mucormycosis is an angioinvasive disease caused by fungi of the order mucorales like rhizopus, mucor, rhizomucor. It is hypothesized that severe acute respiratory syndrome coronavirus -2 infection may affect CD4+ and CD8+ T-cells, which are highly involved in the pathological process of COVID-19 infection. It has been shown that in severe COVID-19 cases, there is a reduction in the absolute number of lymphocytes and T-cells, which is associated with the worst outcomes. Mucorales-specific T-cells (CD4+ and CD8+) produce cytokines such as interleukin IL 4, IL-10, IL-17, and interferon-gamma (IFN-γ) that damage the fungal hyphae.

Mucormycosis is more often seen in immunocompromised individuals, and complications of orbital and cerebral involvement are likely in patients with diabetes mellitus and with concomitant use of steroids. The patients treated with antifungal alone have a higher mortality rate when compared to the patients undergoing surgical debridement too.^[4] Previous studies done for mucormycosis recommend aggressive antifungal and surgical treatment for improved outcome.^[5] Thus, in our center the patients on amphotericin B for mucormycosis were posted for debridement on emergency basis with due preparations for comorbidities and metabolic derangements.

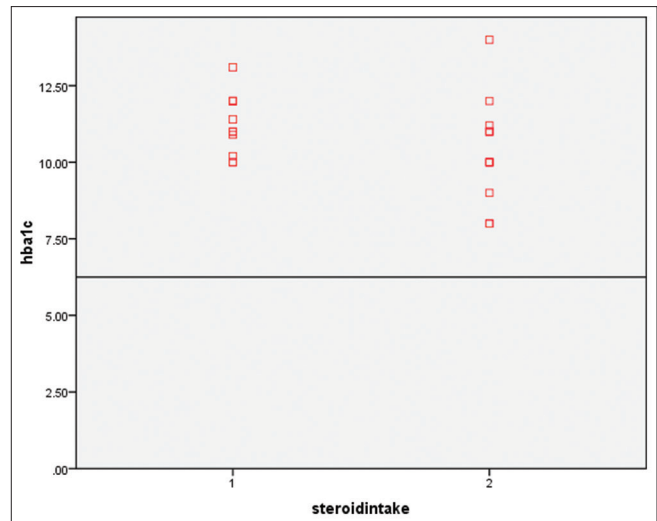


Figure 2: Correlation between steroid intake and HbA1c

Table 3: Pearsons' correlation between steroid intake and HbA1c

Variables	n	P	r
Steroid intake HbA1c	25	0.039	0.711

Table 4: Hemodynamic measurements at different time intervals

Vitals	Mean	Range	P
HR			
Baseline	79.7	77.4-82.07	0.061 (NS)
Intubation	79.8	77.5-82.12	0.063 (NS)
30 min	82.43	79.94-84.9	0.031 (S)
1 h	83.9	81.35-86.4	0.023 (S)
After extubation	80.9	78.8-83.02	0.011 (S)
MAP			
Baseline	84	76-90	0.066 (NS)
Intubation	83	78-94	0.012 (S)
30 min	86	77-97	0.033 (S)
1 h	92	79-98	0.014 (S)
After extubation	87	80-00	0.017 (S)
SpO ₂	93.04	92.22-93.86	0.041 (S)

The data collected in our study found majority of patients had new onset of uncontrolled diabetes and on statistical evaluation found a strong correlation between steroid intake during COVID illness and raised HbA1C ($r > 0.7$). Dash AK et al. have also shown higher occurrence of mucormycosis in patients with diabetes mellitus.^[6] Thus, long-term steroid intake can be related to higher chances of being infected with mucormycosis.

Anesthesiologist may face difficult ventilation and intubation scenario in patients with mucormycosis patients owing to fungal debris and associated airway edema;^[7] thus, a difficult airway cart should be kept ready in view of anticipated difficult airway. In our study, one patient required fiberoptic intubation.

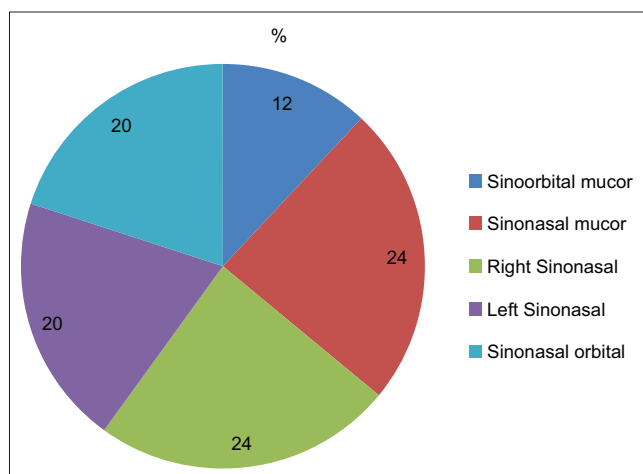


Figure 3: Extension of mucormycosis

Mucormycosis patients with coexistent sepsis, multisystemic involvement, and immunosuppression have increased morbidity and mortality,^[8] and the surgeries performed under general anesthesia will have added complications. In our study, 16 patients (64%) had associated pneumonitis making them more prone to postoperative pulmonary complications (POPCs) if done under GA; thus, we preferred MAC over GA where ever possible after due discussion with the operating surgeon. If the surgeries were done under GA, the lung protective ventilatory settings were set.^[9]

Systemic amphotericin B, antifungal used for mucormycosis, has been reported to have some side effects like hypokalemia, hypomagnesemia, fever, shivering, dyspnea, hypotension, and in some cases leads to nephrotoxicity, less commonly seen with liposomal amphotericin B.

Maintaining hemodynamic stability in the perioperative period is of utmost priority for adequate renal perfusion and preventing any renal compromise. The patients on chronic steroid therapy are prone for hypotension in cases of adrenal suppression. Thus, invasive intraarterial monitoring was done to monitor hemodynamic parameters. Electrolyte and metabolic parameters were maintained on the basis of arterial blood gas values.

There has been no ideal intravenous or inhaled anesthetic agent recommended for patients posted for debridement in progressive fungal infections with like mucormycosis. Some volatile anesthetic agents have shown antibacterial and antifungal activity. Barodka *et al.*,^[10] in a previously done *in vitro* study, documented that isoflurane inhibited the growth of albicans. We used isoflurane as an inhaled anesthetic agent during maintenance of anesthesia in our patients.

Keeping in view that the electrolyte imbalance, drug interaction with amphotericin B, and multisystem involvement

can prolong muscle relaxation, we supplemented the maintenance dose of muscle relaxant in accordance with the neuromuscular monitoring.

Debridement of necrotic tissue is usually not associated with significant bleeding, still blood grouping and crossmatching was performed and blood bank informed for urgent requirement of PRBC if needed.

Three patients required blood transfusion in the postoperative period.

The limitation in our study is that the sample size is relatively small and the patients were from our institute only. The analysis done from various other center with large sample size can validate the findings in our study.

Anesthetic concerns

The concerns in our patients were:

1. **Difficult airway:** Patients with ROC mucormycosis should be considered as case of anticipated difficult mask ventilation and endotracheal intubation because of associated airway edema and fungal debris. Thus, a difficult airway cart should be kept ready with well-fitting facemasks, supraglottic airways (LMA/I Gel), rigid laryngoscope with variable blade, suction catheters, stylets or gum elastic bougies, video laryngoscopes, fiberoptic bronchoscope, and all equipment for emergency tracheostomy.^[11]
2. **Pulmonary complications:** The COVID presentation might vary from asymptomatic to pulmonary complication (pulmonary fibrosis). The patients were assessed for clinical finding, radiographic presentation, and PFT. The perioperative presentation may be a risk factor for POPC.
3. **Uncontrolled/labile blood sugar levels:** The patients of ROM presented with new onset DM because of steroid use during COVID illness. Labile perioperative blood sugar levels were independent risk factor for perioperative and postoperative morbidity.
4. **Septicemia:** These patients were immunocompromised with coexistence sepsis, hypoalbuminemia, and multiple organ involvement, making them prone for increased morbidity and mortality.^[5]
5. These patients were treated with amphotericin B which might cause metabolic derangements, and the interaction with anesthetic agents may have added implications.

Conclusion

Considering the rapidly progressive and fulminant nature of mucormycosis, early surgical debridement should be

planned. Strict hemodynamic monitoring to maintain mean arterial pressure, perioperative glucose control, preparation with difficult airway cart, maintenance of metabolic and electrolyte balance, and postoperative ICU management are mandatory for better outcome in COVID recovered patients posted for ROC mucormycosis. We recommend the surgery to be performed under MAC preferably for better outcome and short length of hospital stay. Any lack in preparation can be detrimental to the already compromised patients.

Declaration of patient consent

The authors certify that they have obtained all appropriate patient consent forms. In the form, the patient(s) has/have given his/her/their consent for his/her/their images and other clinical information to be reported in the journal. The patients understand that their names and initials will not be published and due efforts will be made to conceal their identity, but anonymity cannot be guaranteed.

Financial support and sponsorship

Nil.

Conflicts of interest

There are no conflicts of interest.

References

1. Wali U, Balkhair A, Al-Mujaini A. Cerebro-rhino orbital mucormycosis: An update. *J Infect Public Health* 2012;5:116-26.
2. Michael D. Mucormycosis of the head and neck. *Curr Infect Dis Rep* 2011;13:123-31.
3. Viterbo S, Fasolis M, Garzino-Demo P, Griffa A, Boffano P, Iaquina C, *et al.* Management and outcomes of three cases of rhinocerebral mucormycosis. *Oral Surg Oral Med Oral Pathol Oral Radiol Endod* 2011;112:e69-74.
4. Spellberg B, Edwards J, Ibrahim A. Novel perspectives on mucormycosis: Pathophysiology, presentation, and management. *Clin Microbiol Rev* 2005;18:556-69.
5. Teixeira CA, Medeiros PB, Leushner P, Almeida F. Rhinocerebral mucormycosis: Literature review apropos of a rare entity. *BMJ Case Rep* 2013; 2013. doi: 10.1136/bcr-2013-008552.
6. Dash AK, Arora V, Nagarkar NM. Rhino-orbital mucormycosis. *Natl J Otorhinolaryngol Head Neck Surg* 2013;10:5-6.
7. Eckmann DM, Seligman I, Cote CJ, Hussong JW. Mucormycosis supraglottitis: induction of anesthesia in an immunocompromised host. *Anesth Analg* 1998;86:729-30.
8. Karaaslan E. Anesthetic management of rhino-orbitocerebral mucormycosis; Focus on challenges. *J Mycol Med* 2019;29:219-22.
9. Kilpatrick B, Slinger P. Lung protective strategies in anaesthesia. *Anaesth* 2010;105(Suppl 1):i108-16.
10. Barodka VM, Acheampong E, Powell G, Lobach L, Logan DA, Parveen Z, *et al.* Antimicrobial effects of liquid anesthetic isoflurane on *Candida albicans*. *J Transl Med* 2006;9:46. doi: 10.1186/1479-5876-4-46.
11. Apfelbaum JL, Hagberg CA, Caplan RA, Blitt CD, Connis RT. Practice guidelines for management of the difficult airway: An updated report by the American Society of Anesthesiologists Task Force on management of the difficult airway. *Anesthesiology* 2013;118:251-70.

New features on the journal's website

Optimized content for mobile and hand-held devices

HTML pages have been optimized of mobile and other hand-held devices (such as iPad, Kindle, iPod) for faster browsing speed.

Click on [**Mobile Full text**] from Table of Contents page.

This is simple HTML version for faster download on mobiles (if viewed on desktop, it will be automatically redirected to full HTML version)

E-Pub for hand-held devices

EPUB is an open e-book standard recommended by The International Digital Publishing Forum which is designed for reflowable content i.e. the text display can be optimized for a particular display device.

Click on [**EPub**] from Table of Contents page.

There are various e-Pub readers such as for Windows: Digital Editions, OS X: Calibre/Bookworm, iPhone/iPod Touch/iPad: Stanza, and Linux: Calibre/Bookworm.

E-Book for desktop

One can also see the entire issue as printed here in a 'flip book' version on desktops.

Links are available from Current Issue as well as Archives pages.

Click on  View as eBook