



Single-Stage Reconstruction of Maxillectomy and Midfacial Defects in Cases of Covid Associated Mucormycosis

Tarun Ojha¹ · Manish Jain² · Priyanshi Gupta¹

Received: 3 December 2021 / Accepted: 10 July 2022
© Association of Otolaryngologists of India 2022

Abstract

Objective To advocate a single stage reconstruction in cases of maxillectomy and midfacial defects operated for covid associated mucormycosis to enable a favorable overall outcome within a shorter duration in terms of survival, quality of life, speech, deglutition and aesthetics.

Method In our series of six patients with signs and symptoms suggestive of covid associated mucormycosis with diabetes as a predisposing factor had undergone Contrast enhanced CT and MRI with biopsy confirming the diagnosis, were then subsequently posted for resection and reconstruction depending upon extent of disease and defect left behind. Out of six, three were revision cases and the other three were primary cases. All had undergone single stage reconstruction using free flap (5/6) and pedicle (1/6) after intra-operative margins and distal most part of recipient vessels was found negative for mucormycosis on histopathology. Post-operative Liposomal Amphotericin B with Oral Posaconazole along with antibiotics and supportive treatment were given and were then followed up.

Results All the cases have complete flap survival after a mean follow-up of 90 days with no recurrence of mucormycosis. We had a survival rate of 100% with patients having good quality of life, speech, deglutition and acceptable aesthetical outcome.

Conclusion Stepping up on the reconstruction ladder to provide a single stage management in patients of covid associated mucormycosis by adequate surgical debridement, intraoperative negative margins on histopathology and subsequent reconstruction using autologous flaps is the need of the hour to provide within a shorter duration, favourable overall outcome in terms of survival, quality of life, speech, deglutition and aesthetics.

Keywords Covid Associated Mucormycosis · Maxillectomy · Free flap reconstruction

Introduction

The COVID 19 pandemic originated in Wuhan in 2019 and subsequently spread to all corners of the globe leading to widespread morbidity and mortality along with unprecedented economic and societal disruption. The ‘second wave’

of the epidemic in India in the months of April to June 2021 occurred due to the Delta (B.1.617.2) variant and was particularly devastating [1]. It prompted the use of steroids as the first line of management which proved to be a double-edged sword exacerbating diabetes which was previously well controlled or flaring up of latent or previously undiagnosed diabetes. The angio-invasive fungal form of this disease spread by fungal spores in a hyperglycaemic environment causing luminal thrombosis resulting in mucosal infraction and necrosis, bony erosion with its rapid progression advancing into Sino-nasal cavity, orbit and eventually into cranial cavity.[2].

Mucormycosis carries a high fatality rate and the management involves prompt surgical intervention along with liposomal Amphotericin B [3, 4]. It is imperative that all involved sites be thoroughly debrided (as one would expect in a case of malignancy) and no residual disease is left behind. Such large volume excision leaves behind major

✉ Priyanshi Gupta
priyanshi728@gmail.com

Tarun Ojha
drtarunojha_ent@yahoo.com

Manish Jain
drmanishjainms@gmail.com

¹ Department of ENT, Mahatma Gandhi Medical College and Hospital, Jaipur, India

² Department of Plastic Surgery, Mahatma Gandhi Medical College and Hospital, Jaipur, India

Table 1 Demography and clinical presentation in individual cases

Case	Age	Sex	Predisposing factor	Date of surgery	Onset after COVID (days)	Presenting complaints	Initial medical treatment
1	52yr	M	Diabetes, Hypertension	7-7-2021	35 days	Right side Facial swelling,	Amphotericin 30 days
2	41yr	M	Diabetes	3-7-2021	40 days	Right Purulent nasal discharge, right periorbital swelling	Amphotericin 3 days before debridement
3	36yr	M	Diabetes	24-6-2021	55 days	Headache, Left eye reduced vision and Pain over Left cheeks	Amphotericin 3 days before debridement
4	48yr	M	Diabetes	12-06-2021	27 days	Right purulent Nasal discharge, Right eye decreased vision	Amphotericin 12 days before debridement
5	56yr	F	Diabetes	2-06-2021	54 days	Left side Facial swelling	Amphotericin 2 days before debridement
6	46yr	F	Diabetes	24-05-2021	23 days	Right side facial swelling, right purulent nasal discharge, Right Peri-orbital oedema.	Amphotericin 4 days before debridement

anatomical defects and the reconstruction in such cases can be equally challenging. In this series we present 6 cases of CAM where resection and immediate flap reconstruction was performed.

Methods

The reported case series was conducted as a retrospective study. Six patients, consisting of four males and two females with a mean age of 46.5 years (range 36–56 years) who presented with signs and symptoms of post covid mucormycosis were evaluated by contrast MRI and CT scan and pre-operative biopsy were sent from the most representative site on radiology. [Table 1] However, Amphotericin B was initiated on high index of clinical suspicion. Diabetes was the predisposing factor in all the cases either diagnosed on admission or uncontrolled previously diagnosed on medication. Three cases had previously undergone endoscopic debridement with post-operative amphotericin B. however they had recurrence of mucormycosis and were then subjected to revision procedure. Three cases had extensive involvement which could not be cleared endoscopically hence were subjected to primary open maxillectomy in one and with orbital exenteration in the other. Reconstruction was done using free flap (five out of six cases) and pedicle (one-sixth). [Table 2]. Institutional ethical committee approval was obtained. The medical charts were reviewed to obtain data on (1) age, (2) sex, (3) Date of surgery, (4) Predisposing factor, (5) Onset after covid, (6) Presenting complaints, (7) Initial medical treatment, [Table:1] (8) Afflicted areas, (9) Surgical procedure and reconstruction (10) Follow-up. [Table 2]

Operative Technique

Diagnosis of post-covid mucormycosis necessitated early intervention with Liposomal Amphotericin B and surgical debridement with reconstruction. The size and volume of a flap for reconstruction were evaluated by assessing the extent of disease on MRI and CT. A two-team approach was used thus reducing the operative time and contamination of wound in the donor area. The skin and soft tissue were resected with a 2-cm macroscopic healthy tissue margin along with affected tissue. Alongside, flap elevation was started by raising one of the flap's margins to find primary perforator and continued until pedicle dissection of desired length was accomplished.

All resected specimen were sent to pathologist to rule out fungal presence. The samples were evaluated using haematoxylin and eosin staining (20–30 min) for rapid hyphae evaluation. The definitive biopsies were evaluated after staining with Grocott's methenamine silver. After evaluating intra-operatively with no apparent affected tissue left, we selected the recipient vessels based on the flap location and pedicle length. After dissection, 1 to 2 mm of distal most portion of recipient artery and vein were sent for hyphae analysis in the similar way. On confirmation of fungal hyphae absence and adequate debridement of all the affected tissues, the anastomosis was performed with the pedicle. The purpose of the flap was cavity filling, bulk restoration, provision of oral and nasal lining. The donor site was primarily closed in all the cases (Fig. 1 and 2).

Post-operative care was done in mucormycosis intensive care unit.

Table 2 Excisional defect and reconstructive method in individual cases

Case	Primary or revision cases	Previous operative procedure	Areas afflicted	Excision and defect	Reconstruction	Remarks
1	Revision	Right, Endoscopic Medial Maxillectomy (Modified Denker's), sinus debridement, Partial Middle and Inferior turbinectomy	Ipsilateral maxilla,	Subtotal maxillectomy ^a	Free Fascio-cutaneous ALT flap	Complete flap survival; Amphotericin for 22 days post-op. Follow-up of 60 days.
2	Revision	Right, Endoscopic Medial Maxillectomy (Modified Denker's), sinus debridement, Partial Middle and Inferior turbinectomy	Ipsilateral maxilla, Infra-orbital rim, lateral 1/4th of ipsilateral palate	Subtotal maxillectomy ^b	Free Fascio-cutaneous ALT flap	Complete flap survival; required resuturing on 6th post-op day; Amphotericin for 45 days post-op. Follow-up of 63 days
3	Revision	Left, Endoscopic Medial Maxillectomy (Modified Denker's), sinus debridement,	Ipsilateral Hard palate, 1/3rd Soft palate,	Palate debridement.	Pedicled Facial artery myomucosal flap	Complete flap survival; Amphotericin for 25 days post-op. Follow-up of 90 days
4	Primary	None	Eye, Ipsilateral Maxilla, Palate	Maxillectomy and orbital exenteration	Free Bipaddle Anterolateral thigh flap	Complete flap survival; Amphotericin for 42 days post-op. Follow-up of 96 day
5	Primary	None	Ipsilateral Maxilla, Ipsilateral hard Palate	Maxillectomy with orbital preservation	Free Bipaddle Anterolateral thigh flap	Complete flap survival; Amphotericin for 20 days post-op. Follow-up of 110 days
6	Primary	None	Ipsilateral Maxilla, Ipsilateral Hard palate,	Subtotal maxillectomy ^c with orbital preservation	Free Radial artery forearm flap	Complete flap survival; Amphotericin for 23 days post-op. Follow-up of 120 days.

a- Lateral upper alveolus, lateral nasal walls

b- Lateral upper alveolus, adjacent palate, lateral nasal walls

c- Lateral upper alveolus, adjacent palate, Anterolateral wall of maxilla, preserving the upper orbital rim

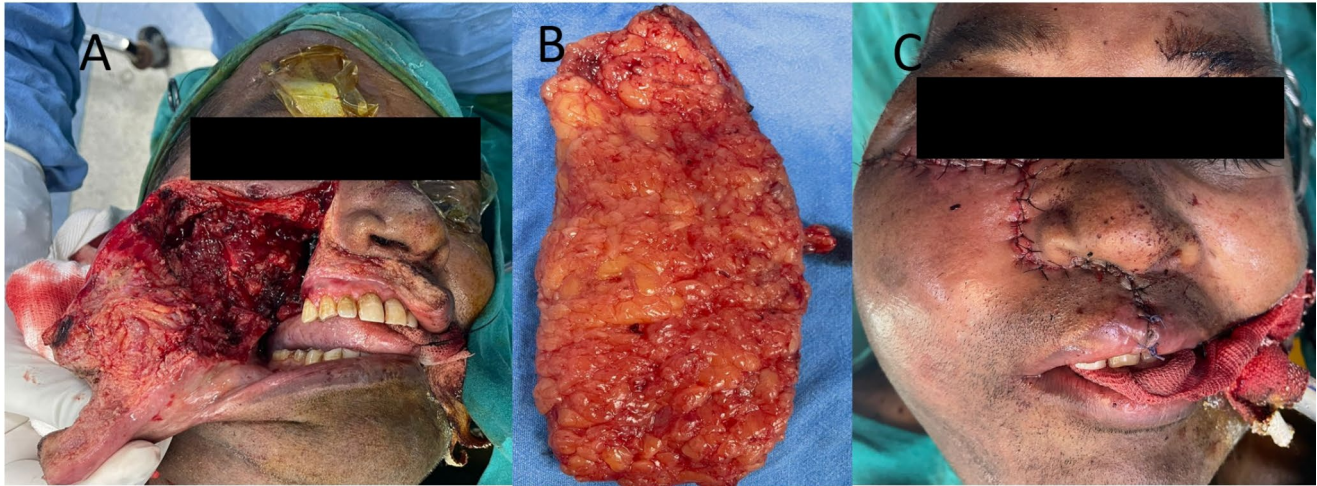


Figure 1, A,B,C

Fig. 1

Results

Six cases of post-covid mucormycosis with reconstruction are presented. In all these cases we had complete flap survival with mean follow-up of 90 days. All donor sites healed uneventfully. All these patients were given Post-operative

L-AmB with a mean of 30 days [range 20–45 days] and then switched to Oral Posaconazole tablets for 3 months. All these cases are asymptomatic and on regular-follow-up.

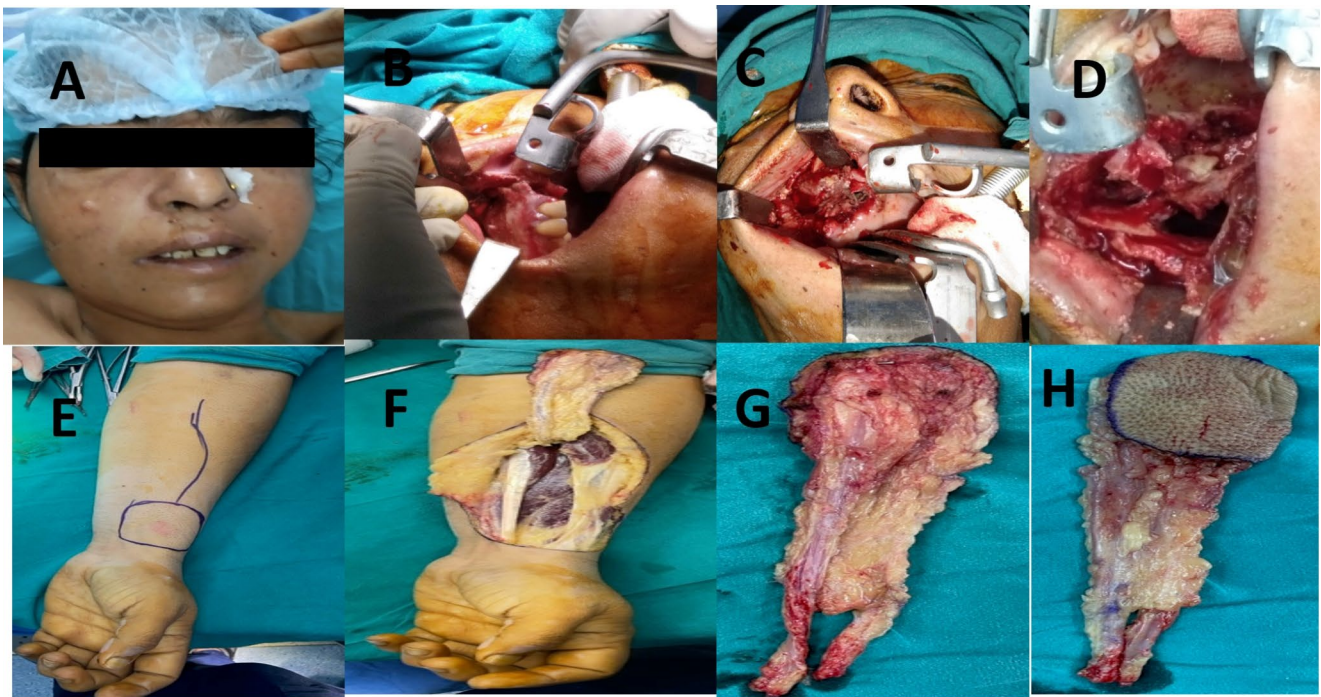


FIGURE 2, A,B,C,D,E,F,G,H

Fig. 2

Discussion

Covid associated mucormycosis [CAM] may involve the nose, paranasal sinuses, orbit, cranium and palate which is challenging in terms of management. The most critical aspect in having a favourable outcome is prompt diagnosis. It is known that diplopia, ophthalmoplegia, proptosis, periocular cellulitis, ocular pain, acute vision loss, nasoantral or cutaneous eschar in a predisposed host carry a potentially high predictive value.[5] Along with L-AmB, radical surgical debridement must be expeditious to eradicate the fungal reservoir by acting aggressively until bleeding tissue, bone, and periosteum is well perfused with the antifungal agent.

It is vital to provide these patients with a good outcome in terms of survival, quality of life, speech, feeding and aesthetics [7]. The appropriate technique for reconstruction depends primarily on the type of anatomical defect. There are several classification systems for maxillary defects [8], although the Brown classification system has been widely adopted. [9] Although these are more pertinent for maxillary tumours, similar principles may be extrapolated for cases of CAM as well. The reconstruction may be done by the use of prosthesis or flap reconstruction.

Historically, maxillectomy defects were reconstructed with a skin graft to revive a mucosal barrier followed by use of an obturator. [6] Obturator can be used when the defect is limited, patients are poor surgical candidates with an

advantage that it is a cheaper reconstructive option, causing less surgical morbidity but with a disadvantage of giving persistent crusting and pain, subjective to wear and tear over time, require daily maintenance and may require frequent visits for adjustments. It may demand a level of manual dexterity for insertion, removal and cleaning which can be challenging for elderly and people with failing dexterity. [10]

Depending of the size and volume of defect, either free flaps or pedicled flaps may be employed. With free flap reconstruction, there are several options like fasciocutaneous flap from anterolateral thigh, radial forearm, myocutaneous flaps from latissimus dorsi or rectus abdominis, or osseocutaneous flaps - fibular free flap, scapular flaps with either thoracodorsal artery or circumflex scapular artery, radial forearm osseocutaneous flap and iliac crest free flap. All types of flaps have their pros and cons and the ultimate decision rests with the reconstructive surgeon based on the type and size of the defect along with convenience and expertise. [11] The algorithms proposed by Cordeiro and Chen serve as valuable guides in decision making [12].

Perforator free flaps allow surgeons to reap large areas of skin and subcutaneous tissue, supplied by vessels perforating the underlying muscle, without harvesting denervated muscle. In so doing, surgeons can minimize postoperative pain, muscle weakness, and therefore the risk of hernia formation after muscle harvest. Surgeons can also better predict flap bulk by not including denervated muscle during

a flap which will significantly atrophy over time. [13] The anterolateral thigh (ALT) flap for example, can be harvested as a perforator flap for midface reconstruction. It provides significant tissue bulk and an extended pedicle (10–15 cm), allows for primary closure of the donor [13]. site, and can be sensate. Further, when two separate perforators are harvested, then the ALT can provide two separate skin flaps allowing for intraoral and skin reconstruction. Other perforator flaps include the deep inferior epigastric perforator flap, the anteromedial thigh perforator flap, the arteria glutes perforator flap, the thoracodorsal artery perforator flap, peroneal artery perforator flap, submental perforator flap, and others [13].

Previous studies have demonstrated the feasibility of flap reconstruction in maxilla defects. [14] The reconstruction may also be either immediate or delayed. A large proportion of cases from older series underwent delayed reconstruction. [14] The apprehension with immediate reconstruction is that of recurrence of local disease and failure of the flap which may render the whole surgery futile and lead to tremendous patient morbidity. However, it has been demonstrated that if the margins are clear of the disease, then simultaneous flap reconstruction is also a valid option. [14, 15]

The management of CAM during the deadly second wave of COVID 19 was a challenge not just in terms of medical and surgical management but also in terms of logistics. The volume of cases was unprecedented. Health facilities and intensive care were completely saturated with COVID cases. There were also issues with availability of Liposomal Amphotericin. This series highlights that despite these mitigating factors it was still possible to provide satisfactory patient outcome with single-stage surgical debridement and autologous flap reconstruction.

Conclusions

Stepping up on the reconstruction ladder to provide a single stage management in patients of covid associated mucormycosis by adequate surgical debridement, intra-operative negative margins on histopathology and subsequent reconstruction using autologous flaps is the need of the hour to provide within a shorter duration, favourable overall outcome in terms of survival, quality of life, speech, deglutition and aesthetics.

Supplementary Information The online version contains supplementary material available at <https://doi.org/10.1007/s12070-022-03121-1>.

Acknowledgements I would like to express my gratitude towards the Department of Pathology, Department of Microbiology, Department of Radiodiagnosis and Department of Plastic and reconstructive surgery in Mahatma Gandhi University of medical sciences and technology

(MGUMST) for supporting us in carrying out this research.

Funding No Funding was obtained.

Declarations

Conflict of Interest There is No conflict of interest pertaining to this study.

Ethical Approval All procedures performed in the study involving human subjects were in accordance with the ethical standards of the institutional and national research committee and with the 1964 Helsinki declaration and its later amendments or comparable ethical standards.

Informed Consent Informed consent was obtained from all participants included in the study. They were informed and explained in their language about the disease in detail. Its progression and cause. The future course of disease. All the patients were explained in detail about the effect and side-effects of Amphotericin-B, Posaconazole, its dosing and cost. They were explained in detail about the surgery including the resection, its morbidity, rare chance of mortality, intra-operative frozen and given an option of opting to undergo reconstruction using autologous tissue in the form of flap in the same sitting (to which all of them approved). They were informed about the donor site morbidity and chances of flap failure. They were explained and given option of using a prosthesis verses flap, explaining the merits and demerits of each. They were also informed about the post-operative care and treatment. The probability of disease recurrence and its poor overall survival with residual morbidity was also explained. They were explained about the outcome in case they do not wish to undergo the treatment. ICU and ventilator consent was taken for each patient. Death on table consent was taken for each patient. Only after the patient and his relatives fully understood the details and gave consent for the surgery, they underwent complete multi-speciality check-up. Pre- Anaesthetic approval. Following which surgery was performed.

References

1. Raut A, Huy NT (2021) Rising incidence of mucormycosis in patients with COVID-19: another challenge for India amidst the second wave? *Lancet Respir Med* 9(8):e77
2. L de HS, A A-I KV (2019) A Revised Species Concept for Opportunistic *Mucor* Species Reveals Species-Specific Antifungal Susceptibility Profiles. *Antimicrob Agents Chemother* 63(8):00653–00619
3. Honavar SG, Code, *Mucor* (2021) Guidelines for the diagnosis, staging and management of rhino-orbito-cerebral mucormycosis in the setting of COVID-19. *Indian J Ophthalmol* 69(6):1361–1365
4. Cornely OA, Alastruey-Izquierdo A, Arenz D, Chen SCA, Dannaoui E, Hochhegger B et al (2019) Global guideline for the diagnosis and management of mucormycosis: an initiative of the European Confederation of Medical Mycology in cooperation with the Mycoses Study Group Education and Research Consortium. *Lancet Infect Dis* 19(12):e405–e421
5. G SA, O L, Tj ER, Dp W (2012) K. Epidemiology and clinical manifestations of mucormycosis. *Clin Infect Dis.* ;54(June, Suppl. 1)
6. Costa H, Zenha H, Sequeira H, Coelho G, Gomes N, Pinto C et al (2015) Microsurgical reconstruction of the maxilla: Algorithm and concepts. *J Plast Reconstr Aesthet Surg* 68(5):e89–104
7. Rogers SN, Lowe D, McNally D, Brown JS, Vaughan ED (2003) Health-related quality of life after maxillectomy: a comparison

- between prosthetic obturation and free flap. *J Oral Maxillofac Surg* 61(2):174–181
8. Alam D, Ali Y, Klem C, Coventry D (2016) The evolution of complex microsurgical midface reconstruction: A classification scheme and reconstructive algorithm. *Facial Plast Surg Clin North Am* 24(4):593–603
 9. Brown JS, Shaw RJ (2010) Reconstruction of the maxilla and midface: introducing a new classification. *Lancet Oncol* 11(10):1001–1008
 10. Yetzer J, Fernandes R (2013) Reconstruction of orbitomaxillary defects. *J Oral Maxillofac Surg* 71(2):398–409
 11. Vincent A, Burkes J, Williams F, Ducic Y (2019) Free flap reconstruction of the maxilla. *Semin Plast Surg* 33(1):30–37
 12. Cordeiro PG, Chen CM (2012) A 15-year review of midface reconstruction after total and subtotal maxillectomy: part II. Technical modifications to maximize aesthetic and functional outcomes. *Plast Reconstr Surg* 129(1):139–147
 13. Chana JS, Odili J (2010) Perforator flaps in head and neck reconstruction. *Semin Plast Surg* 24(3):237–254
 14. Palacios JJ, Hanson EV, Rendon MAM, Infante R-SL (2019) Reconstruction of head and neck mucormycosis: A literature review and own experience in immediate reconstruction. *J Reconstr Microsurg Open* 04(02):e65–72
 15. Parvati R, Subbalaxmi MV, Srikanth R, Sajani P, Koteswara Rao RV (2021) Is single-stage microvascular reconstruction for facial mucormycosis safe? *Indian J Plast Surg* 54(2):130–137

Publisher's Note Springer Nature remains neutral with regard to jurisdictional claims in published maps and institutional affiliations.

Springer Nature or its licensor holds exclusive rights to this article under a publishing agreement with the author(s) or other rightsholder(s); author self-archiving of the accepted manuscript version of this article is solely governed by the terms of such publishing agreement and applicable law.