

Management of early group A streptococcus fasciitis by imaging-guided percutaneous drainage

Saman Fakheri, MD, George Vatakencherry, MD, and Townson Tsai, MD

Group A streptococcus (GAS) is associated with a spectrum of soft-tissue infections that include toxic shock syndrome, myositis, and necrotizing fasciitis (1-3). The mainstay of therapy for invasive GAS soft-tissue infections is surgical exploration and debridement, as penicillin treatment alone is associated with a high morbidity and mortality (4). We report a case that suggests that imaging-guided percutaneous drainage may have a role in the treatment of some cases of GAS fasciitis, and may preclude the need for surgical intervention.

Case report

A 40-year-old man with no significant medical history presented with severe left-sided abdominal pain, and associated nausea and vomiting. The pain began in the groin five days prior after having taken a large step to avoid tripping. Fevers, rigors, and dysuria with dark-colored urine followed development of the pain. On admission, the patient had a temperature of 103.3 F, pulse 160 beats/min, blood pressure 102/71 mm Hg, and a respiratory rate of 28 with 92% oxygen saturation by finger oximetry on room air. Examination revealed marked tenderness over the left abdomen and flank with left costovertebral angle tenderness. No overlying erythema or warmth of the skin was appreciated. The remainder of the abdomen was mildly distended but without hepatosplenomegaly, rebound tenderness, or guarding. Initial blood tests showed a WBC count of 8,600/ μl , serum creatinine of 2.7 mg/dL, total

bilirubin of 1.8 mg/dL and alanine aminotransferase 66 U/L. The urinalysis was unremarkable. Blood cultures were taken and the patient was begun on empiric piperacillin-tazobactam for presumed intra-abdominal sepsis versus pyelonephritis.

A CT scan was remarkable for a retroperitoneal fluid collection medial to the left internal oblique muscle extending into the pelvic extraperitoneal space and medial paraspinous musculature (Fig. 1,A-B). The fluid tracked

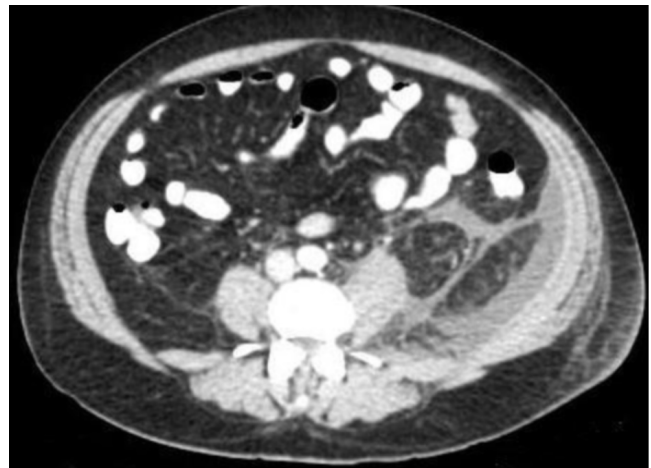


Figure 1A. 40-year-old man with group A streptococcus fasciitis. Axial CT at presentation shows fascial edema with fluid collection.

Citation: Fakheri S, Vatakencherry G, Tsai T. Management of early group A streptococcus fasciitis by imaging-guided percutaneous drainage. *Radiology Case Reports*. [Online] 2008;3:227.

Copyright: © 2008 The Authors. This is an open-access article distributed under the terms of the Creative Commons Attribution-NonCommercial-NoDerivs 2.5 License, which permits reproduction and distribution, provided the original work is properly cited. Commercial use and derivative works are not permitted.

Saman Fakheri, M.D. (Email: samanfakheri@yahoo.com), is at Kaiser Permanente Los Angeles Medical Center, Los Angeles, CA, United States of America. George Vatakencherry, M.D. (Email: gvataken@hotmail.com), is in the Department of Interventional Radiology, Kaiser Permanente Los Angeles Medical Center, Los Angeles, CA, United States of America. Townson Tsai, M.D. (Email: townson.x.tsai@kp.org), is in the Department of Infectious Disease, Kaiser Permanente Los Angeles Medical Center, Los Angeles, CA, United States of America.

Competing Interests: The authors have declared that no competing interests exist.

DOI: 10.2484/rcr.v3i4.227

Management of early group A streptococcus fasciitis by imaging-guided percutaneous drainage

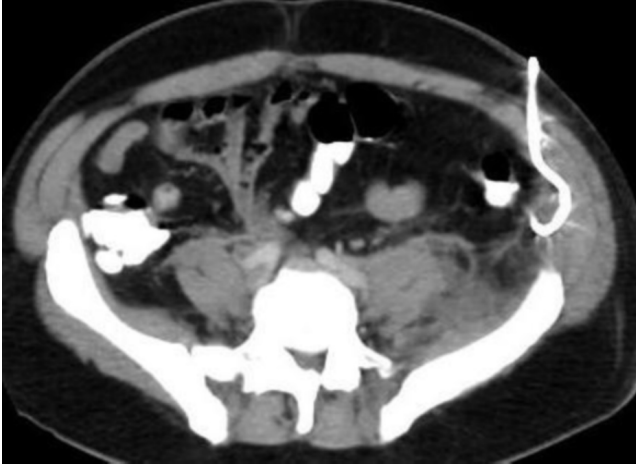


Figure 1B. 40-year-old man with group A streptococcus fasciitis. Coronal CT reformation shows retroperitoneal and extraperitoneal fluid along the left flank extending into the abdomen and pelvis along fascial planes.

along fascial planes with associated fascial edema. No abnormalities of the kidneys and intestines were noted. The patient was observed in the intensive care unit, where tachycardia and pain persisted with frequent febrile episodes. The WBC increased to over 15,000/ μl ; however, the patient remained hemodynamically stable and was breathing comfortably on room air. Blood cultures quickly grew group A streptococcus; the patient's antibiotic was changed to ceftriaxone and clindamycin. The patient's abdomen was

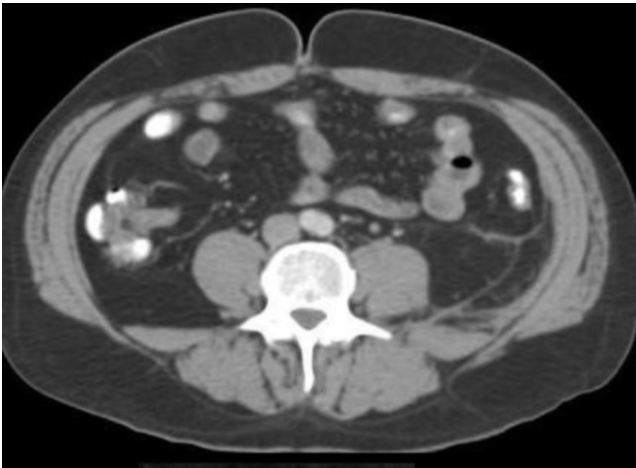


Figure 2A. 40-year-old man with group A streptococcus fasciitis. Axial CT following CT-guided catheter placement shows drain in place.

less distended, but he continued to have paresthesia on the left abdomen, flank, and groin. On exam, pitting edema of the involved area developed without erythema, warmth, or bullae formation.

A repeat CT scan performed on hospital day five showed persistence of fluid along the left flank musculature and fascial planes. In the setting of GAS bacteremia, these radiological findings were worrisome for an invasive soft-tissue infection. The severity of the infection, as evidenced

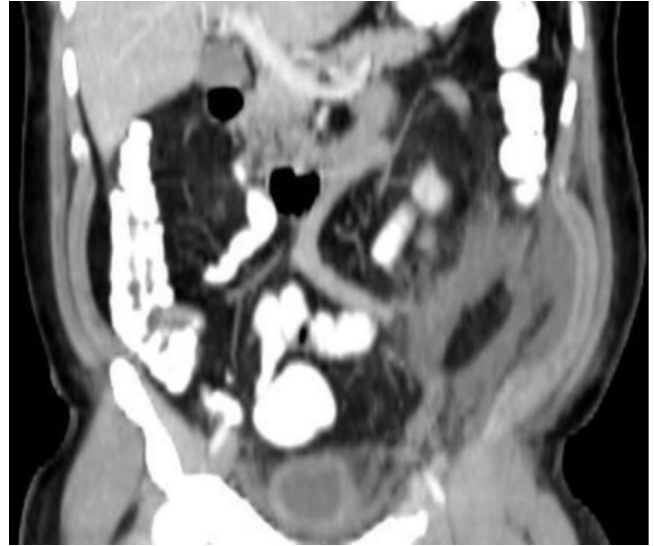

Figure 2B. 40-year-old man with group A streptococcus fasciitis. Coronal CT reformation following CT-guided catheter placement shows drain in place.

by systemic toxicity with azotemia and liver involvement, furthered this suspicion and raised awareness of possible progression to necrotizing fasciitis and toxic shock syndrome. The patient was monitored closely in the intensive care unit for any signs or symptoms of disease progression. Our surgery team was hesitant to explore the area in the operating arena, as the patient remained hemodynamically stable and did not appear perilously ill. General surgery consultants evaluated the patient and followed him with no plans for operation. As the patient remained febrile and continued to have paresthesia, however, it became clear that drainage would be necessary. We turned to our interventional radiology colleagues, who shared our concern for possible progression to necrotizing fasciitis.

At this point, the interventional radiology consultants, under CT guidance, placed a drainage catheter into the fluid collection along the left oblique musculature and fascial planes (Fig. 2). Turbid yellow fluid was obtained, and analysis revealed a cell count of 31,400 WBC (95% PMNs). A gram stain showed many PMNs with no organisms, and cultures yielded no growth.

The patient had immediate pain relief and fever resolution after drain placement. Output was brisk from the drain and persisted for one week, after which a CT scan showed significant improvement in the amount of fluid (Fig. 3). There was complete renal recovery; the bilirubin and alanine aminotransferase also normalized. The patient was discharged with home infusion of ceftriaxone. Initial ESR

Management of early group A streptococcus fasciitis by imaging-guided percutaneous drainage

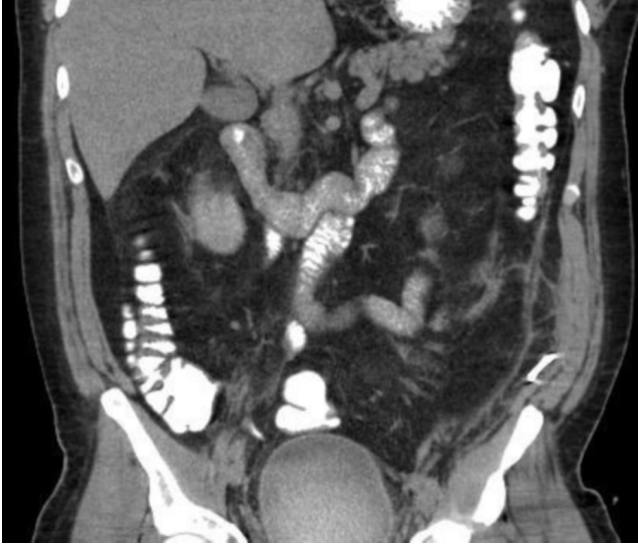

Figure 3. 40-year-old man with group A streptococcus fasciitis. Coronal CT reformation, one week after CT-guided percutaneous drain placement, shows decreased fluid collection.

was elevated and was used as a marker of improvement. Based on weekly levels and clinical exam, the patient was continued on therapy for six weeks. After eight weeks, a follow-up CT showed near resolution of fascial edema and fluid (Fig. 4). The patient made a full recovery.

Discussion

Group A streptococcus (GAS) is associated with a spectrum of skin and soft-tissue infections from erysipelas and cellulitis to myositis and necrotizing fasciitis. In situations where there is minimal cutaneous involvement, the diagnosis can be challenging, and direct observation guides the decision for simple drainage, radical debridement, or amputation. Initially, it can be difficult to distinguish between a cellulitis and a necrotizing fasciitis, with the average time to diagnosis being two to three days—with some cases taking up to six weeks to diagnose (5). Further, case reports of subacute necrotizing fasciitis presenting initially as an indolent infection with little to no systemic signs have been previously made (6).

We suggest that the slow progression of disease in our case may be explained by the particular medical therapy employed. The agents used were ceftriaxone and clindamycin, the latter of which is known to inhibit protein synthesis and production of bacterial toxins and surface proteins. These bacterial components and toxins such as M-protein, streptolysins O and S, and the family of streptococcal pyrogenic exotoxins, as well as several unique superantigens, are felt to directly mediate cytokine production and streptococcal toxic shock syndrome. Inhibition of these cytotoxic mediators may have slowed the usual rapidity of the process. The duration of antibiotic therapy was quite long for a case

of GAS soft-tissue infection; however, the ESR elevations persisted for well over one month. It is a matter of practice in infectious diseases to follow ESR, once elevated, to lower levels before pronouncing completion of therapy. The presence of damaged or necrotic tissues and the body's process of dealing with such could account for the prolonged course.

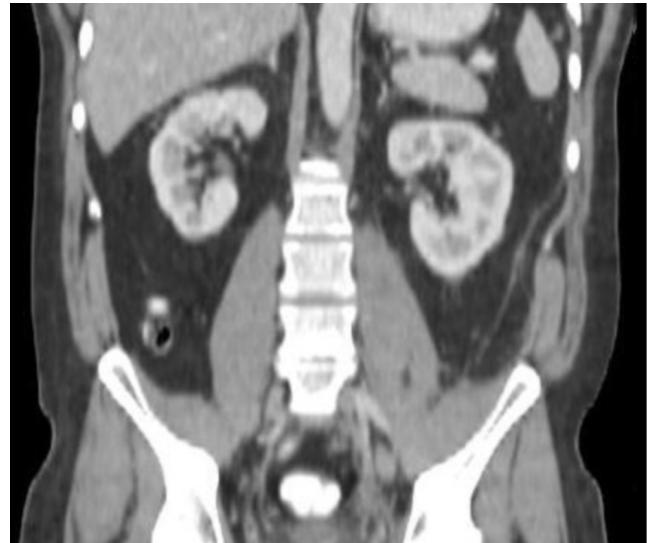
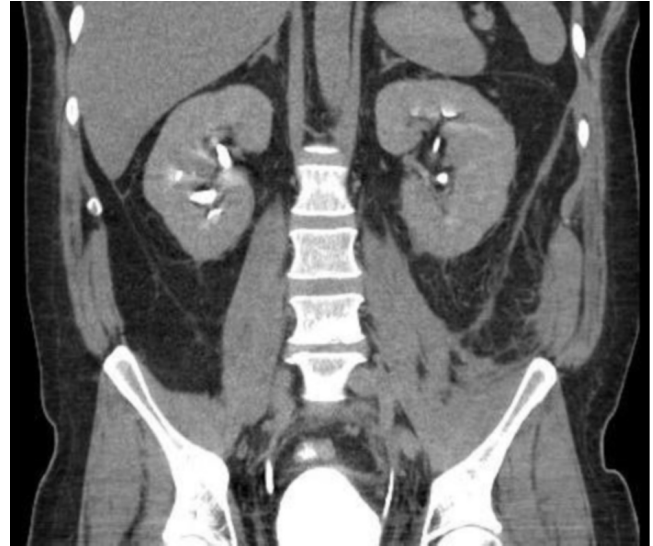

Figure 4. 40-year-old man with group A streptococcus fasciitis. Axial CT (top) and coronal reformation (above), eight weeks after drainage placement, show near resolution of fascial edema and fluid.

The radiologic findings of thickened fascia, fluid collection along deep fascial sheaths, and extension of edema into the intramuscular septa and muscles that were seen on CT are consistent with necrotizing fasciitis (7). These findings, however, are more sensitive than specific, and can only suggest the diagnosis of necrotizing fasciitis. Although the

Management of early group A streptococcus fasciitis by imaging-guided percutaneous drainage

presence of soft-tissue gas dissecting along fascial planes on CT imaging is specific for necrotizing fasciitis, this finding is not observed in all cases (7), as infection may be caused by non-gas-forming organisms or an early stage of disease caused by gas-forming-organisms exposed to early antimicrobial treatment. Other imaging modalities that may be used to help diagnose necrotizing fasciitis include plain radiography, ultrasonography, and MRI. Radiographs can help identify gas, which is a very specific finding but not very sensitive in patients with necrotizing fasciitis (4). Further, gas in the deeper fascia is rarely identified on plain radiography. Sonography demonstrates similar findings to cellulitis, often with the additional involvement of deep fascial planes between muscle bundles (8). Although sonography of the scrotum has been used in the diagnosis of Fournier gangrene (9), its role in the evaluation of other areas of the body is not known. MRI can be overly sensitive, as it tends to overestimate deep-tissue involvement and does not distinguish necrotizing fasciitis from cellulitis or inflammation (10). Further MRI may not adequately delineate findings of air along the fascial planes.

Definitive diagnosis of necrotizing fasciitis in settings without cutaneous involvement is made by direct visualization at time of surgery, histopathologic characterization of tissue samples, and (less commonly) measurements of muscle-compartment pressures. Given the nonspecific imaging findings and relative lack of cutaneous involvement, we cannot be definitive in the diagnosis. However, the severity of the infection as evidenced by systemic toxicity and its refractoriness to early and appropriate antimicrobial therapy raise concern that if the infection was not necrotizing fasciitis, it would have soon progressed to it if not for drainage by interventional radiology.

GAS bacteremia is often secondary to a primary site of infection usually involving the skin and soft tissues (11, 12). Recent series suggest that persons of all ages may be afflicted with invasive GAS infections, and most are not immunosuppressed. Risk factors associated with severe GAS infections include minor trauma and injuries resulting in hematoma, bruising, or muscle strain (2), the latter of which was likely the cause in this case. Although most GAS infections, such as pharyngitis, erysipelas, impetigo, and cellulitis remain susceptible to B-lactam antibiotics (3), invasive soft-tissue infections such as necrotizing fasciitis and myositis require exploration and debridement, as penicillin treatment is associated with high morbidity and mortality (1, 2, 13). The successful use of interventional radiology in a suspected case of early necrotizing fasciitis has not been previously reported. We suggest that early intervention by such means may lead to less invasive procedures in deep soft-tissue infections due to GAS and other organisms. Of course, surgery is still the mainstay for overwhelming life- and limb-threatening soft-tissue infections. However, imaging-guided percutaneous catheter drainage may provide an additional option to medical therapy and/or surgery in the future.

References

- 1 Stevens DL. Invasive group A streptococcus infections. *Clin Infect Dis*. 1992 Jan;14(1):2-11. [\[PubMed\]](#)
- 2 Stevens DL, Tanner MH, Winship J, Swartz R, Ries KM, Schlievert PM, Kaplan E. Severe group A streptococcal infections associated with a toxic shock-like syndrome and scarlet fever toxin A. *N Engl J Med*. 1989 Jul 6;321(1):1-7. [\[PubMed\]](#)
- 3 Bisno AL, Stevens DL. Streptococcal infections of skin and soft tissues. *N Engl J Med*. 1996 Jan 25;334(4):240-5. [\[PubMed\]](#)
- 4 Anaya DA, Dellinger EP. Necrotizing soft-tissue infection: diagnosis and management. *Clin Infect Dis*. 2007 Mar 1;44(5):705-10. Epub 2007 Jan 22. [\[PubMed\]](#)
- 5 Wysoki MG, Santora TA, Shah RM, Friedman AC. Necrotizing fasciitis: CT characteristics. *Radiology*. 1997 Jun;203(3):859-63. [\[PubMed\]](#)
- 6 Wong CH, Wang YS. What is subacute necrotizing fasciitis? A proposed clinical diagnostic criteria. *J Infect*. 2006 Jun;52(6):415-9. [\[PubMed\]](#)
- 7 Fayad LM, Carrino JA, Fishman EK. Musculoskeletal infection: role of CT in the emergency department. *Radiographics*. 2007 Nov-Dec;27(6):1723-36. [\[PubMed\]](#)
- 8 Struk DW, Munk PL, Lee MJ, Ho SG, Worsley DF. Imaging of soft tissue infections. *Radiol Clin North Am*. 2001 Mar;39(2):277-303. [\[PubMed\]](#)
- 9 Begley MG, Shawker TH, Robertson CN, Bock SN, Wei JP, Lotze MT. Fournier gangrene: diagnosis with scrotal US. *Radiology*. 1988 Nov;169(2):387-9. [\[PubMed\]](#)
- 10 Schmid MR, Kossman T, Duester S. Differentiation of necrotizing fasciitis and cellulitis using MR imaging. *AJR Am J Roentgenol*. 1998 Mar;170(3):615-20. [\[PubMed\]](#)
- 11 Kiska DL, Thiede B, Caracciolo J, Jordan M, Johnson D, Kaplan EL, Gruninger RP, Lohr JA, Gilligan PH, Denny FW Jr. Invasive group A streptococcal infections in North Carolina: epidemiology, clinical features, and genetic and serotype analysis of causative organisms. *J Infect Dis*. 1997 Oct;176(4):992-1000. [\[PubMed\]](#)
- 12 Demers B, Simor AE, Vellend H, Schlievert PM, Byrne S, Jamieson F, Walmsley S, Low DE. Severe invasive group A streptococcal infections in Ontario, Canada: 1987-1991. *Clin Infect Dis*. 1993 Jun;16(6):792-800. [\[PubMed\]](#)
- 13 Martin PR, Høiby EA. *Streptococcal serogroup A epidemic in Norway 1987-1988*.