



Loss of vision after transurethral resection of prostate: A case report

Sepideh Emami ^a, Fatima Alfaham ^b, Behnam Shakiba ^{c,*}, Mehran Moghimian ^c, Zahra Mirzaasgari ^d

^a Department of Cardiology, Firoozgar Hospital, Iran University of Medical Sciences, Tehran, Iran

^b Student Research Committee, Faculty of Medicine, Iran University of Medical Sciences, Iran

^c Department of Urology, Firoozgar Hospital, Iran University of Medical Sciences, Tehran, Iran

^d Department of Neurology, Firoozgar Hospital, Iran University of Medical Sciences, Tehran, Iran

ARTICLE INFO

Keywords:

Paradoxical embolism

Urological complication

Case report

Transurethral resection of prostate

ABSTRACT

The overall complication rate of Transurethral resection of prostate (TURP) is about 11.1%. Amongst all complications, ocular complications are one of the rarest. In this paper, we present a case of vision loss due to paradoxical embolism as a rare complication following TURP. Ocular complications are very rare in urological surgeries but can happen due to paradoxical embolism following patent foramen ovale. Therefore, we recommend the early diagnosis and treatment of PFO prior to this type of surgery.

Introduction

Transurethral resection of prostate (TURP) is a routine and standard surgery for patients with significant prostate enlargement due to benign prostatic hyperplasia. The overall complication rate of TURP is about 11.1%. The most common surgical complications include failure to void (5.8%), surgical revision (5.6%), urinary tract infection (3.6%) and bleeding (2.9%).^{1,2}

Although deep vein thrombosis (DVT) is a known complication following urologic surgeries, paradoxical embolism is a rare consequence.

In this paper, we present a case of vision loss due to paradoxical embolism, a rare complication after TURP.

Case presentation

A 71-year-old Iranian man was referred to our clinic with recurrent urinary retention despite previous medical therapy; he had long term lower urinary tract symptoms. On physical examination, his bladder was palpable, non-tender and tense. On digital rectal examination, he had a grossly enlarged prostate with benign structure. Rectal sphincter tone was normal. He had no history of previous surgery, diabetes mellitus or neurological diseases. The results of laboratory studies including blood hemoglobin, hematocrit, serum electrolytes and renal function tests were within normal limits. The patient had no history of coagulation disorders or anticoagulant therapy. Bladder catheterization was

performed returning 800 ml of urine. Abdominal ultrasound imaging revealed a bladder with a thickened wall, mild bilateral hydronephrosis and an enlarged prostate (55 ml in volume). Uroflowmetry was not possible because the patient could not void.

The operation was done under spinal anesthesia with monopolar TURP. Distilled water was used as the irrigation fluid for this purpose. The surgery was uneventful and the operation time was about 55 min. In the first 12 h after surgery the patient performed the dorsiflexion and plantarflexion exercises, then, he ambulated. The patient was discharged after 2 days with a urethral catheter which was removed in the outpatient clinic 5 days after surgery with no complications afterwards. He voided with no difficulty and his post-void residue was about 25 ml. One week after surgery, the patient was once again referred to our hospital with left lower limb pain and edema along with reduced vision in both eyes.

Color Doppler ultrasonography showed Deep Venous Thrombosis (DVT) of the left lower extremity. Brain CT scan revealed acute bilateral occipital ischemia which was accounted responsible for the loss of vision (Fig. 1). Due to this issue and the diagnosis of arterial embolism, echocardiography was performed which reported a Patent Foramen Ovale (PFO). Anticoagulant therapy was administered and after several days, his visual acuity increased. The patient was then discharged and referred for surgical closure of the PFO.

* Corresponding author. Department of Urology, Firoozgar Hospital, Iran University of Medical Sciences, Valadi St., Valiasr Ave., 1593748711, Tehran, Iran.
E-mail address: Shakiba.b@iums.ac.ir (B. Shakiba).

<https://doi.org/10.1016/j.eucr.2021.101739>

Received 12 May 2021; Received in revised form 27 May 2021; Accepted 28 May 2021

Available online 2 June 2021

2214-4420/© 2021 Published by Elsevier Inc. This is an open access article under the CC BY-NC-ND license (<http://creativecommons.org/licenses/by-nc-nd/4.0/>).

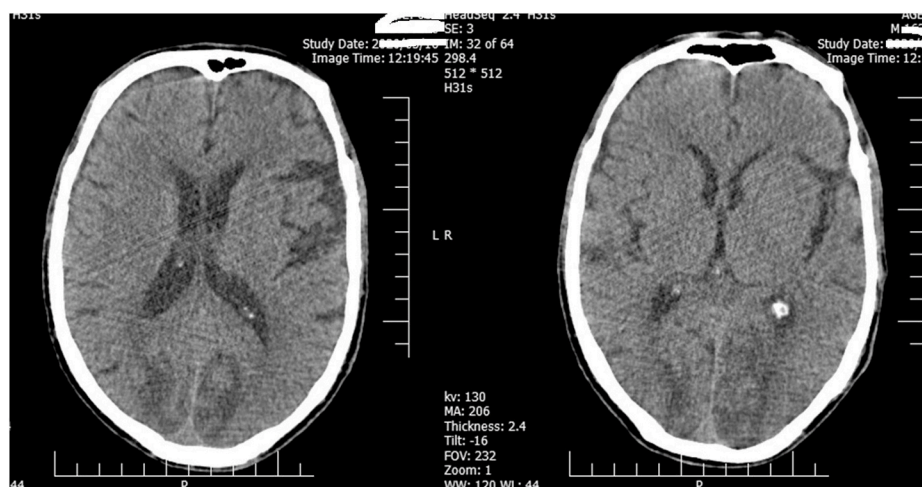


Fig. 1. Brain CT scan revealed an acute bilateral occipital ischemia.

Discussion

Despite deep vein thrombosis being a common complication following surgery, paradoxical embolism is a rare complication that usually occurs due to patent foramen ovale.³ DVT of the lower limb can pass through the PFO and subsequently cause arterial embolism in terminal branches. Nevertheless, central retinal artery embolism or occipital cerebrovascular accident (CVA) is a very rare complication following urological surgeries.⁴

Foramen oval is a hole between the right and left atrium that closes after birth. PFO is a flap like valve between the two atria. In fetal life the oxygenated blood of the umbilical veins reaches into the systemic circulation via foramen ovale, whereas most of the superior vena cava flow crosses the tricuspid valve and enters into the right ventricle. At birth with the first independent respiration of the neonate, the reduced pulmonary vascular resistance and increased left atrial pressure contribute to flap closure. The foramen oval flap is fused in 75% of children by the age of two, whereas the remaining 25% have a PFO for the rest of their life.^{3,5} Although most individuals with PFO remain asymptomatic, it is a potential pathway for paradoxical emboli from the venous system to the systemic circulation, whereas in about 40–50% of cases with paradoxical emboli a patent foramen ovale is diagnosed.⁴ Paradoxical emboli start with thrombi formation in the lower extremities, venous system and occasionally the pelvic veins, which transfer through the patent foramen ovale (PFO) or other right to left communications and enter into the systemic circulation; they may lead to stroke or peripheral emboli.⁵

A PFO may have either a transient or permanent right to left shunt. Any maneuver that increases the intra-abdominal pressure leads to increased right atrial pressure and transient right to left gradients; e.g. a strain for defecation, coughing or lifting heavy objects.⁴ PFO is also known to increase the risk of migraine headaches, platypnea orthodeoxia syndrome (a rare condition with oxygen desaturation and dyspnea in the upright position), decompression sickness in divers and recently acute mountain sickness.

Evaluation of PFO is indicated when the possibility of paradoxical embolism is present, especially in the presence of deep venous thrombosis. Transesophageal echocardiography (TEE) is the definite diagnostic test; with the use of aerated saline it has a sensitivity and

specificity of about 100%. Due to the semi-invasive nature of this procedure, it is not suitable for screening.³

Transthoracic echocardiography (TTE) with agitated saline injection into peripheral veins is the first step for PFO diagnosis and screening. Visualization of contrast bubbles in the left atrium within three heart beats after right atrial opacification supports the presence of an intracardiac shunt at the atrial level. Transthoracic echocardiography has a reported sensitivity ranging from 32% to 100%, specificity from 55% to 97% and false-negative findings ranging from 18% to 43%.⁵

Nevertheless, false negative cases are of greatest concern in TTE study as it is generally the first modality of choice for screening a PFO, especially in preoperative examinations.

According to the results of the aforementioned studies and the high rate of false negative results in TTE, in the present case we missed the PFO in the preoperative cardiovascular consult and TTE examination. As a result, following the deep vein thrombosis and paradoxical embolism, the patient developed a cerebrovascular accident. Taken together, the early detection and treatment of arterial embolism and the subsequent diagnosis of PFO was the highlight of our case study.

Conclusion

Ocular consequences are very rare in urological surgeries but may occur due to paradoxical embolism following deep vein thrombosis.

References

1. Langan RC. Benign prostatic hyperplasia. *Prim Care Clin Off Pract.* 2019;46(2): 223–232.
2. Reich O, Gratzke C, Bachmann A, et al. Morbidity, mortality and early outcome of transurethral resection of the prostate: a prospective multicenter evaluation of 10,654 patients. *J Urol.* 2008;180(1):246–249.
3. Donat R, Mancey-Jones B. Incidence of thromboembolism after transurethral resection of the prostate (TURP)—a study on TED stocking prophylaxis and literature review. *Scand J Urol Nephrol.* 2002;36(2):119–123.
4. Homma S, Messé SR, Rundek T, et al. Patent foramen ovale. *Nat. Rev. Dis. Prim.* 2016; 2:15086.
5. Stafford MB, Bagley JE, DiGiacinto D. Comparison of transthoracic echocardiography, transesophageal echocardiography, and transcranial Doppler in the detection of patent foramen ovale as the etiology for cryptogenic stroke. *J Diagn Med Sonogr.* 2019; 35(2):127–133.