

Slit-lamp measurement of anterior chamber depth and its agreement with anterior segment optical coherence tomography and Lenstar LS 900 in pseudoexfoliation and normal eyes

Vanita Pathak Ray, Smitha B Ramesh¹, Varsha Rathi²

Purpose: There is a considerable lack of awareness of slit-lamp measurement of anterior chamber depth (ACD) by the Redmond Smith method (SACD) in present day-to-day clinical practice, which may provide rapid assessment in pseudoexfoliation (PXF) when assessing for angle closure and planning for cataract surgery. This assumes importance not only in outreach clinics but also in the ongoing pandemic caused by the highly contagious novel coronavirus, where social distancing is advocated to contain the spread. We aimed to compare the axial ACD in PXF and normal patients by SACD, and its agreement with the anterior segment optical coherence tomography (ASOCT) and LenstarLS-900. **Methods:** A prospective comparative observational study was done at a tertiary eye care hospital. A PXF group and a normal group of controls were recruited. All eyes were phakic with normal cornea. Any eye with previous intraocular/refractive surgery and cause of other secondary or uncontrolled glaucoma was excluded. SACD was measured clinically via slit-lamp method and also via ASOCT and Lenstar; agreement between the methodologies was plotted. **Results:** Fifty patients were recruited in each group. Mean age was 66.82 ± 4.88 years in PXF patients and 65 ± 5.46 years in controls ($P = 0.2$). ACD was found to be greater in controls compared with the PXF patients; this difference was statistically significant ($P < 0.001$) across all methodologies. A good agreement with narrow 95% limits of agreement was found between these methodologies. **Conclusion:** Redmond Smith slit-lamp methodology of estimating the axial ACD is recommended as a rapid, quantifiable, noncontact screening technique during routine examination, especially in primary outreach centers, and is also advantageous during the ongoing pandemic by reducing expendable investigations.

Key words: ACD, ASOCT, Lenstar LS 900, noncontact technique, pseudoexfoliation, Redmond Smith, slit-lamp anterior chamber depth measurement

Pseudoexfoliation (PXF) syndrome is an age-related systemic microfibrilopathy wherein both intraocular and extraocular deposits occur (in the skin and visceral organs), suggesting that it may be an ocular manifestation of a systemic disorder.^[1] The prevalence rate of PXF syndrome in different populations shows extensive variations: none in the Eskimos,^[2] 1.6% in a southeastern U.S. population,^[3] 1.8% in the Framingham Eye Study,^[4] 5% to 25% in the Scandinavian countries,^[2,5] and 38% in the Navajo Indians.^[6] Population-based estimates in the Blue Mountains Eye Study revealed a prevalence rate of 2.3%.^[7] In a hospital-based study of the clinical profile of PXF in South India, PXF glaucoma (PXFG) occurred in 1.9% of eyes, and 4.7% of eyes were glaucoma suspects.^[8] Open-angle glaucoma not only occurs more commonly in eyes with PXF, but its presence has also been recognized as one of the most common identifiable causes of glaucoma.^[9] Overall, glaucoma in PXF has not only a more serious clinical course but also a worse prognosis compared with primary open-angle glaucoma (POAG).

However, patients with PXF may be predisposed to developing angle-closure glaucoma too.^[10]

On the other hand, zonular weakness and poor pupillary dilatation are the primary risk factors for surgical complications in PXF.^[11] Vitreous loss is reported to be five times more common when PXF is present than in patients without PXF (9.0% vs. 1.8%).^[11] Nonetheless, the amount of PXF material present in the eye does not predict the degree of zonular weakness or the risk of developing glaucoma. However, the anterior chamber depth (ACD) has been reported to be a useful predictor of intraoperative complications in eyes with PXF.^[12] Zonular fragility accounts for much of the increased complication rate as the risk of lens dislocation is up to 10 times higher in PXF^[13]; its clinical manifestation is primarily in the form of iridophacodonesis.^[13] Zonular instability has also been implicated in the development of angle closure.^[10] Therefore,

This is an open access journal, and articles are distributed under the terms of the Creative Commons Attribution-NonCommercial-ShareAlike 4.0 License, which allows others to remix, tweak, and build upon the work non-commercially, as long as appropriate credit is given and the new creations are licensed under the identical terms.

For reprints contact: WKHLRPMedknow_reprints@wolterskluwer.com

Cite this article as: Pathak Ray V, Ramesh SB, Rathi V. Slit-lamp measurement of anterior chamber depth and its agreement with anterior segment optical coherence tomography and Lenstar LS 900 in pseudoexfoliation and normal eyes. Indian J Ophthalmol 2021;69:2469-74.

Access this article online

Website:
www.ijo.in

DOI:
10.4103/ijo.IJO_3738_20

Quick Response Code:



Department of Glaucoma, Centre for Sight, Banjara Hills, ¹L V Prasad Eye Institute, Banjara Hills, ²GPR-International Centre for Advancement of Rural Eyecare L V Prasad Eye Institute, Hyderabad, Telangana, India

Correspondence to: Dr. Vanita Pathak Ray, Centre for Sight, Road No 2, Banjara Hills, Hyderabad - 500 034, Telangana, India. E-mail: vpathakray@gmail.com

Received: 21-Dec-2020

Revision: 06-Mar-2021

Accepted: 09-Apr-2021

Published: 25-Aug-2021

a central ACD of less than 2.5 mm is a probable indicator of zonular instability,^[12] which may not only assist in the detection of angle closure but also serve as a useful predictor of intraoperative complications in eyes with PXF.

ACD represents the distance between the corneal endothelium and the anterior capsule of the crystalline lens. The average depth of ACD in normal individuals is approximately 3 mm.^[14] It can be measured using the slit lamp with relative ease, but awareness of this technique is limited; instead, relatively more expensive technology is used (including the anterior segment optical coherence tomography [ASOCT; Carl Zeiss Meditec, Dublin, CA] and Lenstar-LS900 [Haag-Streit AG, Köniz, Switzerland]), and so its availability in primary care centers in outreach areas in low- to middle-income countries may be limited. Also, clinical estimation of the ACD at the slit lamp seems to have assumed much greater importance during the ongoing pandemic because of “social distancing” being advocated due to the highly contagious novel coronavirus, whereby it is prudent to minimize touch, points of contact, and duration of examination with a patient. Slit-lamp estimation of the ACD may serve as a simple, quantifiable, noncontact technique that may eliminate expendable investigations in certain clinical situations, thereby reducing stay in a hospital/clinical setting and exposure to the aerosolized virus.

Redmond Smith^[15] measured the ACD using the Haag-Streit-900 slit-lamp (Haag-Streit Inc., Köniz, Switzerland) without any extra attachments. Its value is independent of corneal thickness, and the author stated that the axial ACD was estimated with an accuracy of approximately 0.1 mm.^[15]

This study examines the measurement of axial ACD as obtained at the slit lamp via the Redmond Smith method and reports its agreement with that acquired by the ASOCT and Lenstar in PXF and normal eyes.

Methods

This was a prospective, comparative, observational study performed at a tertiary-care eye hospital. Ethics Committee (EC) approval was obtained from the institutional EC; informed consent was obtained from all the participants. Data handling was as per the tenets laid down by the Declaration of Helsinki.

Two groups were recruited – a study group of PXF and a control group.

In the study group, the inclusion criteria were presence of PXF/PXFG (visible gray-white deposits on pupillary margin and anterior surface of the lens) and phakic eyes.

Age- and gender-matched population was recruited as controls. These eyes were phakic with open angles on gonioscopy and absence of glaucoma clinically.

Exclusion criteria in both groups were any history of trauma, corneal abnormalities, intraocular or refractive surgery, any other cause of secondary glaucoma, and uncontrolled intraocular pressure (IOP).

Comprehensive clinical examination was performed for all those recruited – this was done in the following sequence.

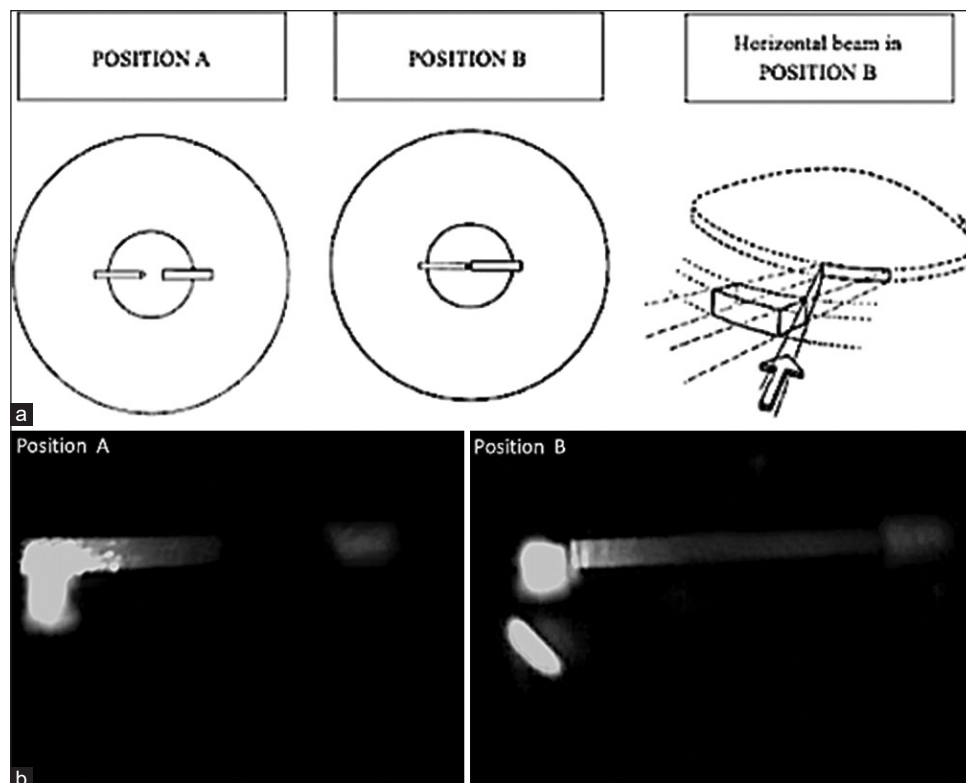


Figure 1: (a) Diagrammatic representation of Positions A and B for clinical assessment of anterior chamber depth at the slit lamp. Courtesy Smith.^[15] (Reproduced from Smith, R.J., A new method of estimating the depth of the anterior chamber. *Br J Ophthalmol.* 1979;63 (4):215-20. Permission Licence no. 4973651427126, dated December 21, 2020). (b) Slit-lamp view of Positions A and B for clinical assessment of anterior chamber depth at the slit lamp

The best-corrected visual acuity (BCVA) for distance and near was documented, followed by slit-lamp examination of the anterior segment (AS) and estimation of the ACD.

Slit-lamp measurement of the ACD by Smith method (SACD):

We followed Redmond Smith's method of ACD measurement, using the Haag-Streit 900 slit-lamp and its calibrated adjustable slit-length facility.^[15] For measurement of the ACD on the right side, the apparatus was arranged so that the slit beam was on the operator's left (the patient's right) and vice versa for the fellow eye. The right eyepiece was used for the right eye and the left one for the left eye. The microscope was aimed such that it was pointing straight ahead at the optical axis of the patient, and the axis of the slit beam was set at 60°, while the patient was instructed to look straight ahead. The apparatus was moved forward by means of the joystick until the slit beam was focused on the cornea. The beam was then set to horizontal; the thickness of the slit is not vitally important. The slit beam was reduced in length by the knurled knob provided. Here two slit images were obtained – a sharp focused slit on the cornea on the left-hand side and a blurred out-of-focus slit image on the anterior lens capsule on the right-hand side with an optically empty gap (Position A) [Fig. 1a Left]. The slit was now lengthened until the gap was just obliterated (Position B) [Fig. 1a Centre]. At this moment, the optical conditions were such that the left-hand edge of the slit image on the cornea (at endothelial level) was coincident with the right-hand edge of the slit image at the anterior lens surface [Fig. 1a. Right]. Fig. 1b depicts the slit-lamp view of Position A and Position B for the clinical assessment of ACD.

The length of the slit was then recorded from the scale. Smith proposed that multiplying this slit length with a factor of 1.4 provided the ACD.

For example, if the slit length is read as 1.8 from the scale, after the gap is obliterated in Position B, then the ACD is calculated as $1.8 \times 1.4 = 2.52$ mm.

The average of three readings via SACD was noted by an independent masked observer, and each observation was completed within a few seconds.

The ACD was also obtained via ASOCT (AACD) and Lenstar (LACD). Both are noncontact optical imaging modalities; the former uses low-coherence interferometry, whereas the latter obtains totally automated complete optical biometry using optical low-coherence reflectometry (OLCR). One Lenstar scan consists of 16 individual full eye scans and four individual keratometric scans, taken on two concentric rings along the patient's visual axis.

The ASOCT scans were obtained and followed by the Lenstar LS900 biometer scans. The AACD was measured by marking the boundaries of the posterior surface of the cornea and the anterior surface of the lens by use of proprietary calipers.

Three readings were taken by a single masked observer for all.

Ocular examination was then completed by recording the IOP via Goldmann Applanation tonometry followed by gonioscopy with Sussman 4 mirror, in dim ambient illumination with a small beam not crossing the pupil and a narrow width (3 mm × 1 mm) at high magnification. Finally, a dilated fundus examination was done for each patient with

the 78D or 90D lens and an indirect ophthalmoscopy with the 20D lens.

Statistical method

Statistical analyses were performed using the R software (Version 2.12). To check whether the SACD was equivalent to AACD (and LACD) or not, we performed a test of equivalence (one-sided Wilcoxon signed-rank test). The ACD was compared between the cases and the normal controls by using one-way ANOVA (analysis of variance). A *P* value of < 0.05 was considered statistically significant. Bland–Altman plots were constructed to evaluate the agreement between techniques. The sample size was calculated based on a pilot study of 10 eyes of SACD versus AACD and SACD versus LACD. With the alpha set at 0.8, the power at 0.05, and an equivalence of 0.1, a sample size of 50 was determined in the study group; a size less than 50 was appropriate in the control group.

Results

Fifty patients were recruited in each group as per the inclusion and exclusion criteria. Mean age of the patients in the study and control groups was 66.82 ± 4.88 years and 65 ± 5.46 years, respectively ($P = 0.2$). In the study group, males accounted for 33 and females 17, and in the normal group there were 30 males and 20 females ($P = 0.534$, Chi squared test). PXF was unilateral in 11 participants (22%) and bilateral in 39 participants (78%). When PXF was bilateral, only the right eye was included in the study. Seven eyes (14%) in the PXF group had closed angles; all eyes in the normal group were open. All the patients in the PXF group and all but one patient in the normal controls had cataract. Slit-lamp assessment of the ACD (three observations) did not exceed 30 seconds. The ACD was found to be greater in controls compared with the PXF participants, and this difference was statistically significant ($P < 0.001$) across all methodologies. When the angle-closure eyes were excluded and the data was reanalyzed, the PXF eyes continued to be significantly shallower than the normal eyes in the SACD method (2.63 ± 0.42 mm; $P < 0.001$).

Mean ACD with 95% confidence intervals (CI) are presented in Table 1; Fig. 2 is the graphical representation of the ACD measurements in PXF (study group) and normal controls.

A test of equivalence showed that SACD was equivalent to AACD with an equivalence margin of 0.1 ($P = 0.002$) and also to LACD ($P < 0.001$).

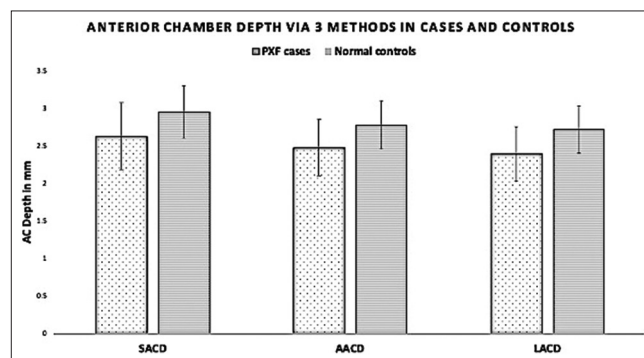


Figure 2: Anterior chamber depth (y-axis) via 3 methods in pseudoexfoliation group (cases) and normal controls

Table 1: Anterior chamber depth (ACD) measurement by three methodologies in pseudoexfoliation group (PXF) and in normal controls

	SACD [†] in mm	AACD [‡] in mm	LACD [§] in mm
Mean (SD)	2.63 (0.46)	2.48 (0.38)	2.40 (0.37)
PXF group	95% CI [2.5, 2.76]	95% CI [2.37, 2.59]	95% CI [2.29, 2.5]
Mean (SD)	2.95 (0.35)	2.78 (0.32)	2.72 (0.31)
Normal controls	95% CI [2.85, 3.04]	95% CI [2.69, 2.87]	95% CI [2.63, 2.81]
ANOVA	$P < 0.001$	$P < 0.001$	$P < 0.001$

SD=Standard deviation, CI=Confidence interval; ANOVA=Analysis of variance. [†]SACD - ACD measurement by Redmond Smith method [‡]AACD - ACD obtained by anterior segment OCT [§]LACD - ACD obtained by Lenstar

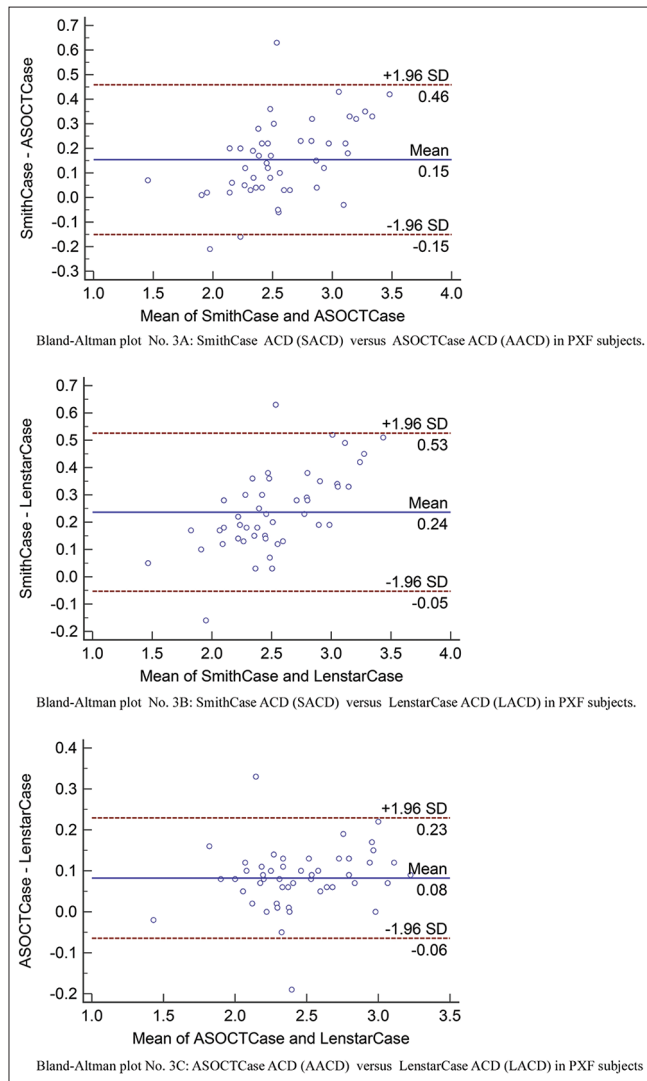


Figure 3: ABC: Bland–Altman plots in pseudoexfoliation (PXF) group. Dashed lines represent the 95% confidence intervals. Solid line represents the mean difference

Bland–Altman plots of PXF and normal controls are shown in Figs. 3 and 4, respectively.

The mean difference in the ACD between SACD and AACD in the PXF group was 0.15 mm, and the 95% limits of agreement (LoA = $\pm 1.96SD$) ranged from -0.15 to 0.46 mm. The mean difference in the ACD between SACD and LACD in PXF

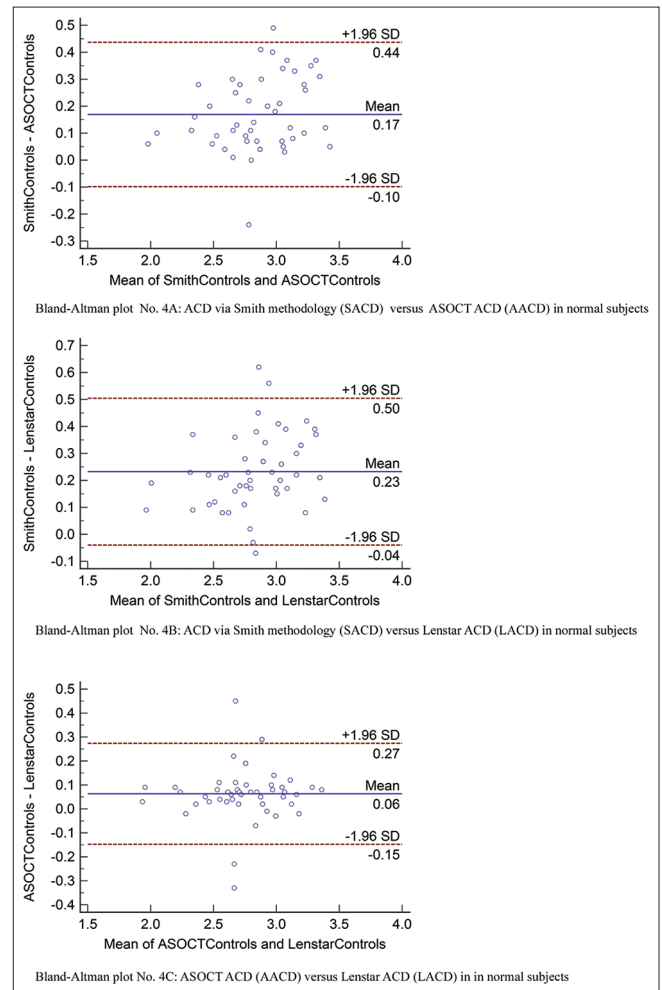


Figure 4: ABC: Bland–Altman plots in normal control group. Dashed lines represent the 95% confidence intervals. Solid line represents the mean difference

was 0.24 mm, the 95% LoA = $\pm 1.96SD$ ranged from -0.05 to 0.53 mm. The mean difference in the ACD between AACD and LACD in PXF was 0.08 mm and the 95% LoA = $\pm 1.96SD$ ranged from -0.06 to 0.23 mm. In controls, the mean difference in the ACD between SACD and AACD was 0.17 mm and the 95% LoA = $\pm 1.96SD$ ranged from -0.10 to 0.44 mm and that between SACD and LACD in controls was 0.23 mm and the 95% LoA = $\pm 1.96SD$ ranged from -0.04 to 0.50 mm. The mean difference in ACD between AACD and LACD in normal controls was 0.06 mm and the 95% LoA = $\pm 1.96SD$ ranged from -0.15 to 0.27 mm.

Discussion

This study shows that the ACD was less in PXF participants when compared with normal controls. Furthermore, this difference was statistically significant across all methodologies ($P < 0.001$). However, the Smith method somewhat overestimated the ACD compared with ASOCT and Lenstar, but virtually all the data are inclusive within the 95% LoA and are evenly distributed in all the Bland–Altman plots, indicating no relationship between the average ACD and interdevice difference. Nonetheless, the agreement for the ACD measure was better between SACD and AACD than with SACD and LACD, agreement being the best between AACD and LACD. In controls too, the agreement was the best between ASOCT and Lenstar.

PXF is the most common identifiable cause of secondary open-angle glaucoma, while the glaucoma associated with it is much more challenging from the management point of view when compared with POAG.^[10] The incidence of angle closure and glaucoma is also relatively high and should not be underestimated in patients with PXF.^[16] However, it also remains undetected at a higher rate,^[17] perhaps because of the wider perception of it being the cause of secondary open-angle glaucoma.

Furthermore, the deposition of PXF on the zonules has implications for cataract surgery and it is important to determine the extent of zonular weakness prior to it. However, the amount of PXF material visible does not seem to correlate with the degree of zonular weakness. Impaired zonular function can cause forward movement of the crystalline lens complex, thus affecting the ACD. Kuchle *et al.*^[12] found an intraoperative complication rate of 13.4% in eyes with an ACD of less than 2.5 mm and only 2.8% in eyes with an ACD of 2.5 mm or greater (a fourfold increased risk of zonular dialysis and/or vitreous loss). The authors therefore suggested that a shallow AC may indicate zonular instability. As such, the ACD can be a useful predictor of intraoperative complications in eyes with PXF. ACD of less than 2.5 mm centrally also poses a significantly higher risk for the presence of angle closure.

Damji and colleagues^[18] described the differences in A-scan and ultrasound biomicroscopy parameters in eyes with PXF and occludable angles (PXFOc), PXF and open angles (PXFOp), and eyes with POAG and concluded that eyes with PXFOc demonstrated lens thickening and shallower central ACD compared to eyes with PXFOp and POAG. This suggests that other than zonular weakness, cataract formation may also contribute to the development of an occludable angle in eyes with PXF.

Our findings are very similar to those reported by Doganay and colleagues^[19] as well as Zheng and colleagues,^[20] although the methodology differed. Doganay *et al.*^[19] evaluated the AS parameters in PXF/G patients with the Pentacam-Scheimpflug imaging system and concluded that the ACD was lower in these eyes when compared with healthy individuals. Zheng *et al.*^[20] did ASOCT analysis in unilateral PXF eyes and showed that such eyes had significantly shallower ACD, and the fellow eyes too had significantly lower ACD than normal controls.

An ACD of 2 mm or less is considered extremely shallow and is at risk from an attack of angle closure after mydriasis.^[12] Hence measurement of ACD is a useful indirect predictor not

only of intraoperative complications but also to identify risk of developing closed-angle glaucoma. Commonly used clinical ACD assessment with the pen light shadow technique as well as the van Herrick method is subjective and lacks a numeric measurement. The sensitivity and specificity of the flashlight test are 45.5% and 82.7%, respectively; for the van Herrick's test, these percentages are 61.9 and 89.3, respectively. Therefore, both the flashlight and van Herrick's tests are of limited value as screening tools for occludable angles.^[21]

The measurement of the ACD has become increasingly important in ophthalmic practice, including in the planning of refractive surgery and refractive cataract surgery. These require extreme precision, and for these situations, automated modalities are preferred.

However, measurement of central ACD assumes importance in other conditions too – in plateau iris (classically shallow peripheral ACD, deep central ACD), aqueous misdirection (shallow central and peripheral ACD), overfiltering bleb (shallow central ACD), subluxated lens (irregular ACD), angle recession (deeper than fellow eye), and so on. In all these situations, a clinical assessment may suffice and may be quantified by SACD.

Barrett *et al.*^[22] validated the SACD method by comparing it with the pachymeter and ultrasonography and found that the estimates were within ± 0.33 when compared with the pachymeter and ± 0.42 relative to ultrasonography. The authors reported that using a ratio of 1.31 provided an accuracy of ± 0.33 mm, and with a ratio of 1.40, the accuracy improved (± 0.25 mm).

The advantage of this procedure is that it allows for rapid screening for measurement of the axial ACD with no requirement of specialized slit-lamp attachments. It is noninvasive and quantifiable, allowing for rapid screening of patients with shallow AC; it is especially useful in primary eye care clinics or in remote areas, where sophisticated equipment may not be available. Furthermore, the ongoing pandemic related to the highly contagious novel coronavirus (referred to as severe acute respiratory syndrome coronavirus 2 or SARS-CoV-2), which is capable of causing a severe respiratory disease (COVID-19), is associated with significant levels of mortality. Therefore, minimizing needless touch and points of contact (i.e., practicing “social distancing”) is mandatory to contain the spread of this highly contagious virus. Although there are several vaccines on the horizon at variable stages of development and deployment, we, as health care professionals, will have to continue to adopt practices that would reflect this social distancing, for a little while yet.^[23] This indeed is an ongoing mammoth task, fulfilled not only by health care and allied professionals but also by our patients worldwide. While the face-to-face proximity at the slit-lamp is essential and unavoidable (with adequate precautions – breath shields, mask, goggles/eye protection, face shields, rigorous disinfection, etc.), some other investigations may be dispensable under these extenuating circumstances. Knowledge of the slit-lamp assessment of the ACD is a step, however minor, that may contribute to mitigating this emergent requirement in ophthalmology practices worldwide. It may benefit by preventing extended periods of waiting in the outpatient departments for nonessential and expendable investigations thereby minimizing risk of exposure to the aerosolized virus, especially in the vulnerable groups.

On the other hand, the advantages of the automated modalities are that they are faster, with less technical skill requirement or interobserver variability. However, its main disadvantage is that it is a relatively expensive technology, hence its possible nonavailability in outreach primary centers. Therefore, knowledge of, and ability to perform, this relatively effortless skill is useful and is desirable in the clinical armamentarium of individuals imparting ophthalmic care.

There are a few limitations to our study. Clinical grading of PXF and the possibility of this influencing the ACD measurements were not taken into account. Furthermore, corneal opacity may preclude measurement of ACD via this method; therefore, only eyes with clear cornea were included in this study. However, to the best of our knowledge, there is no prospective clinical study that has quantitatively evaluated the axial ACD clinically in PXF eyes by Redmond Smith method or has reported its agreement with the measurements obtained via ASOCT and Lenstar.

Conclusion

The Smith methodology of estimating the axial ACD at the slit lamp can be used as a low-cost, rapid, quantifiable, noncontact screening technique during a routine clinical examination. We recommend its use especially in primary outreach centers, where sophisticated equipment may not be available. The use of this technique will also contribute to mitigating the need-of-the-hour in the ongoing pandemic related to the novel coronavirus, by preventing extended hospital stay for nonessential and expendable investigations and needless increased risk of exposure to the aerosolized virus.

Disclosures

Vanita Pathak-Ray (VPR)– Santen, Novartis, Allergan (Nil relevant)

Acknowledgments

We would like to thank Late Dr. Annie Mathai, MS, DNB, FRCS, for her invaluable guidance during the conduct of this study.

Financial support and sponsorship

This research did not receive any specific grant from funding agencies in the public, commercial, or not-for-profit sectors.

Conflicts of interest

There are no conflicts of interest.

References

- Schlötzer-Schrehardt UM, Koca MR, Naumann GO, Volkholz H. Pseudoexfoliation syndrome. Ocular manifestation of a systemic disorder? *Arch Ophthalmol* 1992;110:1752-6.
- Forsius, H., Prevalence of pseudoexfoliation of the lens in Finns, Lapps, Icelanders, Eskimos, and Russians. *Trans Ophthalmol Soc U* 1979;99:296-8.
- Cashwell LF Jr, Shields MB. Exfoliation syndrome in the south-eastern United States. I. Prevalence in open-angle glaucoma and non-glaucoma populations. *Acta Ophthalmol Suppl* 1988;184:99-102.
- Hiller R, Sperduto RD, Krueger DE. Pseudoexfoliation, intraocular pressure, and senile lens changes in a population-based survey. *Arch Ophthalmol* 1982;100:1080-2.
- Cashwell LF Jr, Shields MB. Exfoliation syndrome. Prevalence in a southeastern United States population. *Arch Ophthalmol* 1988;106:335-6.
- Faulkner HW. Pseudo-exfoliation of the lens among the Navajo Indians. *Am J Ophthalmol* 1971;72:206-7.
- Mitchell P, Wang JJ, Hourihan F. The relationship between glaucoma and pseudoexfoliation: The Blue Mountains eye study. *Arch Ophthalmol* 1999;117:1319-24.
- Philip SS, John SS, Simha AR, Jasper S, Braganza AD. Ocular clinical profile of patients with pseudoexfoliation syndrome in a tertiary eye care centre in South India. *Middle East Afr J Ophthalmol* 2012;19:231-6.
- Ritch R. Exfoliation syndrome—the most common identifiable cause of open-angle glaucoma. *J Glaucoma* 1994;3:176-7.
- Ritch R, Schlötzer-Schrehardt U, Konstas AG. Why is glaucoma associated with exfoliation syndrome? *Prog Retin Eye Res* 2003;22:253-75.
- Naumann GO. Exfoliation syndrome as a risk factor for vitreous loss in extracapsular cataract surgery (preliminary report). Erlanger-Augenblatter-Group. *Acta Ophthalmol Suppl* 1988;184:129-31.
- Küchle M, Viestenz A, Martus P, Händel A, Jünemann A, Naumann GO. Anterior chamber depth and complications during cataract surgery in eyes with pseudoexfoliation syndrome. *Am J Ophthalmol* 2000;129:281-5.
- Moreno J, Duch S, Lajara J. Pseudoexfoliation syndrome: Clinical factors related to capsular rupture in cataract surgery. *Acta Ophthalmol* 1993;71:181-4.
- Feng MT, Belin MW, Ambrósio R Jr, Grewal SPS, Yan W, Shaheen MS, *et al.* Anterior chamber depth in normal subjects by rotating scheinplflug imaging. *Saudi J Ophthalmol* 2011;25:255-9.
- Smith RJ. A new method of estimating the depth of the anterior chamber. *Br J Ophthalmol* 1979;63:215-20.
- Gross FJ, Tingey D, Epstein DL. Increased prevalence of occludable angles and angle-closure glaucoma in patients with pseudoexfoliation. *Am J Ophthalmol* 1994;117:333-6.
- Varma DK, Simpson SM, Rai AS, Ahmed IIK. Undetected angle closure in patients with a diagnosis of open-angle glaucoma. *Can J Ophthalmol* 2017;52:373-8.
- Damji KF, Chialant D, Shah K, Kulkarni SV, Ross EA, Al-Ani A, *et al.* Biometric characteristics of eyes with exfoliation syndrome and occludable as well as open angles and eyes with primary open-angle glaucoma. *Can J Ophthalmol* 2009;44:70-5.
- Doganay S, Tasar A, Cankaya C, Firat PG, Yologlu S. Evaluation of Pentacam-Scheinplflug imaging of anterior segment parameters in patients with pseudoexfoliation syndrome and pseudoexfoliative glaucoma. *Clin Exp Optom* 2012;95:218-22.
- Zheng X, Sakai H, Goto T, Namiguchi K, Mizoue S, Shiraishi A, *et al.* Anterior segment optical coherence tomography analysis of clinically unilateral pseudoexfoliation syndrome: Evidence of bilateral involvement and morphologic factors related to asymmetry. *Invest Ophthalmol Vis Sci* 2011;52:5679-84.
- Thomas R, George T, Braganza A, Muliylil J. The flashlight test and van Herick's test are poor predictors for occludable angles. *Aust N Z J Ophthalmol* 1996;24:251-6.
- Barrett BT, McGraw PV, Murray LA, Murgatroyd P. Anterior chamber depth measurement in clinical practice. *Optom Vis Sci* 1996;73:482-6.
- Olivia Li JP, Shantha J, Wong TY, Wong EY, Mehta J, Lin H, *et al.* Preparedness among Ophthalmologists: During and beyond the COVID-19 pandemic. *Ophthalmology* 2020;127:569-72.