

A 2-Year-Old Girl with Intermittent Vomiting

Tristan Reddan*

Medical Imaging and Nuclear Medicine, Lady Cilento Children's Hospital, South Brisbane, Queensland, Australia

SECTION 1: QUIZ

Case

This is the case of a 2-year-old female who presented with a 2-week history of intermittent nonbilious vomiting and diffuse abdominal pain. She had a history of gastroschisis repair as a neonate which involved an initial surgical reduction shortly after birth, returning as much bowel as possible. The remaining eviscerated bowel was placed in a silo for 5 days, after which the wound site and wall defect were surgically closed.

Figure 1 is a radiograph captured during a contrast swallow fluoroscopy procedure, figures 2 and 3 [Video 1] are transverse sonograms of the epigastric region.

WHAT IS YOUR DIAGNOSIS?

Declaration of patient consent

The authors certify that they have obtained all appropriate patient consent forms. In the form, the legal guardian has given his consent for images and other clinical information to be reported in the journal. The guardian understands that names and initials will not be published and due efforts will be made to conceal patient identity, but anonymity cannot be guaranteed.

Financial support and sponsorship

Nil.

Conflicts of interest

There are no conflicts of interest.

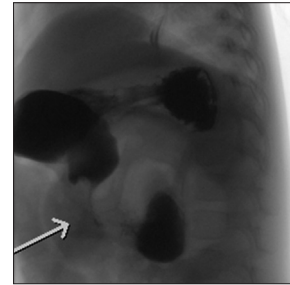


Figure 1: Contrast swallow radiograph

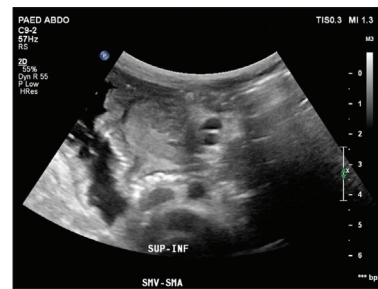


Figure 2: A transverse sonogram of the epigastric region across the patient's midline

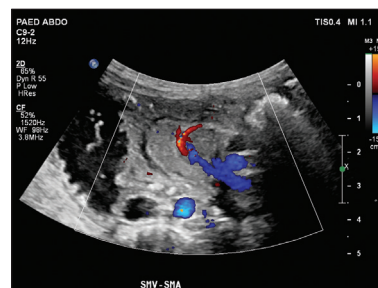


Figure 3: A transverse sonogram of the epigastric region across the patient's midline with color Doppler

Received: 24-10-2017 Accepted: 26-12-2017 Available Online: 28-03-2018

Video available on: www.jmuonline.org

Access this article online

Quick Response Code:



Website:
www.jmuonline.org

DOI:
10.4103/JMU.JMU_15_18

Address for correspondence: Mr. Tristan Reddan,
Medical Imaging and Nuclear Medicine, Lady Cilento Children's Hospital,
South Brisbane, Queensland, Australia.
E-mail: tristan.reddan@health.qld.gov.au

This is an open access journal, and articles are distributed under the terms of the Creative Commons Attribution-NonCommercial-ShareAlike 4.0 License, which allows others to remix, tweak, and build upon the work non-commercially, as long as appropriate credit is given and the new creations are licensed under the identical terms.

For reprints contact: reprints@medknow.com

How to cite this article: Reddan T. A 2-year-old girl with intermittent vomiting. J Med Ultrasound 2018;26:63.