

An Overview of Acute Hepatic Porphyrrias: Clinical Implications, Diagnostic Approaches, and Management Strategies

Tanyel Zübarioğlu , Ertuğrul Kıyıkım , Çiğdem Aktuğlu-Zeybek 

Division of Nutrition and Metabolism, Department of Pediatrics, İstanbul University-Cerrahpaşa, Cerrahpaşa Medical Faculty, İstanbul, Turkey

ABSTRACT

Porphyrias are inborn errors of heme biosynthesis pathway that result in neurovisceral and/or cutaneous manifestations which occur with episodic attacks, usually accompanied by a multisystemic involvement. Acute hepatic porphyrias include acute intermittent porphyria, variegate porphyria, hereditary coproporphyria, and aminolevulinic acid dehydratase deficiency porphyria. Acute hepatic porphyrias may present with symptoms of an affected central, peripheral, and autonomic nervous system and are generally diagnosed in time of an acute neurovisceral attack. In children, clinical picture is more complicated and presents with neurological findings predominantly. First-line investigation should be the urinary porphobilinogen and aminolevulinic acid performance when acute hepatic porphyria is clinically suspected. Comprehensive testing including urine porphyrin separation, fluorescence scanning of diluted plasma at neutral pH, evaluation of fecal porphyrins, and measurement of erythrocyte porphobilinogen deaminase activity is indicated for confirmation or exclusion of the porphyria and define the type of acute hepatic porphyrias. The main aim of the treatment is to decrease aminolevulinic acid, porphobilinogen, and porphyrins by reducing hepatic ALAS1 activity. The first measure should always be the avoidance of any porphyrinogenic drugs. Hemin therapy should not be delayed in the treatment of a severe acute attack. Gonadotropin-releasing hormone analogs and prophylactic hemin protocols can be used for selected cases with more than 4 attacks per year. Givosiran is a promising treatment option for severe cases.

Keywords: Porphyria, AHP, hemin, givosiran, PBG, prophylactic hemin

INTRODUCTION

The term “porphyria” is derived from the ancient Greek term “porphyros,” meaning purple. The term was first used by Phoenicians, who extracted a purple pigment from purpura mollusks to dye the clothes of their royal families. Later, in the Byzantine Empire, it was replaced by the term “porphyrogenitos: born to the purple,” meaning that the imperial heir was born after the father's accession to the throne in a colorful palace room. Beyond the myths about patients with porphyria in history such as King George III of Britain and Vincent van Gogh, clinical porphyria was first described in 1960s, and today, the pathogenesis of disease is well established.^{1,2}

Porphyrias are inborn errors of heme biosynthesis pathway that result in neurovisceral and/or cutaneous manifestations which occur with episodic attacks, usually accompanied by a multisystemic involvement. It is divided into 2 subgroups as hepatic or erythropoietic porphyria, depending on whether the pathway intermediates accumulate in the liver or bone marrow. In this review, clinical manifestations, diagnostic approaches, and management strategies of acute hepatic porphyrias (AHP), acute intermittent porphyria (AIP), variegate porphyria (VP), hereditary coproporphyria (HCP), and aminolevulinic acid dehydratase deficiency porphyria (ADP) are discussed.^{3,4}

Corresponding author:

Tanyel Zübarioğlu
✉ tanyel.zubarioğlu@iuc.edu.tr
Received: December 6, 2022
Accepted: December 9, 2022
Publication Date: December 29, 2022

Content of this journal is licensed under a Creative Commons Attribution-NonCommercial 4.0 International License.



Cite this article as: Zübarioğlu T, Kıyıkım E, Aktuğlu-Zeybek C. An overview of acute hepatic porphyrias: clinical implications, diagnostic approaches, and management strategies. *Turk Arch Pediatr.* 2023;58(1):3-9.

HEME BIOSYNTHESIS PATHWAY AND PATHOGENESIS OF AN ACUTE HEPATIC PORPHYRIA

Although heme biosynthesis occurs in almost all cell types, biosynthesis process is critical in 2 tissues: in the bone marrow (85%) primarily for hemoglobin synthesis and in hepatocytes (15%) for hemoproteins synthesis including cytochrome P450 enzymes. Physiological heme synthesis takes place in an 8-stepped enzymatic process; in which the first and the last 3 steps occur in the mitochondria, the others in the cytosol. Enzymatic steps of heme biosynthesis and the subclassification of inborn errors of heme metabolisms depending on the pathological enzyme activity are given in Figure 1.

- The first and rate-limiting enzyme in the heme biosynthetic pathway is 5-aminolevulinic acid-synthase (5-ALA-S) which is responsible for the condensation of glycine and succinyl-CoA. Enzymatic process requires pyridoxal-5-phosphate as a cofactor and results in 5-ALA formation.
- In the second step of the pathway, 2 molecules of 5-ALA move from mitochondria into the cytosol and form porphobilinogen (PBG) by the enzymatic activity of ALA dehydratase (ALAD).
- The third enzyme in heme biosynthesis is porphobilinogen deaminase (PBG-D) which was previously named as preuroporphyrinogen I synthase. It is responsible for deamination and condensation of 4 molecules of PBG to a linear tetrapyrrole hydroxymethylbilane (HMB).
- Next step of the pathway includes the enzymatic activity of uroporphyrinogen III synthase (UROS) that is involved in the synthesis of uroporphyrinogen III from HMB via

the reactions of intramolecular rearrangement and ring closure.

- In the fifth step of the pathway, a more hydrophobic metabolite coproporphyrinogen III is synthesized from uroporphyrinogen III by removal of the carboxymethyl side chains which are catalyzed by uroporphyrinogen decarboxylase (UROD).
- Coproporphyrinogen III first enters into the mitochondria and is converted to protoporphyrinogen IX and protoporphyrin IX by 2 consecutive oxidation reactions catalyzed by coproporphyrinogen oxidase (CPOX) and protoporphyrinogen oxidase (PPOX), respectively.
- The final step of heme biosynthesis pathway is catalyzed by ferrochelatase that is responsible for the insertion of ferrous iron (Fe²⁺) into protoporphyrin IX resulting in heme production.^{5,6}

The AHPs are caused by enzymatic deficiency of 4 different enzymes in heme biosynthetic pathway. 5-Aminolevulinic acid dehydratase deficiency porphyria is caused by the defective enzyme activity of ALAD and mainly results in ALA accumulation. Acute intermittent porphyria is the most common acute porphyria caused by defective enzyme activity of PBGD. Hereditary coproporphyria and variegate porphyria result from enzymatic deficiency of CPOX and PPOX, respectively.⁷

PATHOLOGIC HEME BIOSYNTHESIS AND ITS CONSEQUENCES ON NEUROTOXICITY IN ACUTE HEPATIC PORPHYRIA

Pathologic heme biosynthesis in AHP results in the accumulation of 2 main porphyrin precursors, ALA and PBG, which are

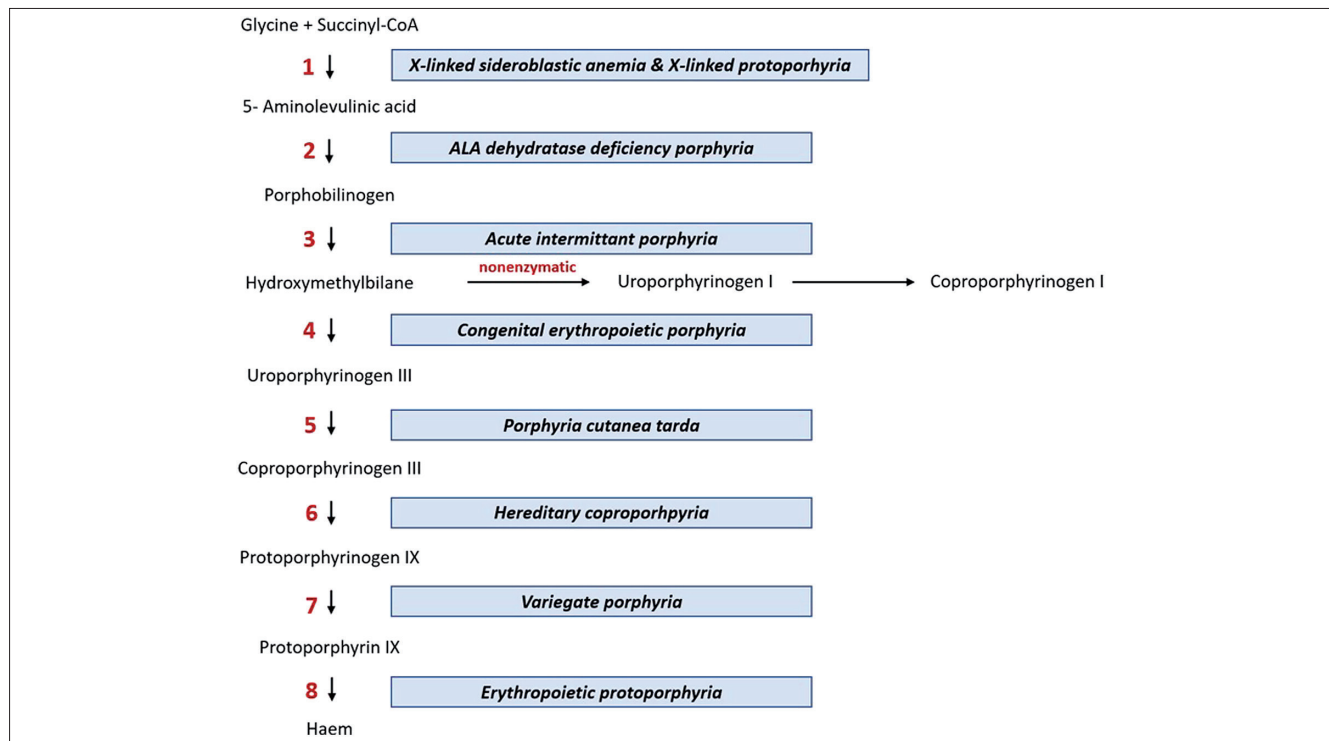


Figure 1. Intermediates and enzymes of the heme biosynthetic pathway. Each step is catalyzed by a different enzyme symbolized by numbers. 1: 5-aminolevulinic acid synthase, 2: 5-aminolevulinic acid dehydratase, 3: porphobilinogen deaminase, 4: uroporphyrinogen III synthase, 5: uroporphyrinogen decarboxylase, 6: coproporphyrinogen oxidase, 7: protoporphyrinogen oxidase, 8: ferrochelatase.

thought to be primarily involved in neurotoxicity. The concentrations of both ALA and PBG are remarkably elevated in circulation during an acute attack and can lead to vascular injury by increasing permeability and edema in central nervous system. Brain regions without blood-brain barrier protection such as hypothalamus and limbic area have tendencies to be severely affected by the circulating porphyrin precursors. In addition, ALA is structurally similar to γ -aminobutyric acid (GABA) and acts like a neurotransmitter upon GABA receptors.⁸

Liver plays a crucial role in producing large amounts of toxic porphyrin precursors during an acute attack. Evidence of the relationship between liver and neurotoxicity was shown by the clinical efficacy of liver transplantation over preventing attacks in patients with severe AIP. In addition, neuropathic symptoms consistent with porphyria developed in donors in domino liver transplants using liver from AIP patients.⁶

There are several hypotheses that are thought to be responsible for underlying pathophysiology of AHP findings, especially in AIP. These hypotheses can be summarized as follows:

- Deficiency of PBG deaminase can result in intracellular heme depletion and deficiency of hemoproteins essential for neuronal cells.
- Heme pathway intermediates or derivatized intermediates, especially ALA, can cause direct neurotoxicity.
- Concentrations of tryptophan in plasma and central nervous system can increase because of the decreased hepatic tryptophan pyrolyase activity which is caused by impaired hepatic heme synthesis and cause an elevation of neurotransmitter 5-hydroxytryptamine synthesis.⁹

UNDERSTANDING THE MOLECULAR MECHANISMS BENEATH ACUTE HEPATIC PORPHYRIAS: INHERITANCE, PENETRANCE, AND MOLECULAR HETEROGENEITY

Acute intermittent porphyria, variegate porphyria, and hereditary coproporphyria are inherited autosomal dominantly and show a low penetrance. In these patients, heterozygote mutations cause an approximately half-normal activity of the affected enzyme. In contrast, ADP is an autosomal recessively inborn error of metabolism, and homozygote or compound heterozygote mutations cause a severe enzymatic deficiency.⁷

In patients with autosomal dominantly inherited AIP, VP, and HCP, clinical signs consistent with acute porphyria and elevated ALA and PBG levels do not develop in the vast majority due to low penetrance. Individuals who are free of symptoms and carrying pathological mutation are named as "latent patients." Environmental factors and existence of modifier genes are thought to have a pivotal role in determination of the phenotype.³

The affected genes in each AHP are shown in Table 1. Regulatory gene defects in the 5'-promoter regions of the HMBS and UROS have also been reported. Recently, PEPT2 gene was reported as a modifier gene in AHP which was relevant to re-uptake of ALA into the renal cells. Polymorphism in PEPT2 genes has been associated with increased renal toxicity and higher ALA levels.^{10,11}

Table 1. Genotypic Features of Acute Hepatic Porphyrias

Porphyrin Subtype	Inheritance Pattern	Allele
Acute intermittent porphyria	AD	HMBS*
Variegate porphyria	AD	PPOX
Hereditary coproporphyria	AD	CPOX
ALA dehydratase deficiency porphyria	AR	ADP

*HMBS is also named as PBGD.
AD, autosomal dominant; ADP, aminolevulinic acid dehydratase deficiency porphyria; ALA, aminolevulinic acid; AR, autosomal recessive; CPOX, coproporphyrinogen oxidase; protoporphyrinogen oxidase.

The most well-known environmental factor affecting the porphyrinogenic phenotype is the hormonal changes that occur after puberty in female patients. In women, symptoms usually develop after puberty, and the incidence of porphyria after puberty is higher in females than males. It is thought to be closely dependent on the increase in progesterone levels. Indeed, increases in progesterone levels are associated with attacks during the luteal phase of the menstrual cycle in some women. Drugs, hormonal products, strict dietary restrictions, and smoking can be listed as other environmental factors.⁷

CLINICAL MANIFESTATIONS OF AN ACUTE HEPATIC PORPHYRIA

Acute hepatic porphyrias may present with symptoms of an affected central, peripheral, and autonomic nervous system and are generally diagnosed in time of an acute neurovisceral attack. Confusion, memory loss, depression, seizures, and hallucinations can develop from the affected central nervous system. Neuropathic pain, sensory loss, and muscle weakness are most frequent peripheral nervous system manifestations. Severe abdominal pain, hyponatremia, hypertension, tachycardia, and constipation are the cardinal signs of an acute neurovisceral attack caused by an affected autonomic nervous system involvement.^{3,9}

Cardinal Signs of an Acute Neurovisceral Attack

The most frequent finding is intense, diffuse, and persistent abdominal pain which is found in approximately 90% of patients. Nausea, vomiting, constipation, or diarrhea in a less context can accompany abdominal pain. Paralytic ileus and pancreatitis can be seen as gastrointestinal finding.

Neurological findings of the attack typically develop days to weeks after the onset of abdominal pain. Progressive muscle weakness is the most common neurologic manifestation and can progress to progressive bulbar palsy and respiratory failure in severe cases. More rarely, patients can exhibit neurosensitive symptoms localized in "glove and stocking" or "bathing trunk" distributions.

Cranial nerve involvement, arterial hypertension, and tachycardia are common in the course of an acute attack. Seizures can develop due to hyponatremia. Reported psychiatric manifestations including insomnia, depression, anxiety, and psychosis can mimic other psychiatric disorders and be conflicting in making a definite diagnosis.

Cutaneous manifestations in AHP are generally seen in VP and, rarely, in HCP and presented by blisters and fluid-filled bullae

on sun-exposed areas. However, in any case of a severe acute attack, cutaneous findings can occur because of the elevated porphyrin levels independent from the AHP subtype.^{4,9}

Natural History of Acute Hepatic Failure and Challenges in Pediatric Patients

As already mentioned, most patients carrying a disease-causing mutation do not develop any attack or experience only a few acute attacks during a lifetime due to the low penetrance of AHP. However, in pediatric-aged patients, the clinical picture can entirely be different from adult porphyria patients.

The first differing point in children is the predominant gender. Until puberty, a predominance of male gender is seen in pediatric AHP patients, following puberty, a female-to-male ratio starts to increase.

Main clinical findings also differ in children when compared to adult patients. In contrary to adults, abdominal pain is less common during attacks in pediatric-aged patients. However, AHP can reveal a severely complicated neurological disease in children. Hyponatremia and seizures relevant to hyponatremia can be challenging. In addition, systemic arterial hypertension has been more announced and difficult to control in children.¹²

DIAGNOSTIC ALGORITHM IN ACUTE HEPATIC PORPHYRIA

Precautions in Accurate Sampling Process

Pitfalls in laboratory diagnosis of AHP mainly result from inappropriate sample collection, storage, and/or shipment. Therefore, main bullets of sampling process are briefly summarized before introducing the diagnostic algorithm of an acute attack.

A spot 10–20 mL fresh early morning urine sample which is protected from light and collected preferably at the time of acute attack is recommended. The collection of a 24-hour urine sample is now not recommended to avoid diagnostic delays and misleading results due to incomplete collection and inappropriate storage. Quantitative urine measurements of ALA, PBG, and total porphyrins should be expressed per gram or mmol of creatinine. For measurement of fecal porphyrins, 5–10 g of stool sample can be collected into a container. Collection within 1–2 days of starting hemin can likely be suitable for stool as rate of fecal flow is slow. Blood should be collected preferably into a blood collection tube with Ethylenediaminetetraacetic acid (EDTA) anticoagulant, although heparinized whole blood is acceptable for a plasma fluorescence scan. Hemolyzed blood is unsuitable for plasma porphyrin analysis.

All samples should be protected from light by black plastic coverage or tin foil immediately after collection until the point of analysis. It is generally recommended that the analyses be completed within 24 hours of sampling in order to prevent porphyrin degradation. In cases of delays, fecal specimens should be frozen, urine and blood samples should be stored at 4°C, and all samples should be protected from light exposure.^{7,13}

First-Line Testing: Assessment of Urinary Porphobilinogen and Aminolevulinic Acid

First-line investigation should be the urinary PBG and ALA performance when AHP is clinically suspected. In healthy

individuals, normal ranges of urinary PBG excretion are 0–4 mg/day. Excretion of ALA is usually about half that of PBG. However, during an acute attack, PBG excretion can exceed 20–200 mg/day. In AIP patients, ALA and PBG can be measured persistently elevated even long after an acute attack. In HCP and VP patients, normalization of ALA and PBG is more rapid. Second-line testing is indicated to make a definite diagnosis of AHP subgroups in cases with elevated PBG and ALA.

Detection of elevated total porphyrins but normal urinary PBG is suggestive of ADP and urinary ALA excretion should be performed. Elevated urinary ALA levels can support the diagnosis, and second-line testing is usually indicated.

In case of significantly elevated ALA levels despite normal urinary PBG, secondary causes other than porphyria that may lead to ALA-dehydratase deficiency should be included in the differential diagnosis. Both hereditary tyrosinemia type 1 and lead poisoning (plumboporphyria) can cause elevated ALA levels by inhibiting ALAD mimic an acute porphyria attack. In suspicion of these secondary etiologies, urinary/plasma succinyl acetone analysis and measurement of lead in plasma and urine should be performed.¹³

Detection of normal urinary PBG, ALA, and porphyrin levels generally excludes the diagnosis of AHP. Second-line testing is not recommended, and if clinical suspicion remains, urinary PBG and ALA testing should be made when the patient is symptomatic.

Clinicians should be careful for the false-negative analysis as urine tests may be completely normal except for acute attacks. Sampling after the initiation of hemin treatment should also result in a false-negative urine test.

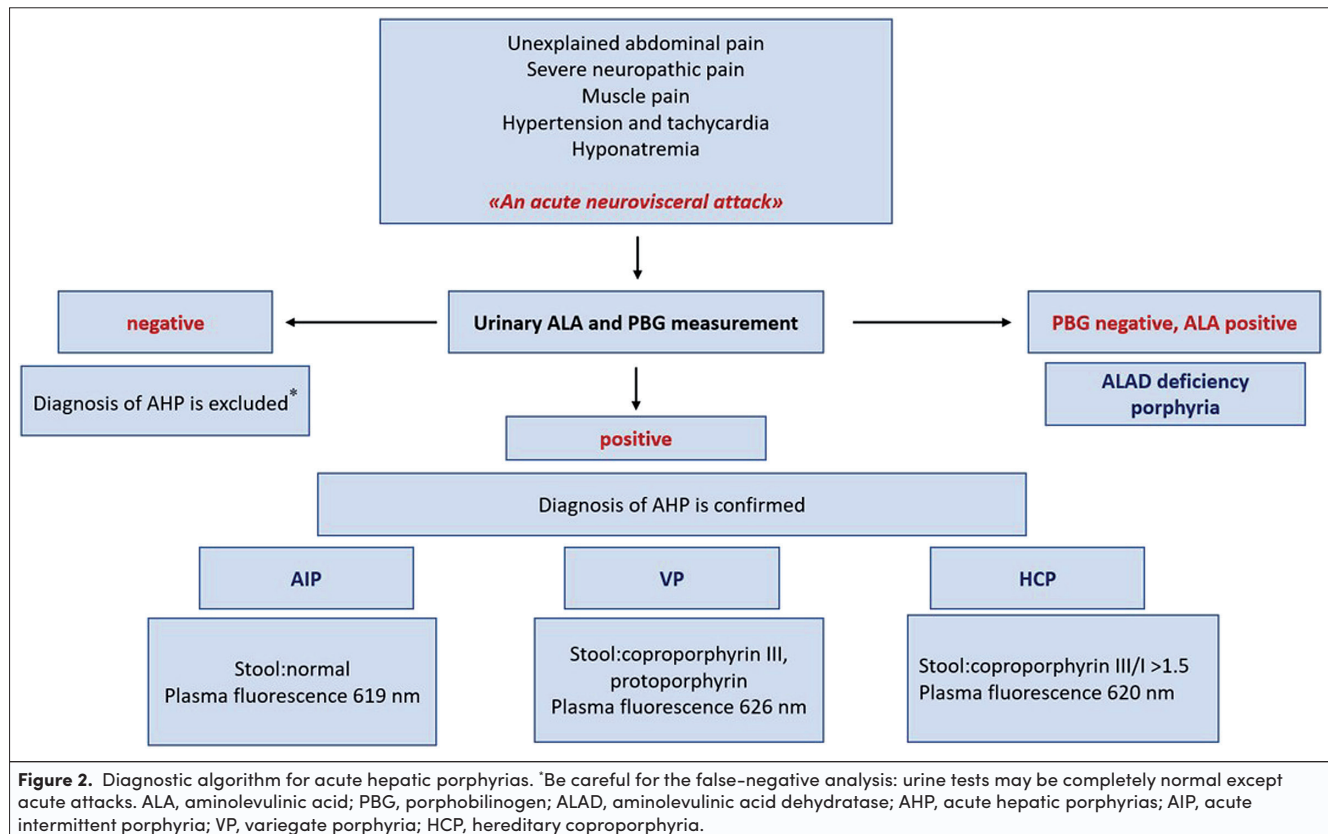
Biochemical analysis reveals some degree of hyponatremia which can be relevant to inappropriate antidiuretic hormone secretion. Mild leukocytosis and elevation of transaminases can be found. The reddish appearance of the urine is caused by elevated urinary porphyrins, since ALA and PBG are colorless.^{4,8,14}

Second-Line Testing: Confirming and Defining the Type of Acute Hepatic Porphyrria

Comprehensive testing including urine porphyrin separation, fluorescence scanning of diluted plasma at neutral pH, evaluation of fecal porphyrins, and measurement of erythrocyte PBG deaminase activity is indicated for confirmation or exclusion of the porphyria and define the type of AHP.

Urine porphyrin separation by high-performance liquid chromatography (HPLC) reveals the pattern of each porphyrins. During an acute attack, total urinary porphyrins can increase; therefore, it is a supportive measurement for including the diagnosis of AHP. Despite isolated elevated excretions are not diagnostic, it is known that uroporphyrin elevation is generally consistent with PBG elevation. In HCP and VP, elevated levels of coproporphyrin may persist apart from the acute phase contrary to AIP.

Fluorescence scanning of diluted plasma at neutral pH can give diagnostic clues about AHP subtypes. A fluorescence emission



peak positivity at 619 nm is highly suggestive of AIP, at 620 nm in HCP and at 626 ± 2 nm in VP.

Measurement of elevated fecal porphyrins is supportive of the diagnosis of HCP and VP. In HCP, coproporphyrin III predominance is seen; however, in VP, fecal amounts of coproporphyrin III and protoporphyrin are both elevated. The ratio of coproporphyrin III/I is a highly sensitive marker and levels exceeding 1.5 support the diagnosis of HCP. In AIP, fecal porphyrins are generally in normal ranges.^{7,8,14}

A practical diagnostic algorithm in clinical suspicion of acute neurovisceral attack of an AHP is given in Figure 2.

PROGNOSIS AND LONG-TERM COMPLICATIONS OF ACUTE HEPATIC PORPHYRIA

Primary liver cancers (PLC), including especially hepatocellular carcinoma (HCC) and cholangiocarcinoma in a lesser context, chronic kidney disease (CKD), and hypertension are the main complications of AHP.

Primary Liver Cancer: Hepatocellular Carcinoma and Cholangiocarcinoma

Risk of PLC is significantly increased in AIP patients; however, literature data are limited on sporadic cases in VP and HCP. Only a small subset of patients was found to develop cholangiocarcinoma.

There are different hypotheses about the pathophysiological changes underlying carcinogenesis in AIP patients. Direct toxicity of ALA and loss of antioxidant effects possibly developing

because of heme depletion and decreased energy production due to secondary mitochondrial failure are the most announced mechanisms.¹⁵

Low-risk groups in terms of PLC are described as younger patients, latent patients, and normal urinary PBG levels. Porphyria guidelines generally recommend screening AIP patients every 6-12 months by imaging and measurement of alpha-fetoprotein levels beginning from the age of 50 years.^{15,16}

Chronic Kidney Disease

Porphyria-associated kidney disease (PAKD) is a challenging, long-term, and degenerating complication and is observed in approximately 50% of symptomatic AIP patients. Renal lesions of PAKD are characterized by tubular atrophy and interstitial fibrosis, and less frequently, chronic fibrous intimal hyperplasia is associated with focal cortical atrophy. End-stage renal disease can also develop in the course of PAKD.¹⁷

Hypertension is a common complication in AHP patients and hypertensive damage was thought to be responsible for PAKD. However, renal impairment can also develop in the absence of hypertension. Direct toxicity of porphyrin precursors and oxidative damage are the other possible factors that affect renal functions. Recently, a modifier gene PEPT2 was found relevant to severe kidney disease in AIP patients.^{18,19}

PREGNANCY IN ACUTE HEPATIC PORPHYRIA: A POTENTIALLY DANGEROUS CROSSROAD

Women with AIP are more vulnerable during pregnancy. Increased hormonal levels, caloric deprivation caused by

hyperemesis, and use of any porphyrinogenic drugs during labor can contribute to an increased tendency to acute attacks. In the past, pregnancy was associated with a significant morbidity for women with AHP; however, today, taking the right precautions regarding this issue has reduced morbidity.

The required measures for a safe pregnancy can be listed as the involvement of porphyria specialists in the patients' maternal care, prelabor carbohydrate loading, infusion of glucose during labor, and avoidance of porphyrinogenic drugs.^{20,21}

There are limited data about the use of heme arginate treatment during pregnancy which states that it could be a safe option in selected individuals. It is generally recommended that heme arginate treatment can be an option in cases with frequent and severe attacks despite supportive treatment with intravenous glucose and avoidance of triggering factors.²²

THERAPEUTIC APPROACHES IN ACUTE HEPATIC PORPHYRIA

General Aspects in Management of an Acute Porphyria Attack

The main aim of the treatment is to decrease ALA, PBG, and porphyrins by reducing hepatic ALAS1 activity. The first measure should always be the avoidance of any porphyrinogenic drugs (a database of safe and unsafe medications can be found here: www.drugs-porphyrria.org). The other triggering factors including caloric restrictions, smoking, and alcohol should be avoided. Infections should properly be treated.³

Daily dietary intake may consist adequate energy in appropriate contents of protein, fat, and carbohydrate and should maintain weight. During an acute attack, high glucose infusions (approximately up to 450-600 g/day) can decrease the excretion of porphyrin precursors and improve the clinical status of the patients as glucose acts as a downregulator of hepatic 5-ALAS1 transcription. Plasma sodium levels should be checked closely during high glucose infusions as it can precipitate hyponatremia.⁵

Pain is a cardinal and challenging symptom of AHP; patients generally need an opioid analgesic during an acute attack. During the selection of analgesics, it should be checked whether the selected drug is on the safe drug list. Among opioids, morphine is considered as a safe option. Hypertension, tachycardia, correction of hyponatremia, and gastrointestinal symptoms such as nausea and vomiting should be treated appropriately.³

Intravenous Hemin Treatment

Hemin (Panhematin®) was approved in the US in 1983, heme arginate (Normosang®) in 2006 in the European Union, and both drugs have been accepted as the standard first-line treatment of an acute neurovisceral attack.⁵ Similar to glucose loading, hemin/heme acts also as a hepatic ALAS1 transcription downregulator. However, they are more effective in replenishing heme pool when compared to glucose. Therefore, hemin therapy should not be delayed in the treatment of a severe acute attack. They are administered intravenously and main complication is thrombophlebitis. Usage of a large venous catheter and reconstitution of the drug with human serum albumin may reduce the risk of thrombophlebitis.²³

Prophylactic/Regular Hemin Treatment Protocols

Prophylactic hemin treatment should be a therapeutic option in patients resistant to general measures and who experience more than 4 attacks per year. However, there is still no guideline for prophylactic hemin treatment clarifying the optimal frequency of therapy or cessation protocol. As a result, this treatment protocol should be individualized for each patient. Literature data stated that prophylactic infusions can ameliorate acute attacks by 75%-100%. Common complications during the course of treatment were infection and thrombosis of the venous access. Another condition to be careful of and needs follow-up is iron accumulation.²⁴⁻²⁶

Gonadotropin-Releasing Hormone Analogs

Gonadotropin-releasing hormone (GnRH) analogs can improve the attacks, especially precipitated by menstrual cycles by suppressing the endogenous production of sex hormones.²⁷ Females in whom acute attack is associated with menstrual cycle can be treated with GnRH analogs if they experience more than 4 attacks per year. Both intranasal and subcutaneous preparations are available. First dose should be given in the first 5 days of the menstrual cycle. The major side effect of GnRH analogs is secondary estrogen deficiency.²⁸

A siRNA-Based Therapy: Givosiran

Givosiran is an ALAS1-specific siRNA that is covalently linked to N-acetyl galactosamine. Following its administration via subcutaneous route, it is uptaken to hepatocytes. After uptake into hepatocytes, the siRNA is processed by the cellular enzyme dicer into approximately 20 bp long single strands which bind to ALAS1 mRNA and target it for destruction. The whole process results in reduced translation of the ALAS1 protein and ALA production. Givosiran was approved by the Food and Drug Administration in November 2019 for adult AHP patients.^{29,30}

Isolated liver, isolated kidney, and combined liver and kidney transplantations should be considered as a curative option in selected individuals as a treatment option in AHP.^{17,31,32}

CONCLUSION

In summary, AHP should always be considered in patients with severe abdominal pain, peripheral neuropathy, and resistant hyponatremia. The predominance of neurological signs including seizures and severe hypertension should be kept in mind as the clinical presentations of AHP in childhood period. As the manifestations of AHP can mimic many other disorders, it should be included in differential diagnosis of lead poisoning, Guillain-Barré Syndrome, vasculitis, and polymyositis. All such patients should have at least 1 test for urinary ALA and PBG performed during or shortly after one of these acute attacks. The first measure should always be the avoidance of any porphyrinogenic drugs. Hemin therapy should not be delayed in the treatment of an acute attack.

Peer-review: Externally peer-reviewed.

Author Contributions: Concept – T.Z, E.K, Ç.A.Z.; Design – T.Z., E.K., Ç.A.Z.; Supervision – Ç.A.Z.; Literature Review – T.Z., E.K.; Writing – T.Z.; Critical Review – E.K., Ç.A.Z.

Declaration of Interests: The authors have no conflict of interest to declare.

Funding: The authors declared that this study has received no financial support.

REFERENCES

1. Macalpine I, Hunter R, Rimington C. Porphyrin in the royal houses of Stuart, Hanover, and Prussia. A follow-up study of George 3d's illness. *Br Med J*. 1968 ;1(5583):7-18. [\[CrossRef\]](#)
2. Arnold WN. The illness of Vincent van Gogh. *J Hist Neurosci*. 2004;13(1):22-43. [\[CrossRef\]](#)
3. Marcacci M, Ricci A, Cuoghi C, Marchini S, Pietrangelo A, Ventura P. Challenges in diagnosis and management of acute hepatic porphyrias: from an uncommon pediatric onset to innovative treatments and perspectives. *Orphanet J Rare Dis*. 2022;17(1):160. [\[CrossRef\]](#)
4. Rigor J, Pinto SA, Martins-Mendes D. Porphyrins: a clinically based approach. *Eur J Intern Med*. 2019;67:24-29. [\[CrossRef\]](#)
5. Petrides PE. Therapy follows diagnosis: old and new approaches for the treatment of acute porphyrias, what we know and what we should know. *Diagnostics (Basel)*. 2022;12(7):1618. [\[CrossRef\]](#)
6. Phillips JD. Heme biosynthesis and the porphyrias. *Mol Genet Metab*. 2019;128(3):164-177. [\[CrossRef\]](#)
7. Anderson KE. Acute hepatic porphyrias: current diagnosis & management. *Mol Genet Metab*. 2019;128(3):219-227. [\[CrossRef\]](#)
8. Kauppinen R. Porphyrins. *Lancet*. 2005;365(9455):241-252. [\[CrossRef\]](#)
9. Bonkovsky HL, Dixon N, Rudnick S. Pathogenesis and clinical features of the acute hepatic porphyrias (AHPs). *Mol Genet Metab*. 2019;128(3):213-218. [\[CrossRef\]](#)
10. Yasuda M, Chen B, Desnick RJ. Recent advances on porphyria genetics: inheritance, penetrance & molecular heterogeneity, including new modifying/causative genes. *Mol Genet Metab*. 2019;3(3):320-331. [\[CrossRef\]](#)
11. Chen B, Whatley S, Badminton M, et al. International porphyria Molecular Diagnostic Collaborative: an evidence-based database of verified pathogenic and benign variants for the porphyrias. *Genet Med*. 2019;21(11):2605-2613. [\[CrossRef\]](#)
12. Jaramillo-Calle DA, Martinez YA, Balwani M, Fernandez C, Toro M. Porphyrin attacks in prepubertal children and adolescents. *Mol Genet Metab*. 2021;133(3):242-249. [\[CrossRef\]](#)
13. Woolf J, Marsden JT, Degg T, et al. Best practice guidelines on first-line laboratory testing for porphyria. *Ann Clin Biochem*. 2017;54(2):188-198. [\[CrossRef\]](#)
14. Ventura P, Cappellini MD, Biolcati G, Guida CC, Rocchi E, Gruppo Italiano Porfiria (GrIP). A challenging diagnosis for potential fatal diseases: recommendations for diagnosing acute porphyrias. *Eur J Intern Med*. 2014;25(6):497-505. [\[CrossRef\]](#)
15. Peoc'h K, Manceau H, Karim Z, et al. Hepatocellular carcinoma in acute hepatic porphyrias: a Damocles Sword. *Mol Genet Metab*. 2019 ;128(3):236-241. [\[CrossRef\]](#)
16. Ramai D, Deliwala SS, Chandan S, et al. Risk of hepatocellular carcinoma in patients with porphyria: a systematic review. *Cancers (Basel)*. 2022;14(12):2947. [\[CrossRef\]](#)
17. Lazareth H, Talbi N, Kamar N, et al. Kidney transplantation improves the clinical outcomes of Acute Intermittent porphyria. *Mol Genet Metab*. 2020;131(1-2):259-266. [\[CrossRef\]](#)
18. Ricci A, Guida CC, Manzini P, Cuoghi C, Ventura P. Kidney involvement in acute hepatic porphyrias: pathophysiology and diagnostic implications. *Diagnostics (Basel)*. 2021;11(12):2324. [\[CrossRef\]](#)
19. Pallet N, Mami I, Schmitt C, et al. High prevalence of and potential mechanisms for chronic kidney disease in patients with acute intermittent porphyria. *Kidney Int*. 2015 ;88(2):386-395. [\[CrossRef\]](#)
20. Vassiliou D, Sardh E. Acute hepatic porphyria and maternal health: clinical and biochemical follow-up of 44 pregnancies. *J Intern Med*. 2022;291(1):81-94. [\[CrossRef\]](#)
21. Aggarwal N, Bagga R, Sawhney H, Suri V, Vasishtha K. Pregnancy with acute intermittent porphyria: a case report and review of literature. *J Obstet Gynaecol Res*. 2022;28(3):160-162. [\[CrossRef\]](#)
22. Vassiliou D, Lempecci C, Harper P, Sardh E. Challenges in the management of acute intermittent porphyria with recurrent attacks during pregnancy: a case report. *Clin Case Rep*. 2020;8(12):2483-2487. [\[CrossRef\]](#)
23. Fontanellas A, Ávila MA, Anderson KE, Deybach JC. Current and innovative emerging therapies for porphyrias with hepatic involvement. *J Hepatol*. 2019;71(2):422-433. [\[CrossRef\]](#)
24. Kuo HC, Lin CN, Tang YF. Prophylactic heme arginate infusion for acute intermittent porphyria. *Front Pharmacol*. 2021;12:712305. [\[CrossRef\]](#)
25. Yarra P, Faust D, Bennett M, Rudnick S, Bonkovsky HL. Benefits of prophylactic heme therapy in severe acute intermittent porphyria. *Mol Genet Metab Rep*. 2019;19:100450. [\[CrossRef\]](#)
26. Marsden JT, Guppy S, Stein P, et al. Audit of the use of regular haem arginate infusions in patients with acute porphyria to prevent recurrent symptoms. *JIMD Rep*. 2015;22:57-65. [\[CrossRef\]](#)
27. Andersson C, Innala E, Bäckström T. Acute intermittent porphyria in women: clinical expression, use and experience of exogenous sex hormones. A population-based study in northern Sweden. *J Intern Med*. 2003;254(2):176-183. [\[CrossRef\]](#)
28. Schulenburg-Brand D, Gardiner T, Guppy S, et al. An audit of the use of gonadorelin analogues to prevent recurrent acute symptoms in patients with acute porphyria in the United Kingdom. *JIMD Rep*. 2017;36:99-107. [\[CrossRef\]](#)
29. Sardh E, Harper P. RNAi therapy with givosiran significantly reduces attack rates in acute intermittent porphyria. *J Intern Med*. 2022;291(5):593-610. [\[CrossRef\]](#)
30. Wang B. Novel treatment options for acute hepatic porphyrias. *Curr Opin Gastroenterol*. 2021;37(3):194-199. [\[CrossRef\]](#)
31. Soonawalla ZF, Orug T, Badminton MN, et al. Liver transplantation as a cure for acute intermittent porphyria. *Lancet*. 2004;363(9410):705-706. [\[CrossRef\]](#)
32. Wahlin S, Harper P, Sardh E, Andersson C, Andersson DE, Ericzon BG. Combined liver and kidney transplantation in acute intermittent porphyria. *Transpl Int*. 2010;23(6):e18-e21. [\[CrossRef\]](#)